(Acta Urologica Japonica
Vol. 11, No. 2 Feb. 1965)

ULTRASONIC DIAGNOSIS OF PROSTATIC CANCER

Kaoru GOTOH and Moriya NISHI

From the Gifu University School of Medicine, Department of Urology, Gifu, Japan
(Director : Prof. K. Gotoh)

Since about twenty years ago, ultrasonic methods have been used for the detection of submarines, fish finding and flaw detection of metal. Now ultrasonics have been applied to medical purpose. Recently, many reports on ultrasonic diagnosis have been published, but only a few reports (Schlegel, Takahashi, Gotoh etc.) have appeared in the field of urology. In this paper, the authors will present the results of ultrasonic diagnosis of prostatic cancer.

ULTRASONIC APPARATUS

The ultrasonic apparatus used by the authors was a portable Aloka SSD-2B which was designed for A-scope indication (Fig. 1, Japan Radio Co.). The A-scope indication is to display the ultrasonic echoes as wave forms. A special transducer, UST-1110 built by Takahashi and co-workers which was designed for the transrectal method to scan the prostate was used (Fig. 2). The frequency was 5 megacyles.

ULTRASONIC EXAMINATIONS OF THE PROSTATE BY TRANSRECTAL METHOD

Ultrasonic examinations of the prostate by transrectal method were performed as follows :

1. Preliminary test

The special transducer was covered with a rubber sack and this was made water tight at its neck. Then it was filled with 100 to 250 ml of water with a syringe (Fig. 3). Care was taken not to mix air. Thus, only echoes reflected from the rubber sack could be scanned.

2. Transrectal method.

The patient was placed on a cystoscopic table in the supine lithotomy position. The special transducer which was covered with a rubber sack was inserted into the anus under the guide of the tip of a forefinger of the examiner so as to be in contact directly with the rectal mucosa in the region of the prostate. Then the sack was filled with 200 to 300 ml of water without mixing air (Fig. 4). After this procedure, the echoes which were reflected from the prostate could be scanned.

3. Conditions of the ultrasonic apparatus to scan the prostate.

To find the most suitable conditions of the apparatus, studies were made under the following conditions :

a) EREO (impulse frequency): 5 MC ……constant

b) PULSE RATE : 500 c/s……constant

c) POWER : 100V ……constant

d) H. AMP (horizontal amplifier) : ……constant

e) MARKER (marker generator) : As one unit graduation on the cathode ray tube was adjusted to correspond to one centimeter, the distance from the rectal mucosa to the prostate could be measured.

f) GAIN (gain of receiving amplifier) : 10 ……constant

g) REJECTION : 10 ……constant

Accepted for publication October 2, 1964.

h) PULSE L (pulse length) : Variable

This is to say that only the condition of PULSE L was varied stepwise, and the ultrasonic procedure was performed, the other conditions being kept constant.

If the graduation of PULSE L is elevated, the width of the transmitted pulse is increased and then the ability of receiving the echoes is enhanced. On the contrary, if the graduation is dropped, the width of the transmitted pulse is decreased and then the ability of analysis is enhanced. Therefore, the authors performed the ultrasonic procedure under such conditions that PULSE L was varied from 0 to 0.5, 1.0, 2.0, 3.0, 4.0 and more.

4. Materials.

Ultrasonic examinations of the normal prostate, benign prostatic hypertrophy and prostatic cancer were carried out under the previously mentioned conditions that PULSE L was varied from 0 to 4 or more.

Cases of which echo patterns are presented in the figure are as follows : a 41-year-old healthy man who has a normal prostate, a 75-year-old man who was diagnosed as having benign prostatic hypertrophy by rectal examination, by urethrography and by needle biopsy and a 65-year-old man who was diagnosed as having prostatic cancer by the same diagnostic methods as used in the benign prostatic hypertrophy.

UNDER CONDITIONS THAT PULSE L WAS VARIED FROM 0 *TO* 1.0 :

Echoes reflected from the rubber sack or from the prostate could not be detected in all the cases.

UNDER CONDITIONS THAT PULSE L WAS VARIED FROM 1.0 *TO* 2.0 :

The echo reflected from the rubber sack could be detected. No echo could be detected from the normal prostate. The echoes reflected from benign prostatic hypertrophy and prostatic cancer could be detected, but they showed no difference between each other.

UNDER CONDITIONS THAT PULSE L WAS VARIED FROM 2.0 *TO* 3.0 :

The echo reflected from the rubber sack could be detected (Fig. 5). The echo reflected from the normal prostate could be detected as a weak echo pattern (Fig. 6). The echo reflected from benign prostatic hypertrophy could be detected as a sharp independent echo pattern (Fig. 7). The echo reflected from prostatic cancer could be detected as an irregular and continued echo pattern (Fig.8).

UNDER CONDITIONS THAT PULSE L WAS VARIED FROM 4.0 *TO MORE* :

The echoes reflected from the prostates of all the cases could be detected as complex echo patterns and therefore no distinct difference was found among each case.

DISCUSSION

Under such conditions of the apparatus that PULSE L was varied and the other conditions were kept constant, ultrasonic examinations of the prostate by transrectal method were performed. The echo patterns obtained by the method mentioned above are as follows :

PULSE L	Normal	Benign Prostatic Hypertrophy	Prostatic Cancer
1.0	−	+	÷
2.0	÷	+	+
3.0	+	+	+
echo pattern	weak	sharp and independent	irregulara nd continued

Under conditions that PULSE L was 4.0 or more, the echo patterns obtained from the normal prostate, the benign prostatic hypertrophy and the prostatic cance rwere complex ; therefore, no diagnostic value was found in this range of PULSE L.

In other words, in ultrasonic examina tions of the prostatic cancer the optimal condition to be used is that PULSE L is from 2.0 to 3.0. This method yields neither danger nor pain to patients.

SUMMARY

Ultrasonic diagnosis of prostatic cancer by transrectal method was reported. Echo patterns, including that of prostatic cancer, were presented and discussed and then its cancer echo was shown.

This study was presented before the Fifth Meeting of the Japan Society of Ultrasonics in Medicne held in Tokyo, on May 21, 1964.

BIBLIOGRAPHY

1. Schlegel, J. U., Diggdon, P. and Cuellar J. : The Use of Ultrasound for Localizing Renal Calculi. J. Urol., **86** : 367—369, 1961.
2. Takahashi, H. and Ouchi, T. : The Ultrasonic Diagnosis in the Field of Urology : On the Diagnosis of Prostate Disease. Japanese Medical Ultrasonics, 1963.
3. Gotoh, K. et al. : Ultrasonic Diagnosis in Urological Diseases. Acta Urol. Jap., **9** : 560—563, 1963.

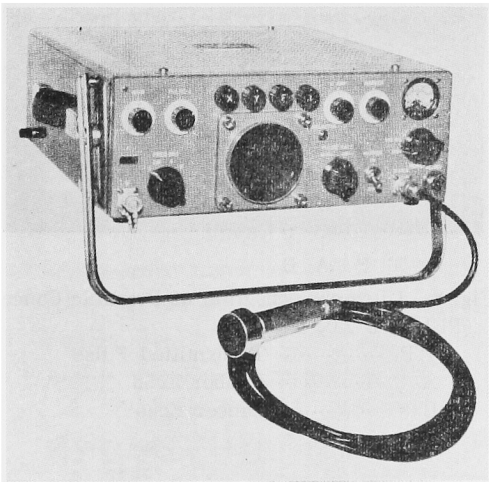

Fig. 1. Ultrasonic Diagnostic Apparatus (A-Scope Indication, Japan Radio Co.)

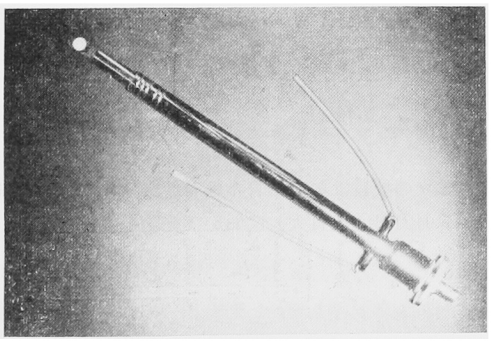

Fig. 2. Special Transducer for Transrectal Method.

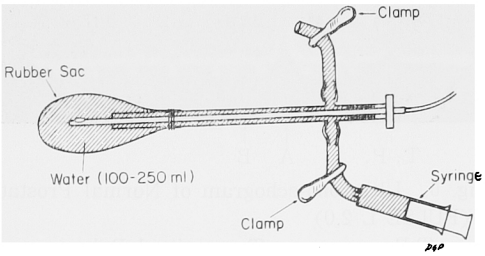

Fig. 3. Special Transducer Covered with a Rubber Sack.

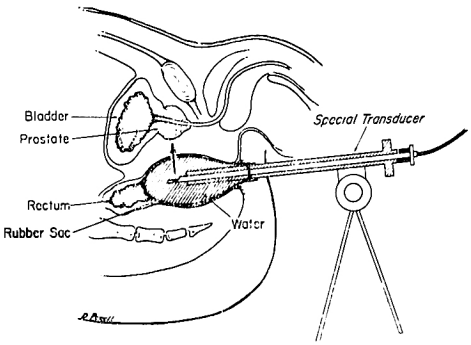

Fig. 4. Schema of Ultrasonic Examination of Prostate by Transrectal Method.

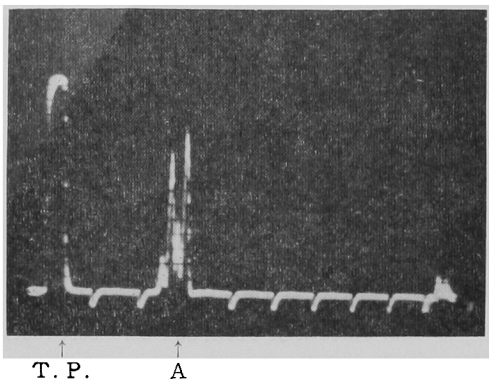

Fig. 5. Ultrasono-echogram of Rubber Sack (PULSE L 2.0)
T.P. ····· Transmitted Pulse
A ····· Rubber Echo

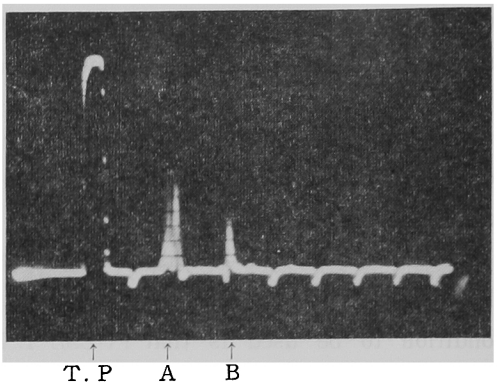

Fig. 7. Ultrasono-echogram of Benign Prostatic Hypertrophy (PULSE L 2.0)
T.P. ····· Transmitted Pulse
A ····· Rubber Echo
B ····· Hypertrophy Echo

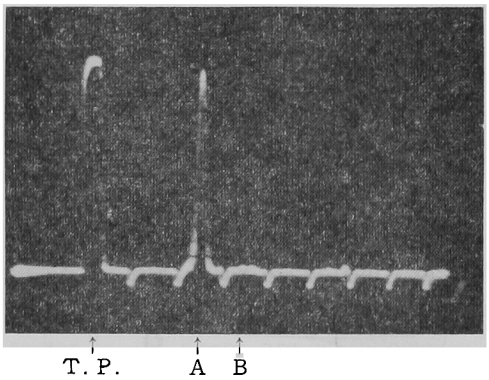

Fig. 6. Ultrasono-echogram of Normal Prostate (PULSE L 2.0)
T.P. ····· Transmitted Pulse
A ····· Rubber Echo
B ····· Prostate Echo

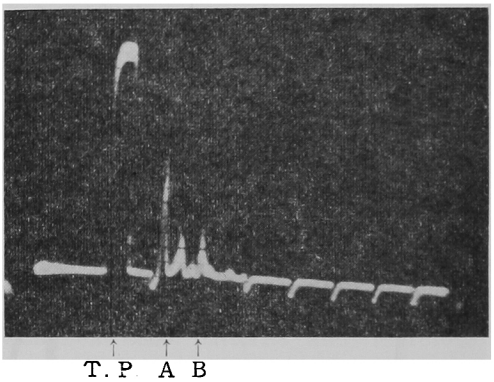

Fig. 8. Ultrasono-echogram of Prostatic Cancer (PULSE L 2.0)
T.P. ····· Transmitted Pulse
A ····· Rubber Echo
B ····· Cancer Echo

前立腺癌の超音波診断法

岐阜大学医学部泌尿器科教室（主任　後藤　薫教授）
教　　授　後　藤　　薫
大学院学生　西　　守　哉

前立腺癌の経直腸的方法による超音波診断法について述べた．

本論文の要旨は第5回日本超音波医学研究会（昭和39年5月21日，於日大）において発表した．