

NON-HORMONAL ADRENOCORTICAL ADENOMA WITH ONCOCYTOMA-LIKE APPEARANCES

Shigeru KAKIMOTO, Yoshiaki YUSHITA, Takeshi SANEFUJI
and Atsushi KONDO

*From the Department of Urology, Isahaya General Health Insurance Hospital
(Chief. Dr. S. Kakimoto)*

Naoki FUJISHIMA

*From the Department of Internal Medicine, Isahaya General Health Insurance Hospital
(Chief. Dr. H. Kuratsune)*

Masao KISHIKAWA and Koji MATSUMOTO

*From the Department of Pathology, Atomic Disease Institute, Nagasaki University School of Medicine
(Director: Prof. I. Nishimori)*

We report a case of non-hormonal adrenocortical adenoma. The tumor was removed en block with the adrenal gland. The specimen was $5.0 \times 4.5 \times 3.0$ cm, weighed 30 g and was solid.

Histologically, this tumor had an oncocytoma-like appearance. However, as there is no concept of oncocytoma in connection with adrenocortical adenoma, this case was diagnosed as adrenocortical adenoma. A case with such histological findings has never been reported.

Key words: Non-hormonal, Adrenocortical adenoma, Oncocytoma

INTRODUCTION

The non-hormonal adrenal tumor is a relatively rare disease. The non-hormonal adrenocortical adenoma, in particular, has been so rare in Japan that we could find only 14 cases in reports published since the report by Hayashi (1961)¹⁾. We experienced a case of non-hormonal adrenocortical adenoma with an oncocytoma-like histological appearance which has never been described in the previous reports on adrenocortical adenoma.

CASE REPORT

Patient: S.T. A 41-year-old housewife.

Chief complaint: Sense of general fatigue.

Family history: Nothing particularly remarkable.

Past history: Appendectomy at the age of 24 years. Iodine allergy upon CT scan-

ning.

Present illness: The patient complained of sweating, chills and shiver and consulted the Department of Internal Medicine in our hospital on June 16, 1983. Therapy was initiated for mild hyperthyroidism. The abdominal echo taken on June 20 revealed the suspicion of a pancreas tail cyst. Laboratory findings showed no specifically abnormal findings.

The abdominal echo was again found on October 12, 1983, when a round hypoechogenic mass was found adjacent to the upper pole of left kidney and spleen as shown in Fig. 1. The size and the properties of the hypoechogenic mass remained almost unchanged from those of the previous findings. A left adrenal tumor was suspected. As shown in Fig. 2, the CT scanning revealed a round mass in the upper part of the left kidney, and a part of its periphery was calcified.

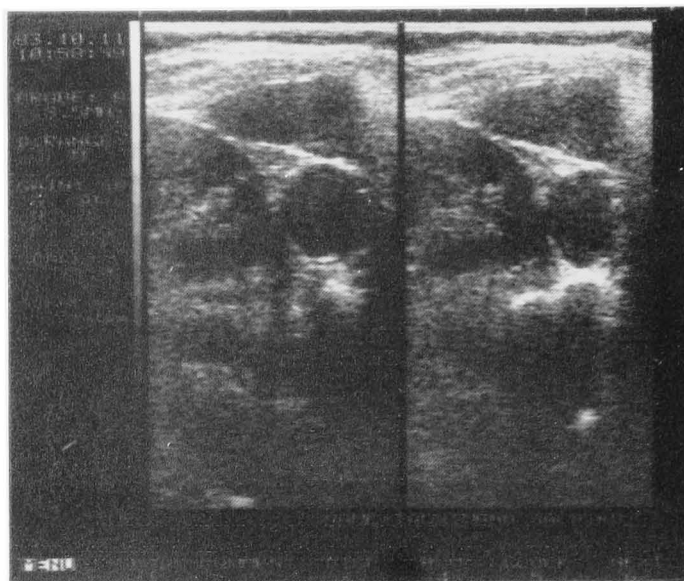


Fig. 1. Abdominal echo revealed a round hypoechoic mass adjacent to the upper pole of left kidney and spleen.

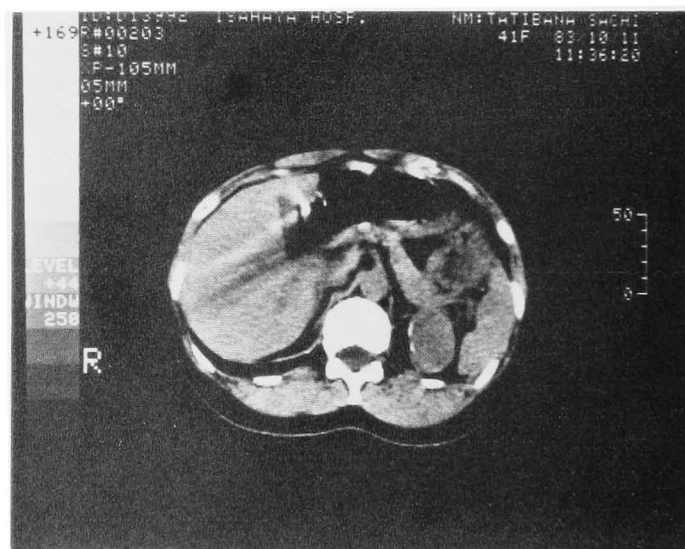


Fig. 2. CT scanning revealed a round mass in the upper part of the left kidney, and a part of its periphery was calcified.

On the basis of the above findings, the patient was admitted to our department on November 24, 1983 with the suspicion of left adrenal tumor or a retroperitoneal tumor.

Present status: Height 159 cm, weight 52.5 kg, and pulse 72/min, regular, blood pressure 110/78 mmHg, anemia (—). There was no abnormality in the heart or

lungs. In the abdomen no tumor was palpable. Neither liver, spleen nor kidney were palpable. There was no swelling of the superficial lymph nodes.

The laboratory findings: erythrocyte sedimentation rate at 1 and 2 hours, was 5 mm and 15 mm, respectively, peripheral blood smear showed on RBC of 409×10^4 , Hgb of 12.5 g/dl, Hct of 37%, WBC of 4000,

(Eosin of 1, Seg of 55, Mono of 1, Stab of 6 and Lymph of 37), Throm cyt of 25.3×10^4 , Reti cyt of 5%, Prothrombin time of 10.7 seconds, APTT of 26.5 seconds, Fibrinogen of 250 ng/ml and FDP of less than 10 MCG/dl.

Biochemical findings: Total bilirubin was 0.50 mg/dl, direct bilirubin was 0.15 mg/dl, TP was 7.3 g/dl, (Al; 65.9%, α_1 ; 3.1%, α_2 ; 7.7%, β ; 8.1%, γ ; 15.2%), ZnTT was 4.6 u, cholinesterase was 0.98 pH, cholesterol T was 203 ng/dl, GOT was 18 u, GPT was 10 u, γ -GTP was 10 IU/dl, LDH was 183 u, amylase was 129 somogyi unit, BUN was 18 mg/dl, Creatinine was 0.7 mg/dl, Uric acid was 3.8 mg/dl, Na was 141 mEq/l, K was 3.8 mEq/l, Cl was 104 mEq/l, Ca was 4.9 mEq/l, P was 3.6 mg/dl, Neutral fat was 62 mg/dl, and FPG (fasting plasma glucose) was 104 ng/dl. The basal metabolic rate was 4%.

Urinalysis revealed pale yellow urine with sugar (—), protein (—), sediment, RBC : 0–1/hpf, WBC : 0–1/hpf. Renal functions: In the Fishberg test; 1032, 1038 and 1036, PSP test was 15 min, 30%, and 120 min in total, 68%, Ccr; 83.8 ml/min.

Hormonal examinations revealed 17 OHCS in urine (normal, 2.00–4.00 mg/day) of 4.00 mg/day, and 4.20 mg/day, 17 KS in urine (normal: 4.00–8.00 mg/day), 8.70 mg/day and 13.00 mg/day showing mild elevation.

ACTH Rapid test revealed serum cortisol levels of 13.0 MCG/dl before, 20.5 MCG/dl at 30 minutes, and 23.1 MCG/dl at 60 minutes, showing almost normal levels, catecholamine and adrenalin in urine were (normal: 2–30 MCG/day) 12.40 MCG/day. Noradrenalin in urine (normal: 15–120 MCG/day) was 112.10 MCG/day. Thyroid function test showed normal results.

X-ray findings revealed normal chest X-ray findings. DIP was not performed due to iodine allergy. Retrograde pyelography revealed no abnormality in the left renal pelvis and calyces. Adrenal scintigraphy revealed no intake of RI.

On the grounds of the above-mentioned findings, a diagnosis of non-hormonal adrenocortical adenoma was made and enuclea-

tion of the left adrenal tumor was carried out under general anesthesia on December 21, 1983.

Operation findings: A left lumbar incision was made. The 11th and 12th ribs were resected, and then the muscular layer was cut, reaching the retroperitoneal lumen. Gerota's capsule was incised, then the left kidney and the adrenal tumor were exposed. The tumor had hardly any adhesions to its surrounding tissues and the tumor was removed as one block with the adrenal gland. The operation time was 1 hour and 43 minutes. The amount of bleeding was 186 g.

Enucleated specimen: The specimen was $5.0 \times 4.5 \times 3.0$ cm, weighted 30 g and was solid. The cut surface was yellowish and the tumor was clearly bounded by fibrous capsule. The original adrenal gland was atrophic and was adhering to the outside of the tumor in the shape of a cord.

Histological findings

Microscopic findings: There were no extracapsular or capsular invasions of the tumor, which was covered by a capsule of connective tissue. The tumor was composed primarily of large, plump cells with abundant acidophilic cytoplasm and eccentric nuclei. The nuclei had distinct nucleoli and showed no mitotic figures. These tumoral cells existed close to each other in the form of a nest combined with thin connective tissues. Infiltrations of lymphocytes and plasma cells, which displayed no atypism, were observed diffusely in the form of focal aggregation or scattered diffusely in the stroma. Those interstitial mononuclear cells were consistent with so-called myeloid metaplasia (Fig. 3). The tumor cells were negative for fat stain.

Electronmicroscopic findings: A number of well-developed mitochondria were observed in the cytoplasm of the tumor cells. A moderate amount of lysosomes and a small amount of intramitochondrial inclusions were also observed. (Fig. 4)

The above findings are consistent with oncocytoma. However, as there is no concept of oncocytoma in connection with adrenal adenoma, this case was diagnosed as adrenal cortical adenoma of the compact cell type.

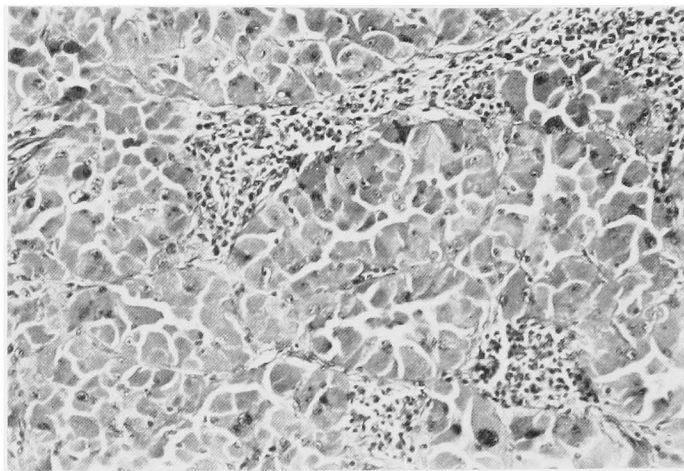


Fig. 3. Large and plump cells with abundant acidophilic cytoplasm. Infiltrations of mononuclear cells were also detected. $\times 190$, H&E

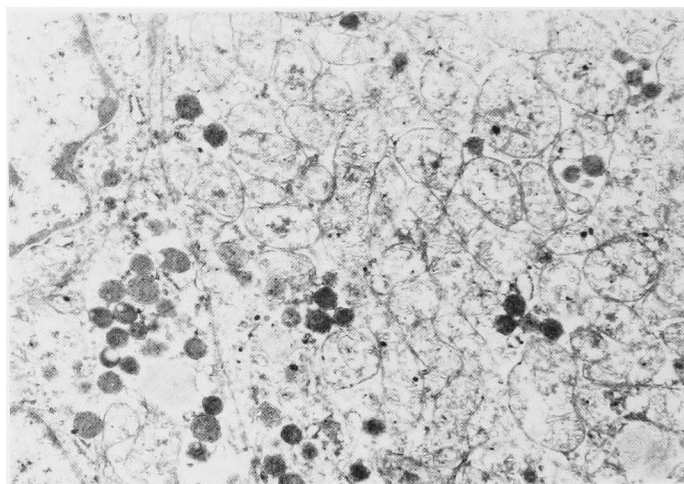


Fig. 4. Well-developed mitochondria in neoplastic cytoplasm. A moderate amount of lysosomes was observed. $\times 25,000$

DISCUSSION

The non-hormonal adrenocortical adenoma is extremely rare and we could find only 15 cases including our own case in the bibliographs available in Japan. The weights, age distributions, sexual ratio and histological findings of these 15 cases were investigated.

1) Weight: As shown in Table 1, the weight was more than 50.0 g in 9 out of 13 cases. The remaining 4 were 18.5 g, 7.2 g, 14 g and 30 g as in our own case. The

chief complaints of those with weights over 500 g were mostly abdominal tumor or abdominal attack without any hormonal symptom.

However, all of the 4 cases weighing less than 50 g were detected incidentally. Two of them were detected during operation (case 1 and 10), while the other two were detected during extensive examination of the abdomen. Case No. 11 reported by Yamashita et al.³⁾ was incidentally detected during abdominal CT scanning in the internal clinic, as in our present case. With the

Table 1. Non-hormonal adrenocortical adenoma: 15 cases in Japan

Reporters	Sex Age	Disease's side	Chief complaints	Therapy	Extirpated materials
1. Hayashi et al (1961)	M 60	Right	Anorexia Loss of body weight	Total extirpation	4 x 4.5 x 1.8 cm 18.5 g
2. Kurita et al (1964)	M 59	Right	Pain in epigastric region Pain in lateral abdominal region	Total extirpation	15 x 15 x 10 cm 600 g
3. Nakanishi et al (1967)	F 52	Right	Tumor in abdominal region	Total extirpation	22 x 12 x 14 cm 1,900 g
4. Nakankshi et al (1967)	M 24	Left	Tumor in abdominal region	Total extirpation	19 x 16 x 10 cm 1,970 g
5. Yamauchi et al (1968)	F 59	Left	Cough Sense of general fatigue	Total extirpation	Size of infant head 1,400 g
6. Ueda et al	M	Right	Tumor in right hypochondriac region	Partial collection of tissue	Size of human head
7. Yamamoto et al	F	Right	Tumor in right hypochondriac region	Total extirpation	10 x 12 x 12.5 cm 1,000 g
8. Yamazaki et al (1975)	M 57	Left	Tumor in left abdominal region	Total extirpation	13 x 10.5 x 8.5 cm 550 g
9. Furukawa et al (1977)	M	Left	Pain in left abdominal region	Total extirpation	14 x 22 x 8 cm 1,070 g
10. Akda et al (1978)	F 29	Left		Subtotal extirpation	1.5 x 1.4 x 1.2 cm 7.2 g
11. Yamashita et al (1981)	M	Right	Sense of general fatigue	Total extirpation	2.5 x 2.0 x 1.8 cm 14 g
12. Ohe et al	M	Right	Pains in right abdominal and back regions, and slight fever	Total extirpation (Right kidney was extirpated at the same time)	15 x 9 x 7 cm 660 g
13. Hamazaki et al	F	Right	Sense of discomfort on upper abdominal region. Tumor on right abdominal region	Total extirpation	17 x 15 x 8 cm 1,100 g
14. Ito et al	M	Left	Tumor in abdominal region	Subtotal extirpation Complication of huge cystoma	
15. My experimental case	F 41	Left	Sense of general fatigue	Total extirpation	5.0 x 4.5 x 3.0 cm 30 g

popularization of CT scanning and echoing, the rate of detection of non-hormonal adrenal tumor will increase in the future.

The small adenoma of the adrenal gland itself was, as earlier reported by Russi⁴⁾ and Commons⁵⁾ et al., observed in a frequency of 1–3% of the autopsy cases. These small adenomas were of no problem in clinical practice. The important point is whether the adrenal tumor is malignant or benign. It is regrettable, however, that the final conclusion should still resort to histological diagnosis even when angiography and CT scanning are fully utilized.

2) Age and sexual ratio: The patients were between 13 and 60 years old with a mean age of 45.6 ± 13.4 years. The affected side was the right side in 8 cases and the left side in 7 cases. The gender ratio was slightly in favor of males with 9 males and 6 females.

3) Histological patterns: It is believed to be difficult to distinguish whether an adrenocortical tumor is benign or malignant (Heinbecker et al.⁶⁾). In the present case, both the microscopic and electronmicroscopic investigations were carefully examined, and it was identified clearly as oncocytoma. However, as there is no concept of oncocytoma in cases of adrenocortical adenoma, this case was diagnosed as adrenocortical adenoma of the compact cell type.

The oncocytoma can be defined as a tumor composed of cells having acidophilic cytoplasm in light microscopy and a number of mitochondria by electron microscopy. There was no case having such histopathological findings among the 14 cases so far published.

Eight months after the operation, this patient is well and has no sign of recurrence

whatsoever. However, there have been reports of recurrence after benign postoperative diagnosis and this case should be followed-up carefully.

CONCLUSION

A 41-year-old female with non-hormonal adrenocortical adenoma was experienced. Fourteen cases have been found among the reports so far published in Japan. Our case was the 15th case.

Histologically, this tumor had an oncocytoma-like appearance. However, as there is no concept of oncocytoma in connection with adrenocortical adenoma, this case was diagnosed as adrenocortical adenoma. A case with such histological findings has never been reported in Japan.

REFERENCES

- 1) Hayashi I and Isobe Y: Non-hormonal adenoma of adrenal cortex: Report of a case. *Acta Urol Jpn* 7: 712~717, 1961
- 2) Aida M, Shima N and Inogari T: A case of Cushing disease with non-functioning adrenocortical adenoma. *Igakuno-Ayumi Japan* 105: 1010~1018, 1978
- 3) Yamashita S, Kitayama T, Minami Y, Kanetake H, Shindo K, Saito Y, Kuwatsuka M, Mori H and Tsuchiyama H: Non-functioning adrenal cortical adenoma: Report of a case. *Jap Clin Urol* 36: 477~480, 1982
- 4) Russi S and Blunenthal HT: Small adenomas of the adrenal cortex in hypertension and diabetes. *Arch Intern Med* 76: 284~291, 1945
- 5) Commons RR and Callaway CP: Adenomas of the adrenal cortex. *Arch Intern Med* 81: 37~41, 1948
- 6) Heinbecker P, O'Neal LW and Ackerman LV: Functioning and nonfunctioning adrenal cortical tumors, surgery. *Gynecology and obstetrics* 105: 21~33, 1957

(Accepted for publication, August 23, 1985)

和文抄録

Oncocytoma 様所見を呈した内分泌非活性型副腎皮質腺腫の1例

健康保険諫早総合病院泌尿器科（部長：垣本 滋）

垣 本 滋・湯 下 芳 明

実 藤 健・近 藤 厚

健康保険諫早総合病院内科（部長：倉恒宏正）

藤 島 直 幹

長崎大学医学部附属原爆後障害研究所病理学教室（主任：西森一正教授）

岸 川 正 大・松 本 浩 二

内分泌非活性副腎腫瘍は比較的稀な疾患であるが、今回われわれはその組織所見が oncocytoma 様所見を呈した内分泌非活性型副腎皮質腺腫を経験したので報告する。症例は41歳女性、軽度な甲状腺機能亢進症で本院内科で精査中であつたが腹部エコー、腹部 CT スキャンにて偶然、左副腎腫瘍を発見され、当科へ紹介された。内分泌検査、RI 検査などで、内分泌非

活性副腎腫瘍と診断し、1983年12月21日全身麻酔下に左副腎摘出術を施行した。摘出重量は $5 \times 4.5 \times 3.0$ cm, 30 g であつた。組織所見は光顕および電顕上、副腎の oncocytoma と考えられたが、副腎皮質腺腫には oncocytoma の概念がないので adrenal, cortical adenoma, compact cell type と診断した。