

## THE TITLE PAGE

### Article title

Autologous skin reconstruction by combining epidermis and acellular dermal matrix tissue derived from the skin of giant congenital melanocytic nevi

### Authors' names

Pham Hieu Liem M.D., M.Sc.<sup>1,2</sup>; Naoki Morimoto M.D., Ph.D.<sup>1</sup>; Ran Ito M.D.<sup>1</sup>; Katsuya Kawai M.D., Ph.D.<sup>1</sup>; Shigehiko Suzuki M.D., Ph.D.<sup>1</sup>

<sup>1</sup>*Department of Plastic and Reconstructive Surgery, Graduate School of Medicine, Kyoto University, Kyoto, Japan*

<sup>2</sup>*Department of Plastic and Aesthetic Surgery, Pham Ngoc Thach University of Medicine, Ho Chi Minh City, Vietnam*

### State the field of this research

Artificial Skin

### Address for manuscript correspondence

The first corresponding author:

- Pham Hieu Liem, M.D., M.Sc.
- Email: drliempham@pnt.edu.vn
- Telephone: (+81)90-5241-6199
- Fax: (+81)75-751-4340

The second corresponding author:

- Naoki Morimoto, M.D., Ph.D.
- Email: mnaoki22@kuhp.kyoto-u.ac.jp
- Telephone: (+81)90-4563-6041
- Fax: (+81)75-751-4340

### Keywords

giant congenital melanocytic nevi, acellular dermal matrix, skin reconstruction

## **ABSTRACT**

Giant congenital melanocytic nevi (GCMN) are defined as nevi of greater than 20cm in diameter. It is difficult to completely remove GCMN because of the lack of available skin grafts for covering the resultant defects. This study examined whether it is possible to produce reconstructed skin by combining epidermal and acellular dermal matrix (ADM) tissue derived from excised GCMN. GCMN skin samples were obtained with the informed consent of volunteer patients. The abilities of hypertonic saline (1N NaCl), 0.05% trypsin, 0.1% SDS (sodium dodecyl sulfate), and phosphate buffered saline (PBS) to decellularize GCMN tissue were compared. The specimens were incubated in one of the test solutions at 37°C for 48 hours, before being washed with PBS at 4°C for 14 days. Residual nuclei, residual DNA, nevus tissue viability, and the structural integrity of the basement membrane and capillaries were evaluated before treatment, and after 48 hours' treatment with or without 7 or 14 days' washing. We tried to produce reconstructed skin by combining the resultant ADM with enzymatically-separated GCMN epidermal tissue. The histological structure of the reconstructed skin was examined after it had been cultured for 5 days. In the SDS group, most cells had been removed after 48 hours, and the DNA content of the ADM was significantly lower than in the other groups. As for viability, no significant difference was detected among the groups. The basement membrane and capillaries remained intact in all groups. After 5 days' culturing, the epidermis had become attached to the ADM in all groups, except the SDS group. SDS displayed a superior decellularization ability compared with the other methods; however, it can not be used to produce reconstructed skin because of its toxicity. In conclusion, we produced reconstructed skin that was devoid of nevus cells by combining GCMN epidermal tissue with GCMN-derived ADM produced with NaCl or trypsin. This is a promising treatment strategy for giant nevus.

## **INTRODUCTION**

Giant congenital melanocytic nevus (GCMN) is a rare, disfiguring lesion and is associated with malignant melanoma and neurocutaneous melanosis [1]. Two definitions of GCMN have been proposed: CMN lesions that affect a significant portion of an anatomical area such as the face, head, or neck [1, 2] or CMN lesions measuring 20cm or more in greatest diameter [3]. Nevus cells are found in the dermis and subcutaneous tissue, as well as appendages such as sebaceous glands, hair follicles, sweat glands, blood vessel walls, and nerves [4]. The treatment of GCMN should take account of both the likely cosmetic outcome and the need to reduce the risk of malignancy.

It is necessary to surgically resect nevi and remove all nevus cells to decrease the risk of malignancy. However, it is difficult to completely remove GCMN because of the lack of available skin grafts for covering the resultant defects. To overcome this problem, we tried to prepare acellular dermal matrices (ADM) by removing the cellular components from nevus tissue. There are various methods for decellularizing dermal tissue such as freeze-drying it [5, 6] or treating it with surfactants [2, 7], hypertonic or hypotonic solutions, or enzymes [8-10]. Of these methods, treating the dermal tissue with surfactants such as sodium dodecyl sulfate solution (SDS) is reported to be most effective. It was reported that after decellularization dermal tissue exhibits stability, low antigenicity, and a native dermal structure [7, 11]. However, no clinical study has produced acellular skin from nevus tissue and then used it to prepare autologous skin containing no nevus cells.

The aim of this study is to explore whether it is possible to produce reconstructed skin that is devoid of nevus cells from a combination of epidermal and acellular dermis tissue derived from excised GCMN tissue and to elucidate the most suitable decellularization method for producing the abovementioned acellular dermis tissue.

## **MATERIALS AND METHODS**

### **Preparation of nevus skin**

Our protocol was approved by the ethical committee of Kyoto University Graduate School Faculty of Medicine. GCMN skin specimens were obtained from eight volunteer patients (three males and five females; mean age: 4.13-years-old, range: 3-6-years-old) who underwent surgery to remove their nevi at Kyoto University Hospital and provided written informed consent.

The GCMN tissue samples were preserved in normal saline solution (NSS; Otsuka Pharmaceutical Ltd., Tokyo, Japan). Subcutaneous adipose tissue and hair were removed with scissors, and then the full thickness melanocytic nevus tissue samples were punched using a biopsy punch to produce tissue samples of 8mm in diameter (Kai Industries Co., Ltd., Gifu, Japan).

### **Decellularization of melanocytic nevi**

The melanocytic nevus tissues were divided into four groups. Each group included forty pieces of tissue of 8mm in diameter and was treated with a different solution to decellularize it:

- Group A: Phosphate buffered saline solution (PBS; Gibco Ltd., New York, U.S.A.).
- Group B: Hypertonic saline solution (HSS; 1N NaCl; Wako Pure Chemical Industries Ltd., Osaka, Japan).
- Group C: 0.05% trypsin (Wako Pure Chemical Industries Ltd., Osaka, Japan).
- Group D: 0.1% sodium dodecyl sulfate solution (SDS; Wako Pure Chemical Industries Ltd., Osaka, Japan).

The tissue specimens were first incubated in the relevant solution at 37°C for 48 hours. Then, they were soaked in fresh PBS solution, before being washed and shaken using an orbital shaker at 40 revolutions per minute (Shake-XR, Taitec, Ltd., Tokyo, Japan) for 14 days at 4°C [12].

## **Assessment of the decellularized tissue**

We assessed the numbers of residual nuclei in the treated tissue samples using hematoxylin and eosin (H-E) staining and attempted to detect the basement membrane of the epidermis and capillaries using immunohistochemical staining for type IV collagen and von Willebrand factor (vWF), respectively. We also evaluated the viability of the nevus tissue and the amount of DNA it contained before and after treatment.

### *Histological examination*

The decellularized melanocytic nevus tissues were fixed with 10% neutral-buffered formalin solution and embedded in paraffin blocks, and then the central area of each ADM was sectioned into 5µm slices, which were then stained with H-E. We used an optical microscope (Biorevo BZ-9000, Keyence, Co., Osaka, Japan) at x400 magnification to inspect the sections for nevus cells, fibroblasts, and collagen fibers.

### *Immunohistochemical staining of the basement membrane and capillaries*

Five µm-thick paraffin sections were subjected to immunohistochemical staining of type IV collagen and vWF to detect the basement membrane and capillaries, respectively. After deparaffinization and rehydration, the antigen retrieval processing was performed using the heat-induced target retrieval method. The sections were immersed in a pre-heated staining dish containing a modified citrate buffer (pH 6.1; Dako Japan Co., Tokyo, Japan) and incubated for 30 minutes at 90°C. After being cooled to room temperature for 20 minutes, the sections were rinsed twice for 3 minutes in PBS and then immersed in 130ml methanol (CH<sub>3</sub>OH; Wako Pure Chemical Industries Ltd., Osaka, Japan) mixed with 4 ml hydrogen peroxide (H<sub>2</sub>O<sub>2</sub>; Wako Pure Chemical Industries Ltd., Osaka, Japan) for 10 minutes to block endogenous peroxidase activity. To block non-specific protein binding, protein blocking agent (PBA; Thermo Ltd., California, U.S.A.) was applied for 10 minutes at room temperature. Next, the sections were incubated with rabbit polyclonal anti-human vWF antibody (1:300; Dako Japan Co., Ltd., Tokyo, Japan) and rabbit

polyclonal collagen IV antibody (1:500; Abcam Co., Ltd., Boston, U.S.A.) as primary antibodies at room temperature for 30 minutes, before the peroxidase-labeled secondary antibody, rabbit anti-goat simple stain MAX PO (multi) (Histofine, Nichirei Biosciences Co., Ltd., Tokyo, Japan), was applied for 30 minutes at room temperature. The sections were then rinsed with PBS, exposed to DAB (3-3'-diaminobenzidine tetrahydrochloride; Dako Japan Co., Ltd., Japan) for 30 seconds at room temperature, and counterstained with hematoxylin. The basement membrane and capillaries were observed at a magnification of x200.

#### *Evaluation of the viability of the decellularized tissue*

The viability of the decellularized tissue was evaluated using a WST-8 (4-[3-(2-methoxy-4-nitrophenyl)-2-[4-nitrophenyl]-2H-5-tetrazolio]-1,3-benzene disulfonate sodium salt) assay (Cell Count Reagent SF, Nacalai Tesque, Co., Ltd., Kyoto, Japan). After 48 hours' treatment with or without 7 or 14 days' washing, eight specimens of 3mm in diameter were obtained from each group (the PBS, NaCl, trypsin, and SDS treatment groups) using biopsy punches (Kai Industries Co., Ltd., Gifu, Japan) and placed into the wells of a 96-well plate (Thermo Scientific, Nunc Co., Roskilde, Denmark). One hundred  $\mu$ l of Dulbecco's modified Eagles' medium (DMEM) were added to each well, and then the specimens were immersed in the DMEM and incubated for 15 minutes at 37<sup>0</sup>C. Ten  $\mu$ l of the test reagent were added, and then the specimens were incubated for 1 hour at 37<sup>0</sup>C. Next, the specimens were removed, and the absorbance of the wells was read using a microplate reader (model 680; Bio-Rad Laboratories, Inc., Hercules, CA) at a test wavelength of 450nm and a reference wavelength of 650nm [13]. In this experiment, DMEM without dermis and untreated nevus tissue were used as negative and positive controls, respectively. The viability of the untreated nevus tissue was evaluated immediately after it had been obtained from the patients.

#### *Quantification of residual DNA in the decellularized tissue*

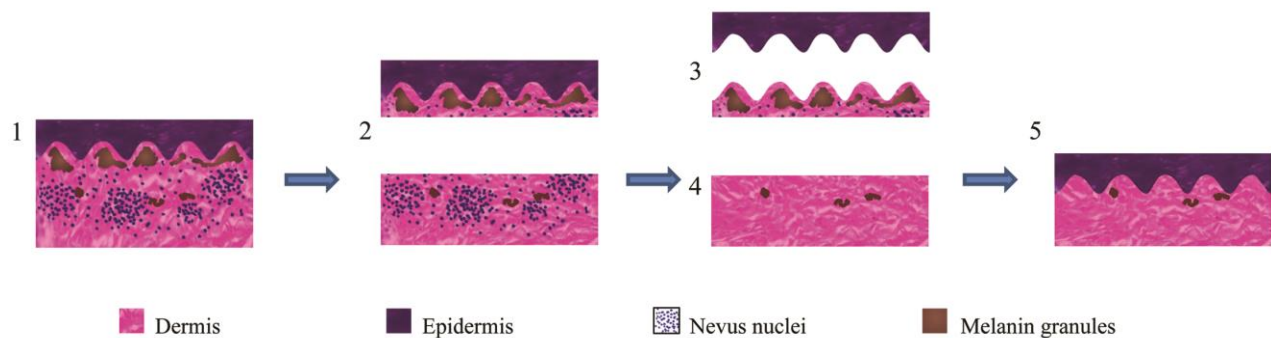
DNeasy blood and tissue kits (Qiagen Sciences, Co., Ltd., Texas, U.S.A.) were used to determine the amount of nuclear DNA in the melanocytic nevus tissues before they were treated with the test

solutions, after 48 hours' treatment in a CO<sub>2</sub>-incubator, and after the latter treatment plus 7 or 14 days' washing and shaking. According to the spin-column protocol of Qiagen Sciences [14], spectrophotometry ( $\lambda=280\text{nm}$ ) was used to quantify the residual amount of DNA (Nanodrop ND-1000, Scrum Inc., Japan).

### **Preparation of reconstituent skin from the ADM**

The method used to produce the reconstituent skin from autologous ADM and epidermal tissue is shown in figure 1. We first excised melanocytic nevus tissue from the buttocks of a 4-year-old female patient. Then, we separated a thin layer of split-thickness skin (280 $\mu\text{m}$ ) from the nevus tissue using a dermatome. The split-thickness skin and remaining dermis were immediately preserved in NSS. The split-thickness GCMN skin was immersed in dispase solution (Godo Shusei Co., Ltd., Tokyo, Japan), which contained 10,000 PU dispase dissolved in 10ml DMEM (Sigma-Aldrich Co., St. Louis, MO) and antibiotics (100 units/mL penicillin, 100 $\mu\text{g}/\text{mL}$  streptomycin, and 250ng/mL amphotericin B; Life Technologies Co., Carlsbad, CA), for 24 hours at 4°C. Then, we separated the epidermis from the papillary layer of the dermis with forceps and stored it in DMEM at 4°C until use. Subcutaneous adipose tissue and hair were removed from the aforementioned dermis using scissors, and then the tissue was punched into pieces of 8mm in diameter using a biopsy punch. The dermis specimens were decellularized for 48 hours using PBS, NaCl, trypsin, or SDS according to the abovementioned protocols, before being soaked in fresh PBS solution, washed, and shaken in an orbital shaker at 40 revolutions per minute for 3 hours at 4°C. Next, the decellularized dermis tissue was placed in 10cm culture dishes (Nunc Surface, Nunc Co., Roskilde, Denmark) so that the surface that had been in contact with the thin split-thickness skin was facing upward. Then, the epidermis was punched into pieces of 8mm in diameter using a biopsy punch, and the pieces were placed on top of the decellularized dermis specimens. We started an air-liquid interface culture in DMEM, 10% fetal bovine serum (FBS, Life Technologies Co., Carlsbad, CA), and antibiotics. The medium was replaced 3 days later. The specimens had their

histological structures examined after 5 days using H-E staining and an optical microscope (magnification: x200).



**Fig. 1** Schematic view of the enzymatic epidermal separation process and the preparation of reconstituent skin from GCMN

1. GCMN tissue was excised.
2. A thin layer of split-thickness skin was removed using a dermatome.
3. The epidermis was separated from the papillary layer of the dermis using an enzyme-based method, and the papillary layer was disposed of.
4. An ADM was produced by decellularizing the remaining dermis tissue.
5. The reconstituent skin was prepared by combining the ADM and epidermis.

### **Implantation of the reconstituent skin into mice**

All of the animal experiments performed in this study were approved by the Committee on the Ethics of Animal Experiments (Faculty of Medicine, Kyoto University, Kyoto, Japan) and were carried out in accordance with the Guidelines for Animal Experiments of the Faculty of Medicine, Kyoto University.

Seven-week-old male BALB/c nude mice (n=8, 2 mice in each group; Shimizu Laboratory Supply, Kyoto, Japan) were used in this study. The mice were anesthetized via the intraperitoneal injection of sodium pentobarbital (40mg/kg; Dainippon Sumitomo Pharmaceutical Co. Ltd, Osaka, Japan). In each mouse, reconstituent skin samples of 8mm in diameter containing decellularized nevus tissue produced using PBS, NaCl, trypsin, or SDS were implanted into the subcutaneous tissue on both sides of their back. Thus, a total of four reconstituent skin samples were grafted into the two mice in each group.

The reconstituent skins samples were examined at 14 days after their implantation. In each group, one sample was used for the histological examination, and 3 samples were used to evaluate viability.



Specimens of 3mm in diameter (n=6) were obtained from each group using biopsy punches, and their viability was evaluated using the WST-8 assay.

### **Statistical analysis**

The statistical significance of differences was assessed using one-way analysis of variance (ANOVA) and Fisher's protected least significant difference (Fisher's PLSD) test as a post-hoc test. All data are expressed as the mean  $\pm$  standard error (SE). Values of  $p < 0.05$  were accepted as statistically significant.

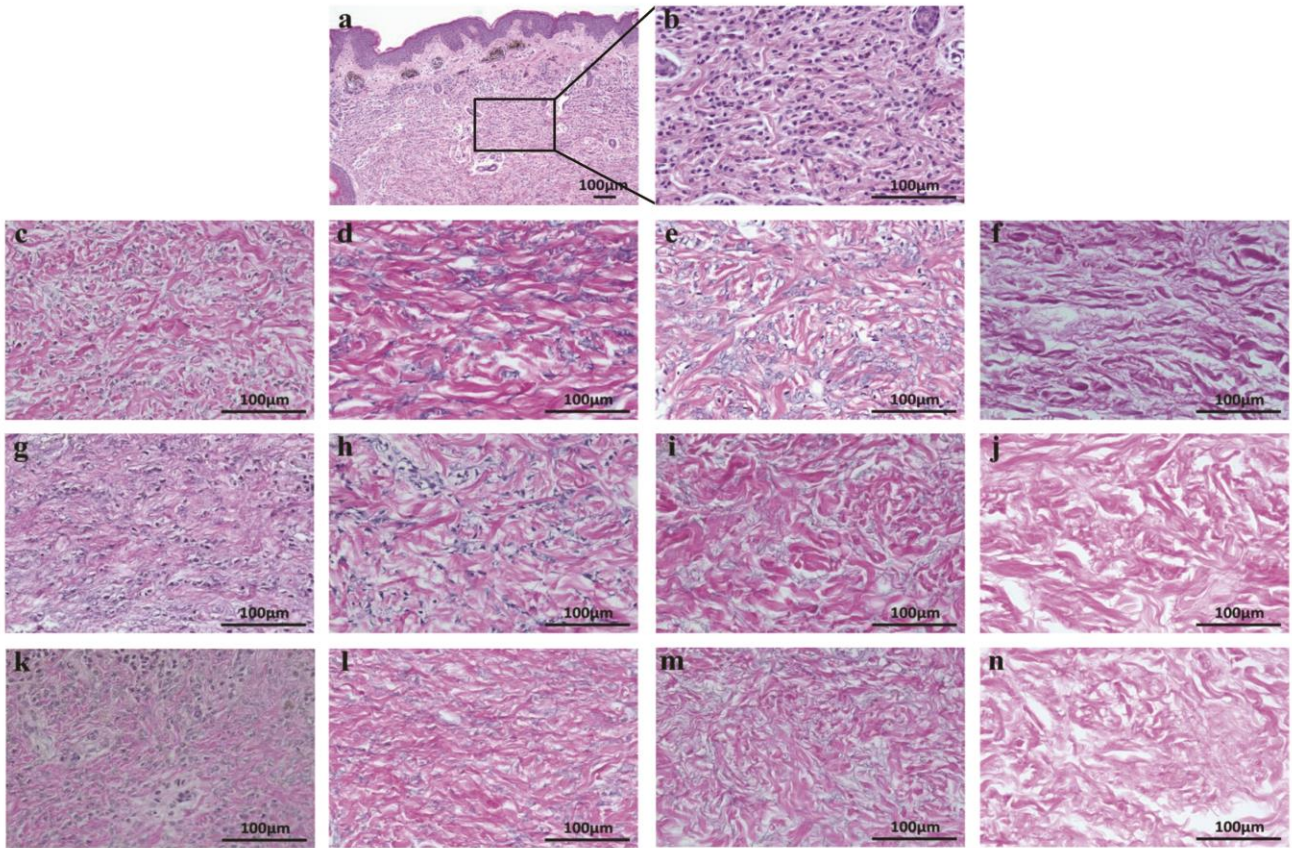
## **RESULTS**

### **Macroscopic evaluation of the ADM**

Forty-eight hours' treatment with NaCl, trypsin, or SDS resulted in the epidermis being completely removed from the nevus tissue samples. Conversely, in the PBS group it remained in place after 48 hours' treatment with or without 7 or 14 days' washing and shaking.

### **Histological evaluation of the ADM**

Representative examples of our H-E staining results are shown in figure 2. Figure 2. a and b show histological images of untreated GCMN tissue. The extracellular interstitium, nuclei, and melanin granules are visible: the pale pink color represents dense collagen fibers, the nuclei appear as dark blue granules, and the brown spots are melanin granules. The nuclear density of each tissue specimen was evaluated after 48 hours' treatment with or without 7 or 14 days' washing. The nuclear densities of the PBS (figure 2.c,g,k), NaCl (figure 2.d,h,l), and trypsin (figure 2.e,i,m) groups were lower than that of the untreated nevus tissue (figure 2.a,b). In addition, their nuclei were more swollen, opaque, and paler than those of the untreated nevus tissue. In contrast, no cells such as nevus cells, fibroblasts, or endothelial cells were seen after 48 hours' treatment in the SDS group (figure 2.f,j,n). Residual melanin granules were observed in all of the treated and untreated nevus tissue specimens. Collagen bundles were also present in all groups.

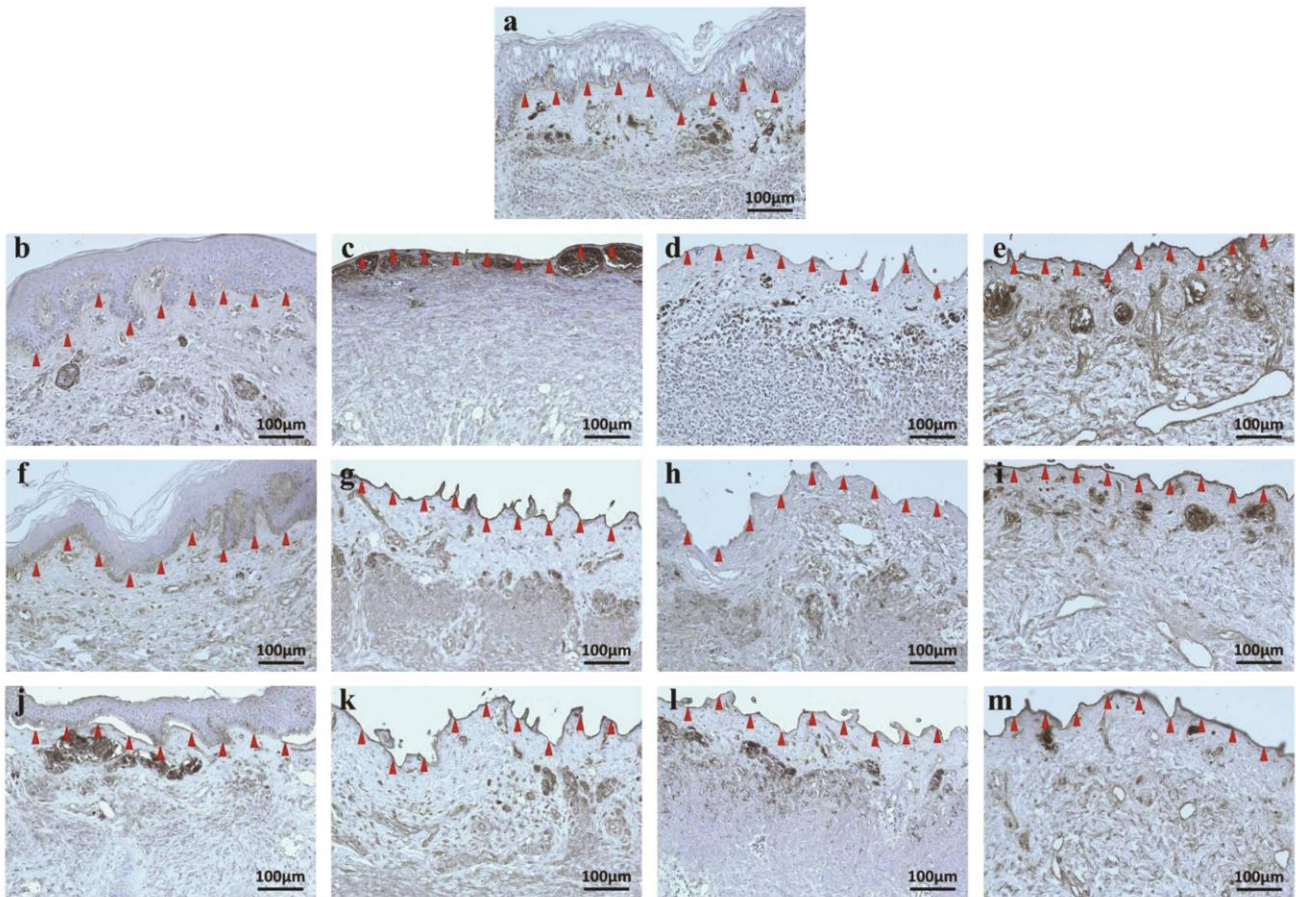


**Fig. 2** H-E staining of decellularized nevus tissues obtained by various methods

(a) Untreated nevus epidermis/dermis tissue at x100 magnification. (b) Untreated nevus tissue. Tissue subjected to (c) 48h PBS treatment, (d) 48h NaCl treatment, (e) 48h trypsin treatment, (f) 48h SDS treatment, (g) 48h PBS treatment and 7d washing, (h) 48h NaCl treatment and 7d washing, (i) 48h trypsin treatment and 7d washing, (j) 48h SDS treatment and 7d washing, (k) 48h PBS treatment and 14d washing, (l) 48h NaCl treatment and 14d washing, (m) 48h trypsin treatment and 14d washing, or (n) 48h SDS treatment and 14d washing. In the untreated nevus tissue specimens, the nuclei were very dense (a,b). The specimens treated with PBS (c,g,k), NaCl (d,h,l), or trypsin (e,i,m) displayed a lower nuclear density than the untreated nevus tissue specimens, and their nuclei were more swollen and opaque as well as paler than those of the untreated specimens. No nuclei were seen in the specimens treated with SDS (f,j,n). Scale bar=100µm at x400 magnification.

### **Observation of the basement membrane and capillaries**

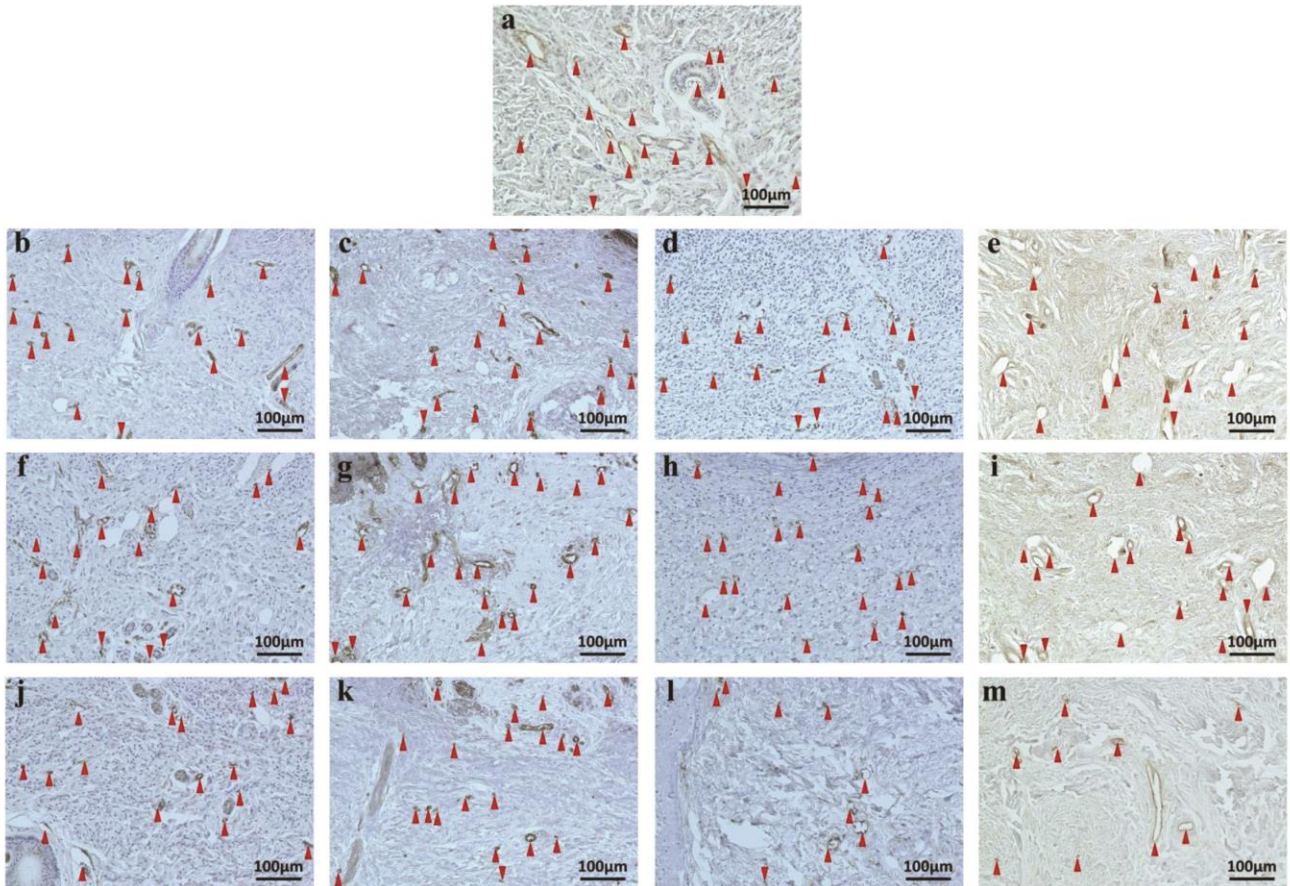
Figure 3 shows tissue sections that had been stained with type IV collagen antibody. In the untreated nevus tissue, type IV collagen, which was used as a marker of the basement membrane, was detected between the epidermis and dermis (figure 3.a). Although the epidermis was completely removed in the NaCl, trypsin, and SDS treatment groups, the basement membrane remained intact in all groups after 48 hours' treatment with or without 7 or 14 days' washing (figure 3.b-m).



**Fig. 3** Type IV collagen staining of decellularized nevus tissues obtained by various methods

(a) *Untreated nevus tissue. Tissue subjected to (b) 48h PBS treatment, (c) 48h NaCl treatment, (d) 48h trypsin treatment, (e) 48h SDS treatment, (f) 48h PBS treatment and 7d washing, (g) 48h NaCl treatment and 7d washing, (h) 48h trypsin treatment and 7d washing, (i) 48h SDS treatment and 7d washing, (j) 48h PBS treatment and 14d washing, (k) 48h NaCl treatment and 14d washing, (l) 48h trypsin treatment and 14d washing, or (m) 48h SDS treatment and 14d washing. Arrowheads indicate the basement membrane. In the untreated nevus tissue (a) and PBS (b,f,j) treated specimens, the basement membrane is shown as a brown line between the epidermis and dermis. Although the epidermis was completely removed in the NaCl (c,g,k), trypsin (d,h,l), and SDS (e,i,m) treated groups, the basement membrane remained intact in all specimens after 48 hours' treatment with or without 7 or 14 days' washing. Scale bar=100µm at x200 magnification.*

Images of capillaries that had been immunohistochemically stained used vWF antibody are shown in figure 4. In the untreated nevus tissue specimens, vWF staining was prominent in the capillaries (figure 4.a). Capillaries were also observed in all of the treated groups after 48 hours' treatment with or without 7 or 14 days' washing and shaking (figure 4.b-m).



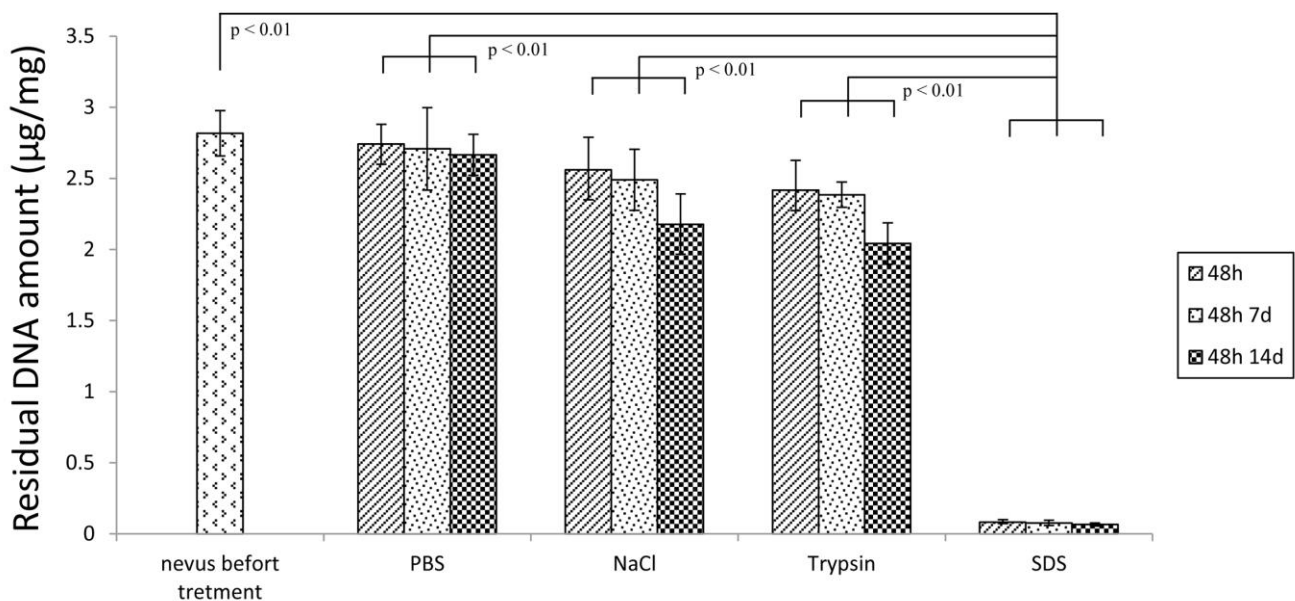
**Fig. 4** Immunohistochemical staining of capillaries in decellularized nevus tissues obtained by various methods using von Willebrand factor antibody

(a) Untreated nevus tissue. Tissue subjected to (b) 48h PBS treatment, (c) 48h NaCl treatment, (d) 48h trypsin treatment, (e) 48h SDS treatment, (f) 48h PBS treatment and 7d washing, (g) 48h NaCl treatment and 7d washing, (h) 48h trypsin treatment and 7d washing, (i) 48h SDS treatment and 7d washing, (j) 48h PBS treatment and 14d washing, (k) 48h NaCl treatment and 14d washing, (l) 48h trypsin treatment and 14d washing, or (m) 48h SDS treatment and 14d washing. Arrowheads indicate capillaries. Capillaries were observed in the untreated nevus tissue (a) as well as the PBS (b,f,g), NaCl (c,g,k), trypsin (d,h,l), and SDS (e,i,m) groups after 48 hours' treatment with or without 7 or 14 days' washing. Scale bar=100µm at x400 magnification.

### Quantification and comparison of residual DNA levels

To quantify the number of cells remaining inside the decellularized nevus tissue samples, we measured the amount of residual DNA that they contained (figure 5). There was no significant difference in the amount of residual DNA between the untreated nevus tissue and the tissue in the PBS, NaCl, or trypsin groups after 48 hours' treatment with or without 7 or 14 days' washing. The quantity of residual DNA was lowest in the SDS group at all three time points and was significantly

different from those of the other groups ( $p < 0.01$ ). However, there was no significant difference in the amount of residual DNA in the SDS group among the three time points.

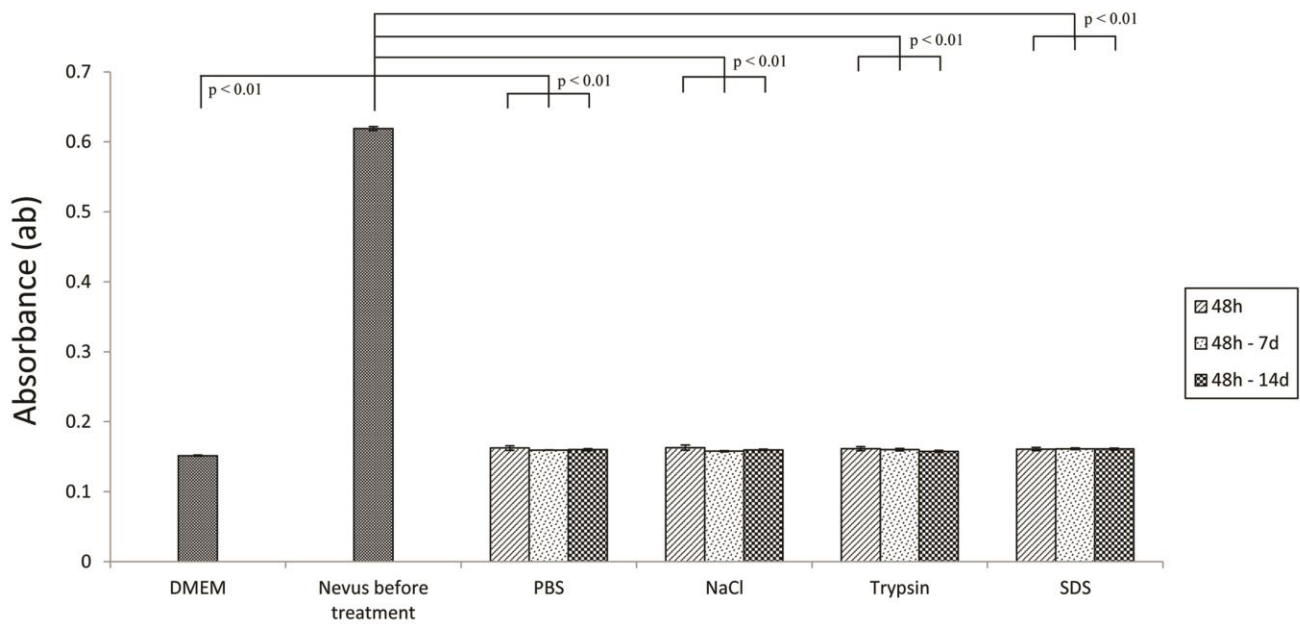


**Fig. 5** Quantification of the amount of residual DNA in the decellularized nevus tissue

*The amount of residual DNA is shown as the mean  $\pm$  SE. The SDS group displayed the lowest amount of residual DNA after each treatment ( $0.081 \pm 0.018 \mu\text{g}/\text{mg}$ ,  $0.076 \pm 0.017 \mu\text{g}/\text{mg}$ , and  $0.065 \pm 0.011 \mu\text{g}/\text{mg}$  after 48 hours' treatment, 48 hours' treatment and 7 days' washing, and 48 hours' treatment and 14 days' washing, respectively), and all of the values for the SDS group were significantly different compared with those for the untreated nevus tissue ( $2.817 \pm 0.16 \mu\text{g}/\text{mg}$ ) and the other treatment groups ( $p < 0.01$ ). There was no significant difference in the amount of residual DNA between the untreated group and the PBS, NaCl, or trypsin groups. There was no significant difference in the amount of residual DNA in the SDS group among the three time points.*

### **The viability of the decellularized nevus tissue**

A quantitative evaluation of the viability of the decellularized nevus tissue is shown in figure 6. The viability of the tissue (absorbance) was low in the PBS, NaCl, trypsin, and SDS groups after 48 hours' treatment with or without 7 or 14 days' washing, and these groups displayed significantly lower viability than the untreated nevus tissue specimens ( $p < 0.01$ ). No significant difference in viability was detected among the three time points in any of the treated groups.

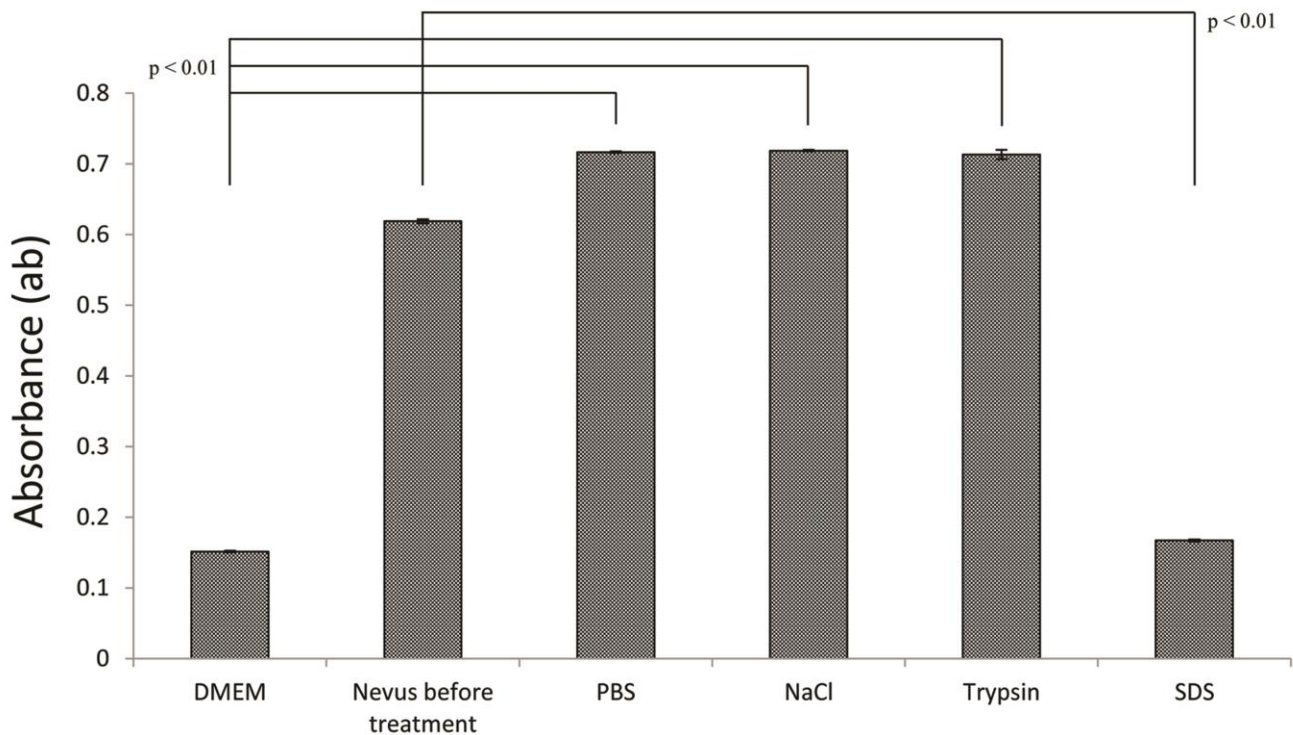


**Fig. 6** Quantification of the viability of decellularized nevus tissue

Absorbance is shown as the mean  $\pm$  SE. DMEM without dermis was used as a negative control (DMEM group). Tissue viability was significantly lower in the PBS, NaCl, trypsin, and SDS groups than in the untreated nevus tissue ( $0.619 \pm 0.003$ ,  $p < 0.01$ ). No significant difference in tissue viability was detected among the three time points in any of the treatment groups or the DMEM group ( $p > 0.05$ ).

### The viability of the reconstituent skin samples after 14 days' grafting

A quantitative evaluation of the viability of the reconstituent skin samples after 14 days' grafting is shown in figure 7. The reconstituent skin samples in the PBS, NaCl and trypsin groups displayed equivalent viability to the untreated nevus tissue. In contrast, the viability of the specimens in the SDS group was significantly lower than that of the untreated nevus tissue ( $p < 0.01$ ).

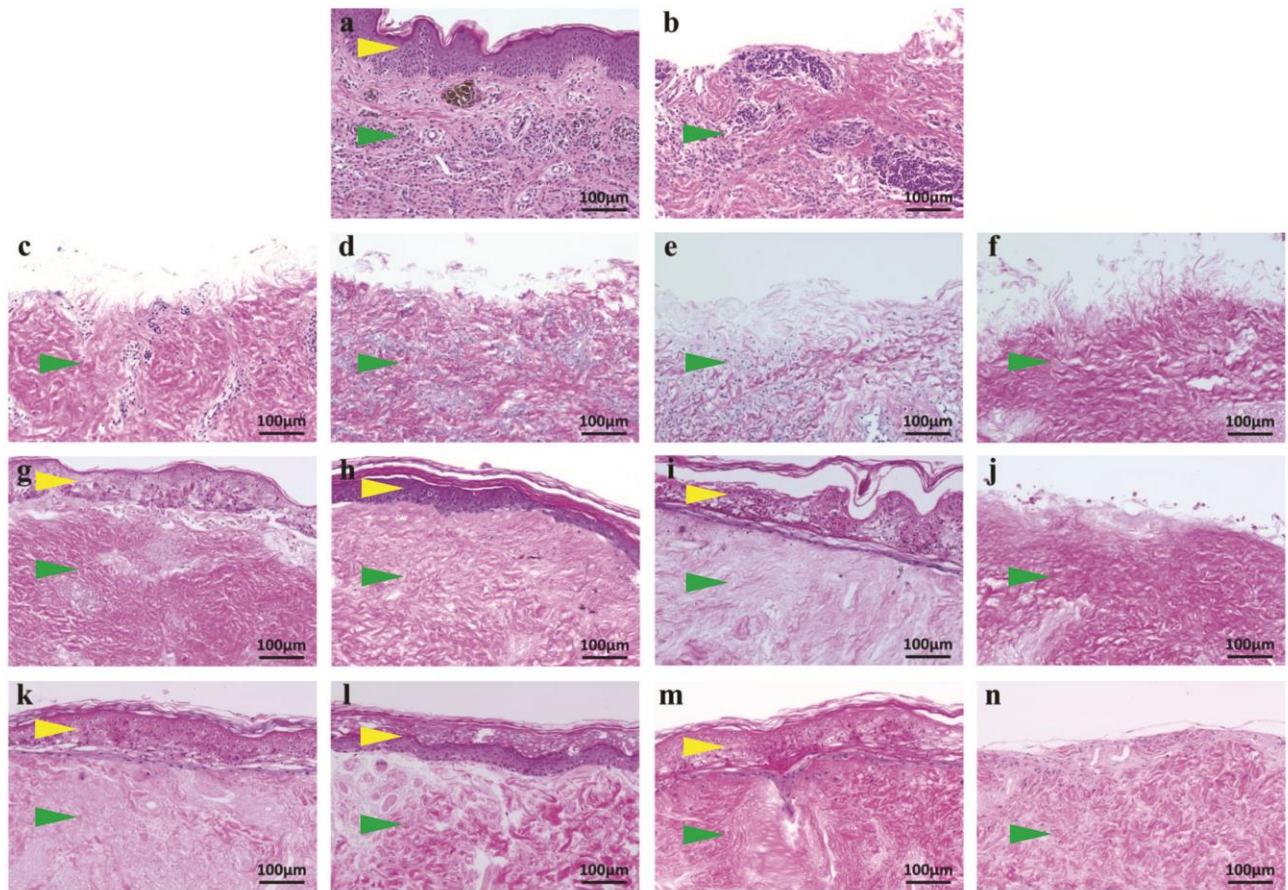


**Fig. 7** Quantification of the viability of the reconstituent skin produced using various decellularized nevus tissues

Absorbance is shown as the mean  $\pm$  SE. The viability of the reconstituent skin containing ADM produced with PBS ( $0.717 \pm 0.001$ ), NaCl ( $0.719 \pm 0.001$ ), or trypsin ( $0.713 \pm 0.007$ ) after being implanted into the subcutaneous tissue on the backs of mice and allowed to engraft for 14 days was as high as that of the untreated nevus tissue ( $0.619 \pm 0.003$ ,  $p > 0.05$ ). In contrast, the viability of the reconstituent skin produced with SDS was significantly lower than that of the untreated nevus tissue ( $p < 0.01$ ).

### **The structure of reconstituent skin composed of autologous ADM and epidermal tissue**

The results of the histological examinations of reconstituent skin specimens that had been cultivated in vitro or implanted into the backs of mice and allowed to engraft for 14 days are shown in figure 8. Figure 8.a and b show nevus tissue before and after the thin split-thickness skin had been removed. ADM that were produced via 48 hours' treatment with PBS, NaCl, trypsin, or SDS are shown in figure 8.c-f. After the reconstituent skin samples had been cultivated in vitro or allowed to engraft for 14 days, the epidermis had become attached to the ADM in the PBS (figure 8.g,k), NaCl (figure 8.h,l), and trypsin (figure 8.i,m) groups. However, the epidermis did not successfully attach to the ADM in the SDS group (figure 8.j,n).



**Fig. 8** H-E staining of the reconstituent skin samples produced using the decellularized nevus tissues and the findings obtained with our in vivo reconstituent skin models

(a) Untreated nevus tissue. (b) Nevus tissue after the thin layer of split-thickness skin had been removed. ADM produced via (c) 48h PBS treatment, (d) 48h NaCl treatment, (e) 48h trypsin treatment, or (f) 48h SDS treatment. (g) Reconstituent skin produced using the ADM from the PBS group, (h) NaCl group, (i) trypsin group, (j) or SDS group after 5 days' in vitro culturing. (k) In vivo reconstituent skin models in which reconstituent skin containing ADM produced with PBS, (l) NaCl, (m) trypsin, (n) or SDS was implanted into the subcutaneous tissue on the backs of mice and allowed to engraft for 14 days. The epidermis had successfully attached to the ADM in the PBS (g,k), NaCl (h,l), and trypsin (i,m) groups by day 5 in vitro and day 14 in vivo. In contrast, the epidermis was not able to attach to the ADM produced with SDS (j,n). Scale bar=100µm at x200 magnification. The yellow arrow indicates the epidermal layer, and the green arrow indicates the dermal layer.

## DISCUSSION

Treatments for GCMN can be categorized into non-excisional and excisional treatments [1, 15]. The former includes dermabrasion [16], laser ablation [17-21], curettage [22-24], chemical peeling, and cryotherapy with dry ice [25], but these methods cannot remove all nevus cells because nevus cells are also found in deeper dermal layers and subcutaneous tissue. Thus, the full-thickness excision of nevus tissue is the only method that can completely remove nevus cells. However, a



lack of donor skin remains a big issue in the treatment of giant nevi. Several recent reports have suggested that skin substitutes could be used for the treatment of skin defects. Artificial dermis products such as Integra<sup>®</sup> (Integra Life Sciences Corp., Plainsboro, New Jersey, U.S.A.) [26-29] and Pelnac<sup>®</sup> (Gunze Ltd., Ayabe, Kyoto, Japan) [2, 30] have been reported to be useful for regenerating dermal tissue in skin defects. However, these artificial dermises usually require two-step procedures, and patients have to wait several weeks for the dermis-like tissue to be prepared before the secondary skin grafting. The use of the acellular human dermis AlloDerm<sup>®</sup> (Life Cell Corp., The Woodlands, Texas, U.S.A.) for simultaneous grafting with a thin layer of autologous skin has also been reported [31, 32]. Treatment with such dermal substitutes is affected by the limitations of autologous skin, and the long-term quality of reconstructed skin produced in this manner is unclear. Kishi reported a grafting procedure involving epidermal tissue that had been separated from excised nevus tissue. In his method, split-thickness skin was taken from a GCMN using a dermatome and immersed in dispase for 75-105 minutes at 37°C. Then, the superficial part of the dermis, which contained relatively thick nevus cells, was removed, and the enzymatically-separated epidermis was grafted onto the remaining dermal tissue [33]. Although this technique has the advantage of using epidermal nevus tissue, nevus cells still remain in the residual dermis. In animal experiments, Mizuno decellularized nevus tissue with SDS and used the resultant ADM together with split-thickness skin from another site to cover nevus defects [2]. This method also uses nevus tissue for dermal reconstruction, but the lack of split-thickness skin remains a problem.

In this study, we manipulated nevus tissue in order to produce reconstructed skin that was devoid of nevus cells. The preparation of reconstructed skin composed of epidermal and autologous ADM tissue derived from nevus tissue could be a useful treatment for GCMN. We excised nevus tissue and then decellularized it with NaCl, trypsin, or SDS solution. SDS is an ionic detergent that simultaneously destroys and washes out cells, which makes it effective at removing nuclear remnants and cytoplasmic proteins from tissue [11, 34, 35]. Trypsin is a proteolytic enzyme used for cell removal. Trypsin can be used to remove cells because it degrades the extracellular matrix

(ECM) and cleaves peptide bonds, leading to the degradation of DNA [36, 37]. The ECM remaining after enzymatic decellularization is still able to support endothelial cell growth in vitro despite the removal of ECM components [38, 39]. Hypertonic NaCl solution has a greater molar concentration of NaCl than is found within cells. Thus, when cells are exposed to hypertonic NaCl, water is drawn out of the cells and into the surrounding solution. The diffusion of water molecules out of the cells results in cell shrinkage and osmotic shock-induced lysis, and there is no need to remove cellular remnants from the tissue [34, 37, 40-43]. In this study, we found that ADM could be produced by treating GCMN dermal tissue with any of these three solutions for 48 hours, while dermal structures such as the basement membrane of the dermal-epidermal junction and capillaries were maintained. The SDS group displayed the lowest amount of residual DNA after 48 hours' treatment, whereas the amounts of residual DNA in the other groups were not significantly different from that in the untreated nevus tissue. However, after 48 hours' treatment all of the treated groups displayed significantly lower viability than the untreated nevus tissue. In addition, we found that 48 hours' treatment with SDS resulted in the complete removal of all nuclei, but after 48 hours' treatment the viability of the tissue in the NaCl and trypsin groups was as low as that of the tissue in the SDS group. These results showed that all of the ADM in the treated groups displayed significantly lower viability than untreated nevus tissue, even though some nuclei remained in the ADM in the NaCl and trypsin groups. We therefore consider that these tissues had been inactivated, and hence, it was acceptable to refer to them as "acellular". In this study, the viability of GCMN tissue was even decreased by treatment with PBS, probably because we incubated the samples at 37°C.

In the next step, we prepared reconstructed skin by combining the autologous ADM with epidermal tissue from nevus samples. We were able to produce reconstructed skin using the ADM produced with PBS, NaCl, and trypsin. In contrast, the epidermis did not attach to the ADM produced with SDS. Previous reports have described the production of ADM from normal skin [11] or nevus tissue [2], but there are no reports about combining epidermal tissue separated from nevus tissue with decellularized nevus dermal tissue. In our method, the epidermis did not adhere to the ADM

produced with SDS. This might have been because the residual SDS was cytotoxic to epidermal cells or prevented them from attaching to the ADM [44-47]. Another possibility is that SDS disrupts the native tissue structure and decreases its glycosaminoglycan and collagen content [37]. After reconstituent skin samples had been implanted into mice and allowed to engraft for 14 days, we found that the reconstituent skin samples containing ADM produced with PBS, NaCl, or trypsin possessed normal epidermal layers and displayed equivalent viability to untreated nevus tissue. These results show that the epidermis had become attached to the ADM and was viable, and suggest that our method could be used to reconstruct skin defects.

Our study showed that the basement membrane and capillaries remained after decellularization with hypertonic NaCl, trypsin, or SDS. Although SDS achieved more complete cell removal than NaCl or trypsin, the epidermal tissue could not attach to the ADM produced with SDS. On the contrary, we found that epidermal tissue was able to rapidly attach to ADM tissue that had been processed with NaCl or trypsin, and hence, reconstituent skin can be produced using either of these reagents. Therefore, these two methods could be suitable for preparing autologous skin substitutes from nevus tissue.

Using our methods, it takes 48 hours from the resection of the GCMN to the implantation of the autologous ADM and epidermis to cover the defect. Thus, our method could solve the shortage of donor skin in GCMN patients.

In conclusion, we successfully manipulated nevus tissue to produce autologous skin substitutes that were devoid of nevus cells. Treating GCMN tissue with NaCl is an appropriate decellularization method for producing ADM. Our method is a promising treatment for GCMN patients, who lack normal skin to cover the skin defects produced by nevus removal.

## **ACKNOWLEDGMENTS**

This study was supported by a Grant-in-Aid for Scientific Research.

## REFERENCES

- [1] Arneja JS, Gosain AK. Giant congenital melanocytic nevi. *Plast Reconstr Surg*. 2009;124:1e-13e.
- [2] Mizuno H, Takeda A, Uchinuma E. Promising therapy for congenital giant pigmented nevi using acellular autograft nevi-dermal matrix. *Ann Plast Surg*. 1999;43:273-82.
- [3] Kopf AW, Bart RS, Hennessey P. Congenital nevocytic nevi and malignant melanomas. *J Am Acad Dermatol*. 1979;1:123-30.
- [4] Tannous ZS, Mihm MC Jr, Sober AJ, Duncan LM. Congenital melanocytic nevi: clinical and histopathologic features, risk of melanoma, and clinical management. *J Am Acad Dermatol*. 2005;52:197-203.
- [5] Wainwright DJ. Use of an acellular allograft dermal matrix (AlloDerm) in the management of full-thickness burns. *Burns*. 1995;21:243-8.
- [6] Livesey SA, Herndon DN, Hollyoak MA, Atkinson YH, Nag A. Transplanted acellular allograft dermal matrix. Potential as a template for the reconstruction of viable dermis. *Transplantation*. 1995;60:1-9.
- [7] Walter RJ, Matsuda T, Reyes HM, Walter JM, Hanumadass M. Characterization of acellular dermal matrices (ADMs) prepared by two different methods. *Burns*. 1998;24:104-13.
- [8] Takami Y, Matsuda T, Yoshitake M, Hanumadass M, Walter RJ. Dispase/detergent treated dermal matrix as a dermal substitute. *Burns*. 1996;22:182-90.
- [9] Takami Y, Matsuda T, Hanumadass M, Sakurai M, Water R. Acellular allogenic dermal matrix as a dermal substitute *Proc Int Conf Plastic Reconstruct Aesthet Surg*. 1995;55:212-5.
- [10] Walter RJ, Jennings LJ, Matsuda T, Reyes HM, Hanumadass M. Dispase/Triton treated acellular dermal matrix as a dermal substitute in rats. *Curr Surg*. 1997;54:371-4.
- [11] Chen RN, Ho HO, Tsai YT, Sheu MT. Process development of an acellular dermal matrix (ADM) for biomedical applications. *Biomaterials*. 2004;25: 2679-86.
- [12] Funamoto S, Nam K, Kimura T, Murakoshi A, Hashimoto Y, Niwaya K, et al. The use of high-hydrostatic pressure treatment to decellularize blood vessels. *Biomaterials*. 2010;31:3590-5.
- [13] Morimoto N, Takemoto S, Kanda N, Ayvazyan A, Taira MT, Suzuki S. The utilization of animal product-free media and autologous serum in an autologous dermal substitute culture. *J Surg Res*. 2011;171:339-46.
- [14] Qiagen. Protocol: Purification of total DNA from animal tissues (Spin-Column protocol). *DNeasy blood and tissue handbook*. 2006:28-30.
- [15] Kobayashi S, Kubo K, Matsui H, Torikai K, Kuroyanagi Y. Skin regeneration for giant pigmented nevus using autologous cultured dermal substitutes and epidermis separated from nevus skin. *Ann Plast Surg*. 2006;56:176-81.
- [16] Rompel R, Möser M, Petres J. Dermabrasion of congenital nevocellular nevi: experience in 215 patients. *Dermatology*. 1997;194:261-7.
- [17] Dave R, Mahaffey PJ. Combined early treatment of congenital melanocytic naevus with carbon dioxide and NdYag lasers. *Br J Plast Surg*. 2004;57:720-4.
- [18] Kono T, Ercocen AR, Kikuchi Y, Isago T, Honda T, Nozaki M. A giant melanocytic nevus treated with combined use of normal mode ruby laser and Q-switched alexandrite laser. *J Dermatol*. 2003;30:538-42.
- [19] Michel JL. Laser therapy of giant congenital melanocytic nevi. *Eur J Dermatol*. 2003;13:57-64.
- [20] Horner BM, El-Muttardi NS, Mayou BJ. Treatment of congenital melanocytic naevi with CO2 laser. *Ann Plast Surg*. 2005;55:276-80.
- [21] August PJ, Ferguson JE, Madan V. A study of the efficacy of carbon dioxide and pigment-specific lasers in the treatment of medium-sized congenital melanocytic naevi. *Br J Dermatol*. 2011;164:1037-42.

- [22] De Raeve LE, Roseeuw DI. Curettage of giant congenital melanocytic nevi in neonates: a decade later. *Arch Dermatol*. 2002;138:943-7.
- [23] Casanova D, Bardot J, Andrac-Meyer L, Magalon G. Early curettage of giant congenital naevi in children. *Br J Dermatol* Feb;(0):. 1998;138:341-5.
- [24] Michel JL, Laborde-Milaa Roux V, Chavrier Y, Roux V, Metafiot H, Chalencon F, et al. Neonatal curettage of giant congenital nevi. *Ann Dermatol Venereol*. 2000;127:23-8.
- [25] Hopkins JD, Smith AW, Jackson IT. Adjunctive treatment of congenital pigmented nevi with phenol chemical peel. *Plast Reconstr Surg*. 2000;105:1-11.
- [26] Abai B, Thayer D, Glat PM. The use of a dermal regeneration template (Integra) for acute resurfacing and reconstruction of defects created by excision of giant hairy nevi. *Plast Reconstr Surg*. 2004;114:162-8.
- [27] Earle SA, Marshall DM. Management of giant congenital nevi with artificial skin substitutes in children. *J Craniofac Surg*. 2005;16:904-7.
- [28] Dantzer E, Braye FM. Reconstructive surgery using an artificial dermis (Integra): results with 39 grafts. *Br J Plast Surg*. 2001;54:659-64.
- [29] Moiemmen N, Yarrow J, Hodgson E, Constantinides J, Chipp E, Oakley H, et al. Long-term clinical and histological analysis of Integra dermal regeneration template. *Plast Reconstr Surg*. 2011;127:1149-54.
- [30] Mastuda K, Suzuki S, Issiki N. Using two layers of artificial skin for giant pigmented nevi. *J Jap Soc Plast Reconstr Surg*. 1990;10:627-35.
- [31] Munster AM, Smith-Meek M, Shalom A. Acellular allograft dermal matrix: immediate or delayed epidermal coverage? *Burns*. 2001;27:150-3.
- [32] Eppley BL. Experimental assessment of the revascularization of acellular human dermis for soft-tissue augmentation. *Plast Reconstr Surg*. 2001;107:757-62.
- [33] Kishi K, Ninomiya R, Okabe K, Konno E, Katsube K, Imanishi N, et al. Treatment of giant congenital melanocytic nevi with enzymatically separated epidermal sheet grafting. *J Plast Reconstr Aesthet Surg*. 2010;63:914-20.
- [34] Woods T, Gratzer PF. Effectiveness of three extraction techniques in the development of a decellularized bone-anterior cruciate ligament-bone graft. *Biomaterials*. 2005;26:7339-49.
- [35] Rieder E, Kasimir MT, Silberhumer G, Seebacher G, Wolner E, Simon P, et al. Decellularization protocols of porcine heart valves differ importantly in efficiency of cell removal and susceptibility of the matrix to recellularization with human vascular cells. *J Thorac Cardiovasc Surg*. 2004;127:399-405.
- [36] Voet D, Voet JG, Pratt CW. *Fundamentals of biochemistry*. New York: Wiley. 2002.
- [37] Gilbert TW, Sellaro TL, Badylak SF. Decellularization of tissues and organs. *Biomaterials*. 2006;27:3675-83.
- [38] Grauss RW, Hazekamp MG, Oppenhuizen F, van Munsteren CJ, Gittenberger-de Groot AC, MC D. Histological evaluation of decellularised porcine aortic valves: matrix changes due to different decellularisation methods. *Eur J Cardiothorac Surg*. 2005;27:566-71.
- [39] Schenke-Layland K, Vasilevski O, Opitz F, König K, Riemann I, Halhuber KJ, et al. Impact of decellularization of xenogeneic tissue on extracellular matrix integrity for tissue engineering of heart valves. *J Struct Biol*. 2003;143:201-8.
- [40] Dahl SL, Koh J, Prabhakar V, Niklason LE. Decellularized native and engineered arterial scaffolds for transplantation. *Cell Transplant*. 2003;12:659-66.
- [41] Goissis G, Suzigan S, Parreira DR, Maniglia JV, Braile DM, Raymundo S. Preparation and characterization of collagen-elastin matrices from blood vessels intended as small diameter vascular grafts. *Artif Organs*. 2000;24:217-23.
- [42] Martins-Green M, Bissel MF. Cell-extracellular matrix interactions in development. *Semi Dev Biol*. 1995;6:149-59.
- [43] Vyavahare N, Hirsch D, Lerner E, Baskin JZ, Schoen FJ, Bianco R, et al. Prevention of Bioprosthetic Heart Valve Calcification by Ethanol Preincubation Efficacy and Mechanisms *Circulation*. 1997 95:479-88.

- [44] Gratzner PF, Harrison RD, Woods T. Matrix alteration and not residual sodium dodecyl sulfate cytotoxicity affects the cellular repopulation of a decellularized matrix. *Tissue Eng.* 2006;12:2975-83.
- [45] Rieder E, Kasimir MT, Silberhumer G, Seebacher G, Wolner E, Simon P, et al. Decellularization protocols of porcine heart valves differ importantly in efficiency of cell removal and susceptibility of the matrix to recellularization with human vascular cells. *J Thorac Cardiovasc Surg.* 2004;127:399-405.
- [46] Wilson GJ, Courtman DW, Klement P, Lee JM, Yeger H. Acellular matrix: biomaterial approach for coronary artery bypass and heart valve replacement *Ann Thorac Surg.* 1995;60:S353.
- [47] Cartmell JS, Dunn MG. Development of cell-seeded patellar tendon allografts for anterior cruciate ligament reconstruction. *Tissue Eng.* 2004;10:1065-75.