Aortic valve replacement in patients with protruding coronary artery stents

Short title: AVR in patients with protruding coronary stents

Masaki Nakamura, MD

Kenji Minakata, MD, PhD

Kazuhiro Yamazaki, MD, PhD

Takeichiro Nakane, MD

Shin-ichi Tsumaru, MD

Eiji Yoshikawa, MD, PhD

Hisashi Sakaguchi, MD, PhD

Akira Marui,MD, PhD

Ryuzo Sakata, MD, PhD

Department of Cardiovascular Surgery

Kyoto University Graduate School of Medicine, Kyoto, Japan

Corresponding author: Kenji Minakata, MD

Mailing address: 54 Kawaharacho, Shogoin, Sakyo-ku, Kyoto, Japan 606-8507

Tel: +81-75-751-3780

Fax: +81-75-751-3098

Email: minakata@kuhp.kyoto-u.ac.jp

Total word count: 1,933 Total number of Figures: 2

Key words: aortic valve replacement, percutaneous coronary intervention, stent protrusion, valve prosthesis

Abstract (179 words)

We present two cases of aortic valve replacement (AVR) in patients with protruding coronary artery stents from the coronary ostia. In the first case, an 87-year-old female was referred for AVR due to severe aortic stenosis (AS). During the operation, we found stents protruding from the left and the right coronary ostia into the aortic root. We performed AVR with a mechanical valve and coronary artery bypass grafting with the saphenous vein to the left anterior descending artery. In the second case, a 77-year-old female was referred for AVR due to severe AS with a history of healed infective endocarditis. During surgery on the second patient, we found a stent protruding 7 mm from the left coronary ostium into the aortic root. The edge of the stent was trimmed, and AVR with a mechanical valve was performed. In both patients, we decided to use a mechanical prosthesis instead of a bioprosthesis because of the risk of leaflet injury. Herein, we discuss some issues regarding patients with AS requiring AVR with prior history of coronary stenting in the coronary ostia.

Leaning objectives

To explore the problem of coronary stents protruding into the ostia in cases of percutaneous coronary intervention of left main or right proximal lesions, which can compromise subsequent aortic valve procedures including surgical aortic valve replacement or even trans-catheter aortic valve replacement thereafter.

Introduction

Recent advances and refinements in percutaneous coronary intervention (PCI) enable successful stent placements even in coronary ostial lesions in patients with left main and/or the right coronary artery diseases. Of those patients, some may develop significant aortic stenosis (AS), subsequently requiring surgical aortic valve replacement (AVR). Herein, we describe two cases of AVR with protruding coronary artery stents from the coronary ostia, and discuss some issues related to intraoperative myocardial protection and selection of valve prostheses.

Case report

Patient 1

An 87-year-old female presented with chest pain at the cardiology department in our hospital. Her past medical history included coronary artery disease with PCI in the proximal right coronary artery 5 years prior. Also, she had been diagnosed with moderate AS 2 years prior. Cardiac catheterization revealed significant stenosis of the ostium of the left main trunk (LMT) of her coronary artery. Thus, it was recommended that she undergo coronary artery bypass grafting (CABG) and AVR, but she refused. Therefore, she underwent PCI with a stent successfully placed in the ostium of the LMT (Figure 1a). One month later, she started to present congestive heart failure symptoms such as shortness of breath and pedal edema. Transthoracic echocardiography (TTE) showed significant progression of AS with a mean pressure gradient across the aortic valve

of 52mmHg and an aortic valve area of 0.53cm^2. Coronary angiography demonstrated significant stenosis in the proximal portion of the left anterior descending (LAD). Based on these findings, she was referred for AVR and CABG.

Through a median sternotomy, cardiopulmonary bypass was established by ascending aortic and single right atrial cannulation. After the ascending aorta was cross-clamped, the initial cardioplegia was delivered in antegrade fashion through the aortic root cannula in addition to retrograde delivery through a coronary sinus catheter. After a transverse aortotomy was performed, we identified stents protruding from both the left and the right coronary ostia into the aortic root (Figure 1b). We were not able to use a selective coronary perfusion catheter because of the stents. Next, we performed a distal anastomosis of a saphenous vein graft (SVG) to the LAD. Additional myocardial protection was conducted with direct perfusion through the SVG and retrograde perfusion. We excised the calcified aortic valve cusps and completely debrided the annular calcification. The sizer of a 19-mm bioprosthesis was very tight because of the heavy calcification of the narrow aortic root. Also, we thought that implanting a bioprosthesis in the supra-annular position carried the risk of leaflet injury interfering with both stents protruding from the coronary ostia. Therefore, we chose a 17-mm St. Jude Medical Regent mechanical prosthesis (St. Jude Medical, Minneapolis, USA). The valve was sutured using 1-0 braided polyester sutures. We confirmed adequate opening of the mechanical prosthetic valve leaflets with no interference from the stents, and left both stents

untouched. Her postoperative course was somewhat complicated, requiring prolonged intensive care with tracheostomy for respiratory failure. Her coronary CT angiography demonstrated a patent SVG to the LAD and no significant stenosis of both coronary stents. She was subsequently discharged on day 62 post-surgery.

Patient 2

A 77-year-old female presented with fever at the internal medicine department of our hospital. Her past medical history included significant coronary artery disease with prior multiple PCI with stents to the LMT and all three coronary arteries 2 years prior (Figure 2a). Her blood culture revealed *Streptococccus mitis*. TTE revealed a 9-mm non-mobile mass on the non-coronary cusp of the aortic valve. The aortic valve was heavily calcified. The mean gradient across the valve was measured at 39 mmHg and the aortic valve area was 0.74 cm^2. Transesophageal echocardiography confirmed vegetation on the non-coronary cusp, which was highly luminescent and 9 x 7 mm in size. She was diagnosed with active infective endocarditis associated with significant AS. After a 4-week course of antimicrobial therapy, she consulted with us for AVR.

After standard cardiopulmonary bypass was established, the ascending aorta was cross-clamped and antegrade cardioplegia was delivered through the aortic root cannula. We found a stent protruding approximately 7 mm from the left coronary ostium into the aortic root (Figure 2b). We

trimmed the edge of the stent in order to proceed with AVR. This was carried out using heavy scissors, and care was taken not to compromise the opening of the stent. During the procedure, we used intermittent retrograde coronary perfusion because we were not able to place a selective antegrade coronary cannula on the left coronary artery. Even after the excision of the aortic cusps and meticulous debridement of the aortic annulus, the sizer of a 19-mm bioprosthetic valve was very tight because of the heavily calcified aortic root and narrow aortic annulus. Also, we thought that the edge of the stent might injure the leaflet of the bioprosthesis. Therefore, we chose a 17-mm mechanical valve, and sutured it in the supra-annular position. Adequate opening of the prosthetic valve was confirmed with no interference from the stent. Her postoperative course was uneventful. After an additional 4-week course of antimicrobial therapy, she was discharged on the day 37 post-surgery.

Discussion

PCI has been the first line treatment in many patients with coronary artery disease for many years. Recently, some interventional cardiologists have become very aggressive in treating those patients who have LMT stenosis or ostial right coronary lesions. During PCI, coronary ostia are often found to be covered by stents, because it is recommended to fully extend the stents beyond the edge of the lesion, resulting in stents protruding from coronary ostia. In fact, Kang et.al reported that stents protruded into the aortic root in more than half of the cases of stenting of an ostial lesion, and the

length of the protrusion was 3.4±1.7mm in the LMT ostium and 2.4±1.4 mm in the right coronary ostium[1]. Therefore, we should keep in mind that stents protrude into the aortic root in the majority of patients who undergo PCI with stents in the coronary ostia. On the other hand, some of these patients may develop severe AS thereafter, and subsequently require surgical AVR. During the surgery, one may try to remove the protruding stents in case they compromise the procedure. Although successful removal of stents from the coronary ostia has been reported previously[2], pulling the stent out of the coronary artery is likely to cause damage to the intima, and result in significant stenosis or even occlusion of the coronary artery. Therefore, we should keep stents intact whenever possible. However, in the second case reported here, the stent protruded so far that it made it impossible to manipulate the diseased aortic valve, thus we needed to cut the protruding part. Care needs to be taken not to bend the rest of the stent when trimming.

Myocardial protection is another issue of interest during surgery. Unless there is significant aortic insufficiency, antegrade cardioplegia through an aortic root cannula is always the best method to start with. However, after an aortotomy is performed, it is impossible to give selective antegrade cardioplegia through the stents protruding into the coronary ostia. Therefore, alternative ways of delivering subsequent cardioplegia become necessary in these patients. Retrograde cardioplegia through a coronary sinus catheter is a valuable option, indeed many surgeons routinely use retrograde cardioplegia in aortic valve operations subsequently to initial antegrade delivery through

the aortic root cannula[3]. Also, even in patients with significant aortic insufficiency, one can still give adequate antegrade cardioplegia through the aortic root cannula to gain diastolic cardiac arrest by manipulating the left ventricle to prevent over distension as needed.

According to the American College of Cardiology/American Heart Association treatment guidelines for valvular patients, bioprostheses are recommended for AVR patients aged 65 years or older without a risk factor for thromboembolism[4]. In one case report, a patient with a protruding stent underwent AVR with a biopresthesis[5]. If the protruding part of the stent is completely trimmed without compromising the opening of the coronary ostia, one can use a bioprosthetic valve in this circumstance. However, we chose mechanical valves in both cases here because of the possibility of injury to the bioprosthetic valve leaflets by protruding stents. Even if a bioprosthesis is anatomically implanted and there seems no interference between the leaflets and the protruding stents in an arrested heart, a risk of injury to the leaflets remains because the bioprosthetic valves expand significantly during systole under arterial pressure and may hit the edge of the stents. Although there are several types of bioprosthetic valves available, one must keep in mind of potential risk of leaflet injury.

Transcatheter aortic valve replacement (TAVR) has emerged as an important treatment of choice for patients with severe symptomatic AS who are inoperable or at high operative risk [6]. Evaluating preoperative co-morbidities in these two cases, TAVR may have been proposed as an alternative to surgical AVR especially in case 1. However, TAVR may have been unsuccessful because of the risks of damage to the protruding stents during ballooning of the aortic valve or delivering the prosthesis, causing myocardial ischemia, or incomplete expansion of the prosthesis with leaflet injury causing malfunction of the prosthesis. The present cases are definitely useful for raising awareness of stents in the coronary ostia when evaluating candidates for TAVR.

Conclusion

We present two cases of AVR in patients with stents protruding from the coronary ostia into the aortic root. These two cases highlight the importance of the correct choice of prostheses, intraoperative myocardial protection, and suitability of TAVR in such patients.

References

1. Kang SJ, Ahn JM, Kim WJ, Lee JY, Park DW, Lee SW, Kim YH, Lee CW, Mintz GS, Park SW, Park SJ. Intravascular ultrasound assessment of drug-eluting stent coverage of the

coronary ostium and effect on outcomes. Am J Cardiol. 2013;111:1401-7

2. Zwoliński R, Ostrowski S, Banyś A, Ammer A, Jaszewski R. Surgical removal of stent from multiply stented vessel: problem with choice of place for anastomosis - one year follow-up. Kardiol Pol. 2013;71:615-7.

3. Yamamoto H, Yamamoto F. Myocardial protection in cardiac surgery: a historical review from the beginning to the current topics. Gen Thorac Cardiovasc Surg. 2013; 61: 485-496

4. American College of Cardiology/American Heart Association Task Force on Practice Guidelines; Society of Cardiovascular Anesthesiologists; Society for Cardiovascular Angiography and Interventions; Society of Thoracic Surgeons; Bonow RO, Carabello BA, Kanu C, de Leon AC Jr, Faxon DP, Freed MD, Gaasch WH, Lytle BW, Nishimura RA, O'Gara PT, O'Rourke RA, et al. ACC/AHA 2006 guidelines for the management of patients with valvular heart disease: a report of the American College of Cardiology/American Heart Association Task Force on Practice Guidelines (writing committee to revise the 1998 Guidelines for the Management of Patients With Valvular Heart Disease): developed in collaboration with the Society of Cardiovascular Anesthesiologists: endorsed by the Society for Cardiovascular Angiography and Interventions and the Society of Thoracic Surgeons. Circulation 2006; 114: e84-231.

5. Nwaejike N, Rozario C, Sogliani F. Management of a protruding right coronary artery stent during aortic valve replacement for aortic stenosis. Innovations 2012;7:213-6.

6. Smith CR, Leon MB, Mack MJ, Miller DC, Moses JW, Svensson LG, et al. Transcatheter versus surgical aortic-valve replacement in high-risk patients. N Engl J Med 2011; 364: 2187-98.

Disclosure

We received no financial support and none of the authors had any conflicts on interest in regard to this report.

Figure legends

Figure 1a (left): Coronary angiography showed a stent implanted in the LMT. 1b (right): In the first case, an intraoperative photograph shows the stents protruding from the left and the coronary ostia.

Figure 2a (left): Coronary angiography shows a stent placed in the LMT. 2b (right): In the second case, an intraoperative photograph shows the stent protruding from the left coronary ostium.

Figure 1.

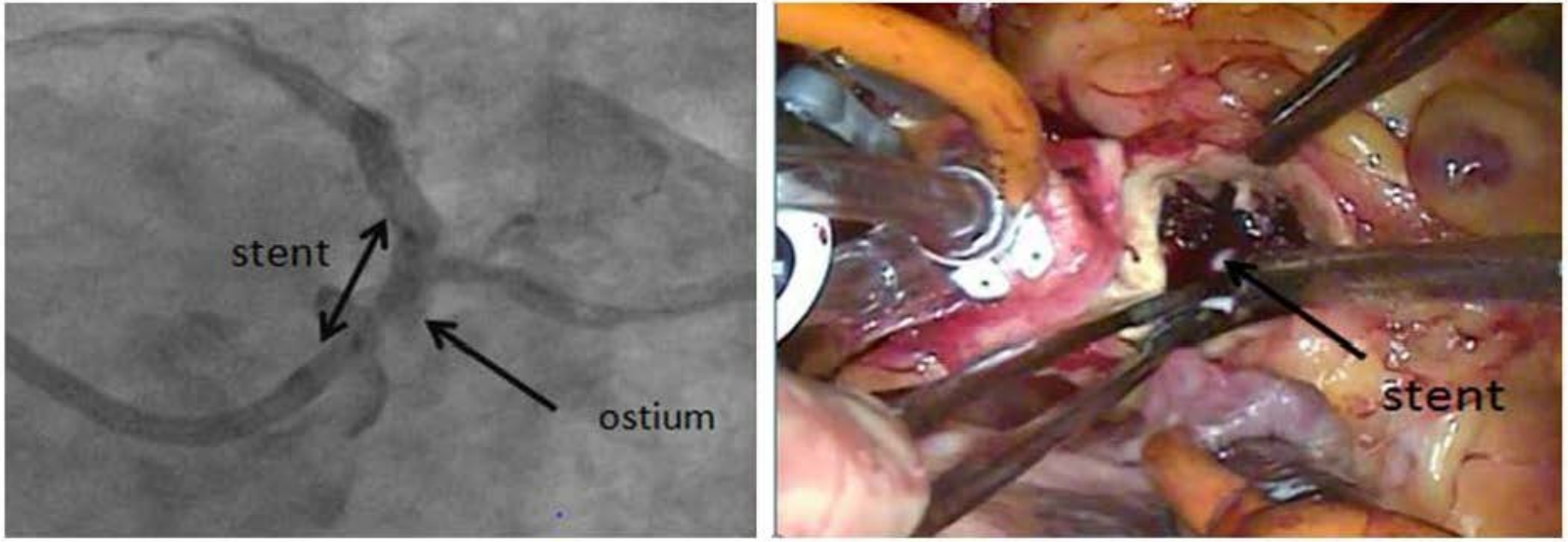

Figure 2.