Arch Jpn Chir 57(2), 143～151, März, 1988

原　　著

Anatomical Characteristics of the Entrapment Point of the Ulnar Nerve at the Elbow

YASUSUKE HIRASAWA* and TAKAO TOKIOKA**

*Department of Orthopaedic Surgery, Kyoto Prefectural University of Medicine, Kyoto, Japan
(Associate Professor)
**Department of Anatomy, Osaka Dental College, Osaka, Japan
(Associate Professor)
Received for Publication,

Abstract

The ulnar arcade at the elbow where ulnar nerve passes through is characterized by several morphological features of entrapment point. The authors proposed the term "cubital arcade", the wider definition of the entrapment point of the ulnar nerve at the elbow rather than "cubital tunnel". The authors investigated the following anatomical characteristics of the cubital arcade using adult cadavers. (1) In the area of sulcus nervi ulnaris, amount of fibrofatty tissue is poor in the nerve trunk, and the nerve is superficially located and runs closely on the hard bony tissue. (2) At the distal margin of bony sulcus of ulnar nerve, the nerve runs on the basis of hard collateral ligament, where it is covered with a hard ligamentous aponeurosis. (3) The nutrient vessel to epineurium of the nerve does not exist in the tunnel under the cover of aponeurosis and the nerve is fed by vessels at the entrance of the tunnel and by the recurrent vessels ascending from the mulculature at the distal end of the tunnel. The blood vessels inside the nerve trunk in the cubital arcade show tortuosity to be adapted to traction force to the nerve by joint motion. (4) Under the cover of aponeurosis at the elbow, the interposition of connective tissue layer between muscle and the nerve provides independent mobility (longitudinal sliding) of the nerve.

Thus the nerve and the blood vessel possess these anatomical characteristics as the entrapment point at the joint, and the surgeons must always pay attention to these anatomical features during any surgical procedure at the elbow.

Introduction

Entrapment neuropathy of the ulnar nerve at the elbow is believed to be caused repeated microtrauma to the nerve due to friction, compression or traction[10]. There are several surgical

Key words: Entrapment point, Cubital arcade, Neural mobility.
索引語：神経絞扼点，肘部管，絞扼神経障害.
Present address: Department of Orthopedic Surgery Kyoto Prefectural University of Medicine, Kamigyo-ku, Kyoto 602, Japan.

procedures to release the entrapment of the nerve, such as medial epicondylectomy[5,6], anterior transposition of the ulnar nerve[7,8], and resection of aponeurosis[9]. The results of these operation vary significantly from one author to another, probably due to differences of techniques employed by these surgeons in addition to duration and mechanism of the nerve entrapment[1].

FEINDEL and STRATFORD[3] defined the entrapment point at the elbow, where ulnar nerve is surrounded anteriorly the medial epicondyle of the humerus, laterally by the ulnohumeral ligaments and posteromedially by the aponeurosis between two heads of flexor carpi ulnaris muscle, as the "cubital tunnel". However, the definition is too narrow, because entrapment of ulnar nerve may be caused even at the proximal portion from the tunnel, such as portion of bony sulcus without any coverage of aponeuros is of the flexor carpi ulnaris[2,11,12].

The authors tried to define the entrapment point as "cubital arcade", that is, a more extensive area covering from the distal edge of medial intermuscular septum of arm where nerve passes posteriorly to medial epicondlyle of humerus, to all way down to its passage through muscles under the cover of aponeurosis bridging two heads of flexor carpi ulnaris in this paper.

Method

Ten upper limbs from adult cadavars were used. Acrylic resin was injected into the brachial artejy to accurately distinguish nerves from blood vessels. The specimens were divided into 2 groups for either (1) exploration of ulnar nerve and its supplying arteries, or (2) preparation and staining of thin cross-sectional slices of 2 cm intervals. For the former, observation was done under a stereoscopic microscope, Type SM, made by Nikon, Tokyo, Japan.

Results

In the proximal half of arm the ulnar nerve runs medially to the brachial artery, brachial vein and median nerve but at the middle of arm it penetrates the proximal part of the medial intermuscular septum to its posterior aspect at the distal edge of the insertion of coracobrachial muscle. Posteriorly to the septum, the ulnar nerve descends distally inside the posterior fascia between the septum and medial heads of humeral triceps muscle along with superior ulnar collateral artery and vein (Figure 1). It reaches the posterior side of medial epicondyle of humerus, where the posterior fascial compartment is located closer to the body surface and an angle is formed in the transition from the septum to brachial fascia. The nerve in this area is covered with fatty tissue outside its epineurium, and over the fat layer with a thin layer of connective tissue. The blood vessels are also covered with fatty tissue and with a thin sheath composed of connective tissue. They attach loosely to the myofascial tissue. In other words, the nerve area is clearly separated from vascular area and nerves and blood vessels can move proximo-distally within a certain range independently from the surrounding tissues. The ulnar nerve is supplied by branches of superior ulnar collateral artery and vein at 2 or 3 levels, and the branch anastomoses with neighboring branches inside the epineurium to form vasa nervorum. Tortuosity of vasa nervorum along the nerve indicate that the nerve trunk has some

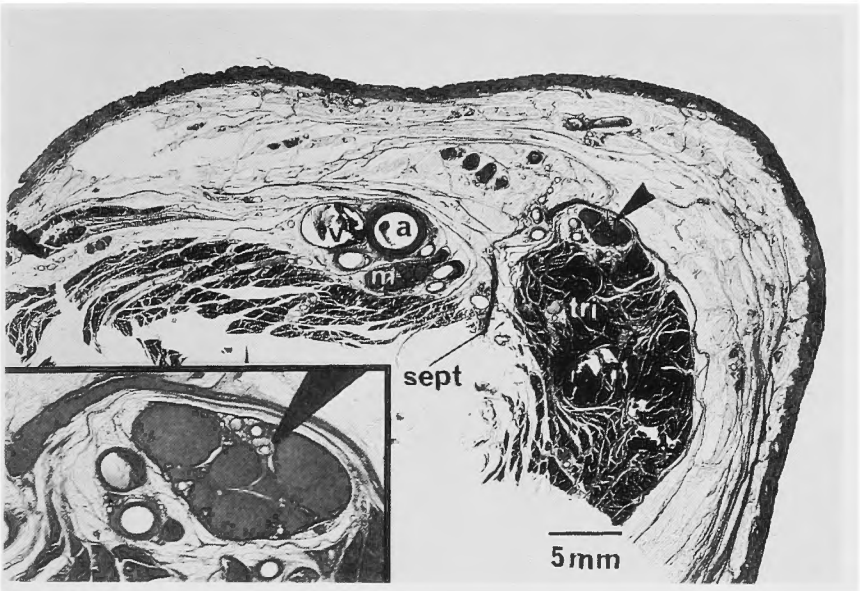

Fig. 1. Cross section at the middle of the arm. Arrow indicates ulnar nerve. (M: median nerve, Sept: intermuscular septum, a: brachial artery, v: brachial vein, tri: triceps muscle)

elasticity to adapt the joint motion (Figure 2).

At the level of elbow joint, the ulnar nerve passes posteriorly to the medial epicondyle of humerus. It passes through the cubital arcade formed with fascia of connective tissue. The cubital arcade can be divided into the proximal portion and distal portion by the type of anterior

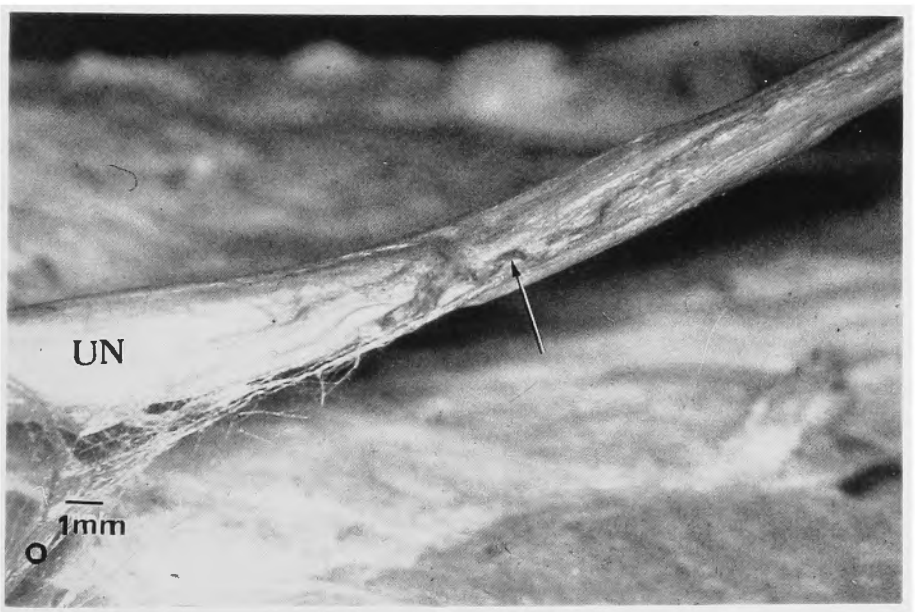

Fig. 2. Ulnar nerve (UN) with vasa nervorum at the proximal site of sulcus nervi ulnaris. Arrow indicates vasa nervorum. (o: origin of vasa nervorum)

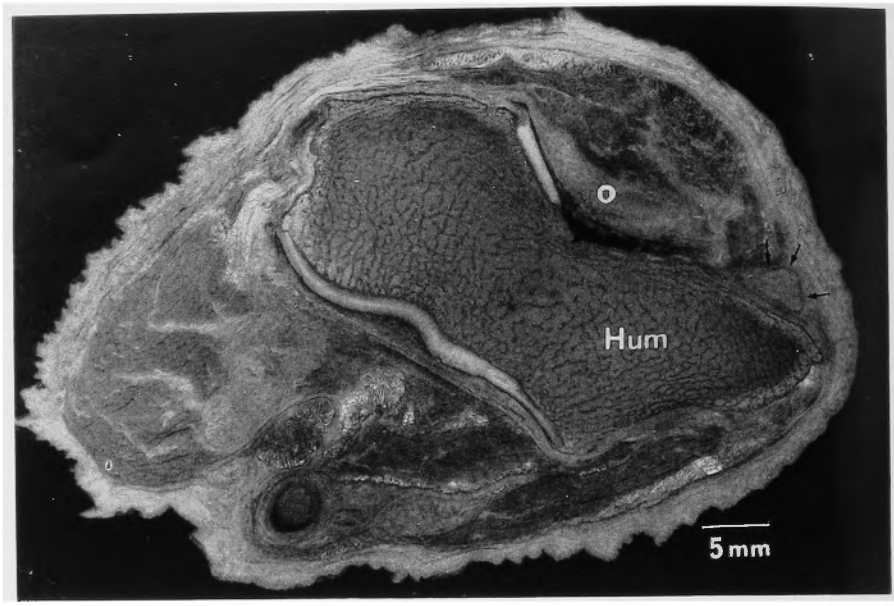

Fig. 3. Ulnar nerve at the sulcus nervi ulnaris. Cross section at olecranon fossa. Arrows indicate ulnar nerve. (Hum: humerus, o: tip of olecranon)

hard basis to which they are attached. The basis of the proximal portion is sulcus nervi ulnaris, and the one of distal portion is ulnar collateral ligament.

In the proximal portion of cubital arcade, the ulnar nerve descends through sulcus nervi ulnaris on the posterior aspect of medial epicondyle of humerus (Figure 3 & 4), and the ulnar nerve is normally enveloped by the fascia bridging olecranon to medial epicondyle. However, in rare instances, it is covered with M. epithrochleo-anconeus[4]. During its passage through this arcade defined by the fascia and sulcus, the outside of epineurium is covered with loose connective tissue layer, where scarcely contains any fat tissue, and the outside of this layer is connective tissue sheath, loosely attached to the periosteum of sulcus or superficial fascia, ensuring mobility of the ulnar nerve independent from the arcade wall (Figure 5). In this area, the superior ulnar collateral vessels are surrounded by a sheath of connective tissue solely containing vessels supplying the ulnar nerve, and pass through inferior-medial part of the arcade to anastomose with posterior branches of ulnar recurrent artery (Figure 4)

In the distal portion of arcade, the ulnar nerve traverses posteriorly to medial collateral ligament. This part of arcade is referred to as "tunnel" by FEINDEL, et al[3]. In this area, the ulnar nerve is covered with relatively thick aponeurosis bridging two heads of flexor carpi ulnaris, which is inserted into ulnar collateral ligament, and its proximal end is in contact with the inferior margin of sulcus nervi ulnaris. This part is covered with poorly elastic aponeurosis. Therefore, in this area, any morphological abnormality of arcade may give rise to friction between the ulnar nerve and surrounding connective tissue sheath by repeated articular movement since, as mentioned earlier in this paper, the nerve is proximo-distally mobile. However, the ulnar nerve

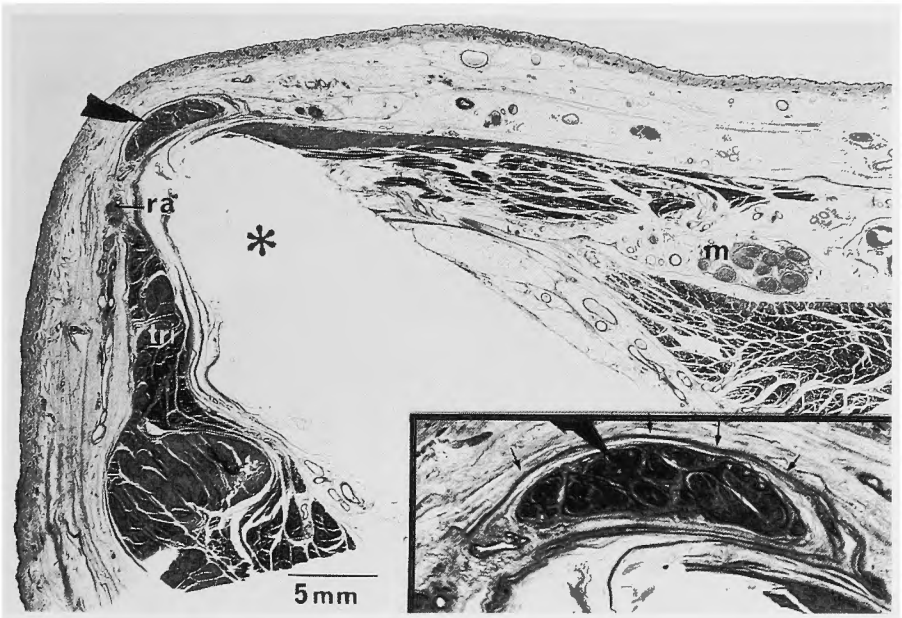

Fig. 4. Cross section at the level of medial epicondyle. Thick arrow indicates ulnar nerve, thin arrows for connective tissue sheath. (tri: triceps muscle, m: median nerve, ra: ulnar recurrent artery, *: medial epicondyle removed)

passage thjough this area is very short, and the nerve passes between brachial head and ulnar head of flexor carpi ulnaris and immediately reaches the anterior side of forearm. In this area, there is again an increased amount of fat tissue of the outer surface of epineurium (Figure 6).

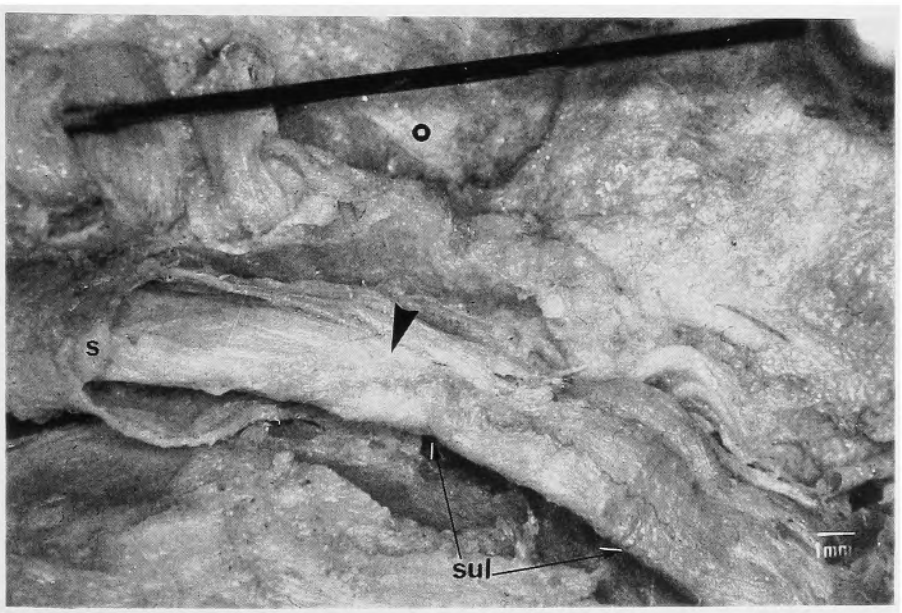

Fig. 5. Ulnar nerve at the cubital arcade. The thick arrow indicates ulnar nerve. (o: olecranon, sul: sulcus nervi ulnaris, s: sheath of the connective tissue around the ulnar nerve)



Fig. 6. Ulnar nerve (UN) just distal of the orifice of aponeurotic arch. Arrows indicate sheath of connective tissue layer. (apo: aponeurosis, lig: collateral ligament)

Furthermore, the ulnar nerve descends distally through the intermuscular space between flexor carpi ulnaris and deep flexor muscle of fingers. In this area, loose connective tissue layer covers the epineurium, and outside this layer is the thin sheath of connective tissue (Figure 7).

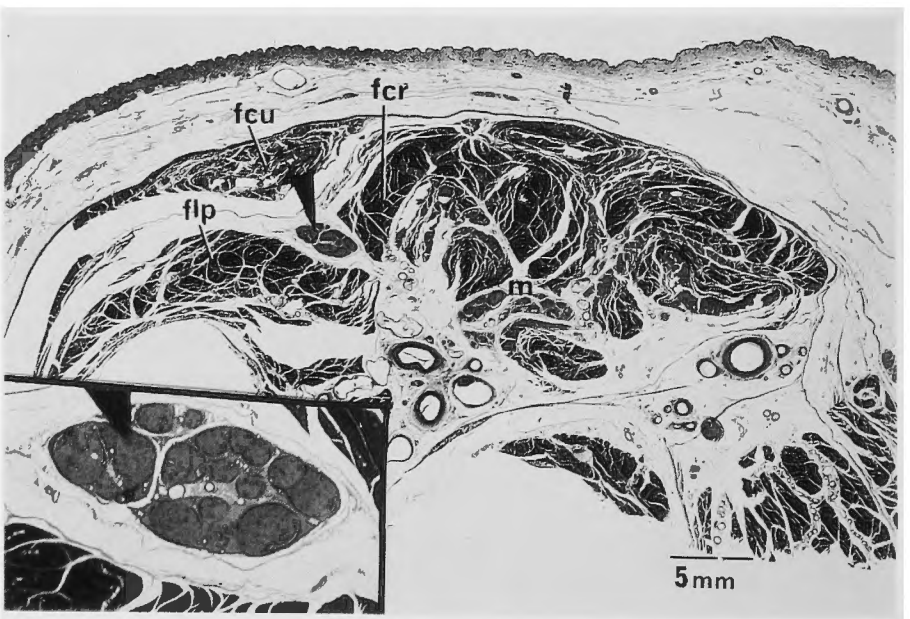

Fig. 7. Ulnar nerve (arrow) among flexor carpi ulnaris and flexor digiti profundus in the proximal forearm. (fcu: flexor carpi ulnaris, fp: flexor digiti profundus)

The articular branches of ulnar nerve are very thin, and it branches out one or two at the proximal margin of sulcus nervi ulnaris, one inside the sulcus, and one under the cover of aponeurosis.

Discussion

The entrapment neuropathy of ulnar nerve at the elbow could result from damage in the area covering the inferior margin of intermuscular septum, in the area behind the medial epicondyle and also in the area referred to as "cubital tunnel" by Feindel et al[3]. The authors proposed the term "cubital arcade", the wider definition of the entrapment point of ulnar nerve, rather than "cubital tunnel". According to the authors' investigation, following characteristic features of cubital arcade were obtained: (1) In area of sulcus nervi ulnaris, amount of fibrofatty tissue providing cushion for the nerve is poor, and the nerve runs superficially closer to the skin. Furthermore, the nerve is located close to hard bony tissue, which predisposes the nerve to microtraumas due to repeated exposure to external forces. (2) In the distal part of sulcus nervi ulnaris, ulnar nerve runs closely on hard collateral ligament, where the nerve is covered with hard ligamentous aponeurosis bridging flexor carpi ulnaris. The amount of fibrofatty tissue in and around the nerve is also poor in this area, and therefore very little room to compensate any morphological abnormality predispofes the nerve to friction neuropathy after long-term use of the elbow. (3) In the tunnel, there is no concomitant, nutrient vessels of the nerve, and the nerve is supplied by vessels at the entrance of the tunnel or by a recurrent vessels ascending from the muscular tissue through the distal end of the tunnel. The blood vessels inside the neural trunk show tortuosity to provide independent mobility of the nerve. (4) The interposition of the sheath of connective tissue between the muscular structure and the nerve in the arcade enable the independent movement (longitudinal sliding) of the nerve. Any morphological abnormality which might occur in this arcade may cause friction between the connective tissue sheath and the nerve, leading to the development of friction neuropathy and the resultant epineurium hypertrophy may progress to the secondary nerve entrapment.

The clinical picture of nerve entrapment suggests the following mechanisms. (1) The severe cubitus valgus resulting from supracondylar fracture of humerus or other reasons will cause friction neuropathy due to traction force pulling the nerve toward the sulcus of the nerve. (2) In osteoarthritic process, the chronic exposure to impingement established between bony bulge of osteophytes and aponeurosis cover causes neuropathy. (3) In rare occasion, hypertrophy of aponeurosis or abnormally developed muscle over the aponeurosis causes neuropathy mainly due to compression[4]. (4) Chronic exposure to mechanical irritation with joint etiology due to intra-articular loose bodies, ganglion or collateral ligament may cause neuropathy[13].

The surgical treatment should be based on the elimination of direct causes of entrapment, and prevention of any residual abnormality can cause entrapment, flexion or compression of the nerve. Furthermore, epineurotomy for the secondary hypertrophy of epineurium under microscopic guidance should be done to relieve the entrapment of funiculus. In order to prevent the adhesion of the nerve to the surrounding tissues, it is important to avoid any injury to the

myofascia and other structures where the nerve passes. If any pre-existing scar is found in this area, it is necessary to cover the nerve with the surrounding subcutaneous fat to prevent the adhesion of the nerve. Furthermore, vascular damage should be minimized, so as to preserve the advantages of characteristic vascular supply in the joint area.

References

1) Broudy AS, Leffert RD, Smith RJ: Technical problems with ulnar nerve transposition at the elbow. Findings and results of reoperation. J Hand Surgery. **3**, 1: 85–89, 1978.
2) Craven PR Jr, Green DP: Cubital tunnel syndrome. J Bone and Joint Surg, 62-A, **6**: 986–989, 1980.
3) Feindel W, Stradford J: Cubital tunnel compression in tardy ulnar palsy. Canada Med Assn J **78**: 351–353, 1958.
4) Hirasawa Y, Sawamura H, Sakakida K: Entrapment neuropathy due to bilateral epitrochleoanconeus muscles. A case report., J Hand Surgery **4**: 181–184, 1979.
5) Hirasawa Y, Katsumi Y, Kojima O: Cubital tunnel syndrome due to osteoarthritis of the elbow. A surgical approach. Peripheral Nerve Repair and Regeneration **2**: 53–62, 1986.
6) King T, Morgan FP: Late results removing the medial humeral epicondyle for traumatic ulnar neuritis. J Bone and Joint Surg **41**-B, **1**: 51–55, 1959.
7) Leffert RD: Anterior submuscular transposition of the ulnar nerves by the Leamonth technique. J Hand Surgery **7**, **2**: 147–155, 1982.
8) McGowan AJ: The results of transposition of the ulnar nerve for traumatic ulnar neuritis. J Bone and Joint Surg **32**-B, **3**: 293–301, 1950.
9) Osborne G: Compression neuritis of the ulnar nerve at the elbow. The Hand **2**: 10–13, 1970.
10) Seddon, Sir H: Surgical disorders of the peripheral nerves. (Churchill Livingstone, Edinburgh), pp. 303–314, 1975.
11) Spinner M: Injuries to the major branches of peripheral nerves of the forearm. (WB Saunders Co.), 1972.
12) Sunderland SS: Nerve and Nerve Injuries. Churchill Livingstone, 1978.
13) Vanderpool DW, Chalmers J, Whiston TB: Peripheral compression lesions of the ulnar nerve. J Bone and Joint Surg. **50**-B, **4**: 792–803, 1968.

和文抄録

肘関節部における尺骨神経の entrapment point の形態的特徴について

京都府立医科大学整形外科学教室
平　澤　泰　介

大阪歯科大学解剖学教室
時　岡　孝　夫

Feindel らは肘関節部における尺骨神経の絞扼(とう)点を前方は上腕骨内側上顆，外側は尺側上腕靱帯，後内側は尺側手根屈筋の二頭間の腱膜で作られる tunnel とし，これを cubital tunnel と名づけた．しかし臨床的には尺骨神経は内側筋間中隔の末梢で上腕骨内側上顆の後方を通る部分より，尺側手根屈筋二頭間にわたる aponeurosis の下に入り込んだ筋肉内を走るまでの広い範囲で絞扼されることが多い．ゆえに筆者らはこの部分を cubital arcade と考え総称し，尺骨神経の entrapment point であると考えた．本論文においては成人屍体を用いて，cubital arcade の形態的特徴について検索し，以下の結果を得た．(1)尺骨神経溝付近では，その中枢側にみられるような cushion の働らきをすると考えられる fibrofatty tissue が少く，神経は皮膚に近く，浅い部位にある．さらにその基底部は硬い骨組織でできており，外からくり返しの微小外傷を受けやすい状態にある．(2)さらに神経溝の末梢へいくと，その基底部は硬い側副靱帯となり，その上は靱帯性の aponeurosis によっておおわれている．また神経周囲の fibrofatty tissue は少なく，形態的にも余裕がなく，わずかな形態異常によって神経に摩擦が生じやすい．(3)いわゆる tunnel 内には，epineurium への供給血管はなく，血行は tunnel 入口部と末梢側の筋組織より反回して登る血管より供給されている．(4) arcade を走る神経と同囲の筋組織の間では鞘状の結合組織が形成され，独立した神経の可動性が得られるようになっている．このような arcade に何らかの原因で形態異常が生じると，鞘状の結合組織と神経の間に抵抗が生じ，さらに二次的な entrapment へと進行すると考えられる．

このように cubital arcade における神経と血管は，entrapment point における形態的特徴とともに，関節の運動に適応するための解剖学的な特徴を有している．肘部管症候群に対しては上記のような形態的かつ機能的特徴を考慮に入れて治療する必要があろう．