

Benign Bile Duct Stricture Associated with Intraductal Mucous Substance: Report of A Non-Jaundiced Case

YOH KASAHARA, SHOZO UEDA, AKIHIKO MORISHITA, NARUMI SONOBE, KIICHI NAKAO,
MASAHIKO TAKEMOTO, YUKIKAZU YAMADA and TAKESHI KUYAMA

The Second Department of Surgery, Kinki University School of Medicine
(Director: Prof. Dr. TAKESHI KUYAMA)
Received for Publication, May 10, 1988.

During screening for liver functions, biliary tract disease in non-jaundiced patients have been occasionally disclosed due to the elevated values of serum enzymes such as alkaline phosphatase, leucine aminopeptidase (LAP), gamma-glutamyl transpeptidase (γ -GTP), etc. Elevated values of these enzymes, in general, reflect the disturbance of bile flow due to cholelithiasis, inflammation or neoplasms related to the bile duct. On the other hand, the bile flow is also disturbed by mucous substances which very rarely develop in the bile duct and is called to be mucobilia or biliary mucinosis^{5,6)}. We report a case of non-jaundiced 76-year-old male who showed abnormally high values of serum enzymes upon liver chemistry studies, stricture of the lower common bile duct and suspected lumps of mucus in the duct.

Case Report

A 76-year-old male complaining of nausea and uncomfotableness in the upper abdomen visited out-patient division of Second Department of Internal Medicine in our hospital on May 27, 1986. Although the patient had medically treated a gastric ulcer 30 years before and had received herniorrhaphy at the left groin 10 years before, he has had neither suggestive sign nor symptom of biliary tract disease. His father and one of brothers died of cerebral apoplexy and his mother died of a renal lesion. Although the patient was nonicteric, abnormally high values of serum enzymes such as GOT 260 IU/l, GPT 270 IU/l, LDH 359 IU/l, alkaline phosphatase 551 IU/l, γ -GTP 840 IU/l and LAP 181 IU/l were obtained on liver chemistry studies. Subsequent fiberoptic gastroscopy revealed only a mild deformity of the duodenal bulb. Dilated intra- and extrahepatic bile ducts were visualized by ultrasonography (US) of the abdomen and dripping intravenous cholangiography. No gallstone was demonstrated by both examinations.

On June 27, 1986, endoscopic retrograde cholangiopancreatography (ERCP) was performed; a circular stricture of 8 millimeters length was noted at the lower common bile duct, two floating filling defects in the common hepatic duct and one filling defect in the cystic duct were visualized. The gallbladder except the was not opacified and the pancreatogram was virtually normal.

Key words: Benign bile duct stricture, Mucobilia, Abnormal liver chemistry studies.

索引語: 良性胆管狭窄, ムコビリヤ, 肝機能検査値異常.

Present address: The Second Department of Surgery, Kinki University School of Medicine, 177-2 Ohno-Higashi, Osaka-Sayama, Osaka, 589, Japan.

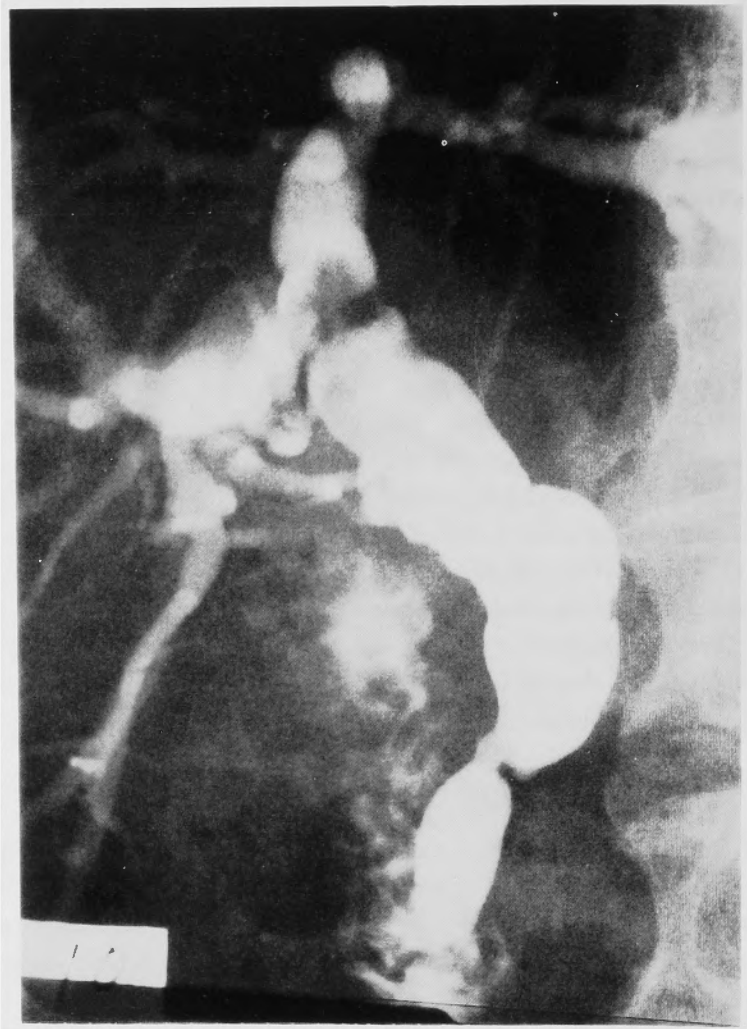

Fig. 1. Endoscopic retrograde cholangiogram showing the stricture at the lower common bile duct and filling defects in the biliary ductal system. Gallbladder is non-opacified.

(Fig. 1) Gallstones or debris were suspected concerning these filling defects.

Although the symptoms of the patient had disappeared, the elevated values of several enzymes in liver chemistry studies persisted at the levels noted on June 24, 1986. The patient was admitted in the Second Department of Surgery in our hospital on July 17, 1986. He was well-nourished, 171 cm in height, weighing 61 kg, with temperature 36.2°C, regular pulse rate 72/min, blood pressure 152/76 mmHg and with regular respiration. On physical examination, there was no jaundice in the sclerae and skin, no abnormality was found in the chest and abdomen except the scar of herniorrhaphy and no abnormal lymphnode was palpated over the entire body surface.

On laboratory data, anemia and leukocytosis were absent, coagulation factors, urinalysis, renal functions and serum tumor markers were all within normal limits. Among liver chemistry

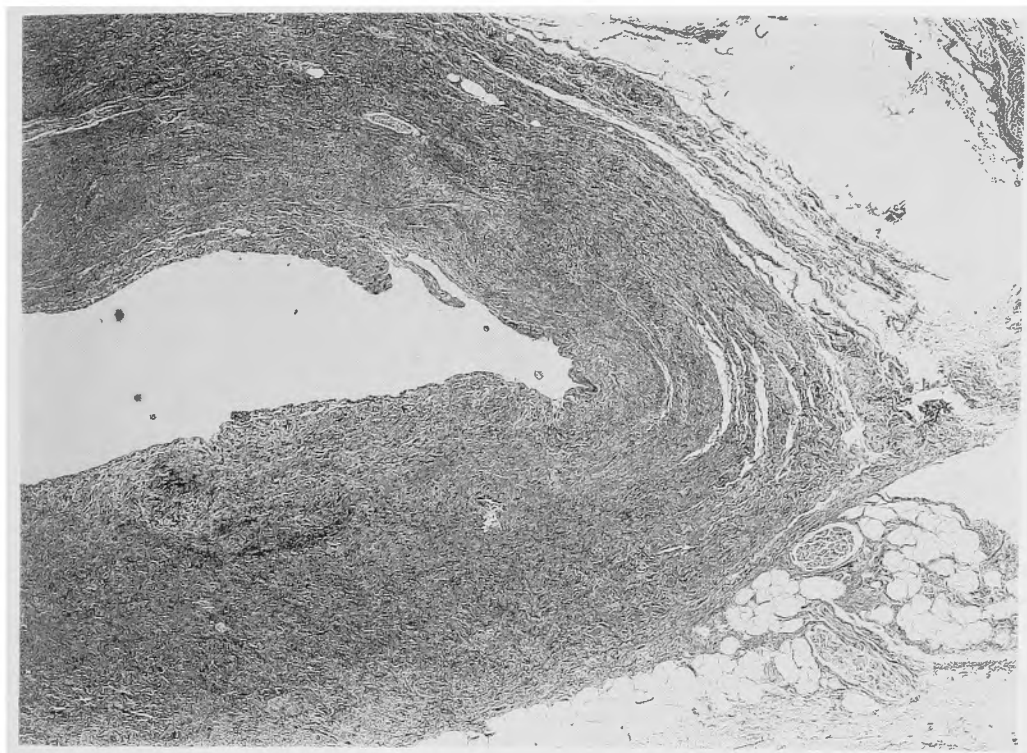


Fig. 2. Photomicrograph of the resected wall of common bile duct (HE×40).

studies, values of GOT and LDH had each returned to its normal range. However, GPT 79 IU/l, alkaline phosphatase 307 IU/l, γ -GTP 792 IU/l and LAP 115 IU/l were noted.

With a tentative diagnosis of benign stricture of the lower common bile duct associated with cholelithiasis, laparotomy was carried out on July 23, 1986; the gallbladder was slightly expanded and the extrahepatic bile duct was moderately dilated. On intraoperative US, neither a stone nor a mass was visible in or around the biliary ductal system. At first, choledochotomy was made; no gallstone was obtained. Saline irrigation through the incision developed some fragmented mucous substances, whose chemical analysis was not performed. Following the repeated irrigation, the common bile duct was divided at the level of insertion into the pancreas. No intraluminal abnormality was found through the cut end, which was closed with interrupted 3-0 silk. At the level of confluence, the bile duct was divided again. Cholecystectomy and Roux-Y type choledochojejunostomy was performed. The gallbladder contained neither stones nor mucous debris.

Histologically, the mucosa and muscle layer of the bile duct were displaced by the fibrinous connective tissues with moderate infiltration of lymphocytes and plasma cells. (Fig. 2) The diagnosis was chronic cholelithiasis. Histology of the gallbladder was usual chronic cholecystitis. The microbe culture of the bile which was obtained at surgery showed proliferation of *Klebsiella pneumoniae*, *Streptococcus faecium*, *Pseudomonas aeruginosa* and *Enterobacter cloacae*.

His postoperative course was uneventful. No mucous discharge in the bile was found

through the stent tube inserted along the anastomosis. Postoperative cholangiogram through the tube revealed no abnormality over the residual biliary ductal system. He was discharged on the 33rd postoperative day and has been doing well approximately two years since surgery without elevated values in liver chemistry studies.

Discussion

Benign stricture of the extrahepatic bile duct *per se* is caused by sclerosing cholangitis¹⁾, proliferative cholangitis²⁾, etc. The stricture localized in the lower common bile duct is occasionally encountered among patients suffering from chronic pancreatitis²⁰⁾. In the present case, however, the presence of the pancreatitis was ruled out based on the personal history, preoperative ERCP and intraoperative findings of the pancreas.

Although the bile duct stricture with dilatation of the upper portion on ERCP was not associated with so-called abnormal pancreatico-biliary ductal union, so-called type 3 choledochocoele of ALONSO-LEJ *et al.*²⁾ was suspected in the present case. However, it was impossible to identify the present lesion to be congenital or acquired from the histology of the resected bile duct.

It may be reasonable that the initial stage of bile duct stricture shows only the abnormally elevated values of serum enzymes without appearance of jaundice. Although expansion of the upper bile duct is frequently demonstrated by imaging modalities such as US, CT, etc. in the early stage of stricture of the lower bile duct, it is occasionally hard to evidence the etiology of the stricture, particularly in shortly localized one. As a rule, jaundice appears with progression of the stricture, and resultant suppurative cholangitis or biliary cirrhosis may develop. When the obstruction of bile duct continues, the intraductal bile becomes thick. For example, inspissated bile syndrome in infants³⁾ is well known. Although minimal mucous substance is occasionally seen at choledochotomy for patients having had choledocholithiasis, cases of mucobilia, who have had massive mucous substances in the biliary ductal system, have been seldom encountered.

TRAIN *et al.*²³⁾ stated that a filling defect near the cystic duct at the initial stage of instillation of contrast material on percutaneous transhepatic cholangiography was visualized in six patients associated with obstructive jaundice. They suspected that the filling defect was caused by incomplete mixture between the inspissated bile and the contrast material due to the different specific gravity between them²³⁾. The inspissated bile was gradually mixed with the contrast material and therefore, the filling defect disappeared in their series of cases²³⁾. On the other hand, if massive mucous substance was present in the bile duct, it may be hard to opacify the whole ductal system. Whereas, a lump of mucus in the bile duct may be visualized to be a floating and perpetual filling defect on the direct cholangiography without mixture to the contrast material. The filling defect caused by a mucous mass should be differentiated from the defect due to the neoplasm, gallstone, clot, air bubble, etc.¹¹⁾, most of which are easily distinguished by US, CT, and other techniques. However, the definitive diagnosis of mucobilia is difficult except cases where the mucous substance was obtained during the maneuver of direct cholan-

Table 1. Cases of mucobilia whose etiology unknown reported in the Japanese literature

Author	Age and Sex	Signs and Symptoms	Preoperative Findings	Mucous substance	Performed operation	Prognosis
Sugiura et al. ²¹⁾ (1976)	55 M	Jaundice, fever, abdominal pain	Post-cholecystectomy Hepatolithiasis	Flog egg-like 105 g	Laparotomy, 5 months later hepatectomy	Cured
Ohi et al. ¹⁸⁾ (1978)	76 F	Jaundice, anorexia	Post-cholecysto- duodenostomy	Agar-like	Cholecystectomy and choledochotomy	Fair
Miyoshi and Kondo ¹⁵⁾ (1981)	54 F	Jaundice, fever, abdominal pain	Stricture of the lower bile duct Some filling defects	Postoperative discharge through T tube	Cholecystectomy and choledochotomy	3 months later T tube removal fair
Hashikura et al. ⁷⁾ (1984)	59 F	Gallstone-like attack	Liver dysfunction	Jelly-like	Cholecystectomy and choledochotomy, later endoscopic papillotomy	Fair
Present case	76 M	Nausea, un- comfortableness in the abdomen	Liver dysfunction, narrowed lower bile duct, filling defects	Fragmented mucus	Cholecystectomy, partial resection of the CBD* and C-Jstomy**	2 years, fair

* common bile duct, ** choledocho-jejunostomy

giography. Although application of US may be helpful in detecting abnormality of the biliary ductal system, the intraoperative US¹⁴⁾, which visualizes the structure more clearly than the extracorporeal US, will generally not provide sufficient detail to identify intraductal soft mucous substance.

Mucobilia has been caused by cystadenocarcinoma of the liver¹⁶⁾ and pancreas⁸⁾, carcinoma of the bile duct^{6,9)}, so-called mucin-producing carcinoma of the pancreas²²⁾, cyst of the pancreas¹⁹⁾, cystadenoma of the liver¹²⁾ and pancreas¹⁷⁾, etc. Whereas, rare cases of mucobilia whose etiology was not determined by careful examinations have been noted. To our knowledge, only 5 cases including our own case have been reported in the Japanese literature^{7,15,18,21)}. (Table 1) Although hepatolithiasis²¹⁾ and possible hypersecretion of the mucus in the post-anastomosed gallbladder¹⁸⁾ were reported to be the associated diseases among these cases, no suggestive pathohistological change but a localized stricture of the lower bile duct was evaluated to be the cause of mucous substance in the present case. If the three filling defects upon pre-operative ERCP in the present case were gallstones, they could not have passed the narrowed portion of the lower common bile duct due to their size and location. The fragmented mucous substance obtained at surgery were far small compared with the filling defects. Possible passage into the duodenum through the narrowed segment of the bile duct may develop if the filling defects were the mucous substance.

CHOU *and* CHAN⁴⁾ stated that long-term irritation of the epithelia of the bile duct should be one of the causative factors of mucin-producing carcinoma. Although there may be slow-growing type of the bile duct carcinoma¹⁰⁾, the postoperative course of this patient indicates no malignant nature of his mucobilia. Benign stricture of the lower bile duct associated with chronic inflammatory change of the ductal lumen was suspected to be the cause of mucobilia in the present case. To our knowledge, the relationship between the proliferation of multiple microbes in the bile and development of mucobilia has not been reported.

References

- 1) Aadland E, Schrupf O, Fausak K, et al: Primary sclerosing cholangitis: a long-term follow-up study. *Scand J Gastroenterol* **22**: 655-664, 1987.
- 2) Alonso-Lej F, Rever WB Jr, Pessagno DJ: Congenital choledochal cyst, with a report of two and analysis of 94 cases. *Int Abstr Surg* **108**: 1-30, 1959.
- 3) Bernstein J, Braylan R, Brough AJ: Bile-plug syndrome: a correctable cause of obstructive jaundice in infants. *Pediatrics* **43**: 273-276, 1969.
- 4) Chow ST, Chan CW: Mucin-producing cholangiocarcinoma: an autopsy study in Hong Kong. *Pathology* **8**: 321-328, 1976.
- 5) Goinard P, Pelissier G, Streit P: Mucinoses des voies biliaires. *Mem Acad Chir* **86**: 849-854, 1960-cited by 6).
- 6) Hadjis NS, Slater RNS, Blumgart LH: Mucobilia: an unusual cause of jaundice. *Br J Surg* **74**: 48-49, 1987.
- 7) Hashikura Y, Azato S, Koike H, et al: Repeated gallstone-like attacks due to the mucinous substance in the bile duct. A case report. *Shinshu Med J* **32**: 190, 1984. (in Japanese).
- 8) Ito Y, Blackstone MO, Frank PH, et al: Mucinous biliary obstruction with a cystic adenocarcinoma of the pancreas. *Gastroenterology* **73**: 1410-1412, 1977.
- 9) Kage M, Koga M, Hidaka H, et al: Mucin-producing cholangiocarcinoma with obstructive jaundice: report of two cases. *Acta Hepatol Jpn* **21**: 1068-1076, 1980. (Eng. Abst.)
- 10) Kinami Y, Miyazaki I: A study of multiple bile duct carcinoma. *J Jpn Soc Cancer Ther* **16**: 26-34, 1981.

- 11) Kittredge RD, Baer JW: Percutaneous transhepatic cholangiography. Problems in interpretation. *Am J Roentgenol* **125**: 35-46, 1975.
- 12) Kumagai Y, Hikosaka A, Ida T, et al: Mucin-producing cholangiocystadenoma in the left hepatic lobe: report of a cured case. *Yamanashi Med J* **8**: 84-87, 1981. (in Japanese).
- 13) Krukowski ZH, McPhie JL, Farquharson AGH, et al: Proliferative cholangitis (cholangitis glandularis proliferans). *Br J Surg* **70**: 166-171, 1983.
- 14) Machi J, Takeda J, Kanegawa T: Advantages of operative ultrasonography over operation contrast cholangiography during biliary surgery. *J Jpn Soc Clin Surg* **47**: 986-990, 1986. (Eng. Abst.)
- 15) Miyoshi T, Kondo Y: Prolonged obstruction of the biliary tract due to mucous substance. *Surg Diag Treatm (Tokyo)* **23**: 1671-1674, 1981. (in Japanese).
- 16) Morodomi T, Yoshida C, Takafuji K, et al: Cystadenocarcinoma with mucinous biliary obstruction. *Kan Tan Sui* **11**: 1163-1168, 1985. (in Japanese).
- 17) Nakasato H, Miyagi Y, Yara T, et al: A case of pancreatic cystadenoma developed obstructive jaundice due to mucin. *Jpn J Gastroenterol Surg* **15**: 1059, 1982. (in Japanese).
- 18) Ohi M, Watanabe T, Yosida S, et al: A cured case of obstructive jaundice due to mucous substance. *Jpn J Gastroenterol* **75**: 1456, 1978. (in Japanese).
- 19) Oketani S, Kuroki T, Shimono K, et al: A case of mucin-producing pancreatic cyst. *Jpn J Gastroenterol* **84**: 827, 1987. (in Japanese).
- 20) Stabile BE, Calabria R, Wilson SE, et al: Stricture of the common bile duct from chronic pancreatitis. *Surg Gynecol Obstet* **165**: 121-126, 1987.
- 21) Sugiura Y, Sotoma A, Endo I, et al: A case of obstructive jaundice associated with massive mucinous substance in the common bile duct. *Jpn J Gastroenterol Surg* **9**: 754, 1976. (in Japanese).
- 22) Takayama T, Kato T, Sano H, et al: Two cases of mucous secreting pancreatic tumor. *Biliary Tract & Pancreas* **5**: 229-234, 1984. (in Japanese).
- 23) Train J, Novick A, Dan SJ, et al: Radiolucency in the common bile duct simulating a gallstone. *Am J Roentgenol* **148**: 136-138, 1987.

和文抄録

胆管内に粘液状物質がみられた良性胆管狭窄：無黄疸の1例

近畿大学医学部第2外科 (主任：久山 健教授)

笠原 洋，上田 省三，森下 明彦，園部 鳴海
中尾 稀一，竹本 雅彦，山田 幸和，久山 健

吐き気と上腹部の不快感のみを訴えた無黄疸の76歳の男性の肝機能検査で，血清中の諸酵素値の異常な上昇がみられた．内視鏡的逆行性胆管膵管造影により，下部胆管の限局性狭窄と胆管内に2コ，胆嚢管内に1コの移動性の透亮像がみられ，胆石症の診断で開腹した．胆管系に結石の存在なく，胆管洗浄により粘液の流出がみられ，上記造影における透亮像も粘液塊であ

った可能性がつかった．胆嚢摘出と胆管部分切除を行い，切除標本は慢性の胆管炎であり，患者は術後約2年を経過して健在である．胆管内粘液物質存在の病態はムコピリアとよばれるが，その成因としての疾患が確認されなかったものは，自験例を含めて本邦では5例のみであった．