綜　　説

HISTOLOGICAL STUDY ON THE INNERVATION OF HUMAN BONE

By

TADASHI IGARI

Department of Orthopedic Surgery Iwate Medical College, Morioka
(Director: Prof. Dr. TADASHI IGARI)
(Received for Publication: Oct. 14, 1957)

INTRODUCTION

Mere routine clinical experience suffices to demonstrate that many kinds of pain sensation are felt in the bone, when any of these are diseased; obtuse pain, acute pain, oppressive pain and so forth. In surgical operation, the periosteum is susceptible to excruciating pain when pierced, cut, bruised or flayed, but when the periosteum is first removed and then the bone cortex is pierced with a drill, often no pain is complained of till the drill touches the bone-marrow. When however, a needle is introduced through the drilled hole or some liquid is poured through it, instantaneously the patient begins to feel pain. When a bone-marrow is laid bare and is cut or bruised, pain is felt too.

Thus clinical observations suggest that the periosteum and the bone-marrows are capable of sensation, but the capacity of feeling is widely different in the two parts.

LITERATURE

Such clinical observations have been known since long ago but reports on studies of the innervation of bones including the periosteum and the bone-marrows are by no means numerous. On the innervation of the periosteum, KÖLLIKER (1850) reported existence of nerve-plexus therein and later on (1858) reported discovery of VATER-PACINI's bodies in the periosteum, which RAUBER (1868) and PANSINI (1891) also have confirmed. Since then, no noteworthy work on the innervation in the periosteum appeared till the recent years. In 1926 MISCOLCZY, in the famous CAJAL'S LABORATORY in MADRID, investigated the nerves distributed in the periostea of the limbs of young mice and of the shoulder blade of young dogs and reported

Fig. 1. Miscolozy's diagram of supply of nerves from the periosteum in to the bone-marrow. Shoulder blade of the dog. Original by Miscolczy.

that they are distributed in net-works (Fig. 1). He also discovered VATER-PACINI's bodies between the origin of muscles and the outer layer of the periosteum of mice and presumed these to be specific to the periosteum. He reports that the nerve bundles distributed herein do not always form their terminations in the periosteum, but sometimes spread into the inner periosteum through the HAVERSIAN canals or run further into the bone-marrow avoiding medullar cells in the diaphysis and the osseous substance and the cartilages in their courses and form nodes in the marrow, but he could not readily detect any termination therein. Regarding such statements, STÖHR (1928) expressed his doubts about nerve fibres forming nodes and pointed out that the VATER-PACINI's bodies being apparatus necessary for regulating metabolism and blood flow in the bones, their existence is inadequate as the ground for neurohistological interpretation of the clinically known pains in the periosteum and bones. More recently, NOZAKI of Prof. SETO's LABORATORY has found in the periosteum of the bones near the knee-joints of early human fetus many nerve terminations including corpuscular end bodies (GOLGI-MAZZONI's bodies, RUFFINI's bodies and PACINIAN bodies) which were found only in the epiphyses, and simple terminations representing receptors of pain sensation.

On the other hand, studies on the innervation of the bone-marrow are even fewer, according to GOERING the oldest being that by DUVERNEY, who asserted in 1700 already that nerve fibres run through the foramina nutricia accompanying blood vessels. He has been followed by LUSCHKA (1863), KÖLLIKER (1899), OTTOLENGHI (1902), GLASER (1928), PETERSEN (1935), SCHANTAU (1936), FOĀ (1936), TAKEYAMA (1936), HURREL (1937), HIRAKI and TANAKA (1955) and few others. Among them, as far as I could ascertain, the only reports on the innervation of human bone-marrows were those by TAKEYAMA and HIRAKI of Japan.

In summarizing the above reports, we see that the majority are of the opinion that the nerves run into the bones through the foramina nutricia. Some affirm the existence of a small number of nerve fibres running via periosteum and HAVERSIAN canals (TAKEYAMA, MISCOLCZY, VARIOT, HIRAKI etc), but others deny them (TAKASE). As to the nature of the nerves, some assert the existence of both myelinated and unmyelinated fibres (VARIOT, OTTOLENGHI, TAKEYAMA, GLASER, ROĀ, RAUBER), but others deny the existence of myelinated fibres or failed to mention them (de CASTRO, HURREL, HIRAKI). PETERSEN gives an illustration of myelinated fibres running through a HAVERSIAN canal (Fig. 2). On the distribution of the nerves in the bone-marrows the opinions are in agreement, pointing out their close relation with blood vessels, especially the arteries in the marrows, some describing their arrangement

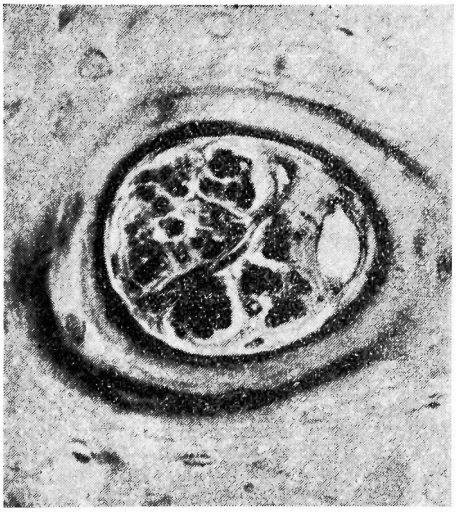

Fig. 2. Myelinated nerve fibres in Haversian canal. Human femur. Oiginal by Petersen.

as reticular and some as entwining. Since Luschka, most of the authors assumed the nerves to be sympathetic but Takeyama call them parasympathetic and Hiraki asserts to have found terminal reticula on the wall of the axial artery of the bone-marrow. There were only Ottolenghi and de Castro that have pointed out other terminations, the former seeing end corpuscles in the muscular layer of the blood vessels and the latter looped terminations.

Thus, the descriptions on the innervation of nerves in the bone-marrow have been in chaotic state and the terminal mode of sensory nerve fibres, if any, is not at all clarified to date. Moreover, reports on studies on human bone-marrows have been limited to those by the Japanese researchers Takeyama and Hiraki, suggesting the great difficulty of staining nerves in human bones.

MATERIALS AND METHOD

My materials of study were all taken from autopsied cases and specimens extracted at surgical operations of human fetus of 5, 6, 7, 8, and 9 months and human adults. The samples of periostea and bone-marrows were collected from the tibia, the femur and the corpus vertebrae, and the tibia and the femur were used as samples of tubal bones and the corpus vertebrae as that of reticular bones. The materials were fixed mostly in 10% neutral formalin, but more rarely in alcohol, for 6 months at the shortest. For decalcification 5% nitric acid solution (mixed with equal quantity of 10% formalin solution) was used. The specimens were usually cut into frozen sections, but the bone-marrows were prepared into celloidin sections. For staining, Seto's silver impregnation was applied, but some of the preparations were immersed in 5% sennite salt bath following a silver ammonium bath of Seto's method. With some specimens, myelin sheath staining was applied for confirmation.

INDIVIDUAL FINDINGS

I. *INNERVATION OF THE PERIOSTEUM.*

In the main, the periostea of the corpus vertebrae, at the height of the lumbar segment, of a 6-month and a 9-month human fetus and an adult were examined.

Myelinated and myelinless fibres derived from the anterior ramus of the n. lumbalis and from the lumbar sympathicus were found to come into the adventitia of the periosteum, accompanying the small arteries and blood capillaries originating in the lumbar artery and form dense basal nerve plexus there.

A) Sensory nerve terminations

The sensory fibres from these basal plexus run irregularly through the adventitia of loose connective tissue into the deeper parts: partly running either parallel to, closely along or entwining small arteries and capillaries, some proceeding unrelated to blood vessels, and others passing across the collagenous fibres. Then, they end either forming terminations within the adventitia, or even run as far as the intima of the periosteum which is formed of connective tissue fibres called fibro elastica or cambium. A very small part, however, penetrate further through the intima to the bone cortex and thence through the HAVERSIAN canals to the bone-marrows.

The terminations in the periosteum may be classified into 4 types in form, as follows:

1) Unbranched and simple branched terminations.
2) Bush-like terminations.
3) Complex branched terminations.
4) Capsulated corpuscular terminations.

1) Unbranched and simple branched terminations (Figs. 3 & 4).

In snch a termination, e. g., as illustrated here a myelinated fibre coming parallel to a small artery crosses the blood vessel and the periosteal connective

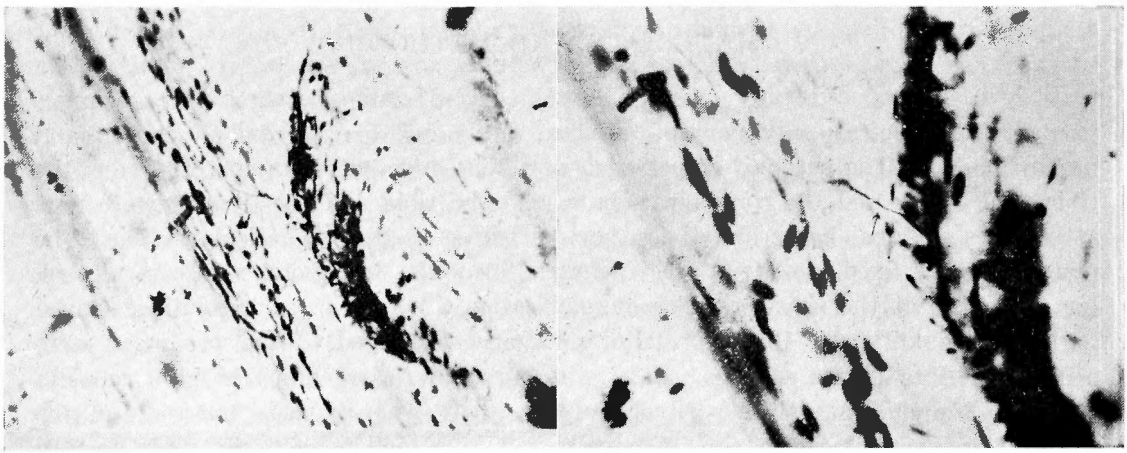

Fig. 3. A unbranched sensory nerve termination is found in the periostum of lumbal vertebrae in adult human. Seto's silver impregnation. Photo × 200.

Fig. 4, Ditto. Photo × 600.

tissue fibres in the transitional layer between the adventitia and the intima toward the deep part of the periosteum, losing its myelin sheath during the course, and branches out into two terminal rami, of which one ends sharply in close vicinity of a connective tissue cell and the other also in a sharp point among the connective tissue fibres.

Alongside the small arteries penetrating through the HAVERSIAN canals in the bone cortex to the bone-marrow, some myelinless nerve fibres were found running from the periosteum to the bone-marrow, but the number was never large at all.

2) Bush-like terminations (Fig. 5).

These terminations are formed by complication of the preceding simple terminations. The stem fibres count 2-3 per termination, which form a bush-like ending in the deep part of the periosteum, repeatedly undulating across the connective tissue fibres. These terminations have the characteristics of being capsuleless and showing no anastomosis among the terminal fibres. These terminations are too much undulating, so that they are difficult to photograph.

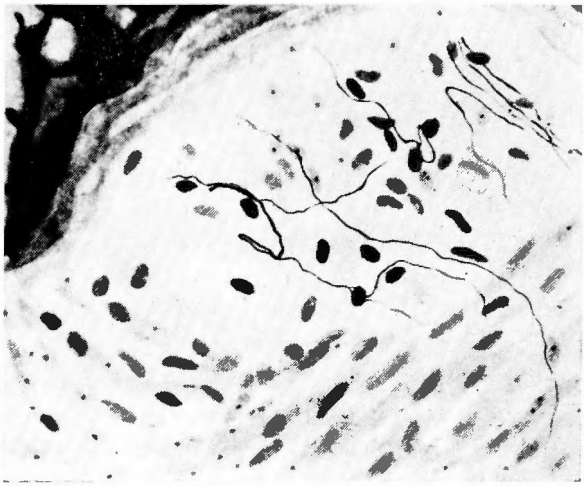

Fig. 5. Bush-like termination in the deep part of the periosteum. Human vertebra. Sketch × 1,000.

3) Complex branched terminations (Figs. 6, 7, & 8).

These are found in the stout dense collagenous fibre layer of the periosteal intima. 2-3 thick sensory fibres, after losing their myelin sheaths, first branch out widely, then repeat anastomosis to form a rhombus, thence throw out several branches, which again ramify arboreally and end in most cases in sharp points among the collagenous fibres after comparatively short courses, but some of the branches run backwards toward the stem fibres to end in fox's tail form.

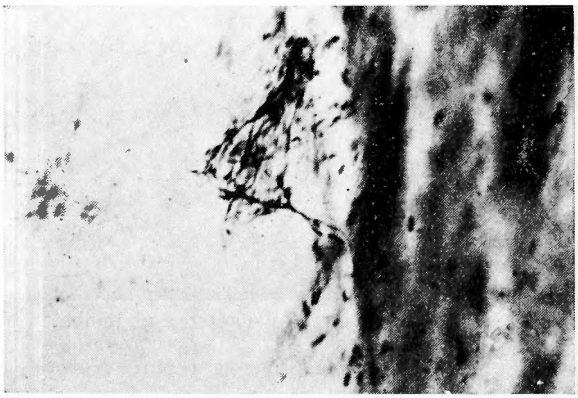

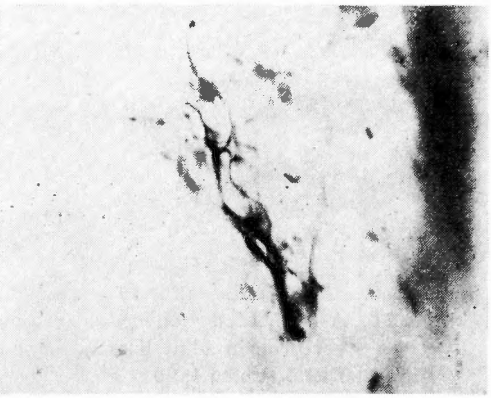

Fig. 6. A complexs branched termination is found in the periosteum of lumbar vertebrae in adult human. Same staining. Photo × 400.

Fig. 7. Ditto. Various level. Stem sensory nerve fibres end in fox's-tail form. Photo × 600.

Fig. 8. Ditto Various level. Photo × 600.

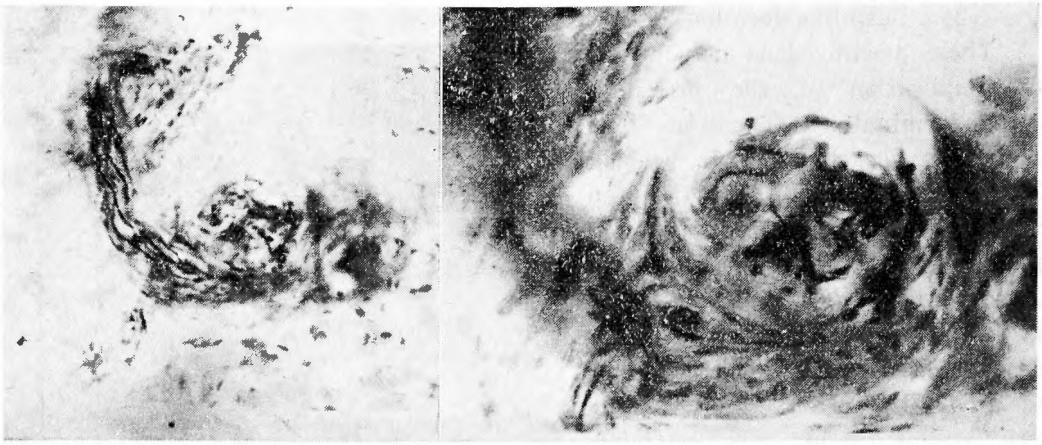

Fig. 9. A capsulated glomerular corpuscle is found in the perioseum of lumbar vertbrae in adult human. Same staining. Photo×600.

Fig.10. Ditto. Photo×1,000

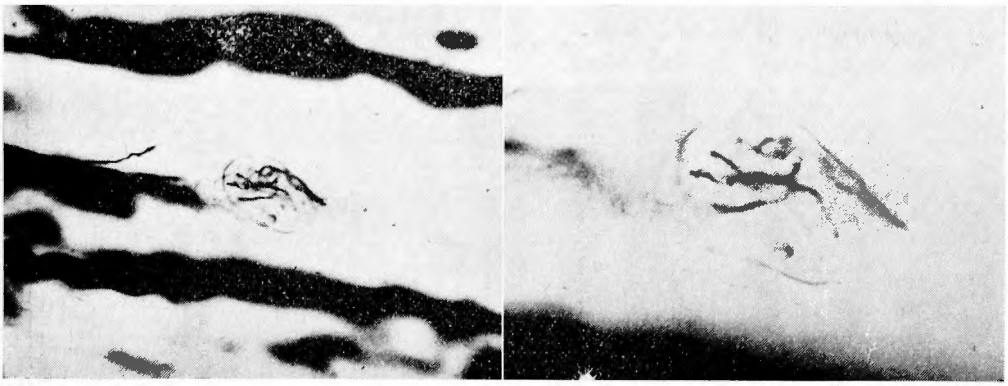

Fig.11 A capsulated glomerular terminal corpuscle is found in the periosteum of lumbal vertbrae in adult human. Same staining. Phot×200.

Fig.12 Ditto. Photo×1,000

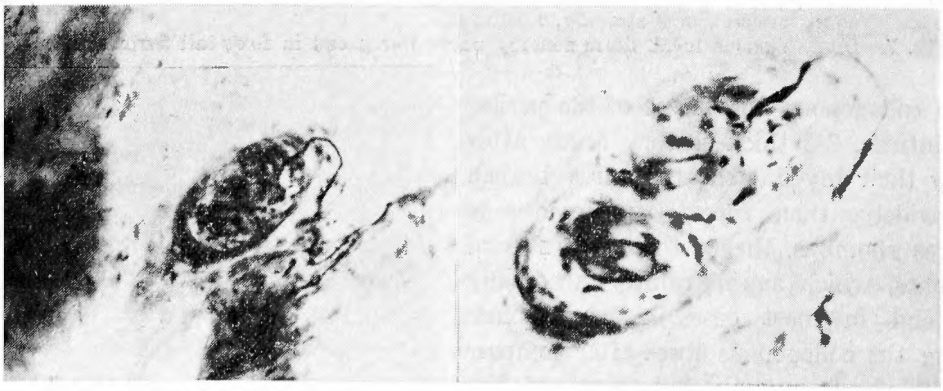

Fig.13. A capsulated double glomerular terminal corpuscle is found in the periosteum of lumbar vertebrae in adult human. Same staining. Photo×600.

Fig.14. Ditto. Photo×1,000.

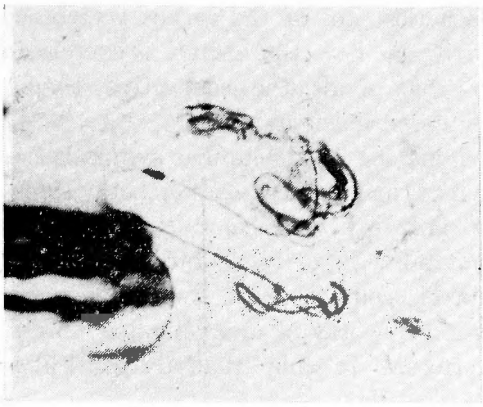

Fig. 15 A capsulated complex glomerular terminal corpuscles found in the is periosteum of lumbar vertebrae in adult human. Same staining. Photo × 600.
Fig. 16. Ditto Photo × 1,200.

4) Capsulated and corpuscular terminations (Figs. 9, 10, 11, 12, 13, 14, 15 & 16). These terminations are specific in form to the periosteum. They are vastly varied in development, are round or elliptical in form and are found in the deep part of the periosteum.

One or two sensory fibres sent out by the stem nerve, after losing their myelin sheaths immediately begin to form a glomerular termination after running wavy and looping courses showing change in size peculiar to sensory fibres and then sending out terminal rami. The glomeruli are varied in formation, and most frequently, a few of the fibres that have formed a glomerule in the capsule proceed to form a secondary glomerule in the same capsule. In general, the sensory fibres participating in the formation of the first glomerule are thick and those coming into the formation of the secondary glomerule are thin. The special nuclei in the corpuscle and the inner bulb are considerably abundant and are divided into two groups in tactile relation with the glomerule. In the corpuscular capsule is found a nervous colloid substance. The myelin sheaths are lost in the vicinity of the capsule, which consists of 2-3 layers of fibre membranes containing usually small cells densely packed and showing a toughness worthy of a sensory termination in a stout connective tissue. It may be that this formation is indicative of the sensitivity of the periosteum to sharp pain, as is the skin, or is related with the metabolism of the bone.

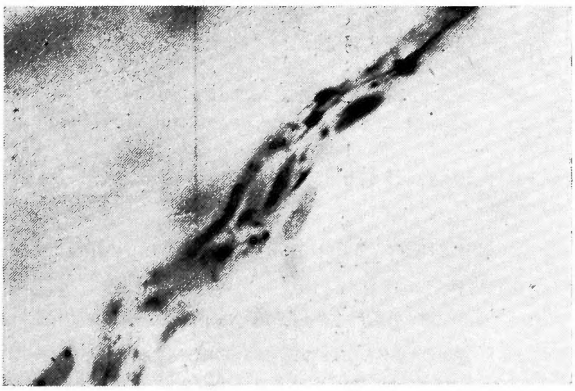

Fig. 17. Stöhr's vegetative terminal retcula is found in the periosteum of lumbar vertebrae in adult human. Same staining. Photo × 1,200.

B) Vegetative terminal reticula in the periosteum (Fig. 17).

There have been indeed no clear description of the vegetative nerves

in the periosteum in general, not to speak of the periosteum of the corpus vertebrae in particular. But now, I have succeeded in clarifying how the control is exercised by the vegetative nerves and in demonstrating that of all the connective tissue organs, the periosteum is the best provided with nerve elements.

The large number of unmyelinated fibres originating in the lumbar sympathetic ganglia and the lumbar nerve plexus formed with their centers on the both sides of the anterior longitudinal ligamentum run in company with small arteries and blood capillaries deep into the proper collagenous fibre layer or as far as into the intima periostei and form here and there in direct contact with the collagenous fibres or in the interfibrous loose tissues abundant net-works of unmyelinated fibres, i. e., the preterminal reticula and vegetative terminal reticula that are cord-like fibrillar reticula, in very active distribution.

These terminal reticula accompany special nuclei probably transformed from SCHWANN's nuclei and stand in control over the periosteal connective tissue cells by close contact. Thus, it has been a valuable fruit of this study that I have succeeded in demonstrating that the formation and the metabolism of the bones are under the control of the collagenous fibres and the blood vessels abundant in the periosteum and not less of the vegetative terminal reticula therein.

C) Innervation of the adventitia periostei and the surrounding loose tissue (Figs. 18, 19 & 20).

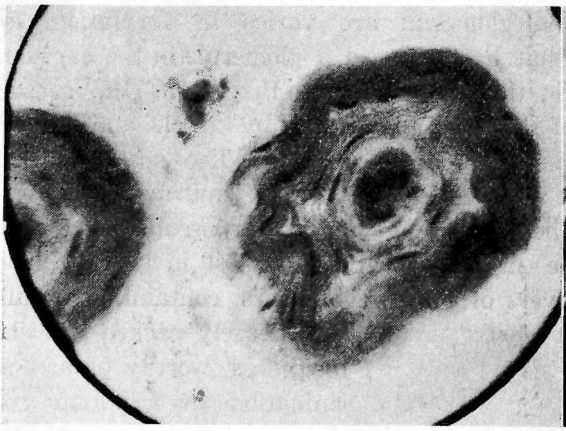

Fig. 18. Vater's corpuscle is found in the loose tissue of the outer layer of the vertebral periosteum. Human adult. Photo×200.

Fig. 19. Krause's corpuscle is found in the outer layer of the Periosteum of the fetal vertebrae (9. M.) Same staining. Photo×200.

The periosteum is bounded off the surrounding tissues by a loose connective tissue, which is also rich in sensory terminations.

As stated above, RAUBER reported that there are many VATER's corpuscles in the periosteum. These seem to be found in the adventitia of the periosteum or the transitional part of this and the adjacent tissues and I saw also them in the loose tissue between the periosteum of a corpus vertebrae and the muscle tissue where it attaches to the bone. SHIMODA of SETO's Laboratory has found GOLGI-

MAZZONI's bodies in or adjacent to the periosteum of the epicondylus tibiae of human fetus and reports that these exist independently or in company of vegetative nerves. Some years ago, I have confirmed the existence of capsulated corpuscles identical in structure to KRAUSE's bodies as found in joints in the same part. These are all glomerular corpuscles with capsules and are probably organs connected with deepsensation, especially, muscular sensation or may be with regulation of blood circulation.

Fig. 20. Ditto. Photo × 600.

II. *INNERVATION OF BONES*

A) *Innervation of cortex of long tubal bones* (Figs. 21, 22, 23, 24, 25, 26 & 27).

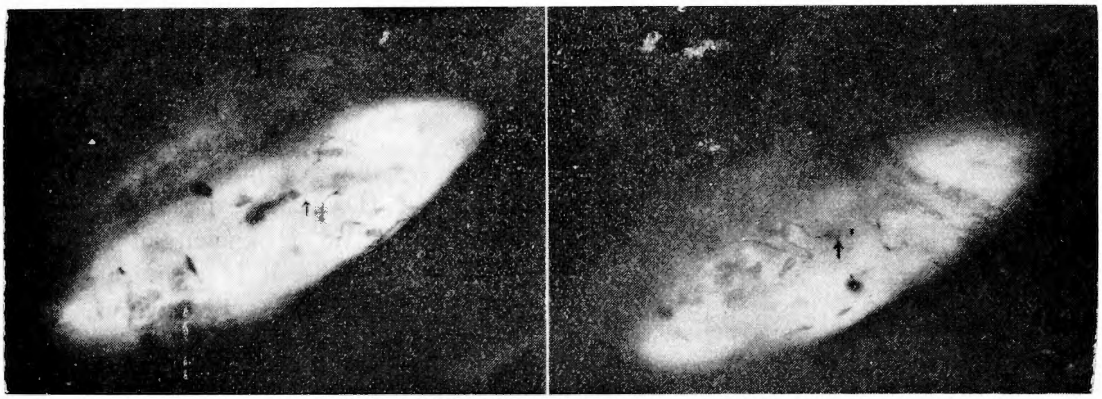

Fig. 21. Sensory nerve fibres are found in the HAVERSIAN canal of the tibial cortex. Human. Same staining. Photo × 600.

Fig. 22. Ditto. The other level. Nerve fibres connect in these 2 photographs (Figs. 21 &22).

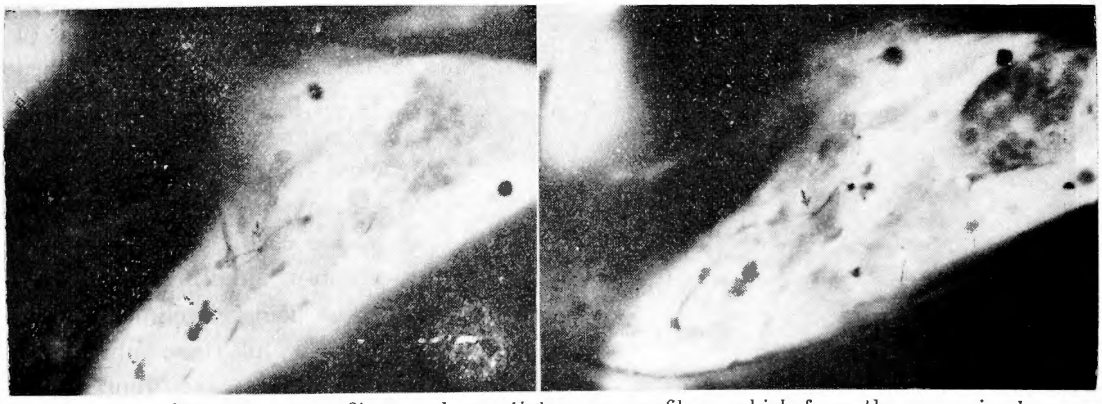

Fig. 23. Sensory nerve fibre and myelinless nerve fibres which form the very simple type of network in the blood capillary wall, in the HAVERSIAN canal.

Fig. 24. Ditto. The other level. Only sensory nerve fibres are found in this level. Sensory nerve fibres connect in these 2 photographs (Figs. 23 & 24.).

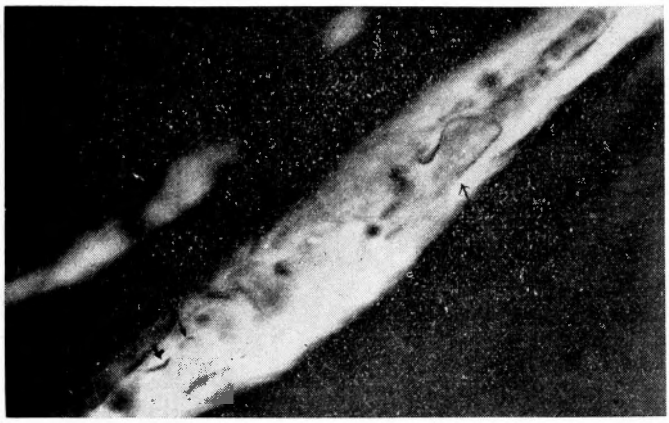

Fig. 25. Sensory nerve fibres are found in the HAVERSIAN canal of the human tibial coxtex. Same staining. Photo × 400.

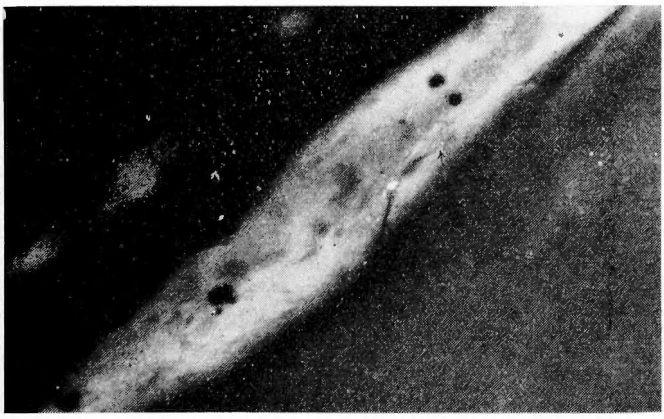

Fig. 26. Ditto. The other level. Sensory nerve fibres connect in these 2 photographs (Figs. 25 & 26) and come in to close contact with the endosteum of the HAVERSIAN canal.

Fig. 27. A myelinless nerve fibre runs in company with blood capillaries through the HAVERSIAN canal. Human tibia. Same staining. Photo × 400.

According to RAUBER, the quantity of nerve fibres varies with different bones, and a part of the fibres exists in the periosteum, another in the osseous substance and yet another in the medulla.

The nerve fibres going over from the periosteum into the bone-marrow run through the HAVERSIAN canals accompanying small arteries and blood capillaries. As stated above, MISCOLCZY has published a diagram of distribution of nerves from the periosteum into the trabeculae. STÖHRE says that PTERSEN has found bundles of myelinated fibres running through the HAVERSIAN canals. At present, little is known of further details. It is a clinically established fact, however, that the bone cortex is low in sensitivity to pain and that in nerve diseases, changes soon appear in the cortex.

According to my study, in the cortex of human long tu -bal bones, the nerves supplied to the periosteum and the medulla are not necessarily in close contact and in quantity the myelinated fibres found in the cortex are almost negligibly small, most of the fibres being myelinless. The majority of these unmyelinated fibres are represented by vascular wall nerves and perivascular nerves, and no one has yet succeeded in

finding how these are terminated.

So, the majority of the branches of the periosteal nerves running through the HAVERSIAN canals into the bone cortex are myelinless, which are smooth-surfaced and show little, if any, change in size while running along blood capillaries solitarily or in bundlets of several strands. These smooth fibres pass over into the STÖHR's so-called capillary nerves.

The greater part of the nerves in the cortex, however, according to what I have learned in my fetal specimens, seems to consist of fibres originating in the intramedullar nerves coming in through the foramina nutricia of the bones.

These fibres, excepting only a very small part, are unmyelinated smooth ones probably of vegetative nature and accompany SCHWANN's nuclei and nuclei seemingly originating from these. These fibres run in company with blood capillaries through the HAVERSIAN canals or the reticular medullar lamina near them toward the periosteum.

The stem fibre of such a sensory nerve changes its course parallel to a blood capillary at the level of a HAVERSIAN canal, and twisting back while showing change in size peculiar to sensory fibres and sending out 1—2 branch fibres, crosses over its previous course, passes across the capillary, obliquely to the other side, then turns back to run meandering along the capillary and while showing again peculiar change in size and parting from the capillary, come up to the osseous wall of a HAVERSIAN canal to end sharply in contact with a bone cell there. The other branch running back wards along the capillary wall and crossing the main fibre also running back as above, turns outward off the capillary and after changing its size in a way peculiar to sensory fibres also runs up to the periosteum on the wall of a HAVERSIAN canal to end sharply in a simple termination.

Another sensory fibre also found in a HAVERSIAN canal was found to run spirally upon losing its myelin sheath, crossing itself twice, running crosswise along a capillary wall and ending sharply in an unbranched termination in contact with the inner periosteum of a HAVERSIAN canal. Such sensory fibres always accompany SCHWANN's nuclei, showing sometimes the appearance of the fibre running right through a SCHWANN's nucleus and sometimes of neurofibrillar distension in which the SCHWANN's nucleus is contained. The nuclei are elliptical or spindle-form in shape and usually have no plasma capsule. Generally speaking, sensory fibres are not uniformly distributed in all the HAVERSIAN canals of the bone cortex, but the distribution is rather thin.

The myelinless nerve fibres in the vascular wall nerves and the perivascular nerves coming in company of aa. nutriciae medullae form no end organs, except a very simple type of net-work. The terminal mode of these medullar fibres is similar to but much simpler than the capillary nerve nets found by STOHR on heart capillaries. In the majority of the cases, however, not only such capillary reticula but nearly always terminal reticula in contact with the endosteum of the wall of HAVERSIAN canals are also formed.

The unmyelinated fibres that run through the HAVERSIAN canals or the compact

substance are nearly smooth-surfaced nerve fibres of uniform size, and running parallel to the capillaries in the bone-marrow and sometimes crossing over them, repeat ramifications and anastomoses, at which they show slight nodule formation and neurofibrillar distension, and proceed toward the distal ends of the blood capillaries. At last they part from the capillaries and then run in labyrinthical complexity along the endosteum, coming into close contact to the osteoblasts of the endosteal wall. 2—3 of these fine unmyelinated fibres form reticular structures but never end free in terminal fibres terminating in sharp or blunt points. Neither do they form clear-cut vegetative terminal reticula which, however, on the other hand is distinctly found around ossification nuclei and blood vessel loops in cartilages of incomplete ossification. As the special features of these fibres to distinguish them from the sensory fibres, we may enumerate that the former, after running along blood capillaries forming capillary reticula, part from them and run along the surface of the endosteum and never send out terminal fibres. In well-stained sections, SCHWANN's nuclei may be found located parallel to and alongside these fibres or penetrated by them. Sometimes such nuclei are found directly in contact with the capillaries.

B) Innervation of bone-marrows.

In the above I have described how a part of the intraperiosteal nerve branch runs via HAVERSIAN canals into the bone-marrow and stated in the preceding that the number of such fibres is very small indeed.

The intramedullar nerve fibres of the long bones are represented in their majority by the nerve bundles running into the bones together with the nutritive blood vessels, as already pointed out in TAKASE's study on the medullar nerves in the tibia of mice. In human long bones, c. g., in the case of the tibia, the trunk nerve run in company with the a. nutricia tibialis branched out from the a. tibialis posterior through the foramen nutricia tibiae on the dorsal side of the shin-bone

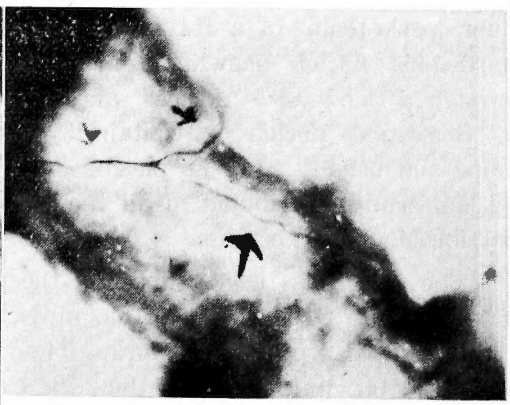

Fig. 28 Intramedullar vascular wall nerves in the surgical neck of femur. Human adult. Same staining. Photox400.

Fig. 29 Myelinless nerve fibres in the intramedullar vascular wall of the human femur. Same staining. Photo × 400.

into the bone-marrow, to form the n. intramedullaris tibiae. This trunk nerve consists of myelinated and myelinless fibres and divide into the following two nerve groups in the medulla:

1) Intramedullar vascular wall nerves.
2) Intramedullar basal nerve plexus.

1) Intramedullar vascular wall nerves (Figs. 28, 29 & 30).

Of the stem nerves that have come into the bone-marrow together with the nutrition arteries, the nerve bundles mainly consisting of myelinless fibres run along the small arteries in the medulla, sometimes surrounding and entwining them and sometimes running in the vascular walls. These nerve bundles contain 5—15 fibres each and running along one or both sides of the nutritive arteries close to their adventia, go on ramifying and anastomosing of the ramified branches, forming nodules and repeating such branching and knotting, proceed through the medulla in company of blood vessels in the form of reticula without terminal branches. The branch fibres of such reticula rarely if ever show change in size as is peculiar to sensory fibres, but are mostly of uniform size and form clear-cut net-works. The reduction in size of a fibre always occurs at the nodules of anastomosis and never before or after them. When the final stage of neurofibrils is reached, no further reduction in size is of course possible and only anostomosis and ramification go on. Some of the fibres depart to a small distance off the vascular adventitia and effect their reticulation in the medulla there but soon return to the side of the blood vessel. From such structure and nature of these myelinless fibres, we may assume them to represent intramedullar vascular wall sympathicus.

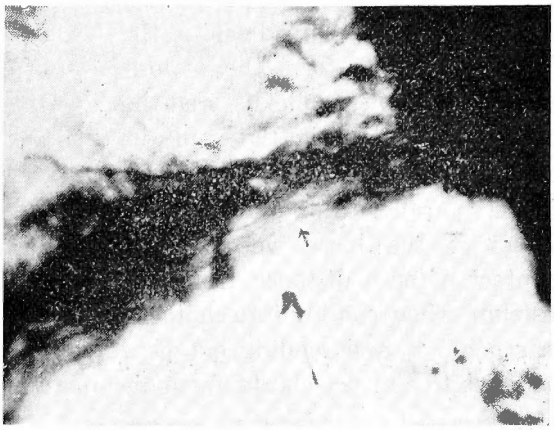

Fig. 30. Ditto. Photo × 1,000

2) Intramedullar basal nerve plexus (Figs. 31, 32, 33 & 34).

The bundles of myelinated fibres containing varying quantity of myelinless fibres, upon reaching the bone-marrow in company with nutritive blood vessels, begin to run approximately parallel to these vessels and go on ramifying and anastomo-

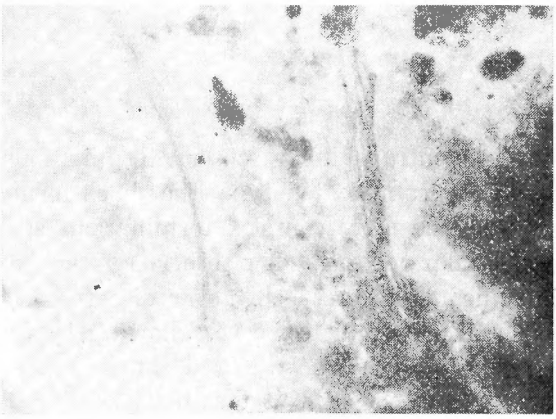

Fig. 31. Intramedullar basal nerve plexus in the human tibia. Same staining. Photo × 400.

sing at the branching points of the blood vessels and otherwise, but this ramifying and anastomosing is effected in a comparatively narrow area of the medulla and never in the entire breadth of the bone-marrow. Thus a net-work of nerve bundles is spread out in the bone-marrow, to form the intramedullar basal nerve plexus, and the nerve fibres forming these plexus run through the medullar parenchyma parallel to or quite independent of the blood vessels or in contact of or a distance from the bone trabecula, sending out branches to the end osteum when coming into contact with the bone trabecula and also into the medullar parenchyma, and sending out nerve rami to the blood vessels during their courses parallel to the vessels, to form terminations in each case.

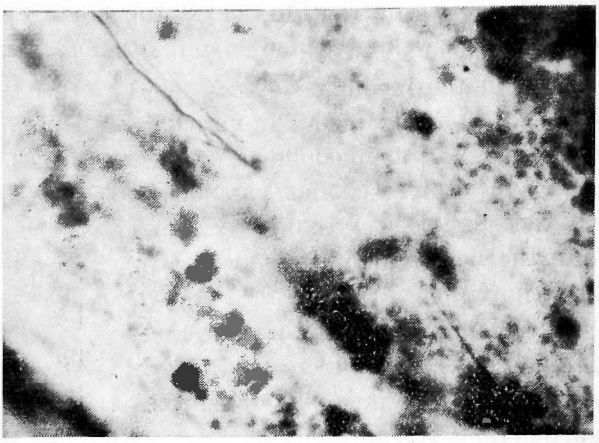

Fig. 32. Ditto.

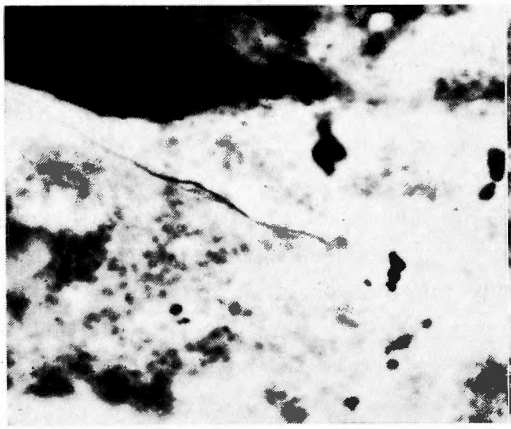

Fig. 33. Ditto.

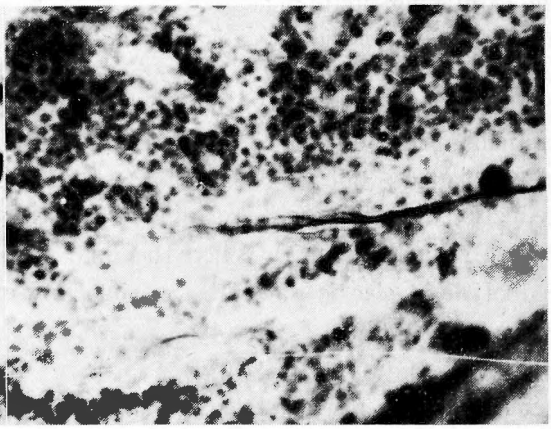

Fig. 34. Ditto.

C) Sensory nerve terminations in the bone-marrow (Fig. 35).

The intramedullar sensory terminations are very simple, only simple type ones and their complicated type the bush-form terminations being found to date, but none of the more complex terminations such as ansiform terminations or capsulated corpuscular endings nor other sensory terminal apparatus, apparently specific to intramedullar fibres being ever discovered. So, the intramedullar sensory terminations comprise only the two following types:

1) Unbranched and simple branched terminations.
2) bush-form terminations.

1) Unbranched and simple branched terminations (Figs. 36, 37, 38 & 39).

The basal nerve plexus formed in the bone-marrow, while engaged in ramifica-

tion and anastomosis, send out a few sensory branch fibres, which upon shedding their myelin sheaths meander, wind and spiral through the medullar parenchyma in courses of varying lengths and mostly end as sharppointed terminal branches in the parenchyma.

In the specimen here is found a thin sensory fibre branching out of a basal plexus running a spiral course repeatedly winding up and down, and finally ending in a sharp point in the medullar parenchyma. This specimen was obtained from the excised subtrochanter of a patient with congenital dislocation of the Hip.

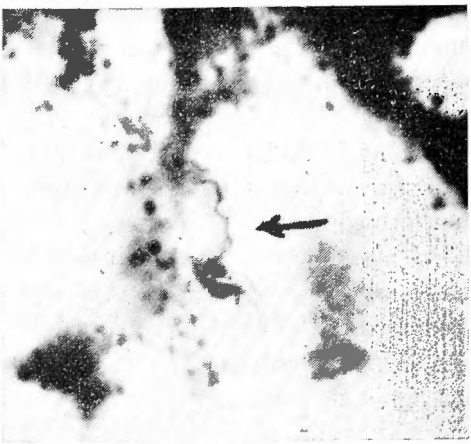

Fig. 35. Sensory nerve fibres in the bone-marrow of the human femur. Same staining. Photo × 1,200.

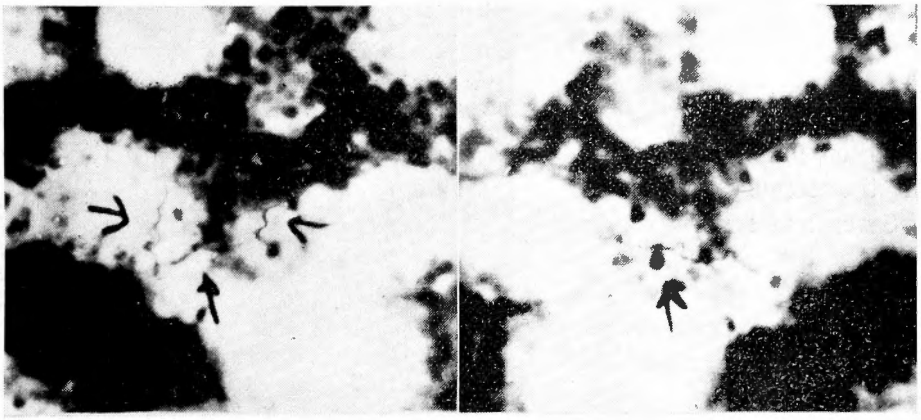

Fig. 36. Unbranhed termination in the bone-marrow of the femur. Human adult. Same staining. Photo × 1,200.

Fig. 37. Ditto. The other level. Terminal nerve fibres connect in these two photographs (Figs. 36 & 37).

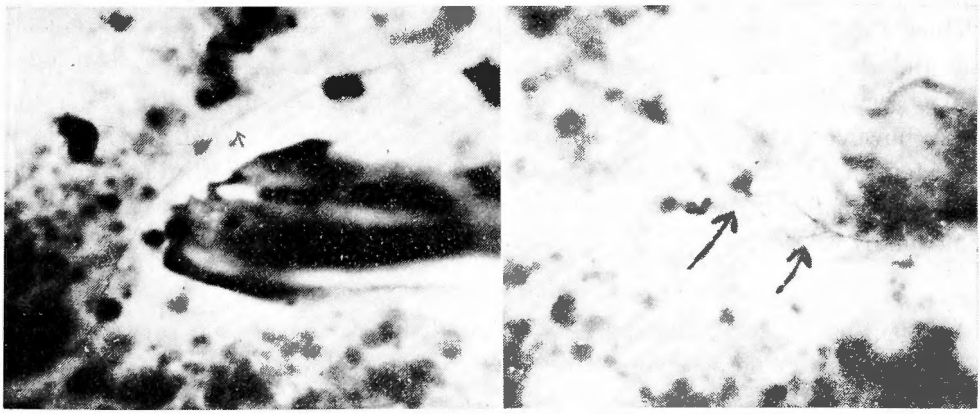

Fig. 38. Unbranched termination near the bone trabecula in the tibial bone-marrow. Human fetus. Same staining. Photo × 400.

Fig. 39. Simple branched termination in the bone-marrow of the femur. Human adult. Same staining. Photox1,200.

Often I found 1—2 strands of thin nerve fibres coming from the basal plexus running a rather short course after losing their myelin sheaths and then along the bone column to end sharply in contact with the endosteum. I cannot, however, as yet decide whether such fibres are of sensory nature or not.

Some of the nerve branches, upon losing their myelin sheaths on the vascular wall, turn perpendicular to the vessel and running long or short courses, end sharply in the medullar parenchyma.

I also found 1—2 myelinated sensory fibres branched out from a vascular wall nerve diverting in their courses to meander among the medullar parenchymal cells, then return to the original direction, then again running a spiral course, winding and looping, finally returning to the adventitia of the original small artery, branching out again and ending after more or less lengthy courses in end-loops formed on the vascular wall. This termination was not photographable owing to its extreme undulation.

2) Bush-form terminations (Fig. 40.).

These are the same simple terminations a little complicated by multiplication of the terminal branches. The sample illustrated here has been found in the diaphysis of the femur of a human adult. Several sensory fibres sent out from an intramedullar vascular wall nerve, after showing crooks near the small arteries, end in sharp points in the intramedullar parenchyma.

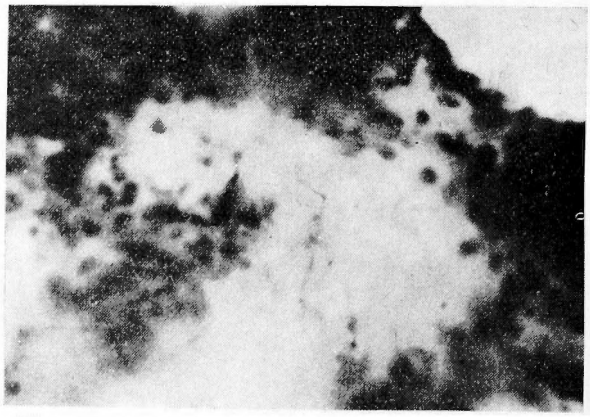

Fig. 40. Bush-like termination in the bone-marrow of the human femur. Same staining. Photo × 1,200.

It is, however, of very rare occurrence to see sensory terminations of that much complexity in the bone marrows.

Thus, the terminal mode of sensory nerves in the bone marrow is extremely simple and the distribution of the terminations is also far from dense, so that the clinical observations cited at the outset of this paper are sufficiently endorsed. It may be, however, that since the bone marrows are covered up on all sides in rigid bone cortex that utterly refuses expansion, this physical limitation in space is helping these thinly distributed and simple terminations in sensitively reacting to intramedullar sensory stimuli.

D) Intramedullar vegetative nerves

As mentioned above, the nerves distributed in the bone marrows are in thier majority vegetative nerves consisting of smooth myelinless fibres of uniform size, forming vasoparietal sympathetic reticula, but the intramedullar basal nerve plexus also contain many unmyelinated fibres, which form neurofibrillar simple terminal cord-like reticula distributed in the medullar parenchyma and probably innervating

the endosteum and the hematopoietic tissue and controling them. These terminal reticula, however, are not distributed over the whole area of the bone-marrow but are usually observable only in vascular walls or perivascularly, where the basal nerve plexus are found.

III *INNERVATION OF THE PERICHONDRIUM*

In 1928, SFAMENI wrote that the innervation of the perichondrium is similar to that of the periosteum, basing himself on examination of his own preparations, but now that numerous and complex sensory terminations have been discovered in the periosteum as above, this general statement is subject to revision.

Upon comparison of silver-impregnated preparations of the perichondria of the tibia and a corpus vertebrae of 6—9 months fetus and of the periostea of the same parts of human adults, the number of sensory fibres and their terminal mode are both far poorer in the former, complex type sensory receptors such as glomerular corpuscles being neves found here, only unmyelinated fibres and vegetative terminal reticula being observed in formation in most part.

IV. *INNERVATION OF OSSIFICATION NUCLEI AND THE UNOSSIFIED CARTILAGE* (Figs. 41, 42 & 43).

Many vascular ansae are found inthe long tubal bones and vertebral bodies offetus with incomplete ossification extending from their perichondria to the ossification

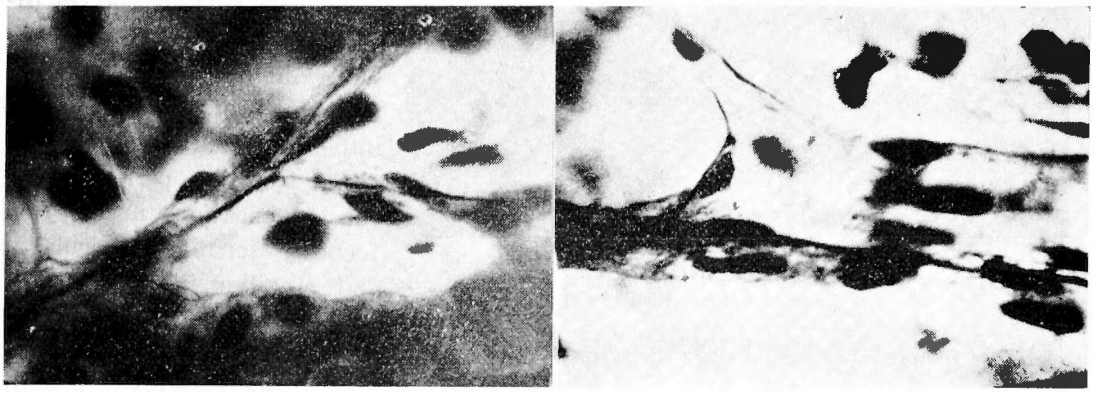

Fig. 41. Myelinless nerve fibrils spread out as cord-like vegetative terminal reticula on the endosteum of the ossification nuclei. Human vertebra. Same staining. Photo × 1,200.

Fig. 42. Ditto. Photo × 1,200.

nuclei, and here are seen nerve fibre bundles accompanying the small blood vessels that come in via the perichondrium. The majority of the fibres are unmyelinated and form vegetative terminal reticula in the blood vessel loops in the cartilages. These terminal reticula run nearly parallel to the blood vessels, divide at the branching points of the latter and spread out as cord-like terminal reticula on the cartilage walls and showing control over them, run further to the ossification nuclei. This finding shows histologically the absolutely close relation of the vegetative terminal reticula, as well as of the blood vessels, to the ossification of cartilages at

the ossification nuclei.

V. *INNERVATION OF THE EPIPHYSEAL CARTILAGE LINE* (Figs. 44 & 45).

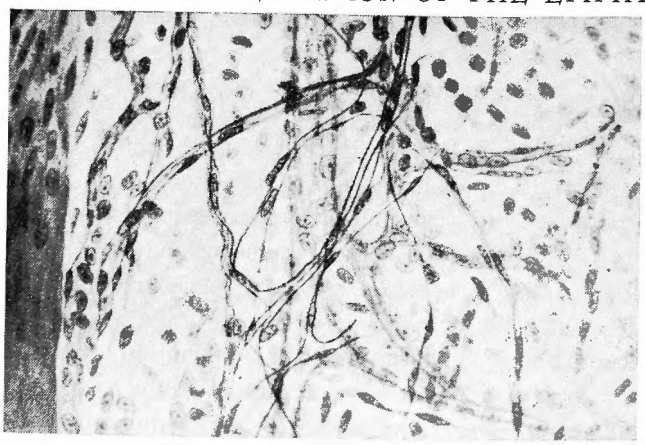

Fig. 43. Ditto. Sketch × 1,000.

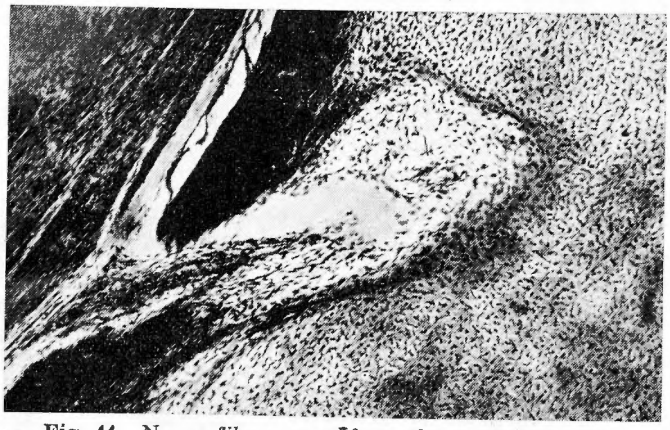

Fig. 44. Nerve fibres come from the periosteum and run into the epiphysal line. Embryonal tibia of Human. Same staining. Photo × 100.

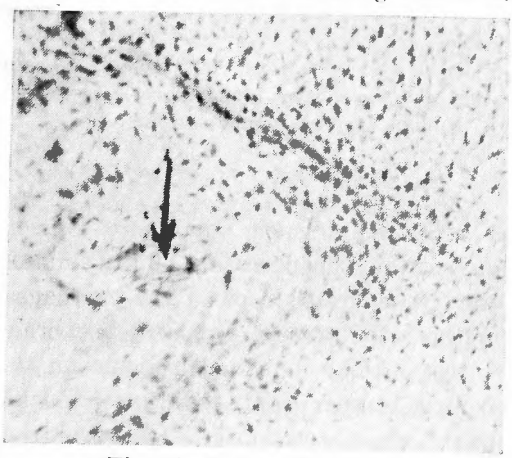

Fig. 45. Dittto. Photo × 400.

Here are distributed bundles of myelinated and myelinless fibres running in from the sides both of the periosteum and the medulla. Vegetative terminal reticula were found formed on the walls of the blood vessels coming from the periosteum into the medullar lumen, and myelinated nerve fibres were seen running through the collagen fibre cords in the suture. These fibres finally reach the vascular ansae in the cartilages.

In the above, I have succeeded in histologically demonstrating that in not yet fully ossfied cartilages many unmyelinated fibres are found running along the blood vessels into the vascular ansae extending from the periosteum to the ossification nuclei and forming terminal reticula in and standing in control over the vascular ansae and the endosteal walls of the ossification nuclei, thus showing close relation together with the blood capillaries on the enchondral ossification.

SUMMARY AND CONCLUSION

That the details on the innervation of human bones and periostea contained hitherto many dubious particulars is attributable in the main to the difficulties standing in the way of staining nerve fibres therein. These difficulties seem to

be chiefly due to the similarity of the bones and the periostea to the nerve fibres in silver affinity and the necessity of decalcifying the specimens.

To accomplish decalcification of thoroughly fixed materials as quickly as possible, using nitric acid, and to stain the sections with SETO's silver impregnation. These precautions have led to the success of this study of mine.

The results revealed the existence in the periosteum of various sensory nerve terminations and vegetative terminal reticula in abundance, as might have been anticipated long ago. As types of sensory terminations I found simple unbranched and branched, bush-like and complex branched, and capsulated corpuscular terminations, of which the last two seemed to show specificity to the periosteum.

The vegetative terminal reticula were found best developed in the periosteum of all the connective tissue organs.

VATER's bodies, KRAUSE's bodies etc. were found in the outer layer of the periosteum and the loose connective tissue forming the transition zone from the periosteum to the surrounding tissues.

In the bones themselves, we find the problem of the origin and the nature of the nerve fibres in the osseous cortex as outstanding. I found here were seemingly more intramedullar nerve fibres coming up into the cortex than the fibres originating in the periosteum and that these fibres coming from the inside and the outside appeard to be in mutual connection. Sensory terminations were very small in number, and their terminal branches always ended sharply, some after running spiral and some meandering courses. The vegetative fibres lacked clear-cut terminal reticula but were found running along blood capillaries in very simple form of STÖHR's capillary nerves, and finally along the endosteal walls of the HAVERSIAN canals and the osteoblasts.

Of the intramedullar nerves, the largest majority come in through the foramina vascularia nutricia and form either vascular wall nerves or intramedullar basal plexus. The former run along the intramedullar arteries, forming vegetative terminal reticula in the vascular wall as far as the artery is of medium size, but when the artery turns into capillaries, the fibres take the terminal form of capillary nets. No nerve elements were found along the venous system.

The intramedullar basal nerve plexus consist of sensory and unmyelinated fibres. In essence they are bushes of more than a dozen nerve fibres, which form unbranched or simple branched terminations and bush-like terminations in the medullar parenchyma.

Vegetative fibres are clearly observed in the form of plexus-nets of medullar nerve fibres but at present no terminal reticula, the real terminal formation of neurofibrils, have ever been found in the medullar parenchyma.

I have touched also upon the nerves in the perichondria and discussed the control relation of capillaries and the vegetative terminal reticula in the ossification nuclei, the perichondria and the vascular ansae in the epiphyseal cartilages, and have succeeded in demonstrating that the vegetative terminal reticula are very closely related to the process of endochondral ossification.

REFERENCES

1) Kölliker: Handb. d. Gewebelehr d. Menschen. Leipzig, W. Engelmann, **1**, 1902.
2) Rauber: Untersuchung über das Vorkommen u. die Bedeutung der Vaterschen Körperchen. München, C. Fritsch. 1867.
3) Pansini: Giorn. Assoc. Natur. Napoli. **1**, 1891. 4) Miscolczy: Z. Anat. 81, 1926.
5) Stöhr: Mikrosko. Anat. d. Veget. Nervensyst. Berlin, J. Springer. 1928. 6) Nozaki: Arch. hist. jap. **9**, 1955. 7) Duverney: Bull. et. Min. de la Soc. des Sciences de Paris. 1700. 8) Goering: Z. F. ges Neurol u. Psychiatrie. **83**, 1924. 9) Ottolenghi: Arch .Ital. d. Biol. **37**, 1902. 10) Petersen: Histologie u, Mikroskop. Anat. Munchen. J. F. Bergman -n. Ⅵ. 1935. 11) Glaser: Z. Anat. 87, 1928.
12) Schantau: Z. mikro. Anat. Forsch. **39**, 1936. 13) Foá: Kongresszbl. f. d. ges. inn. Med. **83**, 1936. 14) Takeyama: Mitt. med. Akad. Kioto. **16**, 1936. 15) Hurrel: J. Anat. **72**, 1938. 16) Hiraki & Tanaka: Okayama igakukaizassi (Jap.) **69**, 1957. 17) Variot und Remy: J. d. l'Anat. et d. la Physical 1880. 18) de Castro: Trab. Lab. Invest. biolo. Univ. Madr. **23**, 1925. 19) Seto: Tohoku j. Experiment. Med. **54**, 1951. 20) Sfameni: Giorn. r. accard. d. med. di Trino. **5**, 1900.
21) Krause: Arch. mikr. Anat. **19**, 1881.
22) Takase: J. Jap. Orthop. Surg. Soc. (Jap.) **30**, 1957. 23) Luschka: Cited by stöhr.
24) Mödendorf: Handb. Mikroskop. Anat. Menschen **4/1**, 1928.

和 文 抄 録

人間の骨及び骨膜に於ける神経分布に関する組織学的検索

岩手医科大学 整形外科教室
教 授 猪 狩 忠

人間の5ヵ月から9ヵ月迄の胎児と成人の剖検，手術により得られた骨，骨膜を硝酸脱灰により，凍結又はツエロイヂン切片となし，瀬戸氏鍍銀法により次の所見を得た．

骨膜 知覚終末として単純性終末，叢状終末，複雑性分岐性終末，有被膜性小体様終末を認めた．特に後二者は骨膜に特異性を示している様に思われた．
骨膜に於ける植物終網は結合織性器管中最もよく発達している．
骨膜周辺の鬆粗組織中には Vater 氏小体，Krause 氏小体を認めた．

骨 皮質に於ける神経線維の由来とその性状が問題となるが，私の所見では骨膜に由来する線維より髄内神経の皮質に及ぶものが多い様に思われた．但しこれらはお互に吻合，分岐しているので断定出来ないのは当然である．

ハーヴェル氏管にも知覚終末，植物神経を認め植物線維は Stöhr 氏の Capillarnerven に規を一にし，Haver 氏管内の毛細血管壁のみならず内骨膜壁にも接しながら，索状に走つている．
骨髄内神経は血管壁神経と髄内基礎神経叢を分ち，血管壁神経は植物神経線維を主とし，処々に植物終網を認める．髄内基礎神経叢は知覚線維，植物線維よりなり，知覚線維は，非分岐性，単純性分岐性終末，及び叢状終末を形成するが，それ以上の複雑な終末は形成していない．髄内に於いては索状の植物線維束が網状に走るも，実質細胞間には植物終網の形成は見られなかつた．次に軟骨膜に於ける神経分布について論じ，最後に骨端軟骨，化骨核に於ける分布について述べた．そこでは植物神経がよく発達し，植物終網を形成して，内軟骨性骨化には血液毛細管と共に非常に密接なる主宰関係のあることを組織学的に証明した．

* 本篇の要旨は第15回日本脳神経外科学会総会に於ける主題演説として発表した。