

EXPEIMENTAL STUDY ON TRAUMATIC LESION OF THE PANCREAS AND TREATMENT OF ITS CUT-END.

by

SHIGEKI NISHIDA

From the 1st Surgical Division Kyoto University Medical School.

(Director: Prof. Dr. CHISATO ARAKI),

(Received for Publication March 28, 1958)

PART I. EXPERIMENTAL STUDY ON TRAUMATIC LESION OF THE PANCREAS.

When the pancreas is occasionally injured during the performance of upper abdominal operation or by a trauma, diffuse peritonitis caused by pancreatic juice may ensue. Reports on such instances are innumerable, as published by WILKS and MOXON, GULEKE, NOST-KOLB, LEHRNBECHER; POLYA, WALZEL, WARREN, NAKAGAWA, FUJIOKA, etc. A search in the recent literature would reveal that only a few, such as TRIPODI and SCHERVIN, BRUNSCWIG, POPPER, KUBOTA, LEE, and ZEN have extensively studied and discussed on the experimentally produced lesion directly to the pancreas. Having carried out a series of experiments of traumatic lesion of the pancreas, POPPER concluded that the intraabdominal changes following the injury are more severe in the cases in which medicaments promoting secretion of the pancreatic juice or foods are administered prior to and after the trauma than in those cases which receive no such administration, and that when the injury is so severe as to cause contusion of the pancreas, the subsequent intraabdominal changes are, contrary to the expectation, rather mild irrespective of whether foods or medicaments are given or not.

Similar results were obtained by KUBOTA, LEE and ZEN when they experimentally studied prognosis and therapy in traumatic lesion of the pancreas.

The present paper is concerned with the experimental study done systematically by the auther in the aim to clarify what kind of traumatic lesion is more harmful, how do administration of medicaments promoting secretion of the pancreatic juice and feeding make influence on the prognosis, and what is the course of healing of the injured part of the pancreas.

METHOD OF EXPERIMENT.

The amount of pancreatic juice secreted and that of the ferments may significantly be varied according to whether or not variable medicaments or foods are given. Secretin, morphine, pilocarpine, and prostigmine promote secretion of the pancreatic juice while barbiturates and atropine are inhibitive. After Sugiyama, the secretion of the pancreatic juice reaches its maximum 2 hours after intake of food.

For standardizing the condition of the experimental animals, adult dogs of around 10 kg in body weight were used, to which, 2 hours after feeding, 0.04 gm per kg of sodium isomital were given intravenously, and various sorts of mechanical lesions were applied to the pancreas. The operation ended with closure of the abdominal wall in three layers after intraperitoneal administration of 100 000 units of penicillin. The mechanical lesion was constantly applied to the tail of the pancreas at the part adjacent to the duodenal wall and 0.5 cm distally to the bifurcation of the pancreatic duct into the main and accessory ducts, because at this part hemostasis after the transection seems to be readily performed and secondary changes due to injury of the vessels hardly occur.

According to LIUM and MADDOCK, the intraabdominal changes following experimental traumatic lesion of the pancreas reach the maximum 48 hours after when it is, therefore, the best time for the examination. Accordingly, autopsy was done, as a rule, 24 to 48 hours after the experimental lesion and one week and one to 2 months after, respectively, for investigation of the postoperative healing process.


The principal findings of autopsy were ascites, fat necrosis and changes of the pancreas, all of which were contrasted with each other, and in long surviving cases, it was carefully examined if formation of fistula or cyst had developed. The pancreas was macroscopically examined for presence of necrosis, degree of edematous changes, and sclerosis of the lobules when the duct was injured. Biopsy pieces were taken from the pancreas which were immediately fixed in BUAN's solution and stained with H. E., HEIDENHEIN's method modified by MARONEY and GOMORI.

Experiment I. Superficial Excision of the Pancreas.

As illustrated in Table 1, a 0.5 × 0.5 cm square sized superficial excision was made. In case the pancreatic duct was grossly injured, the cases were excluded from the examination. Hemostasis was performed always by pressure tamponade and not by ligation, as this might possibly occlude the duct.

The postoperative course was usually uneventful and the experimental animals

Tabl. 1. Superficial Excision

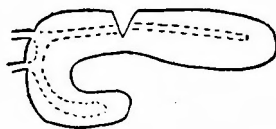


Dog No.	Postop. period	Mode of death	Ascites	Fat necrosis	Formation Cyst or Fistula
1	2 m.	killed	(-)	(-)	(-) (-)
2	2 m.	killed	(-)	(-)	(-) (-)
3	48 h.	killed	(-)	(-)	(-) (-)
4	48 h.	killed	(-)	(-)	(-) (-)
5	48 h.	killed	(-)	(-)	(-) (-)
6	48 h.	killed	(-)	(-)	(-) (-)

were able to stand and walk from the next morning on. Autopsy revealed that a small amount of nonhemorrhagic ascites and a small number of patches of fat necrosis were seen in one case only. In 48 hours cases, the greater omentum was seen to adhere fibrously to the excised part of the pancreas. In 2 months cases, however, no such adhesions were observed and the excised part was converted into a thin scar tissue and healed. In 48 hours cases, cell infiltration and necrosis were not recognized.

EXPERIMENT II. WEDGE-SHAPED EXCISION TOGETHER WITH INCISION OF THE PANCREATIC DUCT.

Tabl. (II) Wedge-shaped Excision (Pancreatic duct opened)



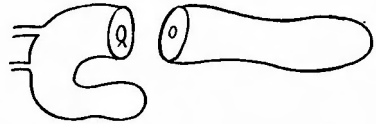Dog No.	Postop. period	Mode of death	Ascites	Fat necrosis	Formation of cyst or fistula
7	48 h.	killed	(+)	(+)	(-) (-)
8	48 h.	killed	(±)	(±)	(-) (-)
9	48 h.	killed	(+)	(+)	(-) (-)
10	48 h.	killed	(+)	(+)	(-) (-)

As illustrated in Table(II,) wedge-shaped excision was made so that the pancreatic duct was opened at the cut-surface. The postoperative course in these cases was somewhat more unfavorable but the experimental animal ameliorated at the 2nd postoperative day. This group of cases was succumbed to autopsy 48 hours after the experiments, in 3 of them 10 to 20 cc of ascites of which 2 were hemorrhagic in nature. In all the cases, patches of fat necrosis were present and the pancreas appeared markedly edematous, occasionally the pancreatic juice flowing out of the opened duct. Histological examination revealed necrosis, hemorrhages and infiltration of inflammatory cells in the very part of the lesion (Fig. I), but these changes are less conspicuous the farther the part away from the lesion.

EXPERIMENT III. TRANSECTION.

As illustrated in Table(III,) a transverse resection of 0.5 cm in length, was made in the tail of the pancreas, the pancreatic duct in the duodenal portion being ligated and that in the distal remained open. The postoperative course in this group was similar to that of Experiment II. In 48 hours cases, 2 were found to have 10 cc of bloody ascites and advanced fat necrosis. Adhesion of the greater omentum with the cut ends was unexceptionally present and necrosis, bleeding and edema were outstanding. Histologically, necrosis and infiltration of inflammatory cells at the cut end were prominent and extended towards the distal part. In the

Tabl. (III) Transection



Dog No.	Postop period	Mode of death	Ascites	Fat necrosis	Formation of cyst or fistula
20	I w.	killed	(-)	(-)	(-) (-)
21	2 m.	killed	(-)	(-)	(-) (-)
23	24 h.	killed	(+) hemorrhagic	(+)	(-) (-)
24	48 h.	killed	(+) hemorrhagic	(+)	(-) (-)
25	48 h.	killed	(±)	(+)	(-) (-)


cases which survived one week to 2 months, ascites and fat necrosis were no longer detectable, although sclerosis of the lobules was quite evident and in the cases of 2 months, the pancreas turned into a yellowish brown tinged rod. In the one week's case, adhesion of the greater omentum to the cut end was firmly established and substitution of the parenchymatous tissue by connective tissue was advancing (Fig. 2). At the end of 2 months, parenchymal cells were almost disappearing, only LANGERHANS islets being observable in the thickened interstitial tissue (Fig. 3 and 4).

EXPERIMENT IV. LONGITUDINAL INCISION OF THE PANCREATIC DUCT.

As illustrated in Table IV, the main pancreatic duct was first looked for, which together with the pancreatic tissue was incised longitudinally, the incision being directed towards the tail and 2 cm. in length. As the large sized artery and vein are coursing in the region where the incision is to be made, care must be taken not to injure these vessels. The postoperative course in this group was somewhat severe until 2 to 3 days later, when the condition of the experimental animal began to improve. Autopsical findings in 48 hours cases were a small amount of ascites and patches of fat necrosis which were as many as those seen in the Experiment II or III, although edematous changes were slightly more marked. In one to 2 months' cases, ascites and fat necrosis were entirely absent, but compact adhesion of the greater omentum to the part of the lesion and prominent atrophy and the sclerosis of the distal portion were seen. Hypertrophy of the head of the pancreas was not present. Histologic features were slightly more advanced as compared with those in the Experiment II or III, but not much different therefrom essentially. In longer surviving cases, conversion into connective tissue in the distal portion was conspicuous and the glandular cells almost disappeared.


EXPERIMENT V. GRUSHING OF THE TAIL OF THE PANCREAS.

Tabl. (IV) Longitudinal Splitting of Pancreatic Duct



Dog No.	Postop. period	Mode of death	Ascites	Fat necrosis	Formation of cyst or fistula
11	48 h.	killed	(±)	(+)	(-)
12	48 h.	killed	(+)	(+)	(-)
13	48 h.	killed	(+)	(+)	(-)
14	48 h.	killed	(+)	(+)	(-)
15	45 d.	killed	(-)	(-)	(-)
16	51 d.	killed	(-)	(-)	(-)
17	38 d.	killed	(-)	(-)	(-)
18	60 d.	killied	(-)	(-)	(-)
19	60 d.	killed	(-)	(-)	(-)

Tabl. (V) Crushing of the Tail of the Pancreas.



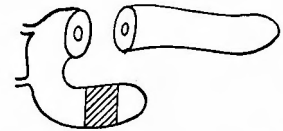
Dog No.	Postop. periode	Mode of death	Ascites	Fat necrosis	Formation of cyst or fistula
26	48 h.	killed	(-)	(-)	(-)
27	48 h.	killed	(-)	(-)	(-)
28	48 h.	killed	(-)	(-)	(-)

As illustrated in Table(v), the tail of the pancreas was crushed, producing a 2 cm long wound which extended to all the layer. The postoperative condition of the animals was rather unfavorable that they first began to stand and walk three days after. At autopsy, neither ascites not patches of fat necrosis were observed in the 48 hours cases. Except for edema and hemorrhages in the part experimentally crushed, few changes could be seen in the distal portion. Histological examination showed that there were marked changes in the part crushed but in its distal portion infiltration of immature interstitial cells and of inflammatory cells was nearly absent (Fig. 5). In other words, the very location where crushing was made revealed conspicuous histopathologic changes, while its distal portion and the intraperitoneal cavity demonstrated surprisingly less changes as contrasted with the results obtained in the Experiments II and III.

EXPERIMENT VI. TRANSECTION ASSOCIATED WITH CRUSHING.

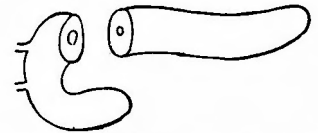
As illustrated in Table(VI), a 0.5cm long transverse resection was made in the tail of the pancreas, the duct being opened at the cut surface. An additional wound by crushing, 2 cm long and extending to all the layer, was made in uniform portion. The postoperative course and general condition were like those found in the Experiment V. Autopsy made 48 hours after the experimental lesions revealed that the changes were obviously less marked than those in the cases to which transection only of the pancreas was applied. In no cases were ascites and patches of fat necrosis observed. Although necrosis, hemorrhages and edematous changes were evident at the cut end and the part crushed, they were almost absent in the other part. Histologically, revealed a relatively heavy degree of necrosis, bleeding

Tabl. (VI) Transection associated with Crushing.



Dog No.	Postop. period	Mode of death	Ascites	Fat necrosis	Formation of cyst or fistula
29	48 h.	killed	(-)	(-)	(-)
30	48 h.	killed	(-)	(-)	(-)
31	48 h.	killed	(-)	(-)	(-)

Table. (VII) Prostigmin Administration after Transection



Dog No.	Postop. period	Mode of death	Ascites	Fat necrosis	Formation of cyst or fistula
32	48 h.	killed	(±)	(+)	(-)
33	48 h.	killed	(+)	(#)	(-)
34	48 h.	killed	(+)	(#)	(-)

Table. (VIII) Fastig Cases (with no Prostigmin administration)

Dog No.	Postop. period	Mode of death	Ascites	Fat necrosis	Formation of cyst or fistula
35	48 h.	killed	(-)	(-)	(-)
36	48 h.	killed	(-)	(-)	(-)
37	48 h.	killed	(-)	(-)	(-)

and edema, which were nearly absent in the distal portion, where parenchymal cells were normal in appearance, and infiltration of inflammatory cells and immature connective tissue cells being devoid of.

EXPERIMENT VII. PROSTIGMIN ADMINISTRATION AFTER TRANSECTION.

As shown in Table(VII), 0.5 cm long transverse resection was made in the tail, opening the duct at the cut surface. For promoting secretion of the pancreatic juice postoperatively, 10 cc of prostigmin (vagostigmin) is injected every 3 hours for 3 times. As to the postoperative condition, the animals were apparently emaciated and standing and walking were impossible. Autopsy made 48 hours after showed that in 3 cases ascites of 5 and 6 cc, respectively, were present. Besides, there were innumerable patches of fatty necrosis, and moreover, hemorrhages, necrosis and edema were found from the cut end to the distal part. The greater omentum was loosely adhered to the end but not occluding the duct. Histologic findings were more conspicuous than those found in the Experiments II and III, as the inflammatory cells infiltrated even to the distal part (Fig. 8).

EXPERIMENT VIII. FASTING CASES WITH NO PROSTIGMIN ADMINISTRATION.

As illustrated in Tacle(VIII), 0.5cm long resection was made in the tail, confirming that the duct was opened. No food but a small amount of water was given to the animals prior to and after the experiment. The postoperative general conditions were favorable and the animals were able to walk from the next day on. In 48 hours cases, the autopsy findings were necrosis and edema of slight degree at the cut end and none of ascites and fatty necrosis. Histological examination also revealed slight changes at the cut end and normal findings in the distal part.

EXPERIMENT IX. EXPERIMENT CAUSING FATTY NECROSIS.

Throughout the experiments stated above, any mechanical lesion to the pancreas could not produce such a severe difusse peritonitis caused by pancreatic juice which was fatal. The reason for this is quite obvious, as the greater omentum promptly adhered to the cut surface so that the opened duct was occluded, preventing outflow of the pancreatic juice. Should it be possible to let the duct be opened for a fairely long time and permitting the pancreatic juice be flowing into the peritoneal cavity continually, it may be successful to develop a diffuse peritonitis caused by the pancreatic juice which is lethal for the animals. For this purpose, the main pancreatic duct was cut, its duodenal end ligated and a vinyl tube inserted ca. one cm long into the pancreatic duct from the cut end, the other end of the tube remaining free in the peritoneal cavity. After the procedure, 100,000 units of penicillin was introduced in that cavity, and the operative wound was closed.

The postoperative course in these experimental animals was very severe and, generally speaking, none of the animals could stand walk. They were in lying position and drank little water. 2 cases died 24 hours and 3 days later, respectively. The autopsical findings were a large amount of hemorrhagic exsudate in both the abdominal and pleural cavity and fatty necrosis extending even to the subcutaneous tissue of the abdominal wall. The autopsy findings in the 4 to 5 days cases were similarly pronounced a great quantity of hemorrhagic ascites. The pancreas in those cases appeared dark reddish brown, markedly edematous and containing scattered patches of fatty necrosis. Histologic examination revealed advanced inflammatory changes, necrosis, hemorrhages and infiltration of inflammatory cells. Invasion of immature connective tissue cells was also present but lobulation and sclerosis of the glandular tissue were scarce. It was learnt by this experiment that the animal would not survive when the pancreatic duct remains opened and the pancreatic juice continually flows out into the free peritoneal cavity.

EXPERIMENT X. COLLECTION OF THE PANCREATIC JUICE.

It would be quite evident from the experiments as numbered above from I to IX that the subsequent pathological changes were slight in dogs in case the main pancreatic duct remained unopened. Even this was kept opened, the changes would variably be influenced by different factors, such as administration of food or medicaments promoting secretion of pancreatic juice, simultaneous lesion to the pancreas other than the purposed experimental trauma. For further investigation of the influence of simultaneous lesion, the pancreatic juice was collected and the relation of its amount with the lesion was estimated by the experiments which follow:

I. Production of PAVLOV-Dogs.

The animal underwent a median upper laparotomy. Firstly, orientation was made to reach the opening of the major pancreatic duct on the duodenal wall and then the pancreatic tissue adhering to the duodenal wall was detached as far 2 cm each above and below that opening, avoiding any lesion to the vessels on the way, which, if injured, should be ligated surely. Intestinal forceps were placed both above and below, as far as possible away from the opening, and the duodenum was cut, and immediately an end-to-end anastomosis was made. One half of the isolated duodenum, opposite to the opening, was cut off and the remaining half was sutured to the abdominal wall in two layers so that the pancreatic juice flew out extracorporally. In such an animal, the pancreatic juice began to flow out, from the 3rd to 4th postoperative day, so sufficiently as to be estimated.

To the longer surviving dogs, enough water, pancreatin and methionine must be given as the animals readily emaciated owing to outflow of the bodily juice and consequent dyspepsie. The following experiment was done in the dogs which survived more than one week and were strong enough to overcome the further experiments.

II. Results of the Experiments.

(I). Influence of Narcosis upon the Outflow.

Table. (X) Experiment Causing Fatty Necrosis.

Dog No.	Postop. period	Mode of death	Ascites	Fat necrosis	Formation of cyst or fistula
59	24 h.	peritonitis	100 cc.	abdominal and thoracic cavities subcutaneous tissue	(-) (-)
61	3 d.	peritonitis	100 cc.	abdominal and thoracic cavities	(-) (-)
62	4 d.	killed	20 cc.	abdominal cavity	(-) (-)
63	5 d.	killed	80 cc.	abdominal cavity subcutaneous tissue	(-) (-)

Table. (X) Influence of Narcosis upon the Outflow

Dog No.	time 30 min. before Narcosis	30 min. after Narcosis	30 × 2	30 × 3	30 × 4	30 × 5	30 × 6	30 × 7	30 × 8	30 × 9	30 × 10
	68	2.30	0.12	0.24	0.36	0.32	0.38	0.42	0.46	0.48	
69	2.00	0.10	0.30	0.26	0.35	0.50	0.50				
70	1.80	0.06	0.24	0.37	0.35	0.48	0.45	0.50	0.60	0.82	1.0
71	2.10	0.20	0.42	0.30	0.42	0.66	0.56				
average min. average 1 h.	2.05	0.12	0.30	0.39	0.36	0.51	0.48	0.48	0.54	0.82	1.0
		0.42		0.75		0.99		1.02		1.82	

Table. (XI) Influence of Crushing on the Outflow

Dog No.	time 30 min. after Narcosis	30 × (2) "	2 h. after Crushing	4 h. "	6 h. "	8 h. "	10 h. "	12 h. "	14 h. "	16 h. "	18 h. "	20 h. "	22 h. "	24 h. "
	76	0.17	0.20		0.	0.20	0.10	0.30	0.15	0.20	0.24			
77	0.14	0.24		0.	0.05	0.14	0.35	0.10	0.15	0.12	0.12	0.66	0.64	1.40
78	0.24	0.24		0.05	0.05	0.27	0.60	0.10	0.80	0.85	1.10	0.80	0.80	1.80
average	0.18	0.21		0.02	0.10	0.17	0.42	0.12	0.38	0.40	0.61	0.73	0.72	1.60

After BAEKIN, MUTO, SUGIYAMA, etc., the amount of the pancreatic juice to be secreted in the dog in the hunger period and per hour is 3 cc in average. In my PAVLOV-dog, the amount was nearly the same. However, the pancreatic juice secreted in a PAVLOV-dog under sodium isomital narcosis (0.04 g per kg of body weight) was, as shown in Table(X), nearly null, particularly during the first one hour, after which period the fluid gradually increased, amounting 1 cc 4 hours later.

(2). Influence of Crushing on the Outflow.

The PAVLOV-dogs were reoperated and the distal part of the pancreas was crushed, 2 cm long, reaching all the layers. The pancreas at this time appeared normal and any changes derived from the primary operation was not found.

As shown in Table (XI), the pancreatic juice secreted was little until eleven hours after when it tended to increase slowly amounting ca. 1 cc 20 to 24 hours

later. The experimental dogs awakened 4-6 hours after the reoperation.

It has become clear from the Experiment (1) and (2) that both sodium isomital narcosis and traumatic lesion exert their effects prohibitively on the secretion of the pancreas. Accordingly, the reason for the unexpectedly slight changes at autopsy in the Experiment V and VI may be accounted for transient interruption or reduction of the pancreatic juice after the crushing.

COMMENT

Little changes resulted when a superficial excision was made, not opening the duct. The pancreatic juice might flow out of the cut surface of the parenchyma but its amount was negligible. The greater omentum promptly adhered to the cut surface and healing immediately took place. In the cases of transection, wedge-shaped excision or longitudinal incision of the duct, on the contrary, the post-operative intraabdominal changes were ordinarily severe, because the pancreatic juice flew in the free peritoneal cavity out of the opened main duct when the animal awakened from the narcosis. The changes were further advancing when prostigmin, promoting the secretion, was given to the animal, although none of the animals succumbed at the 48th postoperative hour. During 24 to 48 hours after the operation, the greater omentum became adhered to the part of the lesion, taking the course of natural healing. When this process of natural healing was interrupted and the pancreatic juice flowing out as in the Experiment IX, the experimental animals died, showing acute fatty necrosis which extended even to the pleural cavity and the abdominal wall. The pancreatic juice contains inactive trypsinogen when it is inside the duct. After NORTHROP and KUNITZ, and MACDONALD and KUNITZ, however, the trypsinogen outside the duct readily becomes active by contacting with miscellaneous inorganic or organic substances.

It has been suggested that when the pancreatic tissue underwent mechanical lesion, particularly at upper abdominal operation, acute fatty necrosis might develop with an unfavorable course by supposedly slight trauma of the pancreas, while severe lesion directly to the pancreas might result in comparatively mild changes to be found at laparotomy. In either case the pancreatic duct was injured but the difference might be due, as pointed out by PAVLOV and BABKIN, to transitory decrease in the secretion by severe trauma of the pancreas. In fact, it is described in H. L. POPPER'S experimental work that the result of severe lesion to the pancreas is abnormally slight irrespective of whether the animal were fed before or after the operation. In my Experiments V and VI above described, this was likewise true. SCHAFFARZIK, on the other hand, said that acute fatty necrosis in dog is unlikely to develop after traumatization of the pancreas, as the organ contain little adipose tissue and is well mobile. As has been shown in the experiment here, the greater omentum promptly comes to adhere to the part of the lesion and occludes the opened duct, preventing flowing out of the pancreatic juice. It is, therefore, considered that the course of healing of the pancreatic lesion in the dog is far quicker than that in man.

In the Group (II) of the Experiment X, in which a crushing lesion was made, secretion of the pancreatic juice was little until 24 hours after the operation, thereafter gradually showing a tendency to reach the preoperative level. Accordingly, when the cut end of the duct is not closed by the greater omentum or the intestinal tract, the result as in the Experiment IX may ensue as the secretory function returns to normal. The occurrence of peritonitis, formation of abscess or fistula as in the case of a man may surely be accounted for the recovery of the secretion. It should, therefore, be stressed that the opened duct must never be neglected and untreated.

By different experiments as above mentioned, the postoperative courses in direct and mechanical trauma of the pancreas were observed. Unless treated especially as in the Experiment IX, the experimental dogs would not die, as a rule. To the part of the lesion, either it is the parenchyma or the duct, the greater omentum or the intestinal tract adhered organically and the glandular tissue in the distal part was always substituted by the connective tissue. The part of the lesion fell in necrosis and hemorrhages 24 hours later and the pancreas showed correspondingly edema, inflammatory cell infiltration and intraabdominal fatty necrosis. In 48 hours these inflammatory changes reached their peaks when the greater omentum began to adhere to the part of the lesion fibrinogenously, thus occluding the opened duct. Immature connective tissue cells proliferated in and around the part where the pancreas showed inflammatory changes and, one week after, the greater omentum was histologically connected with the part of the lesion, revealing its healing. However, in the distal part, substitution by the connective tissue further proceeded owing to closure of the duct. One to 2 months later, the glandular tissue finally disappeared completely, the pancreas appearing as a rod and containing only the LANGERHANS' islets.

In other words, when the pancreas, particularly its duct, is injured, healing may be complete first after disappearance of the glandular tissue belonging to the traumatized duct unless fistula formation is present.

SUMMARY

Different kinds of mechanical lesions were applied directly to the pancreas and the subsequent changes and the process of healing were investigated. The results of the experiments were as followed:

(1). Among the different mechanical lesions, the course was quite favorable and healing took place readily, when the duct was not simultaneously injured.

(2). In case the duct was at the same time severed, the prognosis was very bad. Administration of food or medicaments which promote secretion of the pancreatic juice would aggravate the postoperative condition.

(3). In the case of severe lesion, extensive contusion in particular, transitory interruption or decrease of the secretion might be encountered, during which period the changes used to be mild. 24 hours after, however, the function of the secretion would recover and pronounced changes might occur if the opened duct remained untreated.

(4). When an external or internal fistula is not formed in case of lesion of the pancreas, particularly lesion of the duct, the glandular tissue of the distal part would disappear, resulting in healing.

REFERENCES

- 1) Archibald, E. Acute edema of pancreas: Clinical and experimental study, *Ann. Surg.*, **90**; 803, 1929. 2) Babkin, B. P. Die äussere Sekretion der Verdauungsdrüsen. 1928. 3) Baronofsky, I. R., Walten, W. and Noble, T. E. Occult injuries to the pancreas following splenectomy. *Surg.*, **29**; 852, 1951. 4) Brunschwig, A. The surgery of pancreatic tumors. 67-74. St. Lavis. C. V. Mosby. Co. 1942. 5) Clairmont, P. Injury of pancreas during and after resection of duodenum for ulcer. *Schweiz. med. Wschr.*, **53**, 301, 1923. 6) Coffey, R. T. Unusual features of acute pancreatic disease. *Ann. Surg.*, **135**; 715, 1952. 7) Crider, J. O. and Thomas, T. E. Secretion of pancreatic juice after cutting the extrinsic nerves. *Am. J. Physiol.* **141**; 730, 1944. 8) Dragstedt, L. R. and Haward, H. E. Pathogenesis of acute pancreatitis. *Arch. Surg.*, **28**; 239, 1934. 9) Dragstedt, L. R. Some Physiological problem in Surgery of the pancreas. **118**; 576, 1943. 10) Eilenberger, W. and Baum, H. Anatomie des Hundes Berlin. Verlag. von Paul. Parey. 1891. 11) Fujioka, Z. Acute traumatic pancreatitis. *Arch. Jap. Chir.*, **18**; 264, 1941. 12) Garré, C. Totaler Querriss des Pankreas durch Naht geheilt. *Beit. Klin. Chir.*, **46**; 233, 1904. 13) Gomori, G. Observation with different stains on human islets of Langerhans. *Am. J. Physiol.* **17**; 395, 1941. 14) Greengart, H., Grossman, M. I. and Ivy, A. C. The effect of dietary composition on pancreatic enzyme. *Am. J. Physiol.* **138**, 676, 1943. 15) Guleke, N. Ueber die experimentelle Pankreasnekrosen und die Todesursache bei akuten Pankreaserkrankungen. *Eugeb. chir. orth.* **78**; 845, 1906. 16) Kubota, T. Prognosis and treatment of the total rupture of the pancreas experimental study. *J. J. S. S.* **25**; 1383, 1915. (Japan). 17) Lehrnbecher, A. Ueber isolierte subkutane Pankreasruptur. *Brun. Beitr.*, **132**; 560, 1924. 18) Lium, R. and Madock, S. Etiology of acute pancreatitis. *Surg.* **24**; 593, 1948. 19) Michael Radakovich, Pearse, H. E. and Stain, W. H. Study of the etiology of acute pancreatitis. *Surg. Gynec. & Obst.* **94** ä 749, 1952. 20) McDonald, M. R. and Kunits, M. The effect of calcium and other ions on the autocatalytic formation of trypsin from trypsinogen. *J. Gen. Physiol.* **25**; 53, 1941. 21) Nakagawa, Y. A clinical case of the traumatic pancreatitis. *OKAYAMA. I. Z.* **153**; 1955, 1941. (Japan). 22) Northrop, J. H. and Kunitz, M. Crystalline trypsin. Experimental procedure and method of measuring activity. *J. Gen. Physiol.* **16**; 313, 1932. 23) Nost-Kolb, A. Isolierte subkutane Pankreasruptur. *Brun. Beitr.*, **127**; 462, 1922. 24) Okamoto, S. Etiology of acute pancreas-necrosis. An experimental study. *OKAYAMA. I. Z.* **55**; 377, 1943. 25) Pavlov, J. P. Die Arbeit der Verdauungsorganen. 1893. 26) Polya, E. Ueber die Pathogenese der akuten Pankreaserkankungen. *Mitteil. Grenzgeb. Med. und Chir.*, **24**; 1, 1912. 27) Popper, H. L. Consequences of section of the pancreatic duct. An experimental study. *Surg. Gynec. & Obst.*, **88**; 254, 1949. 28) Popper, H. L. Trauma of the Pancreas. Experimental study. *Am. J. Digest. Disease.* **16**; 343, 1949. 29) Popper, H. L. and Necheles, H. Transition of pancreatic edema into pancreatic necrosis. *Proc. Central. Soc. clin. Res.*, **20**; 65, 1947. 30) Popper, H. L. and Necheles, H. A fatnecrosis produced by pancreatic duct and duodenal mucosa. *Proc. Soc. exp. biol. & med.*, **76**; 277, 1951. 31) Popper, H. L. and Necheles, H. Pancreatic injuries. An experimental study. *Surg. Gynec. & Obst.*, **193**; 621, 1951. 32) Popper, H. L. and Necheles, H. transition of pancreatic edema into pancreatic necrosis. *Surg. Gynec. & Obst.*, **87**; 79, 1948. 33) Ri, S. An experimental study of the pancreatic sutures. *Chiba. IGK. Z.* **11**; 212, 1933. 34) Routley, E. F., Man. F. C. and Bollman, L. Effect of vagotomy on pancreatic secretion in dog with chronic pancreatic fistula. *Surg. Gynec. & Obst.*, **95**; 529, 1952. 35) Schaffar-zich, W. R., Feran, H. H. and McCleery, R. S. A study of the effect of vagotomy on experimental pancreatitis. *Surg. Gynec. & Obst.*, **93**; 9, 1951. 36) Schmieden, V. and Sebening, W. Surgery of pancreas with special consideration of acute pancreatic necrosis. *Surg. Gynec. & Obst.* **46**: 735, 1928. 37) Sprengell, R. Klinisch-anatomisch-histologische Untersuchungen an ausgeheilten Pankreasfettgeweben- nekrosen. *Beitr. Z. Klin. Chir.*, **140**; 117, 1927.

- 38) Sugiyama, Y. A case of subcutaneous rupture of the pancreas. *J. J. S. S.* **38**; 1167, 1941. 39) Sen, B. An experimental study of prognosis and therapy on total pancreatic ruptures. *Chiba. IGK. Z* **20**; 1852, 1942. (Japan). 40) Thomas, T. E. and Komarov, S. A. Physiological aspect of vagotomy. *Gastroenterology.* **11**; 413, 1948. 41) Thomas, J. E. and Crider, J. O. The pancreatic secretagogue action of products of protein digestion. *A.m. J. Physiol.* **134**; 656, 1941. 42) Warren, K. W. Acute pancreatitis and pancreatic injuries following subtotal gastrectomy. *Surg.*, **29**; 643, 1951. 43) Walzel, P. Resection of Pancreas to surgical intervention on neighboring organ. *Arch. f. klin. Chir.*, **137**; 512, 1925. 44) Wangensteen, O. H. Technical suggestion in the performance of total gastrectomy. *Surg.*, **25**; 5, 1949. 45) Wangensteen, O. H. Discussion on use of "Suction-Tip" drainage of peritoneal cavity. *Gastroenterology.* **17**; 777, 1950.

PERT II. EXPERIMENTAL STUDY ON THE TREATMENT OF CUT-END OF SECTIONED PANCREAS.

Several operative methods for treatment of the cut-ends of the rest of the pancreas have hitherto been reported, which either underwent resection of its head in case of a malignant tumor of the head or in the distal portion of the common bile duct, or transection of the body of the pancreas in case of a malignant tumor in the corresponding part. For preservation of external secretion and prevention from formation of external pancreatic fistula, it is the method of choice to make a pancreatoenterostomy, should this procedure be possible.

The great majority of malignant tumor of the head of the pancreas are cancers derived from the epithelium of the pancreatic duct which, as the tumor grows, falls in a stricture, resulting in stagnation of pancreatic juice. Consequently, the cells capable of external pancreatic secretion are compressed and atrophied by the connective tissue proliferation so that external secretion can no longer be expected even by pancreatoenterostomy. On treatment of the distal end of the pancreas after transection, BRUNSWIG, CATTELL, HONJO and YOSHIOKA studied both clinically and experimentally. Concerning treatment of the duodenal cut-end of the pancreas, BRUNSWIG and CATTELL likewise published their own methods of the operation, which, however, are considered, from the viewpoint of direction of the flow of pancreatic juice, not so important as compared with the treatment of the distal cut-end.

Along with remarkable progress in surgery of the pancreas in recent years in JAPAN, various papers dealing with treatment of the cut-end of the transectioned pancreas have been published. They are, however, largely reports of clinical cases, in a great number of which a massligation only was done. As, in some of those cases reported, postoperative complication of fistula or cyst formation was found to have developed, treatment of the duodenal cut-end should be accomplished with much caution, as will be described below. The auther has carried out a series of experiments and investigated concerning treatment of the cut-ends of the pancreas after its resection.

METHODS OF EXPERIMENTS.

The following experiments were done under the same condition as those descr-

ibed in the Part I.

(I) Treatment of the Distal Cut-end of the Transected Pancreas.

a) Non-treated Cut-end. (Shown in Table III in Part I)

It was the routine procedure that the pancreatic duct in the duodenal cut-end was ligated with silk suture. This procedure seemed to be complete, and sufficient, as will be shown in the later experiments.

A transverse resection, 0.5cm in length, was made, avoiding injury to the visible vessels as far as possible, in the tail of the pancreas, where the pancreatic duct is not yet bifurcated into the main and accessory ones. The distal cut-end of the pancreas was not treated in any way.

Autopsy done 24 to 48 hours thereafter revealed 10 cc hemorrhagic fluid in the intraperitoneal cavity in 2 cases, in both of which patches of fatty necrosis were evident.

The pancreas distal to the resection appeared edematous and necrosis and hemorrhages were found at the cut-end.

In one week cases, that is, in the cases in which autopsy was made one week after the experimental resection of the pancreas, the greater omentum was seen to be adhered organically to the cut ends and sclerosis of the lobules tended to occur. Histologically, immature connective tissue cells infiltrated in the parenchymal cells which were compressed and atrophied.

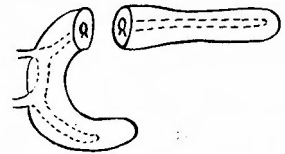
In 2 months cases such changes as mentioned above were so proceeded that the pancreas apparently became a yellowish brown rod. At this stage, histological examination showed that the parenchymal cells completely disappeared and only LANGERHANS' islets were to be found remaining in the connective tissue.

b) Ligation of the Pancreatic Duct (Table b)

After the transverse resection as described in the afore-mentioned Experiment a, the pancreatic duct in the distal cut-end was ligated with silk suture. Hemorrhages, if present, were preferably controlled by pressure tamponade but not by suture.

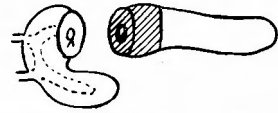48 hours later, autopsy showed no ascites nor fat necrosis and the greater

Table. (b) Ligation of the Pancreatic Duct.



Dog. No.	Postop. period	Mode of death	Ascites	Fat necrosis	Formation of oyst or fistula
38	48 h.	killed	(-)	(-)	(-) (-)
39	48 h.	killed	(-)	(-)	(-) (-)
40	72 h.	killed	(-)	(-)	(-) (-)
41	I w.	killed	(-)	(-)	(-) (-)

Table. (c) Crushing of the Cut-end



Dog No.	Postop. period	Mode of death	Ascites	Fat necrosis	Formation of cyst or fistula
47	48 h.	killed	(-)	(±)	(-)
48	48 h.	killed	(-)	(-)	(-)
49	72 h.	killed	(-)	(-)	(-)
50	I w.	killed	(-)	(-)	(-)

omentum was seen to adhered to the cut-ends fibrously. Hemorrhages, necrosis and edema at the cut-ends of the pancreas were seen only minimally. In general, inflammatory process was quite inconspicuous and histologically no change other than appearance in the distal part of immature connective tissue cells were observed.

In 72 hours cases, adhesion of the greater omentum became more compact and the distal part of the pancreas was coarsely surfaced and more hard in consistency, showing sclerosis of the lobules. Histologically, an increasing number of immature interstitial cells were seen to infiltrate in the parenchyma, the lobules being compressed from the surrounding, and the glandular cells to show morphological changes. In same cases, enlargement of the lumen of the pancreatic duct might be recognized but abnormality like rupture of the wall of the duct was absent entirely.

One week after, the cut-ends were firmly connected with the omentum, showing histologically a healing. Substitution of the parenchymatous tissue in the distal part by interstitium was more quickly done than that in the former Experiments (Fig. 7).

c) Crushing of the Cut-end (Table c).

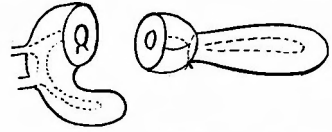
Transection was made as in the Experiment a, and the pancreatic duct at the distal cut-end was not ligated but, instead, the end, 1 cm long and throughout the entire layers, was crushed with a KOCHER'S forceps.

Autopsy done 48 hours later revealed a few patches of fat necrosis in one case but in the other case was there observed neither fatty necrosis nor ascites. Little changes were seen in the distal part, that is, infiltration of few inflammatory cells and negligible invasion of immature connective tissue cells (Fig. 8). At the part severed, necrosis, hemorrhages and edema were more prominent than those seen in the Experiments a and b.

In 72 hours cases, inflammatory changes could be evidenced around the cut-end and immature connective tissue cells appeared in the surrounding of the necrotic tissue. Derangement of the glandular tissue of the distal portion was somewhat retarded if compared with that of Experiment b.

In one week case, adhesion of the greater omentum to the surrounding part of the cut end became organized and the surface of the pancreas appeared rough. Histologically, process of connective tissue proliferation was advancing, yet retarded

Table. (d) Mass-ligation of the Cut-end



Dog No.	Postop. period	Mode of death	Ascites	Fat necrosis	Formation of cyst or fistula
42	24 h.	killed	20 cc. hemorrhagic	(#)	abscess (-)
43	48 h.	killed	20 cc. hemorrhagic	(#)	abscess (-)
44	6 days	killed	little	(#)	abscess (-)
45	7 days	killed	50 cc. hemorrhagic	(##)	abscess (-)
46	8 days	killed	50 cc. hemorrhagic	(##)	cyst (-)

when compared with that in Experiment b.

d) Mass Ligation of the Cut-end (Table d).


Transection was made in the same part as in the Experiment a. A mass ligation was made with silk suture at a distance of 0.5 cm from the cut-end, the duct being not ligated separately. As this mass ligation occluded the duct and, at the same time, the blood flow, the cut-end proximal to the ligation became pale instantly. Autopsical findings in the 24 hours cases were 20 cc of hemorrhagic ascites, numerous fatty necrosis, autolysis of the cut-end proximal to the mass ligation and opening of the duct at a newly established surface.

The pancreatic tissue distal to the mass ligation appeared remarkably edematous and infiltration of inflammatory cells were evident histologically.

In 48 hours cases, the changes mentioned above became more pronounced, the greater omentum covered the cut-end, and an abscess was formed around the dissolved pancreatic tissue.

In 6, 7 or 8 days cases, hemorrhagic ascites, 30 cc. in average, advanced fatty necrosis and abscess formation were discovered. At this stage, the pancreas showed a tendency of sclerosis of the lobules. Histologically, inflammatory cells, such as leucocytes and round cells, were still observable and connective tissue was proliferating in the parenchyma. The reason for the abnormally severe autopsical findings as shown in the foregoing may be explained by that the pancreatic duct became opened on the newly established surface resulted from autolysis of the part proximal to the mass ligation. For confirming this hypothetical interpretation, the following experiment was done: An aseptically removed liver and pancreas were placed on a distilled disk which were preserved with a constant temperature of 37 degree C. They were put on the gauze wet with physiologic saline solution to prevent from dryness. The cut piece of the pancreas became deformed 24 hours after and completely dissolved 48 hours after. The liver, on the other hand, decreased its size while increasing its consistency. The difference may be due to the presence of proteolytic ferments in the pancreatic tissue which cause autolysis of the tissue itself.

Table. (e) Ligation of the Pancreatic Duct and 2-3 Sutures



Dog No.	Postop. period	Mode of death	Ascites	Fat necrosis	Formation of cyst or fistula
64	48 h.	killed	(-)	(-)	(-) (-)
65	48 h.	killed	(-)	(-)	(-) (-)
66	72 h.	killed	(-)	(-)	(-) (-)
67	I w.	killed	(-)	(-)	(-) (-)

Table. 2-a Non-Treated Cut-end (Tail was resected)



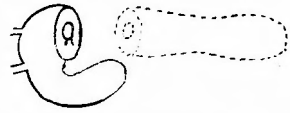
Dog No.	Postop. period	Mode of death	Ascites	Fat necrosis	Formation of cyst or fistula
51	48 h.	killed	(+)	(+)	(-) (-)
52	48 h.	killed	(-)	(+)	(-) (-)
53	48 h.	killed	(-)	(+)	(-) (-)
54	72 h.	killed	(-)	(+)	(-) (-)

e) Ligation of the Pancreatic Duct and 2-3 Sutures (Table e).

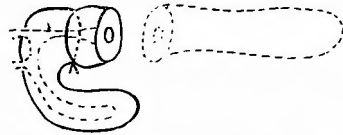
Transsection was made at the same part as in the Experiment a and the pancreatic duct was immediately ligated. For prevention from leakage of the pancreatic juice out of the cut surface, 2-3 additional sutures were supplemented so that the duct was covered thereby.

Autopsy performed 48 hours later disclosed none of the ascites or fatty necrosis but edema and necrosis around the cut end which were more pronounced than those seen in the Experiment b. The changes in the peripheral part were slight edema, nearly the same in degree as in the Experiment b, and appearance of immature connective tissue cells. In 72 hours cases, the necropsical findings were similar to those of the Experiment b. Histologically, proliferation of the connective tissue and atrophy of the parenchyma were seen to commence. However, Necrosis of the cut end was conspicuous. In one week's cases, the greater omentum was organically united with the cut end and the distal part showed sclerosis of the lobules (Fig. 9), reducing its size as in the Experiment b. In summarising, the results and the course were not much different from those of b, though necrosis at the cut end was somewhat more marked.

(II) Treatment of the Duodenal (proximal) Cut-end of the transected

Table 2-b Ligation of the Pancreatic Duct.

Dog No.	Postop. period	Mode of death	Ascites	Fat necrosis	Formation of cyst or fistula
72	48 h.	killed	(-)	(-)	(-) (-)
73	48 h.	killed	(-)	(-)	(-) (-)
74	72 h.	killed	(-)	(-)	(-) (-)
75	I w.	killed	(-)	(-)	(-) (-)

Table 2-c Mass-ligation

Dog No.	Postop. period	Mode of death	Ascites	Fat necrosis	Formation of cyst or fistula
55	48 h.	killed	(-)	(+)	Abscess (-)
56	48 h.	killed	(+)	(+)	Abscess (-)
57	72 h.	killed	(-)	(+)	Abscess (-)
58	I w.	killed	(-)	(+)	Abscess (-)

Pancreas.

The same transection as done in the Experiment (I) was made and the pancreas distal to the section, or the tail, was removed.

a) Non-treated Cut-end. (Table 2-a)

After the transection, the duodenal cut-end was left untouched. The bleeding could sufficiently be controlled by tamponade. Autopsy done 48 hours after revealed 5 cc of ascites and a few patches of fatty necrosis on the greater omentum, and the wall of the intestinal tract near the cut-end. On the cut-end, the greater omentum was seen to loosely adhere fibrously and there were necrosis and edema. Histologic examination disclosed that inflammatory cells had infiltrated. In 72 hours cases, ascites was no longer present but patches of fatty necrosis and immature connective tissue cells were to be observed.

b) Ligation of the Pancreatic Duct (Table 2-b)

Transection was made in the same part as in the Experiment a and the pancreatic duct on the duodenal cut-end was immediately ligated, avoiding any additional lesions.

Autopsy done 48 hours later disclosed in all the cases that patches of fatty necrosis were entirely absent but slight inflammatory changes were present on the cut-end. The autopsical findings obtained 72 hours after were much resembling, i,

e., adhesion of the greater omentum to the cut end, inflammatory changes, and initial appearance of immature connective tissue cells under microscopic observation. In one week's cases, the greater omentum was organically united with the cut-end, the inflammatory changes were subsiding, the cut-end showed a complete healing histologically and inflammatory cells were almost disappearing. Immature connective tissue cells were still more or less proliferating but these cells were not found in the part away from the cut-end.

c) Mass Ligation (Table 2-c)

Transection was made in the same part as in the Experiment a. Mass ligation was done at the point 0.5 cm apart from the cut-end of the duodenal side of the pancreas. 48 hours later, autopsy revealed 5.0cc of ascites, patches of fatty necrosis of moderate degree in all the cases and fibrous adhesion of the greater omentum to the cut-end. The part distal to the mass ligation, however, showed autolysis and a newly established surface, on which the pancreatic duct was seen to open. And owing to the autolysis of the pancreatic tissue and flowing back of the pancreatic juice the changes seemed to have doubtless aggravated. The part distant from the cut-end showed no such prominent changes. Histologically, edema and necrosis were slightly more marked than those observed in the Experiment a and b. Invasion of the connective tissue cells was restricted in the wound and the glandular tissue in the distant part was normal at all.

(III) Pancreoenterostomy.

The operative method of pancreoenterostomy was in resemblance with that of entero-enterostomy in general. When the pancreatic duct was abnormally dilated, anastomosis between the duct and the intestinal tract may be carried out.

It has, however, not been made clear if the pancreas which underwent a pancreoenterostomy actually preserve the function of the external secretion or not. For clarifying this point, the author has accomplished several different methods of pancreoenterostomy.

In this experimental pancreoenterostomy in dogs, the tail of the pancreas was used for the anastomosis, so that the procedure may simulate and be reproduced in men. In this case, the pancreas being anastomosed may possibly lose its function, become sclerosed and atrophied, as the pancreatic duct on the side of the normal pancreas is opened in the intestinal tract. In order to avoid this possibility, the pancreas other than the part to be used for the anastomosis is free from the intestinal tract and then, the opened ends of the duct are ligated and the greater omentum is interposed between them, interrupting any connection with the tract. The pancreas of a dog is far more friable as contrasted with that of a man and readily crushed by mere finger pressure. It is, therefore, conceivable that too many sutures at pancreoenterostomy in dogs would easily cause necrosis of the pancreas where the anastomosis was placed, resulting in insufficiency of the anastomosis, which together with exposure intraperitoneally of mucosae of the small intestine were observed in most of the non-survived cases. Consequently, circular excision of the mucosa of the small intestine to be anastomosed was first made, the bleeding vessels ligated,

then the pancreas inserted in that intestine and one layer sutures were made between the capsule of the pancreas and the intestinal tract, thus completing the anastomosis. The small intestine to be anastomosed was divided at the point some 10 cm anal to the flexura duodenojejunalis. The in-coming loop was made so that it was 10 cm in length away from the Roux's anastomosis. In that way, contamination of the pancreas with the content of the intestinal tract could be avoided as far as possible.

The experimental dogs were killed for necropsy a certain period after. The intraperitoneal changes were carefully observed and microscopic specimens of the pancreas were made.

Anastomosis (I). Mass Ligation and Anastomosis of the Proximal Portion of the Pancreas.

Transection was made at the tail of the pancreas and the anastomosis was performed between the distal pancreas and the small intestine, after mass ligation was placed at the part 1 cm distant from the cut-end of the pancreas.

Autopsical and histological findings: In case No. I autopsy was performed on the 4th postoperative day which showed that the greater omentum and the intestinal tract adhered to the part of the anastomosis and to each other, covering that part. When the adhesion was bluntly separated, abscess was uncovered and the ligated tip disappeared completely, the cut end of the anastomosed small intestine being opened therein. The pancreas, on the other hand, was adhered to the wall of the abscess, revealing unpurposed and unsuccessful anastomosis. The distal part of the pancreas anastomosed swelled edematously and histological examination disclosed infiltration of inflammatory cells and edema.

Cases No. 2 and 3 were killed for necropsy 6 and 7 days, respectively, after the experimental operation. The pancreas in both cases was at the first glance revealed an successful pancreatoenterostomy. After loosening of the omentum and the conglomerated small intestine, however, it was found to adhere to the wall of the intestine other than that anastomosed, that is to say, the anastomosis failed. Histologically, the peripheral part of the pancreas anastomosed showed derangement of the lobules as the result of invasion of connective tissue cells. Besides, inflammatory cells had also infiltrated, though only a few.

Anastomosis (II). Mass Ligation and Anastomosis of the Distal Portion of the Pancreas.

After transection the cut-end which was mass-ligated with silk sutures was inserted into the lumen of the small intestine and the anastomosis was made at the part more distal to the ligation. Such procedure was done for controlling the hemorrhages from the cut-end and for preventing leakage of the pancreatic juice, expecting that the tip of the pancreas would fall in autolysis 24 to 48 hours after and the pancreatic duct out-opens on this newly established surface. 2 to 3 days after, 2 of the experimental dogs excreted black-coloured feces, which gradually changed to normal tinged one in one week. The observed findings might be the result of bleeding successive to the autolysis.

Necropsical and Histological Findings: The autopsy done 32 days later revealed, in all the 6 cases, successful anastomosis. Adhesion at the part of the patent anastomosis was either quite slight or none. The anastomosed pancreas showed that in 2 cases there was slight infiltration of inflammatory cells and moderate substitution by the connective tissue in the pancreatic tissue which projected into the intestinal lumen. In the more distal part such changes were absent and the lobules and the duct likewise showed no abnormality. In other 4 cases, there were no findings to be mentioned, suggesting that function of the external secretion was well preserved. (Fig 10)

Anastomosis (III). Anastomosis after Cauterisation of the Cut-end of the pancreas with Paquelin.

After transection, the bleeding from the cut-end was controlled by cauterisation with Paquelin. After secured hemostasis, the cut-end was anastomosed to the small intestine. One of the 5 cases treated in such way continued to excrete black-coloured feces, which was confirmed to be due to formation of peptic gastric ulcer. In the remaining 4 cases excretion of black-coloured feces was not observed.

Autopsical and Histological Findings: The autopsy made about one month after showed that in all the cases in this series the anastomosis was patent, devoiding of any adhesion to the surrounding. The anastomosed pancreas was also normal in appearance.

In the only one case which excreted black tinged feces, there were several ulcers, the size of a rice grain, on the stomach but no other changes worthy of note. Histologically, the pancreatic tissue inside the small intestine was covered with its mucosa, the duct being opened. In some parts, there was infiltration of inflammatory cells and scar tissue. In one case, slight proliferation of the connective tissue was found, although invasion of the inflammatory cells was absent in the pancreas distal to the anastomosis and no abnormalities in the glandular tissue, the duct and the LANGERHANS' islets (Fig. 11 and 12).

The pancreatic duct on the cut-surface underwent cauterisation also became patent as the function of the external secretion recovered, and the pancreatic juice seemed to flow normally through the duct.

Anastomosis (IV). Anastomosis between the Pancreas, the Duct of which was ligated, and the Intestine.

It may happen that the pancreatic duct is inattentively ligated at the time when ligatures of the bleeding vessels on the cut-end are made after the transection and the removal of the head. When the duct is obviously dilated, such a failure as to ligate the duct would hardly occur, but when the duct is not yet dilated, it would undoubtedly be very difficult to identify the duct, giving rise to unawared ligation of the duct. The result will be that the anastomosed pancreas become interstitially sclerosed and atrophied and function of normal external secretion can not be expected, as has been said in the item, ligation of the pancreatic duct.

After the transection, the duct and the bleeding vessels as well were looked for and ligated with silk sutures and then the anastomosis was carried out. The pos-

toperative course was uneventful and there was no case in which excretion of black tinged feces was observed. Anorexia would recover usually in one week but the stools excreted increase the amount and reduce the consistency.

Necropsical and Histological Findings: Autopsy performed about I month after the opetraion showed that the anastomosis between the pancreas and the intestinal tract was grossly patent and adhesion to the surrounding or other abnormality were absent. However, the pancreas was generally sclerosed and atrophied, markedly reducing its size. Histologically, the pancreas inside the intestinal tract was covered by the mucosa, although the glandular tissue had almost entirely disappeared. (Fig. 13, 14)

COMMENT

As described above, several different operative methods were used for treatment of the cut-end after removal of the head of the pancreas or its transection, the superiority of the method was compared with each other. It is needless to say that in the case of transection of the pancreas the tail of the pancreas should be removed if time allows and there is sufficiently enough pancreatic tissue in the duodenal side.

However, in case there are severe adhesion to the surrounding at the transection and removal of the tail is improbable, or in case of a cancer of the head or in the region of the VATER's papilla, the tail must be left untouched and not removed. In the latter cases, a pancreatoenterostomy should be done from the viewpoint of digestion and absorption, when the rest of the pancreas is presumed to have normal function of external secretion. When sclerosis and atrophy of the tail is pronounced, it is thought that a pancreato-enterostomy is not always necessary. Concerning treatment of the cut-end without a pancreato-enterostomy, the three methods which follow are for the present in use.

- 1) Mass Ligation.
- 2) Ligation of the Duct.
- 3) 2) plus Interrupted Mattress Sutures.

A Comparatively large number of successful cases of mass ligation have recently been reported in this country. In some of these cases, postoperative formation of cyst or fistula was found. As shown in the results of Experiment (1) d, it is thought to be due to that the ligated tip falls into necrosis causing insufficiency of the cut-end.

In the Experiment (1) c, the cut-end, 2 cm in length and throughout all the layers, was crushed with KOCHER's forceps, but then resaltant intraabdominal chages were little and the inflammatory changes of the distal pancreatic tissue were also inconspicuous. This fact was, as already pointed out in the experimental study on traumatic lesion of the pancreas, due to postoperative reduction in secretion of the pancreatic juice and prompt adhesion of the greater omentum and intestinal tracts to the part of the lesion, preventing leakage of the juice intraabdominally.

In regard to the operative method, successful clinical cases were published by

BRUNSCHWIG and CATTELL. YOSHIOKA also contributed there-to with a similar operative method. In all of them, it was recommended that mattress sutures should be added to ligation of the duct for the purpose of preventing leakage of the pancreatic juice or bleeding out of the cut surface.

In the Experiment (I) e, in which the operative method simulated the above-ones, autopsy performed 48 hours after revealed abnormally severe lesion of the cut-end treated and somewhat more conspicuous edema on the side of the tail. The results were apparently less superior if contrasted with those of the Experiment (I) b, in which ligation of the duct and hemostasis of the bleeding vessels only were carried out. However, the findings in the Experiment (I) e obtained one week later also showed that inflammatory changes of the part of the ligation at the cut-end were disappearing and the pancreatic tissue in the periphery was substituted by connective tissue, manifesting the course of healing.

Regarding the treatment of the cut-end of the duodenal side of the sectioned pancreas, BRUNCHWIN, and CATTELL have also published their own methods. They said in this connection that a mere mass ligation would be sufficient because the intraductal pressure is ordinarily low. But as shown by the results of the Experiment (II) c, the part underwent mass ligation may be necrotized, the duct opened on the newly established surface and fatty necrosis ensued owing to back flow of the pancreatic juice as in the cases of Experiment (II) a. A mass ligation with additional mattress sutures has also been reported, in which case, however, there is a possibility that the cut-end becomes necrotic, as shown in the Experiment (I) c. Mere ligation of the duct showed the most favorable results. Consequently, at treatment of the cut-end after transection of the pancreas in man, it should therefore be avoided to place too many sutures and unnecessary lesions.

In the experiments of pancreato-enterostomy, what kind of operative methods can best keep the function of the pancreas in its normal condition was studied with the histologic specimens.

As illustrated in the Fig 15, the normal pancreas is subdivided in glandular lobules by thin connective tissues and the individual glandular cells has a thin interstitial membrane at the base. The cell body is nearly triangular in form, has a round nucleus and contain secretory granules which are visible by MARONEY'S modification of HEIDENHEIN'S stain. The pancreatic ducts differ each other in size but the epithelium is rectangular-formed and arranged in one layer. Should the function of external secretion of the cells be interrupted as by ligation of the duct, connective tissue cells begins to proliferate in 24 hours, surrounding the glandular cells, causing derangement, the glandular cells being deformed and atrophied, all of which finally will disappear, the pancreas becoming a connective tissue rod and LANGERHANS' islets only remain. It is, accordingly, possible to judge by the histological findings whether the function of external secretion of the anastomosed pancreas is preserved or not. In the experimental dogs, this was examined by autopsy done usually about one month after the operation.

In anastomosis (I), autopsy was performed on the 4, 5 and 8 th postoperative

day, respectively, for early examination. In all the cases, the anastomosis was not successful. In anastomosis (IV), in which the duct was ligated, all the 4 cases revealed histologically complete disappearance of cells capable of external secretion.

In 2 cases with anastomosis (II) and in one case with anastomosis (III), slight proliferation of connective tissue was observed in the distal pancreas. But, in other cases, glandular tissue appeared wholly normal and the operation was considered satisfactory.

Poth was the first who, made an anastomosis between the pancreatic duct and the intestinal tract when the former was abnormally dilated in the case of a cancer of the head of the pancreas. YOSHIOKA performed the anastomosis with insertion of a small-sized metallic canule into the duct. These methods seem to have been accomplished in the aim to keep the duct widely opened, rendering no influence on the glandular tissue by stasis of the pancreatic juice. Such methods, however, seem to be not available in the case of normal pancreas or a cancer in the beginning stage when the pancreatic duct is not yet dilated. In such cases, (II) and (III) should be made, as the procedures are more simple and less harmful to the pancreatic tissue. It should be avoided to search for the duct and thus traumatized the pancreatic tissue.

SUMMARY AND CONCLUSIONS

Several different methods were used in treatment of the cut-end at transection of the pancreas and what kind of method is suitable was experimentally studied. The following were the results.

- 1) When a pancreateo-enterostomy is not done, it is the method of choice only to make ligation of the pancreatic duct both on the duodenal and distal cut-end.
- 2) Ligation of the duct with additional 2 to 3 mattress sutures will cause rather marked necrosis of the corresponding part. Healing process of the peripheral part, however, is as favorable as in the case of mere ligation of the duct.
- 3) Mass ligation may occasionally give rise to formation of fistula or cyst, as the result of autolysis of the ligated tip of the pancreas.
- 4) When the pancreatic duct is not dilated, it seems to be impossible to anastomose the duct with an intestinal tract. For anastomosis between the cut-end of the pancreas and intestine, the anastomosis (II) and (III) may be of simplicity and safe in view of postoperative preservation of the function of external secretion.

REFERENCES

- 1) Bartlett, M. K. The status of pancreatoduodenectomy. *Surg. Clin. North. Ameri.*, **27**; 1032, 1947.
- 2) Brunschwig, A. Resection of head of pancreas and duodenum for carcinoma. *Surg. gynecol. and Obst.*, **65**, 681, 1937.
- 3) Brunschwig, A. Radical surgery in advanced abdominal cancer. Co. University of Chicago. 181-215, 1945.
- 4) Cattell, R. B. Resection of the pancreas: Discussion of special problem. *Surg. Clin. North. Ameri.*, **23**, 733, 1943.
- 5) Cattell, R. B. Anastomosis of the duct of Wirsung. Its use in palliative operation for cancer of the head of the pancreas. *Surg. Clin. North. Ameri.*, **27**; 761, 1948.
- 6) Cattell, R. B. A technic for pancreatoduodenostomy. *Surg. Clin. North. Ameri.*, **28**; 761, 1948.
- 7) Cattell, R.

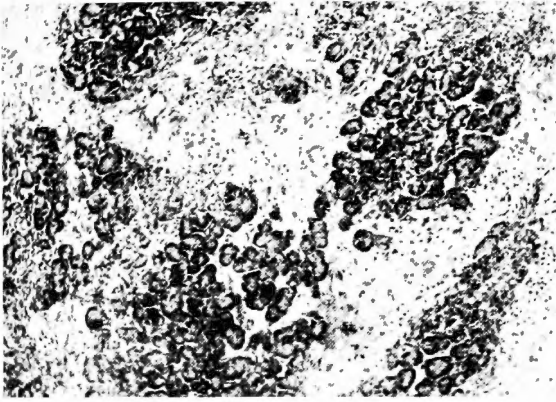


Fig. 1

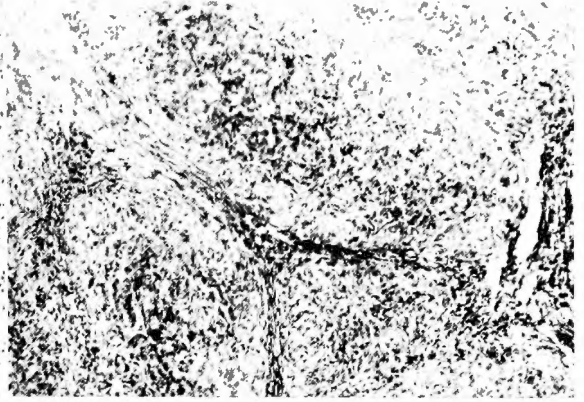


Fig. 2

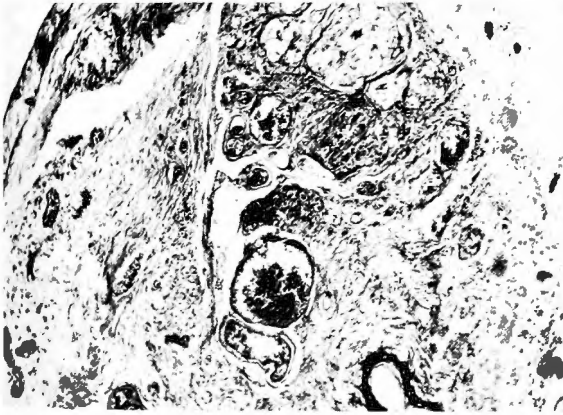


Fig. 3

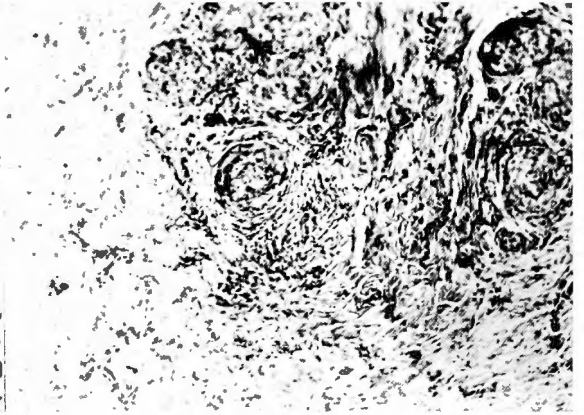


Fig. 4

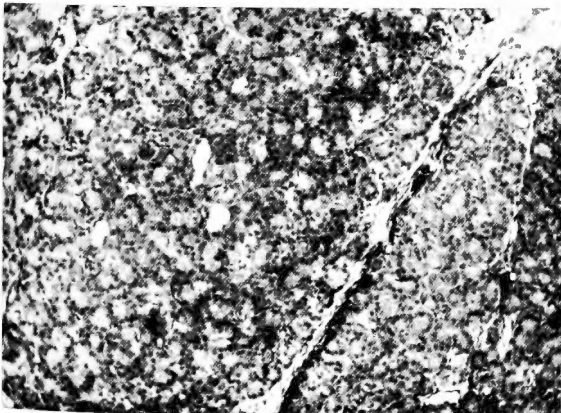


Fig. 5

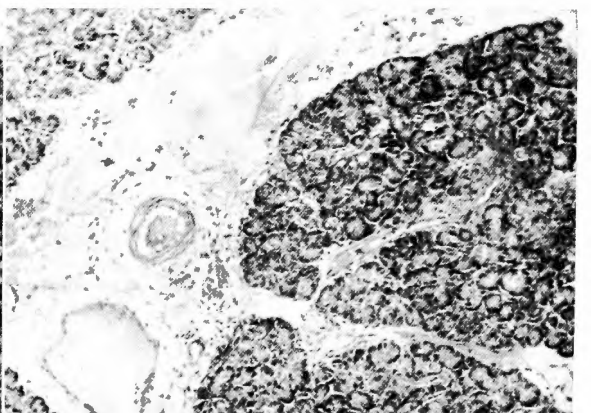


Fig. 6

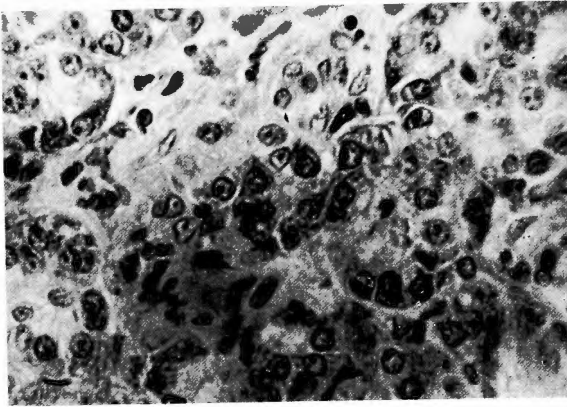


Fig. 7

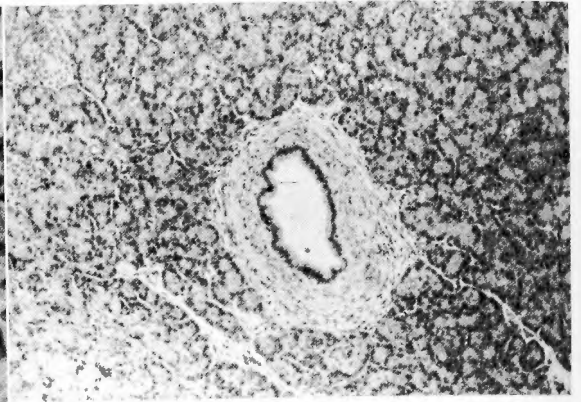


Fig. 8

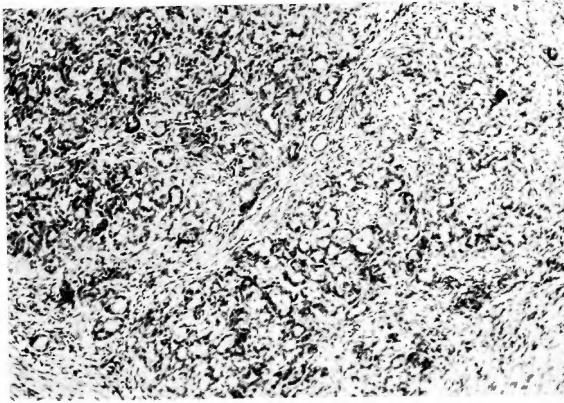


Fig. 9

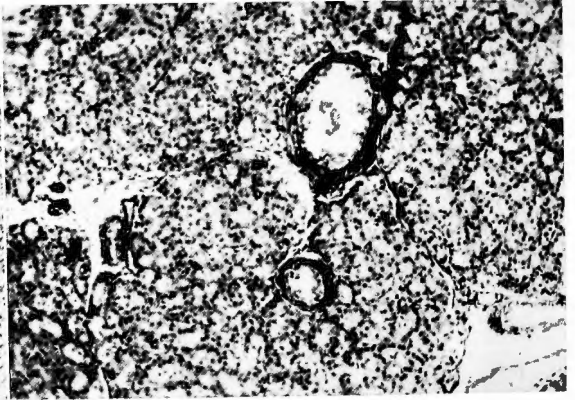


Fig. 10

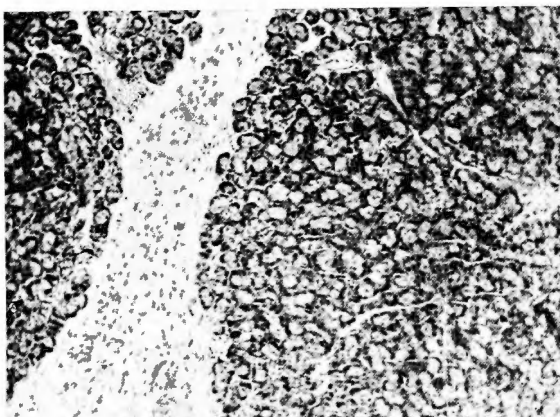


Fig. 11

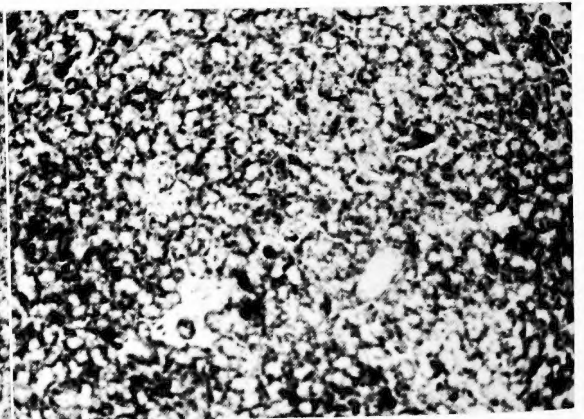


Fig. 12

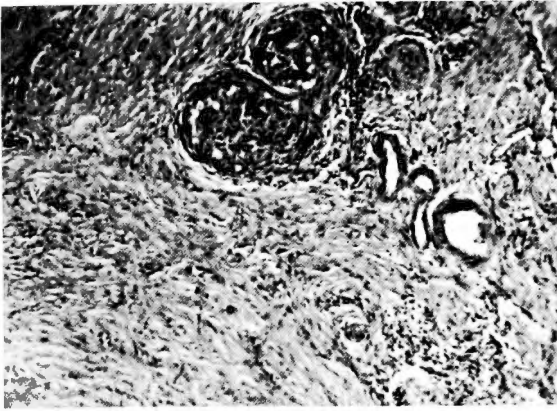

Fig. 13

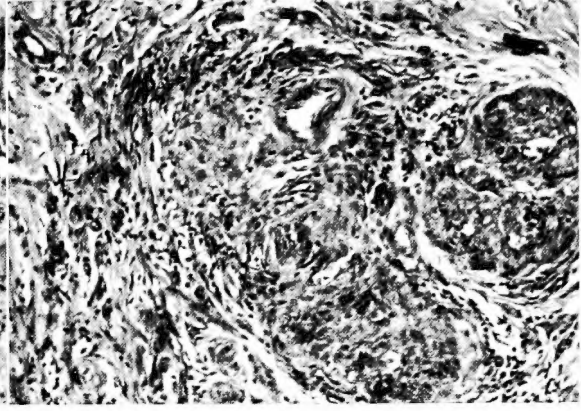


Fig. 14

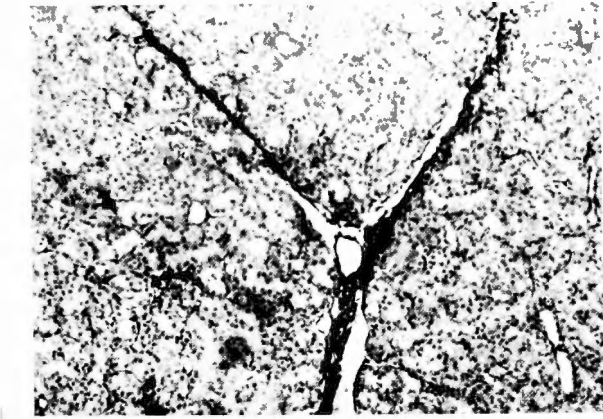


Fig. 15

- B. Partial pancreatectomy, excision of the tail and body of the pancreas. *Surg., Clin. North. Ameri.* **28**; 778, 1949. 8) Child, C. G. III. One-stage radical pancreatoduodenectomy. *Ann. Surg.*, **118**; 838, 1933. 9) Child, C. G. III. Pancreatoduodenectomy and other problem associated with the surgical management of carcinoma involving the head of the pancreas. *Ann. Surg.* **119**, 845, 1943. 10) Child, C. G. III. Radical one-stage pancreatectomy. *Surg.*, **23**, 492, 1948. 11) Davis, V. C. Experience in subtotal resection of the pancreas in hypoglycemia. *Ann. Surg.* **123**; 836, 1946. 12) Dragstedt, L. R. Some physiological problems in surgery of the pancreas. *Ann. Surg.* **118**; 576, 1943. 13) Fujioka, Z. A clinical case of traumatic pancreasnecrosis. *Arch. Jap. Chir.* **18**, 264, 1941. 14) Garré, C. Totaler Querriss des Pankreas durch Naht geheilt. *Beitr. Klin. Chir.* **46**, 233, 1904. 15) Honjo, I. Transection of the pancreas. *J. J. S. S.* **50**, 252, 1950 (Japan). 16) Hunt, V. C. Surgical management of carcinoma of the ampulla of Vater and the periampullary portion of the duodenum. *Ann. Surg.* **114**, 570, 1941. 17) Isawa, T. and Yabe, M. Treatment of the cut end of the pancreas. An experimental study. *J. J. S. S.* **54**; 517, 1954. 18) Katsura, S. and Suzuki, R. Resection of the head of the pancreas. *Shuzuts.* **8**, 97, 1954 (Japan). 19) Loggan, P. B. and L. T. Kleinsasser. Surgery of the pancreas; the results of pancreaticoduodenal resections reported in the literatures. *Surg. Gynec. & Obst.*, **93**, 521, 1951. 20) Mann, F. C. and Williamson, C. S. The experimental production of peptic ulcer. *Ann. Surg.* **77**, 409, 1923. 21) Miller, E. M., Dockerty, M. B., Wollager, E. E. and Waugh, J. M. Carcinoma in the region of the papilla of Vater. *Surg. Gynec. & Obst.* **92**: 172, 1951. 22) Nakagawa, Y. A clinical case of the traumatic pancreasnecrosis. *Okayama. I. Z.* **53**, 1955, 1941. 23) Ohno, R. Resection of the pancreas. *J. J. S. S.* **54**: 516, 1954. 24) Orr, T. G. Pancreatoduodenectomy for carcinoma of the ampulla and ampullary region. *Surg.*, **18**, 141, 1945. 25) Owens, F. M. The problem of peptic ulcer following pancreatectomy. *Ann. Surg.*, **128**, 15, 1948. 26) Pearse, H. E. A simplified anastomosis for resection of the duodenum and head of the pancreas. *Surg. Gynec. & Obst.*, **75**, 333, 1942. 27) Pearse, H. E. Should we standardize the reconstruction after pancreatoduodenectomy. *Surg.*, **20**; 663, 1946. 28) Poth, E. T. The implantation of pancreatic duct into the gastrointestinal tract. *Ann. Surg.*, **15**, 693, 1944. 29) Sugimura, Y. A case of subcutaneous rupture of the pancreas. *Seii. K. Z.* **59**, 1230, 1950. 30) Toda, H. Resection of the head of the pancreas. An experimental study. *J. J. S. S.* **50**, 251, 1950. 31) Waugh, J. M. Resection of the head of pancreas and duodenum. Operative technique. *Surg. Clin. North. Ameri.*, **26**, 941, 1946. 32) Waugh, J. M. and Clagett, O. T. Resection of the duodenum and head of the pancreas for carcinoma; An analysis of 30 cases. *Surg.*, **20**, 224, 1946. 33) Waugh, J. M. Radical resection of head of pancreas and total pancreatectomy. *J. A. M. A.* **2**; 137, 1948. 34) Whipple, A. O., Parsons, W. S. and Mullius, C. R. Treatment of carcinoma of ampulla of Vater. *Ann. Surg.*, **102**: 763, 1934. 35) Whipple, A. O. Radical surgery for certain cases of pancreatic fibrosis associated with calcareous deposit. *Ann. Surg.*, **124**, 911, 1946. 36) Willis, R. A. Pathology of tumors. Butterworth & Co. LTD. 1948. 37) Wollager, E. E., Comfert, M. W., Clagett, O. T. and Asterberg, A. E. Efficiency of gastrointestinal tract after resection of the head of pancreas. *J. A. M. A.* **137**, 838, 1948. 38) Yokota, H. and Kawamoto, M. transection of the pancreas. *J. J. S. S.* **50**, 254, 1950. 39) Yoshioka, H. Treatment of the cut end of the pancreas; An experimental study. *J. J. S. S.* **54**, 518, 1954. 40) Yoshioka, H. Resection of the pancreas. *J. J. S. S.* **54**, 517, 1954.

和 文 抄 録

膵損傷並に膵断端処置に関する実験的研究

京都大学医学部外科第一講座 (主任 荒木千里教授)

西 田 茂 樹

第一部 膵損傷実験に就て

膵に直接間接に損傷が加わり、其の礎放置されると、多くの場合急性腹膜炎を生ずる。この急性腹膜炎は膵液によつて生ずるもので膵液分泌に影響を与える。摂食、薬物の投与の有無、損傷の種類、程度で色々と相違する。此等の点を明にする為に直接正常犬の膵に、種々なる器械的損傷を加え、其の変化、治癒過程をしらべて次の結果を得た。

(1) 器械的損傷の中、膵管に損傷のないものは経過が甚だ良好で、容易に損傷部は治癒する。

(2) 膵管損傷のある場合は、予後甚だ不良で、膵液分泌を促進する食物、薬物投与は更に予後を重篤にする。

(3) 損傷、特に広範囲の挫減創の場合は、一時的に膵液分泌の停止乃至分泌量の減少がある。従つて、此の時期の変化は軽度であつても、24間時後やがて分泌機能が回復し、若し破損膵管が処置されない場合は、高度の変化を惹起するものと考えられる。

(4) 膵損傷、特に膵管損傷の場合、若し内外瘻がな

い場合は、末梢側の腺組織は完全に消失して治癒する。

第二部 膵断端処置に就て

膵断端処置に就ては、種々なる方法があるが、如何なる方法が適當であるか、膵腸吻合をも合せて実験的にしるべ、次の結果を得た。

(1) 膵腸吻合が不能な場合は、十二指腸側、尾側断端共に膵管結紮のみに止めたものが最も結果がよい。

(2) 膵管結紮に2~3の縫合を加える方法は、断端に多少とも壊死を來す。然し末梢側の治癒進行は膵管結紮单独の場合と等しい。

(3) 集束結紮は先端部の自家融解によつて瘻孔、囊腫を形成する。

(4) 膵管が拡張していない場合は、膵管腸吻合は不能である。此の場合は集束結紮をこえて末梢側で膵腸吻合を行うか、又は断端をバ克蘭で焼切して膵腸吻合を行う方法が、吻合膵の機能保存、吻合膵よりの出血がない為に優れた方法と考える。