

ELECTROMYOGRAPHIC STUDIES ON THE VISCERO-MOTOR REFLEXES

by

SEIZO KOZAKO

From The 2nd Surgical Division, Kyoto University Medical School

(Director: Prof. Dr. YASUMASA AOYAGI)

(Received for publication Aug. 8, 1959)

CONTENTS

I. INTRODUCTION	IV. DISCUSSION
II. METHODS	V. CLINICAL EXPERIMENTS
III. RESULTS	VI. SUMMARY AND CONCLUSIONS

I. INTRODUCTION

Manifestation of the visceromotor reflex is the reflex response of skeletal muscles to the stimulation of the abdominal viscera or accompanied sensory nerves.

Since the first description of MACKENZIE and SHERRINGTON, a considerable number of reports have been published on the reflex. MILLER and others reported that the stimulation of the abdominal viscera or the sympathetic nerves produced reflex contraction of the leg and abdominal wall muscles. Recently, TSUNEKAWA of our laboratory studied the reflex by means of electro myographic method, and he emphasized that the method was very useful for the purpose of analysing the reflex muscle responses.

Therefore, the present author adopted the method and thereby tried to clarify,

- 1) irradiation pattern of the visceromotor reflex in abdominal and leg muscles,
- 2) the visceromotor reflexes elicited from the liver and the biliary tract, and
- 3) in some clinical observations, analysis of the electromyograms (EMGs) of abdominal muscles recorded during the laparotomy.

II. METHODS

Experimental animals

Animal experiments have been performed on cats which were decerebrated by transection of the brain stem at the level of the MAGNUS's section.

Recording

An EDISWAN 8-channel electroencephalograph, was used, and all the records were obtained with the ink-writer oscillographs incorporated in the machine.

Stimulation

For electrical stimulation, and isolated output stimulator was employed which derived a monophasic square wave.

The characteristics of electrical stimulation used were as follows; 60 to 200 cycles per second, 0.1 to 0.5 milliseconds pulse duration, and 1 to 40 volts.

Stimulating electrodes were concentric needle electrodes, center pole of which was used as anode.

Chemical stimulus was given by acetylcholin (ACh) solution at concentration of 0.1 gm per 50 to 100 c. c. of physiologic salt solution. In most cases, 0.1 to 0.5 cc. of its solution were used.

III. RESULTS

1) Responses of the leg muscles to stimulation of the abdominal sympathetic nerves.

The leading electrodes were placed on the m. quadriceps femoris, m. tibialis anterior, m. biceps femoris, m. gastrocnemius, in both right and left lower extremities respectively (Fig. 1). Electrical stimuli were supplied to the major

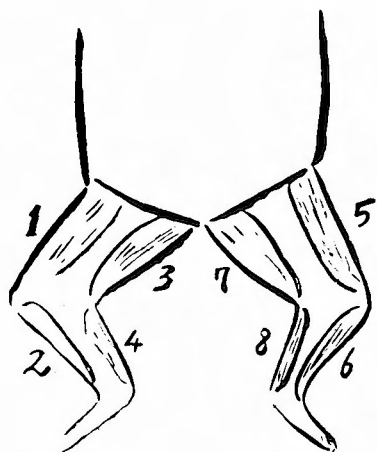


Fig. 1 Tested muscles of the lower extremities. Each muscle is labeled by numbers 1 to 8. They correspond with the recording numbers, 1 to 8, in following Figs. 2, 3 and 4.

- 1, 5. : m. quadriceps femoris
- 3, 7. : m. biceps femoris
- 2, 6. : m. tibialis anterior
- 4, 8. : m. gastrocnemius

splanchnic nerve, superior mesenteric nerve, and inferior mesenteric nerve in turn.

In each instance, reflex responses were evoked in some of the tested muscles (Figs. 2, 3 and 4). The result varied from an experiment to the other. For example, as shown in Fig. 4, by stimulating the inferior mesenteric nerve, remarkable discharges were recorded from left m. biceps femoris. However, in another case the same stimuli on the same nerve produced the reflex responses in other muscles such as right m. quadriceps femoris etc.

The similar results were obtained in experiments of the splanchnic and superior mesenteric nerves.

2) Reflex responses of the leg and abdominal muscles.

In order to compare the reflex responses of the leg muscles with those of

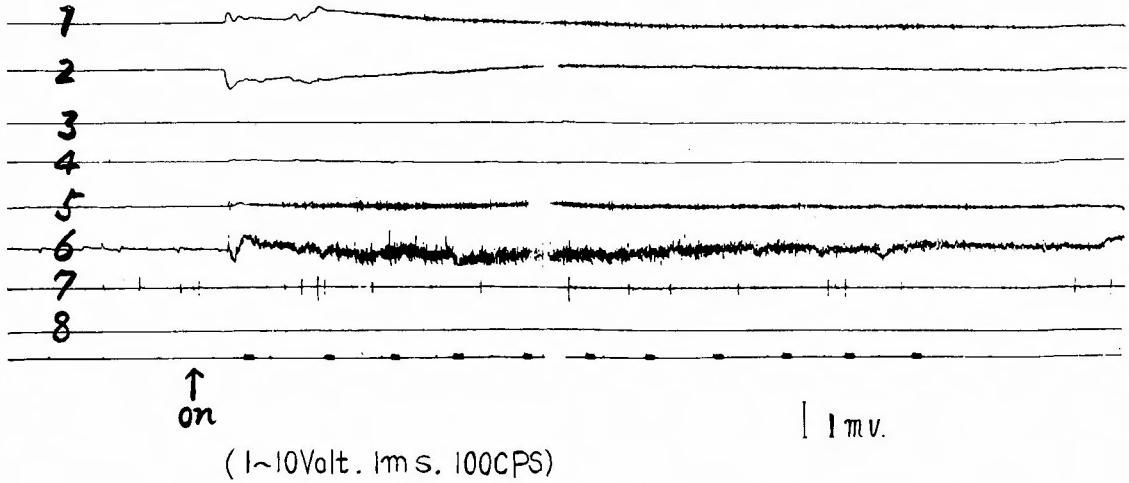


Fig. 2 EMGs of the leg muscles, obtained by the electric stimulation of the major splanchnic nerve.

Intensity of stimuli: 1-10 volts. 1 ms, 100 cps.




Fig. 3 EMGs of the leg muscles, obtained by stimulating the superior mesenteric nerve electrically.

abdominal ones, m. rectus abdominis, m. psoas major, m. quadriceps-femoris, m. biceps femoris were examined (Fig. 5).

Vigorous reflex contraction of the rectus muscles occurred following the injection of Acetylcholine (ACh) solution into the superior mesenteric artery, whereas the reflex changes of leg muscles were not evoked (Fig. 6).

3) Reflex responses of back and anterior abdominal muscles.

M. rectus abdominis and m. longissimus dorsi were examined. By injecting ACh solution into the mesenteric artery, remarkable reflex contraction was elicited in the former muscles, while any reactions did not occur in the latter muscle (Fig. 7).

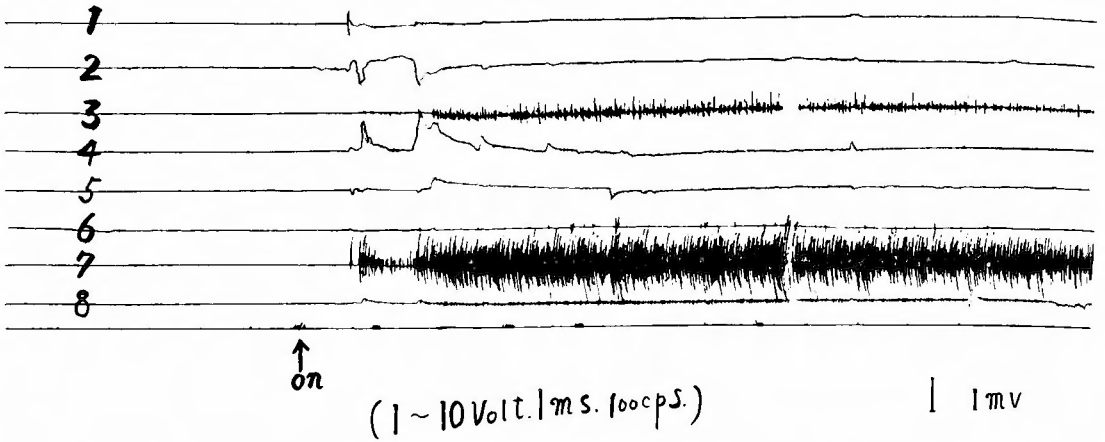


Fig. 4 EMGs of the leg muscles obtained by stimulating the inferior mesenteric nerve electrically.

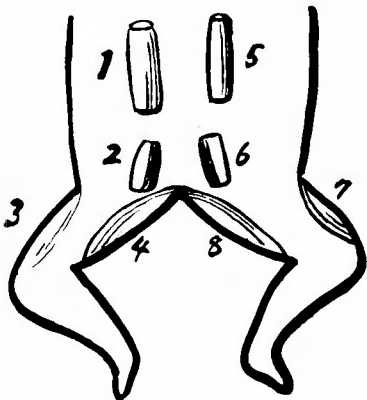


Fig. 5 Tested muscles of the abdominal wall and the lower extremities, the numbers correspond with those of Fig. 6.

- 1,5.: m. rectus abdominis
- 3,7.: m. quadriceps femoris
- 2,6.: m. psoas major
- 4,8.: m. biceps femoris

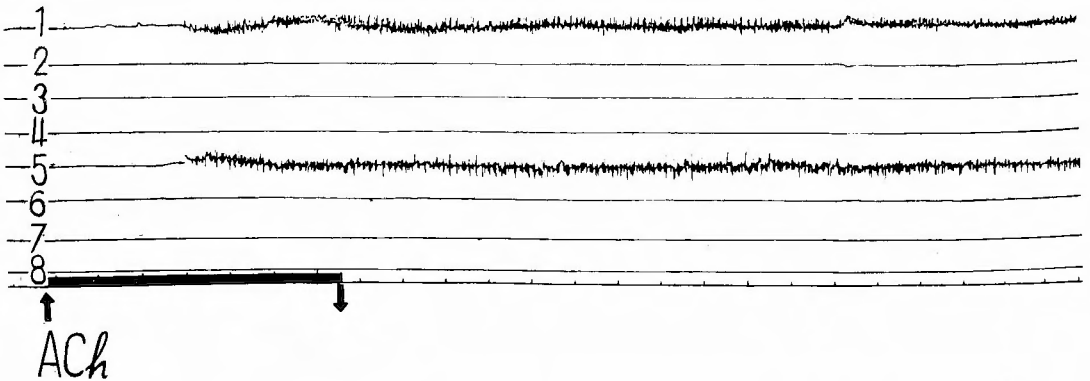


Fig. 6 1 and 5 show EMG's of rectus abdominis and 2, 3, 4, 6, 7 and 8 show no response of the leg muscles, following the injection of ACh solution in the superior mesenteric artery.




Fig. 7 2 EMG of the rectus abdominis and 1, no response of the m. longissimus dorsi, when ACh solution was injected into the superior mesenteric artery.

4) Muscle responses to stimulation given on the biliary tract.

Leading electrodes were symmetrically placed on the right and left rectus abdominis muscle (Fig. 8), then the hepatic, cystic and common bile duct were stimulated electrically. Almost always the spike discharges were observed at upper part of the rectus abdominis muscle, especially on the right side (Fig. 9, 10, 11).

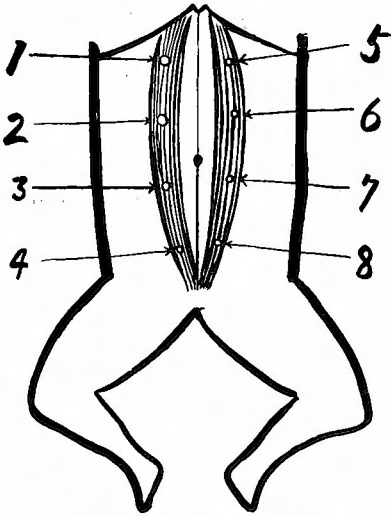


Fig. 8 Shows the placings of electrodes on the rectus abdominis, 1 to 8. The numbers also correspond with recording numbers, 1 to 8, in following EMGs.

5) Muscle responses to stimulation given on the liver.

(a) By injecting ACh solution into the liver through the biliary tract, distinct reflex discharges were recorded in the upper part of rectus muscle, mainly from Th 7 to Th 11 of dermatomes of the abdominal wall (Fig. 12). If the solution was injected into the right lobe through the right hepatic duct, the

discharges were observed only on right rectus abdominis (Fig. 13). In case of left hepatic lobe, a marked electric discharge appeared in the left rectus muscle from Th 7 to Th 9 with slight one in opposite side (Fig. 14).

(b) By injecting the ACh solution into the liver through the portal vein, the similar responses were obtained from the rectus muscle. Sometimes they developed in whole rectus muscles, involving many segments of dermatomes (Fig. 15).

(c) The physiological salt solution was injected with some pressure into the liver through the biliary tract. 2-5 c. c. of the solution did not produced any reaction, but 20 cc of the solution evoked notable spike discharges in the right upper abdominal part (Fig. 16). The similar result was obtained by congestion of the liver, which was produced by the ligation of the hepatic vein (Fig. 17).

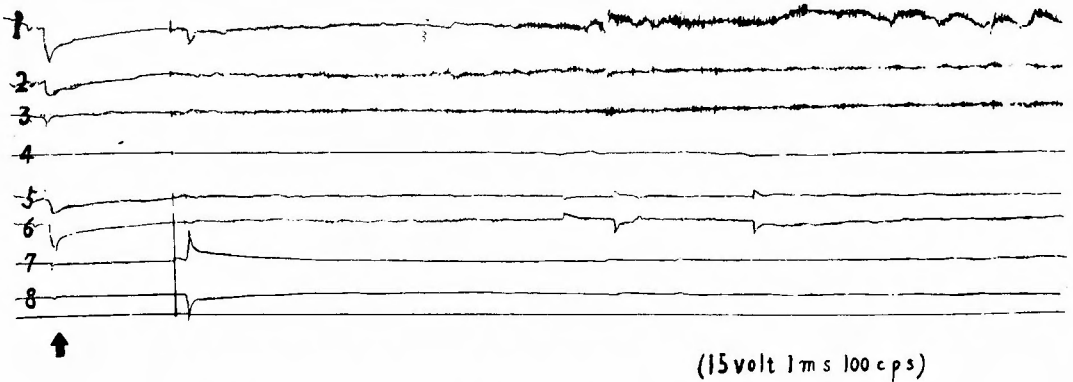


Fig. 9 EMGs of the rectus abdominis recorded by stimulating the common bile duct electrically. In record 1, 2, 3, 5 and 6, they are shown.

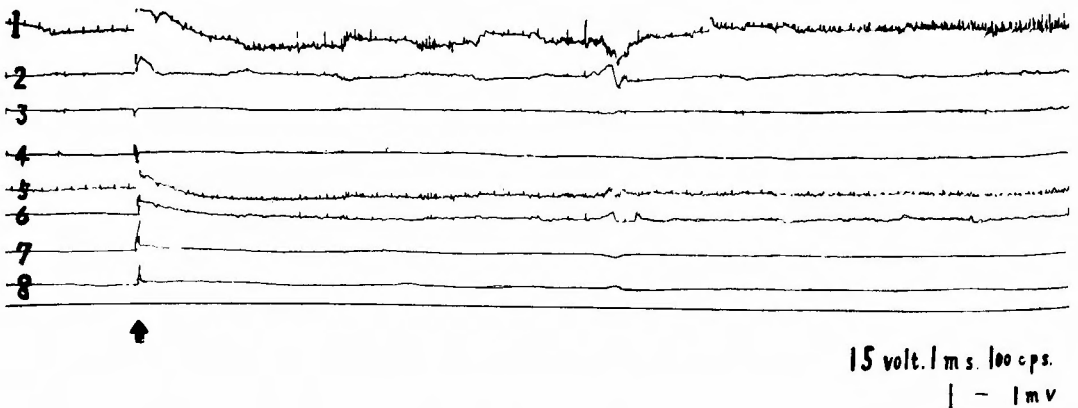


Fig. 10 EMGs of the rectus abdominis, evoked by electrical stimulation of the cystic duct.
The positive discharge appears from upper abdominal muscles, especially from the right side.

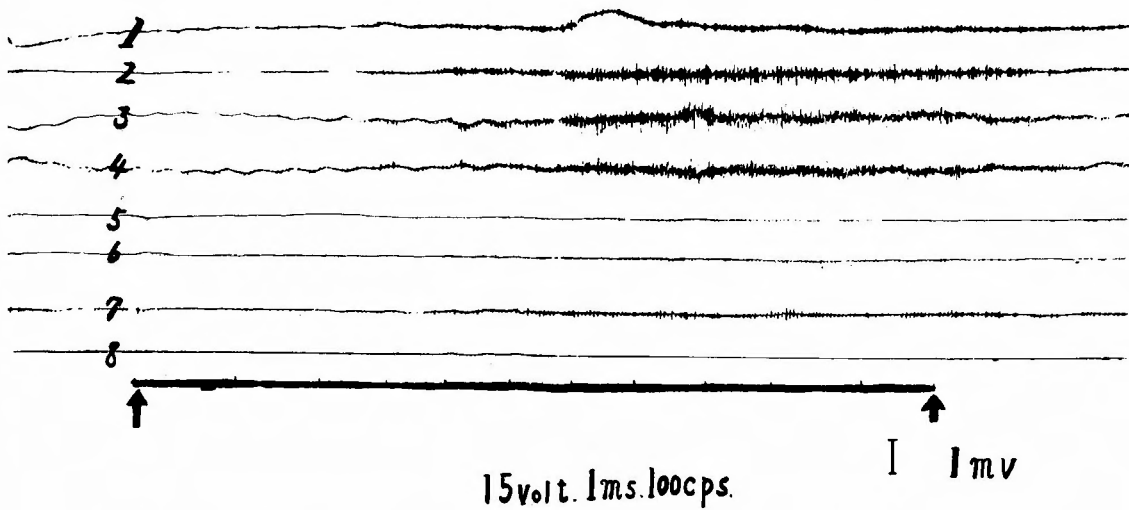


Fig. 11 EMGs of the rectus abdominis elicited by electrical stimulation of the hepatic duct.

The discharge appeared in the muscles on the right side of abdominal wall.




Fig. 12 EMGs of the rectus abdominis, recorded by injecting ACh solution into the liver through the biliary tract. A marked discharge appeared from upper half of the abdominal muscles on the right side and a slight one from the left side.

(d) Experiment of nerve section

By electrical stimulation on the hilum of the liver reflex discharges were evoked in upper part of the right and left rectus muscles, especially marked on the right side (Fig. 18).

After the right splanchnectomy, the reaction disappeared in the right rectus muscle, whereas the responses became more distinct in the left rectus muscle (Fig. 19).

In another animal, left splanchnectomy was performed. An opposite result was recognized, i. e. the muscle responses disappeared in the left side and they remained in the right side (Fig. 20).

Vagotomy did not give any influence upon the visceromotor reflex elicited from the liver (Fig. 21).

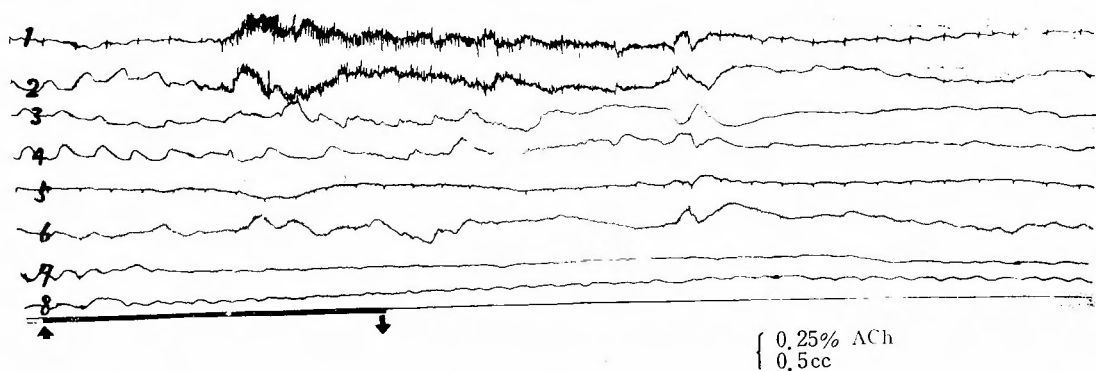


Fig. 13 EMGs of the rectus abdominis muscle, recorded by injecting ACh solution into the right lobe of the liver through the right hepatic duct. A marked discharges were given from the upper abdominal muscles on the right side, while a slight one from the left side.

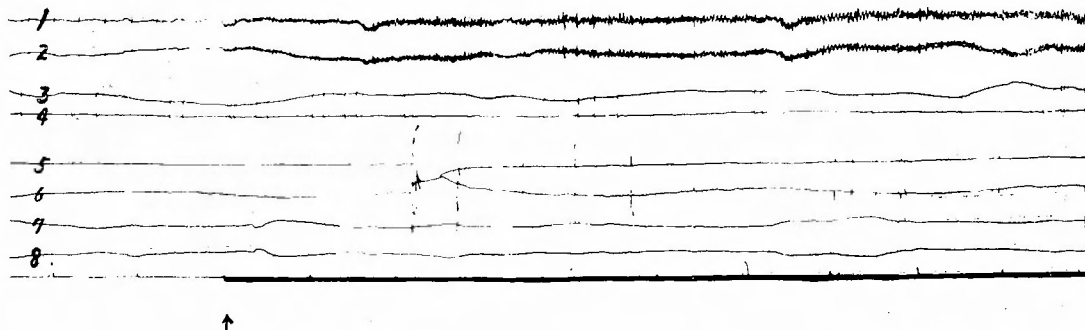


Fig. 13' EMGs of the rectus abdominis muscles, recorded by the electric stimulation on the right lobe of the liver, the action potentials appeared only on the right side.

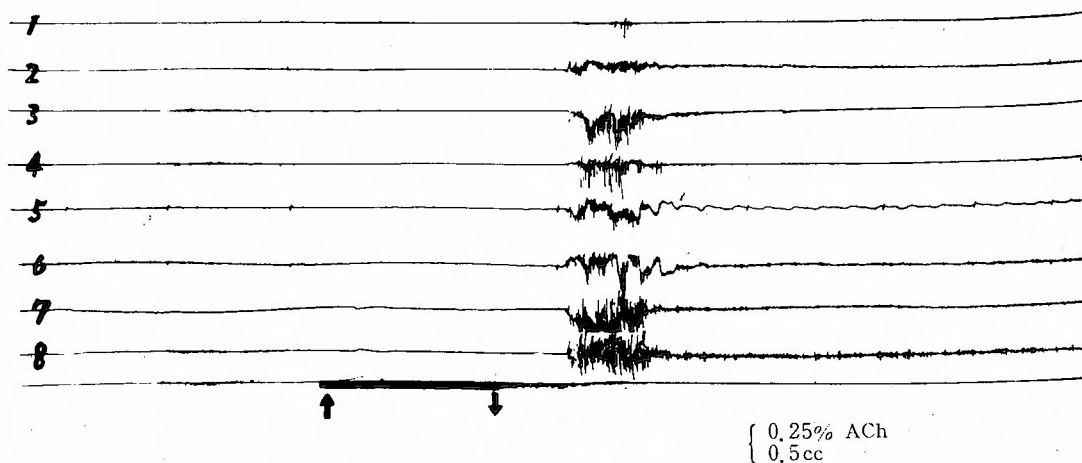


Fig. 14 EMGs of the rectus abdominis, recorded by injecting ACh solution into the left lobe of the liver through the left hepatic duct. The discharge appears from the muscles on both abdominal sides, but somewhat dominantly from the left side.

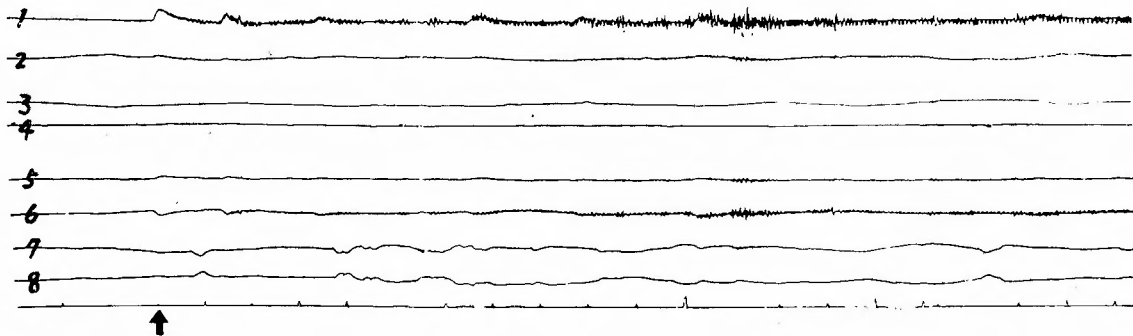


Fig. 14' The EMGs of the rectus abdominis muscles, recorded by the electric stimulation on the left lobe of the liver. The action potentials appeared from the upper abdominal muscles on both sides.

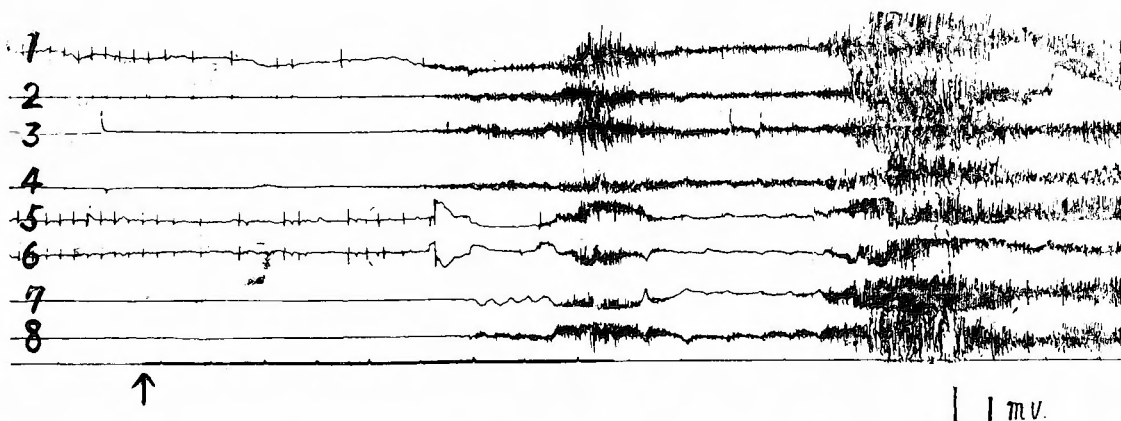


Fig. 15 EMGs of rectus abdominis, recorded by injection of ACh solution into the pfortal vein. The stimulation of the liver through the pfortal vein caused the whole abdominal muscle contractions.

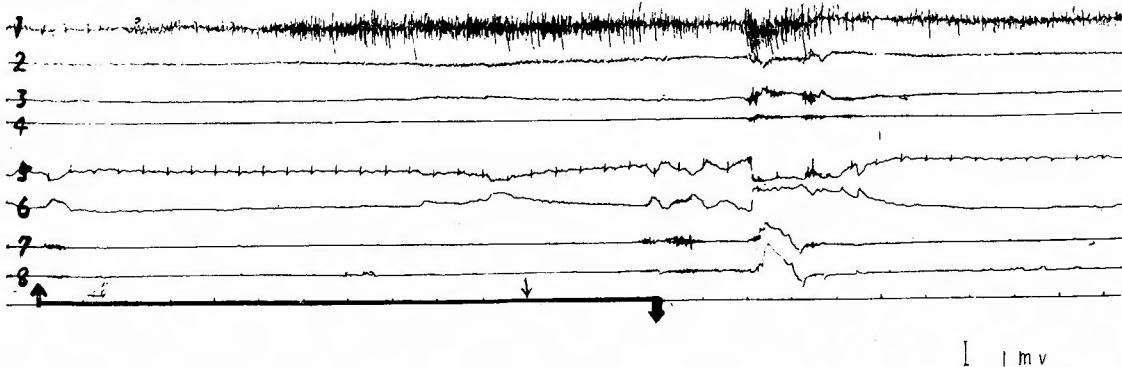


Fig. 16 EMGs of the rectus abdominis, recorded by injection of 20 cc of physiologic salt solution into the liver through the biliary tract with some pressure. The stimulus caused a discharge only of the upper abdominal muscle on the right side.




Fig. 17 EMGs of the rectus abdominis, following the ligation of the hepatic vein resulting in the acute hepatic congestion. The discharge occurred on the whole muscles only on the right side.

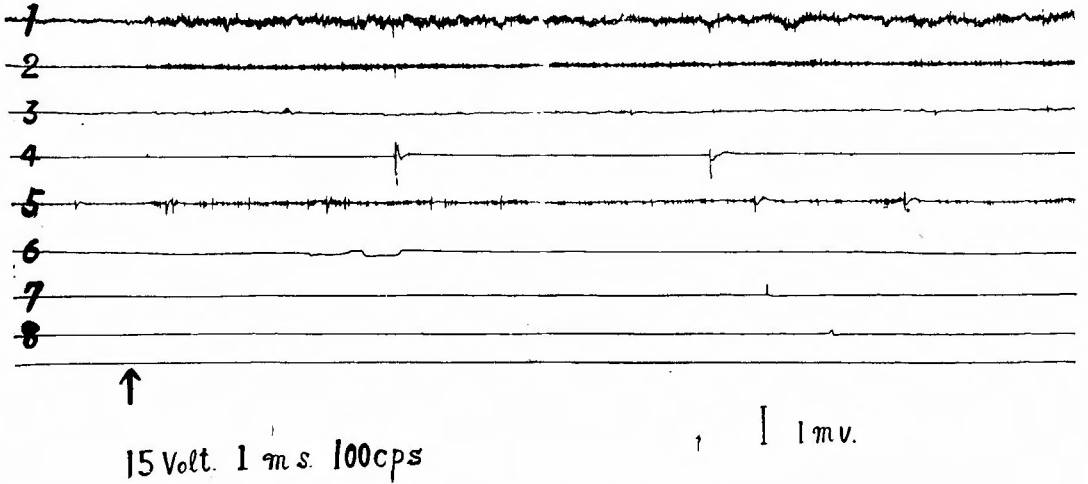


Fig. 18 EMGs of the rectus abdominis, recorded by electrical stimulation on the hilum of the liver. A marked discharge appears on the upper abdominal muscle on the right side, but very slight on the left side.

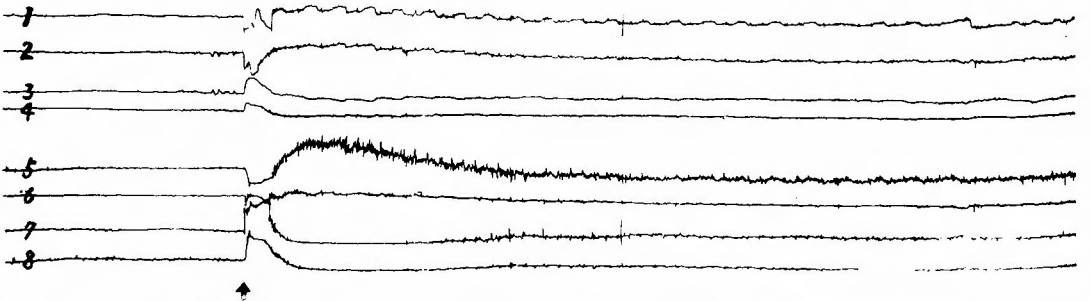


Fig. 19 EMGs of the rectus abdominis, recorded by electrical stimulation of the liver after section of the right splanchnic nerve. The discharge from the muscles on the right side become very slight but those of the left side remain normally.

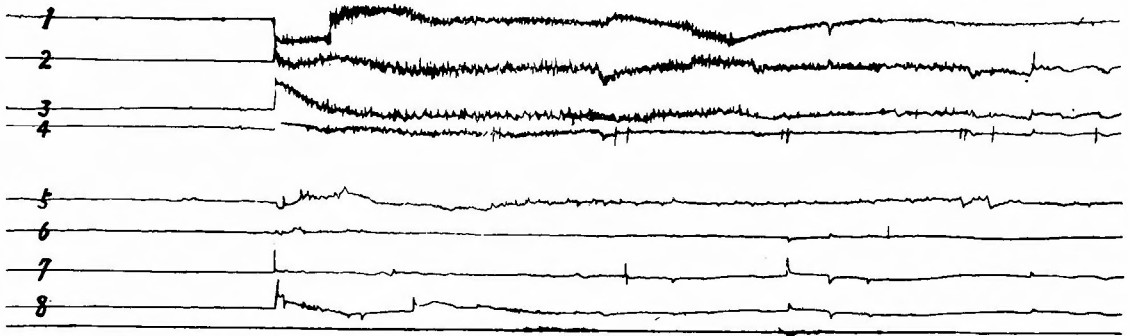


Fig. 20 EMGs of rectus abdominis, recorded by electrical stimulation of the liver after the section of the left splanchnic nerve. The discharge remain only on the right side.

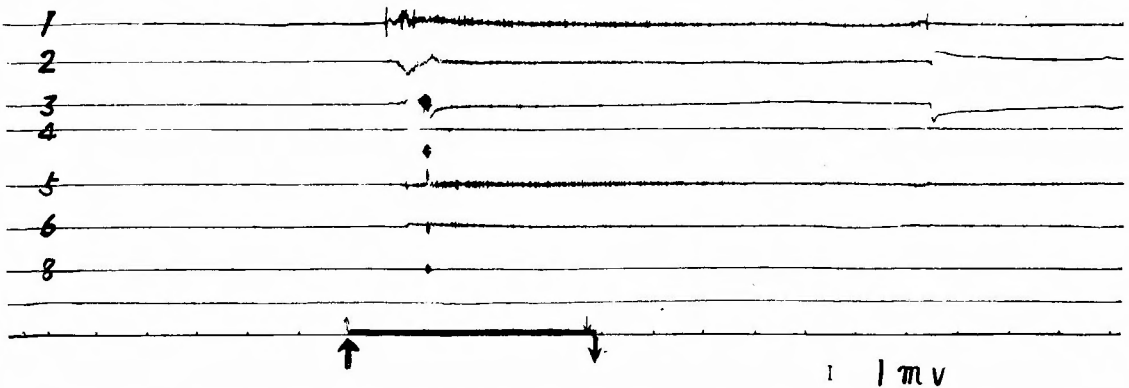


Fig. 21 EMGs of the rectus abdominis, elicited by injection of ACh solution into the liver through the biliary tract, after bilateral cervical vagotomy. The discharge becomes slight.

IV. DISCUSSION

Clinically "défense musculaire" cannot be proved in the extremities of a patient with visceral disease, though the phenomena is often recognized in the abdominal wall muscles.

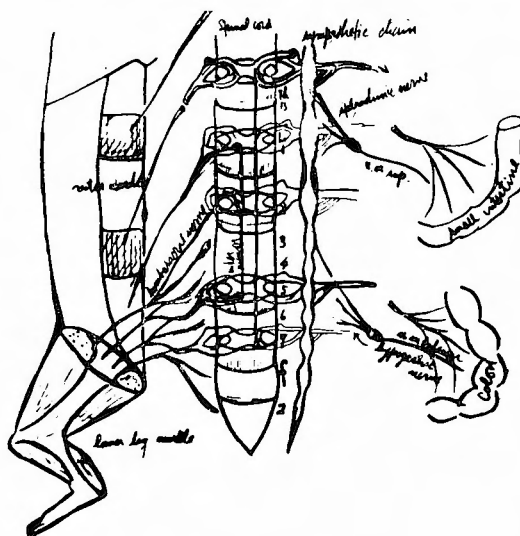
To account the fact, KIMURA of our laboratory has advanced a hypothesis that because of the lack of the white rami between L_2 - S_2 segment of the spinal cord, the "défense musculaire" of the leg which is innervated by those segments does not occur. His opinion is believed to be true with some limit. In the present study, it was fairly demonstrated that remarkable reflex discharges was elicited in the abdominal muscles by stimulating the intestine with ACh solution, but they were not evoked in leg muscles with the same stimuli. Furthermore, it was proved that vigorous muscle responses were evoked in the leg muscles as well as abdominal ones by the electrical stimulation on the abdominal sympathetic trunk.

These results do not agree with the KIMURA's hypothesis in the muscle responses of the leg which elicited by electrical stimulation. In this point, it must be considered that the responses are obtained on decerebrated cat in which inhibition of the upper centrum is completely released, and they are recognized under the specific condition such as direct electrical stimulation of the nerve trunk. At the same time, it is highly suggested that if the applied stimuli become properly stronger, the elicited impulses are mediated through the polysynaptic reflex arc including intraspinal interneurons, to evoke the leg muscle responses.

Such irradiation of the reflex does not observed in patient with abdominal disease or by ACh stimulation in animal experiments. In these cases, reflex arc may be monosynaptic or a few synaptic.

After all, KIMURA's hypothesis is limited by following two factors, viz, intensity of stimuli and inhibition of the upper centrum.

Schematic illustration of the visceromotor reflex is shown in Fig. 22.

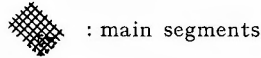
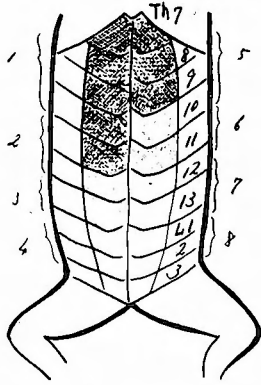


Peripheral effective organ (muscles) Centrum (spinal cord) Starting position of stimuli (viscera and abdominal sympathetic nerve)

Fig. 22 Schematic illustration of the visceromotor reflex. Note the irradiation of the reflex, presumably through the polysynaptic reflex arc.

It is clinically evident that some diseases of the biliary tract or the liver often cause abdominal pain. At that time, viscerosensory reflex, viz, paraesthesia or visceromotor reflex, viz, defense musculaire are notable signs to indicate the disease.

In this study, the segmental distribution of the *défense musculaire* was decided on the abdominal dermatomes. It is proved that the muscular responses evoked from the liver developed from Th 7 to Th 11 of dermatome of abdominal wall on the right side, and from Th 7 to Th 9 on the left side. Almost the same distribution was demonstrated in the experiment of the bile duct (Fig. 23).



: main segments

1—8 : recording numbers

Th L : abdominal dermatomes

Fig. 23 Shows the main segments of dermatomes reflected from the liver and the biliary tract, these segments (Th 7 to Th 11 in right side, and Th 7 Th 9 in left side) were decided by the EMGs of Figs. 12, 13, 14.

In addition, a tendency to homolaterality on the development of visceromotor reflex was shown to some degree between right and left rectus abdominis muscle and corresponding liver lobes though it is dominant on the right side.

From the metameric point of view, the decided areas agree with those of referred pain, paraesthesia and *défense musculaire* observed in patients with the disease of the liver or the biliary tract.

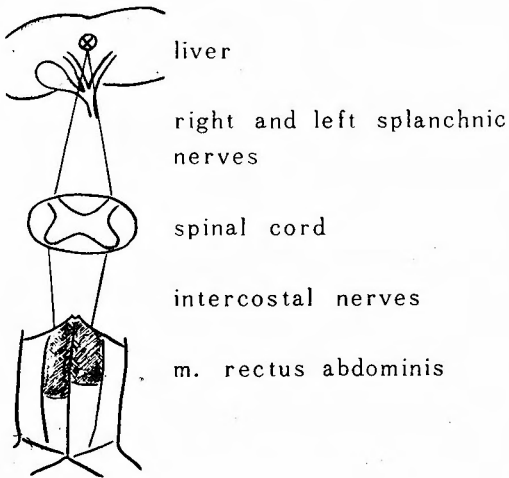


Fig. 24 Schematic illustration of the visceromotor reflex elicited from the liver. Nerve intact.

As mechanical stimuli, effect of pressure was examined with the physiologic salt solution. Appropriate pressure produced by the solution injected into the liver evoked reflex contraction of the rectus muscle, and the same result was also obtained by acute congestion of the liver which was artificially produced.

Recently, INOUE and TSAI in our laboratory found the sensory nerve endings

in the biliary tract and the liver.

Among others, it is of interest that Pacinian corpuscle, considered as a specific pressoreceptor, was detected in the connective tissue septa between hepatic lobules.

Accordingly, it seems reasonable to assume that these endings act as starting points of the reflex impulses.

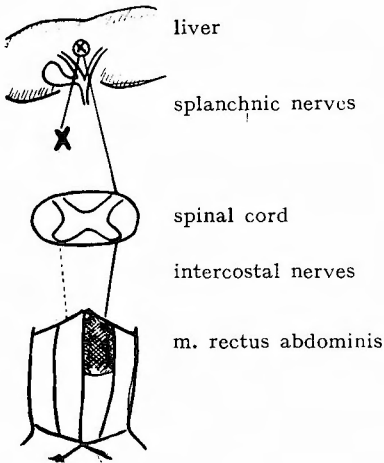
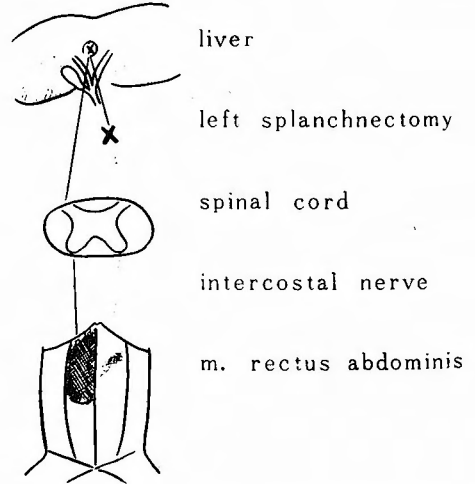


Fig. 25 Schematic illustration of the visceromotor reflex elicited from the liver after the right splanchnectomy, contraction of the right rectus abdominis disappeared.

Fig. 26 Schematic illustration of the visceromotor reflex elicited from the liver. After the left splanchnectomy, contraction of the left rectus abdominis disappeared.



Thus evoked afferent impulses are mediated through the both right and left splanchnic nerves to the spinal cord. In addition, the impulses which evoke the muscle responses of right rectus abdominis muscle pass the right splanchnic nerve. On the contrary, the impulses of the left splanchnic nerve are transmitted to the rectus abdominis on the same side. This is lead from the fact that section of the right and left splanchnic nerves resulted in disappearance of homolateral rectus abdominis muscle responses.

The result is illustrated in Figs. 24, 25 and 26.

V. CLINICAL EXPERIMENT

A 17 year-old female, suffering from postoperative intestinal adhesion was tested. She held anteflexed hip joint in order to avoid the distress (Fig. 27).



Fig. 27 A female, suffering from postoperative intestinal adhesion.

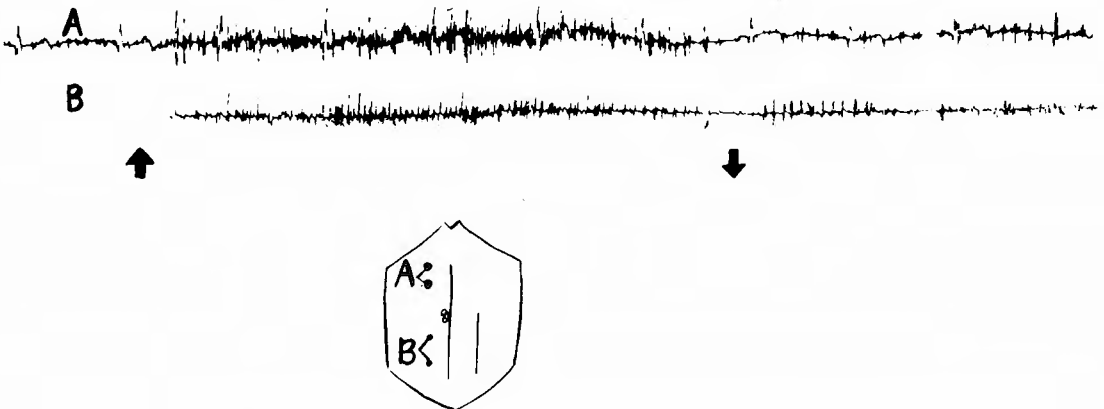


Fig. 23 EMGs of rectus abdominis in a patient with chronic intestinal adhesion. The muscle-action potentials were elicited by voluntary increase of abdominal pressure.

As shown in (Fig. 28), remarkable EMGs were recorded from the rectus abdominis muscles in voluntary increase of abdominal pressure. The same results were obtained by stretching the lower extremities (Fig. 29).

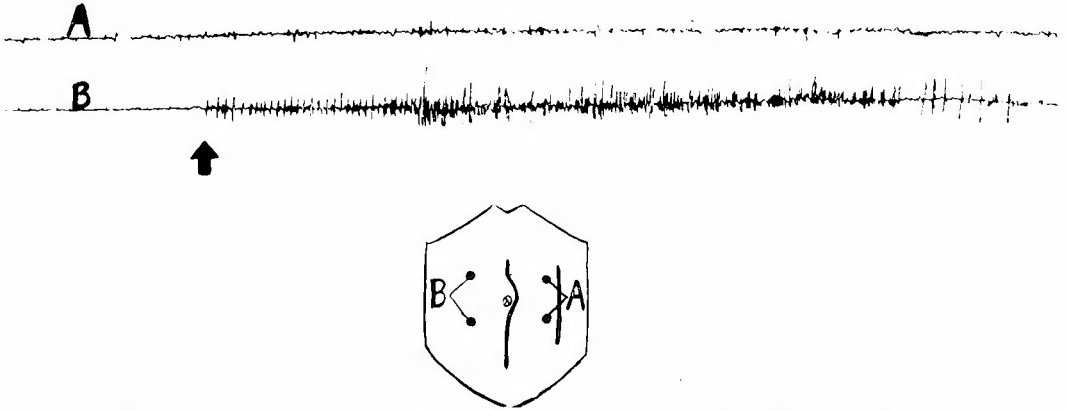


Fig. 29 EMGs of rectus abdominis in the same patient as Fig. 28, they were recorded by stretching the lower extremities.

The EMG is regarded as one type of type of the visceromotor reflex, because it is considered that the muscle-action potentials were evoked by abdominal pressure or stretch of the leg which presumably stimulated the adherent abdominal viscera, however the participation of the peritoneomotor reflex cannot be excluded in this reactions.

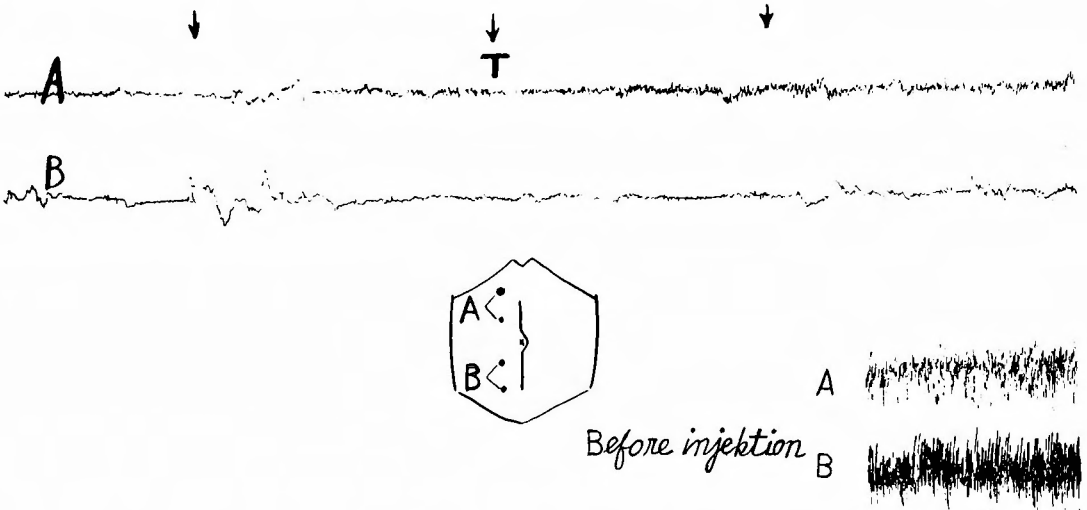


Fig. 30 EMGs of rectus abdominis, recorded during laparotomy by traction of the mesentery after injection of Saccin. T: Traction.

In a patient, stimulation was applied to viscera during the operation. In order to suppress or exclude the discharge caused by laparotomy and to catch the exact increase of spike discharges following the stimulation on viscera, the

author performed the previous injection of Saccin and put her in a deep anesthetic condition. Thereafter, by traction of the mesentery evident increase of discharge was observed (Figs. 30 and 31).

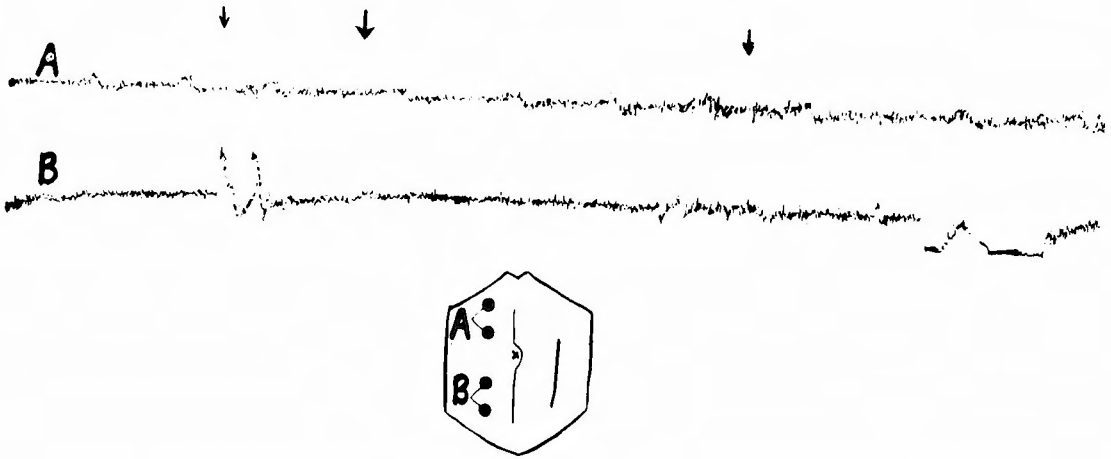


Fig. 31 EMGs of the rectus abdominis, recorded during laparotomy by traction of the mesentery under a deep anesthesia with ether.

However, it was impossible to decide the segmental distribution of reflex area on the abdominal wall from the EMGs.

This may be due to the fact that the visceral sensory nerves running through the mesenteric root belongs to so wide levels of the spinal segments.

VI. SUMMARY

(1) The visceromotor reflexes were studied on the decerebrated cats and in some patients by means of electromyographic method.

(2) The reflex contraction of the leg muscles was evoked by electrical stimulation of the abdominal sympathetic nerves, but they did not occur by stimulation of the abdominal viscera with ACh solution.

The different results are due to the intensity of stimuli, which caused irradiation of the visceromotor reflex.

(3) Simultaneous recording of EMGs of the leg and abdominal muscles demonstrated striking contrast in development of reflex responses to stimulation of the abdominal viscera.

(4) By stimulating the liver with ACh solution, the reflex contraction of the abdominal muscles was evoked from Th 7 to Th 11 of dermatomes on the right side and Th 7 to Th 9 on the left side.

(5) The visceromotor reflex could be also elicited from the biliary tract with electrical stimuli, and the reflected area of abdominal muscles were the

some as those reflected from the liver.

(6) By mechanical stimulation, i. e. by injection of the physiological salt solution into the liver through the biliary tract with high pressure, distinct muscle discharges of rectus abdominis were recorded.

(7) On the standpoint of visceromotor reflex, a homolaterality was proved between the right and left liver lobes and the corresponding abdominal muscles to some degree, though it is dominant on the right side.

(8) The liver had dual sensory supply via the right and left splanchnic nerves. Interruption of afferent impulses in the right and left splanchnic nerves caused disappearance of reflex contraction of rectus abdominis muscle on corresponding side.

(9) In clinical experiments, the visceromotor reflex was demonstrated in a patient with intestinal adhesion and also in a patient during laparotomy. However, the peritoneomotor reflex could not be excluded in the former, while the spinal segments, to which the visceral sensory nerves running through the mesenteric root belonged, could not be determined in the latter.

An abstract of this study has been reported by the author, at the 57th annual meeting of the Japanese Surgical Association, on Apr. 1-3, 1957, in Tokyo, at the 10th annual meeting of the Japanese Electromyographic Association, on Oct. 11-12, 1957, in Okayama, and at the 12th annual meeting of the same association on Jun. 6-7, 1959, in Hiroasaki.

I wish to express my sincere thanks to Assist. Prof. Dr. KIMURA, M. D. of our clinic for his help and criticism throughout this work.

References.

- 1) Downman, C. B. B. : Skeletal muscle reflexes of splanchnic and intercostal nerve origin in acute spinal and decerebrate cats. *J. Neurophysiol.*, **18**, 217, 1955.
- 2) Downman, C. B. B. and McSwiney, B. A. : Reflexes elicited by visceral stimulation in the acute spinal animal. *J. Physiol.*, **105**, 80, 1946.
- 3) Inoue, H. : A histological study of sensory nerves in the biliary tract. *Arch. Jap. Chir.*, **24**, 257, 1955.
- 4) Koya, T. : The afferent autonomic nerves of the liver and gall bladder (in Japanese) *Kyoto Igakukai Zasshi*, **9**, 569, 1932.
- 5) Kimura, Ch. : The problems of abdominal pain. *Arch. Jap. Chir.*, **22**, 59, 1953.
- 6) Lewis, T. and Kellgren, J. H. : Observations relating to referred pain, visceromotor reflexes and other associated phenomena. *Clini. Sci.*, **4**, 47, 1939.
- 7) Miller, F. R. and Simpson, H. M. : Visceromotor reflexes. *Trans. Roy. Soc. Canada*, **18**, **147**, 1924 Sec. 5.
- 8) Ray, B. S. and Neill, C. L. : Abdominal visceral sensation in man. *Ann. Surg.*, **126**, 709, 1947.
- 9) Shikata, I. : Studie über den vegetatiko-cerebro-spinalen reflex. *Tokyo Igakukai Zasshi*, **44**, 42, 1930.
- 10) Tsunekawa, K. : Electromyographic studies on the visceromotor reflexes. in the press.
- 11) Tsai, T. L. : A histological study of sensory nerves in the liver. *Acta Neuro-Veg.*, **17**, 355, 1958.
- 12) Von Euler, C. and Sjostrand, J. : The elicitation of visceromotor reflexes. *Acta physiol. Scand.*, **14**, 363-372, 1947.
- 13) Watanabe, Y. : Studies on the viscerogenic reflexes. *Arch. Jap. Chir.*, **23**, 38, 1954.

和文抄録

内臓運動反射の筋電図学的研究

京都大学医学部外科学教室第2講座(指導：青柳安誠教授)

古 迫 清 三

去脳猫を用い内臓運動反射の筋電図学的研究を行ない、それと関連した2~3の臨床実験を行ない、その結果は次のようである。

1) 下肢筋の反射性収縮は腹部内臓神経の電気刺激によつて惹起されるがアセチルコリンによる内臓刺激では起らない。この相違は、内臓運動反射の放散、拡大を起すところの刺激の強さ如何によるものである。

2) 下肢筋と腹直筋との同時性筋電図を記録することによつて、内臓刺激に対する反射性反応の現われ方の差違を明瞭に知ることができた。

3) 肝臓のアセチルコリン刺激によつて生ずる腹直筋収縮は右側に於いては $Th_7 \sim Th_{11}$ 、左側に於いては $Th_7 \sim Th_9$ の範囲の腹壁デルマトーム上に現わ

れる。

4) 胆道からの運動反射も亦肝臓と同様に現われる。

5) 可成の圧力をもつてする生理食塩水の肝臓内注入は腹直筋右上部の反射収縮を惹起する。

6) 内臓運動反射の観点から、左右の腹直筋と左右の肝臓の間には或る程度の Homolaterality が存在する。

7) 肝臓は左右の内臓神経によつて知覚支配を受ける。内臓神経のいずれか一方の切断は、その側の肝臓刺激に起因する腹直筋収縮を消失させる。

8) 2~3の臨床実験に於いて内臓運動反射が考察された。