Arch. Jap. Chir. 42(4), 293～314, Okt., 1973

原　　著

# Electronmicroscopic Studies on the Differentiation and the Ontogenesis of Gastric Epithelium Cells of Rat Embryo

by

TOMIO MATSUMOTO

## I. Introduction

The studies on pathologic gastroepithelium cells are based on the knowledge about normal gastroepithlium cells.

The investigations regarding normal and abnormal gastroepithelium cells have been performed by many precursors[1),2),3)], and recently, the numerous studies on their fine structures with electronmicroscope have been presented[4),5),6)]. However, the researches of the dynamic processes for their differentiation and growing are few, especially the studies with electronmicroscope.

Therefore, this author researched electronmicronscopically the kinetic courses of the differentiation and growing of the gastroepithelium cells (of each gravid day) which are conjectured to be able to observe ontogenetically.

Since the morphological studies always have to head for being equivalent to the physiological and biochemical truthes, this author tried with a few histochemical methods also.

## II. Materials and Methods

1. Materials: The center part of gastric tube of embryos and newborns of Rattus norvegicus var. albus (gravid day 23) served as the materials.

2. Preparation of the specimens: Under nembutal anesthesia laparotomy was performed on the pregnant rat, and by taking care to keep blood flow to the embryo as long as possible, the embryo's stomach was excised. Then the stomach was immersed in Palade's cold fixing solution (1% buffered osmium tetroxide, PH=7.4 0～4°C) for one hour.

Reprint address : % Fukushima, 456 Honmachi Daiku, Okayama, Japan.
岡山市大供本町456 福島

In the case of very young embryos after opening the embryo's abdomen the whole embryo was immersed in 4% glutaraldehyde phosphate buffered solution, 0～4°C, and the stomach was excised under magnifying glass, then fixed in the solution of 1% buffered osmium tetroxide, PH=7.4 C, 0～4°C for one hour.

Placing the fixed stomach in such a direction as to enable to prepare longitudinal sections of gastric epithelium[7], the material was embedded in Epon, ultrathin sections were cut, then stained with uranyl acetate and lead oxide, after giving carbon coating, these served as the specimens for observation in electronmicroscopes, Hitachi-HU11 and UP7.

3. Indicating: Quantity of the cytoplasmic organoid was expressed for the rate how total area of all the organoids of the same kind occupied in the cut surface of its cytoplasm, serving the specimens of a cell which is cut near cell's center including of both its free surface and basal membrane

4. Measuring: The dimensions were calculated on that the transparent section-sheet is overlapped on the micrograph.

5. Mentioning: The descriptions about the cell are mainly in regard to the most mature cell of certain kind on a same gravid day.

## III. Summary

**1. Stage of Plane Epithelium, Term of Mucous Cell to Appear.**

On and after gravid day 12 the majority of the cells composing the smooth plate of gastric epithelium in a rat embryo transform into columnar cells which would present the characteristics of the early mucous cells in future.

**2. Stage of Primary Gland (Gastric Pit) Formation, Term of Parietal Cell and Basal Clear Cell to Appear.**

On gravid day 16 there are a few conspicuous undifferentiated cells to align in an urn shape among numerous columnar cells which begin to come together as the bundle like a parachute form. And then, according to the infranuclear cytoplasm of columnar cells shorten, the part of their basal membranes bulges up like a tent and the cut surface of the basal membrane which was originally smooth becomes undulated. In the earlier course of the construction of gastric pit there appear young parietal cells, subsequently the basal clear cells appear. The primary gland formation is later nearer to the caudal region of a stomach.

**3. Stage of Secondary Gland (Gastric Chief Gland) Formation, Term of Chief Cell and Basal Granular Cell to Appear.**

By gravid day 20～21 the gastric pits are almost completed all over the epithelium except prepyloric area. Moreover, at the region near the boundary of nonglandular epithelium the germes of chief gland are budding from the bottoms of the pits.

At one month after birth their gastric epithelium (gland=pit+chief gland) becomes the same as that of an adult animal.

The phenomenon as same as the ontogenesis in the gastric epithelium of a rat embryo is repeated at the regeneration of gastric ulcer.

## IV. Result

**The following description about gastric epithelium cells are mainly of the most mature cells among those of the same kind cells at each age.**

**1. Embryos younger than gravid day 14.**

In the gastric epithelium of such early embryos the undifferentiated cells that are originated in entodermal epithelium cells are distributed over the plane basal membrane in a monolayer. Characteristic features of the undifferentiated cells are as follows :

(1). The cell is cuboid~oval in shape, with a large nucleocytoplasmic ratio.

(2). their cell membrane equip with a little desmosmes and advanced terminal bars, neither infolding nor interdigitaton. There're the slight undulations over the free surface.

(3). The nucleus' shape is spherical~elliptical, the membrane has a smooth spherical surface, and the nucleoplasm is distributed homogenously.

(4). Mitochondria on the central cut surface of a cell are less than 5% in cytoplasm, and their shape and size are not uniform. Rough endoplasmic reticulums (rERs) are less than 2% in its cytoplasm, and short ones are distributed separately and their shape varies from tubular to vacuolar structure.

(5). Free ribosomes, fibers and polysomes are distributed evenly.

**2. Embryo On Gravid Day 15**

The major portion of interior surface of the stomach is lined with columnar cells, the cells are perpendicularly standing on the smooth basal membrane in a highly dense array. The basal membrane as a boundary underneath, mesodermal submucosa tissue is located but the cells composing submucosa are not so dense and early muscle plate can barely be distinguished. Sharp apexes of submucosa cells are in contact slightly with the basal membrane in places, but the greater part in between has a space. At a lowermost layer there can be observed a distinct monolayer of serosa cells.

a. Columnar cells

Columnar cell's free surface which has a few microvilli and indentations presents a semispherical shape. The cell membrane hardly shows infoldings and not any interdigitations. The terminal bar has extended all around the cell, and is now well developed. The nuclear membrane is smooth and has assumed an elliptical shape, but occasionally there is observed a solitary deep invagination.

The nuclear fine granules organize irregular aggregates on a small unit, these aggregates further become crossed with another and form networks, however, the nuclear fine granules appear at a glance to be distributed homogenously, as these

units are smaller and denser in comparison with the nucleoplasm of ripen cell's.

Golgi laminae are thin and sometimes a few Golgi vacuoles are seen swollen. Other intracellular structures are identical with those of the undifferentiated cells.

**3. Embryo on Gravid Day 16**

In the lower half of submucosal tissue there can be seen the early muscle layer as a band of somewhat long spindle shaped cells. In the epithelial area a few of the undifferentiated cells become distinct whereat mitosis's seen, embedding among a large number of columnar cells, they already show a tendency to align themselves in an urn shape.

a. Columnar cells (early surface mucous cells)

NC ratio is still fairly big, and even in their fine structures they still retain the characteristic features of the undifferentiated cells. The free surface of these cells appears like a dome and there is not so increase in the microvilli numbers. However, in proportion to number of the undifferentiated cells among columnar cells become distinct, the columnar cells are found to have the tendency to make the groups of several cells.

**4. Embryo On Gravid Day 17**

The swelling of greater curvature of the stomach grows from its oral side. The urn-like alignment of undifferentiated cells, which is the bud of gastric pit, becomes far more distinct among the columnar cells by this time. On the other hand, as some colmnar cells transform into a pyramidal shape, the bundle of these cells assumes a parachute figure.

a. Columnar cells (young surface mucous cells)

The cells located nearer the central part of the columnar cells bundle are taller, while they are shorter nearer the margin of the bundle and become curved, thus the size and shape of columnar cells are variable at this time. In the fine structure of columnar cells there appear characteristic features of surface mucous cell in their nucleus, decreasing NC ratio and shifting toward their basal part, the most of columnar cells show their surface to be wider than their base and some of them contain 1~2 secretory mucous granules. There is a slight increase in the number of mitochondria but no development of rER. On account of concentration of free ribosomes, polysomes and other organella, their cytoplasm assumes a darker tone.

b. Early parietal cells

For the first time there appear peculiar cells showing the cut surface of intracellular canaliculli(Icc), supposed to be composed by the fusion of the protocanalicullar vacuoles.

These early parietal cells are similar to the undifferentiated cells in most respect of their fine structures. But what differs is in that their cytoplasma appear electron-microscopically light because of the scarcity of free ribosomes, especially of ultrafine granules and filaments, and other is in the ballooing of their cell membrane.

| model of development of gastric epithelium | cell which begin to be observable electronmicroscopically | stain method | | | | |
|---|---|---|---|---|---|---|
| | | Hematoxy. Eosin H E | Methylen. Eosine M E | PAS | Sudan-BB | Toluidine blue |
| 1W 2W stage of plane | undifferentiated cell | N(+) C(-) C(±) | N(++) C(+) | | | N(-) C(+) |
| | columnar cell | N(++) N(-) C(±) C(±) | N(++) C(+) | | | N(-) C(+) |
| | (surface) mucous cell | N(+) C(±) C(+) (-) | N(+) C(-) | C(+)~(+++) | | N(-) C(+)~(±) |
| | small cell possessing granula | N(+) | | | | N(-) C(++) |
| 2.5W 3W stage of gastric pit formation | young parietal cell | N(+) | N(+) C(+) | | N(-) C(+) | N(-) C(±)~(-) |
| | parietal cell | N(+) C(±) C(-) C(++) | N(+) C(-) C(+++) | | N(-) C(++) | N(-)(±) C(-) |
| | mucous cell (in pit) | N(+) C(-) C(±) C(±) | N(+) C(+) | C(+)~(++) | | N(-)~(+) C(+) |
| | basal clear cell | N(+) C(-) C(-) | N(+) C(-) | | | N(±) C(-) |
| birth a.b.4W stage of gastric chief gland formation | young chief cell | N(+) | N(+) C(+) | | | N(+) C(+) |
| | chief cell | N(+) C(++) | N(+) C(+++) | | | N(+) C(++) |
| | basal granular cell | N(+) | N(+) C(+) | | | |
| | | | | | C···cytoplasm N···nucleus | |

**Fig. 1** Differentiation and stainability of gastric epithelium cells of rat embryo

**5. Embryo On Gravid Day 18**

The cells located at the border of the columnar cells bundle are smaller and curve themselves outward to form the entrance of the urn as the gastric pit, the cells located nearer to the center of the columnar cells group are taller and are going to show a greater contraction of their infranuclear cytoplasma, so that the basal membrane bulges up like a tent, thereby the cut surface of the basal membrane presents wave profile.

a. Surface mucous cells

Secretory granules can be divided into two groups of high and low electron density, but between the two there is no continuity of electron density nor is there any regularity in their distribution areas. Secretory granules are often intermingled with mitochondria in the supranuclear area. But in the case where the diagonally-crossing filament structure in supranuclear area is distinct, there can't be seen any mitochondria and polysomes in the surface side of this filament structure[8)]

b. Young parietal cells

In such a young parietal cell whose mitochondriocytoplasmic ratio has reached over 50% the volume of intracellular canaliculli increases promptly, of which in consequence increases the cell volume and the cell body is pushed toward the basal membrane, thus their free surface has the tendency to be dented from gastric gland

lumen and to be narrow, on the contrary their face in contact with basal membrane becomes greater than in the case of other kinds. Their nuclear membrane often shows a few smooth waves of a small amplitude, and their nuclear fine granules show a greater tendency to aggregate onto the inner nuclear membrane than in cells of other kinds. As mitochondria markedly increase in number, the mitochondria become more uniform, smaller in size and their shape approaches a perfect sphere. Intracellular canaliculli repeated the fusion secondarily and they develop as to enclose their nucleus as a whole. The rER's do not increase over 3%, whereas the number of rER's and Golgi apparatuses decrease in an inverse proportion to the number of mitochodria.

c. Young mucous cells

These cells are generally smaller than surface mucous cells, and their shape varies as some are curved and others spherical. At this gravid stage the young mucous cells are distributed in or near the pit structures. Although the young mucous cells possess PAS positive secretory granules, they still retain some of the characteristics of undifferentiated cell : the fine granules of nucleoplasm don't aggregate so much, mitochondria and rERs are less in number. Occasionally Golgi apparatus occupies a greater portion of their cytoplasm, in which the secretory granules are encompassed. Size and shape of these secretory granules are more variable -than surface mucous cell's.

**6. Embryo On Gravid Day 19**

Along with the increase in the number of the cells constructing the gastric pit, PAS weak positive cells increase in gastric pit.

a. Undifferentiated cells

By degrees the occupation rate of undifferentiated cells in all the gastric epithelium cells has decreased. Even in the undifferentiated cells themselves, there can be observed slight changes: such as nuclear membrane with small amplitude waves, a slight aggregation of fine granules onto the nuclear inner membrane, and slightly unhomogenous distribution of the nucleoplasm, in comparison with the undifferen tiated cells on early gravid day.

b. Surface mucous cells

In some cells whose supranucleocytoplasm are filled with numerous secretory granules, their granules are uniform in size and have become smaller. Such a mature cell gives a dark tone over the entire cell due to the grossness and concentration of free ribosomes.

c. Parietal cells

The majority of cells belonging to the parietal cell series contain mitochondria that occupy as much as over 50% of their cytoplasm. the interdigitations become marked, and even in the interdigitation some desmosomes are well developed. Near the nuclear membrane pore the aggregation of nuclear fine granules to inner nuclear

membrane are brocken off with funnel-like crevice, which by this time becomes especially distinct. Sometimes the intracellular canaliculli retain thin septums after their fusion, but on the whole the Icc are continuous with each other as to surround their nucleus.

d. Mucous cells

They retain the characteristics of undifferentiated intracellular structure, while there is no fixed tendency in cell body shape.

No mucous cells contain so much secretory granules as the surface mucous cells, but they have rERs and Golgi apparatuses of more developed type than the surface mucous cells'.

**7. Embryo On Gravid Day 20**

a. Undifferentiated cells

Since these cells are intermingled among the other kind cells which have the large intracellular pressure, they sometimes present variegated shapes but it is seemed that their fundamental shape is eggplant-like.

b. Surface mucous cells

In the case of the surface mucous cell whose supranuclear cytoplasm is filled with secretory granules, its supranuclear cytoplasm is not stained by methylenblue and presents semi-transparency, but it can be stained deep with PAS. The most mature cell does not show distinctly any rER, Golgi apparatus, nucleolus and nuclear fine granules, and their nuclear membrane becomes less smooth, presenting undulations like saw-teeth but has not any deep invagination.

c. Parietal cells

In the parietal cells having mitochondria over the occupation ratio 70 % of their cytoplasm, the number of of mitochondria is roughly in an inverse proportion to the NC ratio, while it is directly proportional to total volume of the intracellular canaliculli.

d. Basal clear cells

Around the base of gastric pit there appear a few of small and round cells with clear cell body. Their free surface can't be recognized in any specimens and they are embedded among cells of other kinds. Their cell boundary is simple and their cell membrane is very smooth and spherical in figure.

There are desmosomes but no terminal bar. Wavy nuclear membrane and nucleoplasm aggregation onto the nuclear inner membrane are marked from the beginning of their differentiation. Its mitochondrion size is small in proportion to its cell -body size and dimensions of all the mitochondria exist in less than 5% in dimensions of its cytoplasm on a side view and the free ribosomes are also less, so that its cytoplasm is markedly light.

**8. Embryo On Gravid Day 21.**

In some places, the bottom of gastric pit bulges spherically toward the submucosa tissue.

**9. Embryo On Gravid Day 22**

a. Cells containing relatively many rERs

In the embryos on gravid day 22, i.e. in the date immediately before birth, there appear sometimes cells of which cytoplasm stain relatively deep with methylenblue. This cell is negative with pepsinogen stain, but electronmicroscopically, there's no cell which has better developed rERs except this cell, so far appeared until this gravid stage. In this cell there can be observed rERs arranged concentrically around the nuclear membrane and occasionally in parallel with the mitochondria outer membrane. Since their rER layers are thinner as compared with the rERs of chief cells of a mature rat, and the cells have some secretory granules of high electron density, this cell is difficult to distinguish definitively from the young mucous cell.

b. Parietal cells

Free ribosomes and other organellei being compressed by numerous mitochodria become denser, resulting in a darker tone of cytoplasm, but the electron density of their cytoplasm is not as large as it after the first suck.

**10. Newborn Animal, One Day Old**

(a) Columnar～pyramidal cells possessing PAS positive granules, i. e. surface mucous cells, (b) acidophilic large cells, i, e, parietal cells, and (c) basophilic small cells occupy respectively about one third of whole the gastric epithelium cells. Since the last group includes the undifferentiated cells, the mucous cells and a few of endocrine cells, their shape and stainability with methylenblue vary among them. But the cells that stain deep basophilic, as observable in adult rat, have not appeared. Gastric pits are completed at the corpus of stomach, and at its oral side the buds of gastric chief gland are swelling up from the bottoms of gastric pits. As it gets near the pyloric area, the gastric pit is still imcomplete where the number of acidophilic cells decrease, in exchange for acidophilic cells there are large round cells that stain deeply with neither basophilic nor acidophilic, these later cells contain many mitochondria, resembling parietal cells in the process of their growth, but they have no intracellular canaliculli.[9]

On one day old already the nuclei of some surface mucous cells have shrunken and their nuclear membrane has formed small pointed waves and their nuclear fine granules have become one mass of high electron density.

After birth the parietal cells being filled up with mitochondria increase abruptly eosinophilic stainability and suddenly get high electron density. Electron density of the cytoplasmic particles at the interspaces among mitochondria becomes so marked that mitochondrioplasm appear light in contrast. Owing to the addition of mitochondria number and enlargement of their canalicullar lumen, these parietal cells expand secondaryly in volume.

**11. Newdorn, 4 Days Old**

From the bottom of one gastric pit there can be recognized single or sometimes plural gastric chief gland growing out, and there are some differences in their growth even between a gastric chief gland and its neighboring gastric chief glands, but the growth of the gland is usually faster near the boundary of nongladular area and slower toward the caudal side.

The average depth of the chief glands is 2~2.5 times that of their gastric pit.

At this time the polysomes in basal clear cells are observed accumulating like the initial substance of the secretory granules in basal granular cells[8].

**12. Newborn, 9 Days Old**

The gastric chief gland near the boundary of nonglandular stomach has grown to the depth 3~4 times (cell number : 15~20) that of gastric pit, and the number of gastric chief glands has increased and also the interspaces among the glands are tighter. The deeper half of gastric gland is composed mainly of basophilic cells, the middle one fourth is occupied mostly by parietal cells, at the gastric pit that occupies surface side 1/4 of the whole gastric gland the surface mucous cells have been predominant in number. Towarder caudal side the gastric gland becomes shallower, decreasing the deepest layer taken mainly by basophilic cells.

**13. Newborn, 22 Days Old**

The distribution area of parietal cells widers precipitously, and this tendency is most marked at the oral side where the growth of gastric glands is most rapid.

The nuclei of the most mature parietal cells (their cytoplasm is filled up at all with mitochondria and gets high electron density) have shrunken and the nuclei often can't be observed in section specimens.

The cells which are deeper in basophilic stainability appear someplaces.

**14. Newborn, 31 Days Old**

These day's grastric chief gland has grown to the depth 5~6 times of their gastric pit's depth. The deepest one third~fourth of the gastric gland is occupied generally by chief cells that stain deep with methylenblue, among which are intermingled a few parietal cells, endocrine cells also become conspicuous at these areas. At the middle of the gastric gland, parietal cells, mucous cells having PAS positive granules and undifferentiated cells are to intermingle, but the deeper middle of the gastric glands have an inclination to be mainly built of parietal cells, and the upper midle mainly of mucous cells and undifferentiated cells. The gastric pit (surface one sixth of gland) is occupied by surface mucous cells. The gastric glands at this 31 days old are similar to them of a adult rat.

## V. Discussion

** At the embryo of rat the first period when mucous secretory cells, hydrochloric acid secretory cells and zymogen secretory cells specialize from undifferentiated cells differs with each kind of the cells. They come in sight as the blast cells

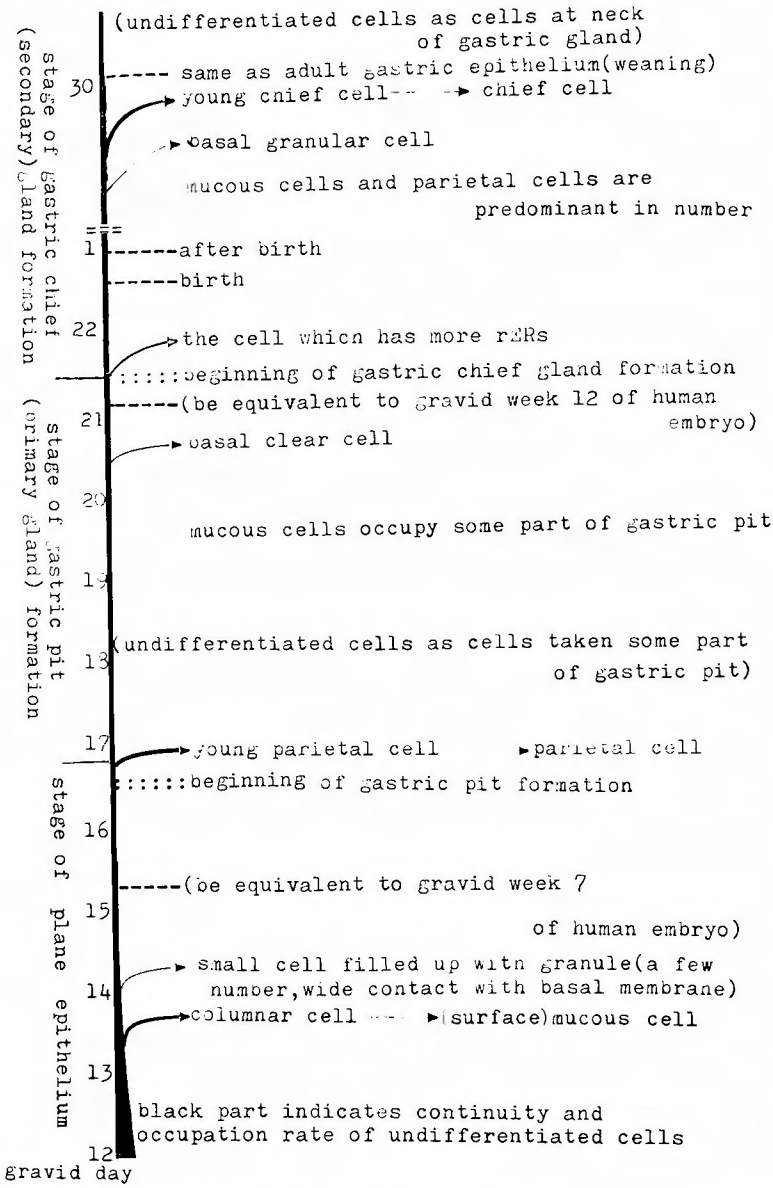


**Fig. 2** Genetic process of gastric epithelium cells of rat embryo.

(the youngest type cell for them)and gradually come to maturity (gradual differentiation).

* It would be said that the earliest differentiated cell is the columnar (somtimes pyramidal) cell appearing around gravid day 14 and they line the smooth basal membrane, since the columnar cells have the direction to be grown into the mucous secretory cells. At the early stage of the gastric pits to appear, the parietal cells have differentiated, At the terminal stage of embryo the gastric pits are finished

and the parietal cells predominate. A rat's delivery is made at the stage corresponding to gravid week 12~13 in the epithelium of human embryo's stomach. The early gastric chief glands of rat are mainly composed after birth. And in the process up to their chief gland formation, the chief cells undergo their differentiation. By about one month after birth i. e. at the weaning period, the gastric glands are finally completely. In other words, the "stage of plane basal membrane" corresponds to the differentiation-term of mucous cells, and the "stage of gastric pit formation (primary gland formation)" to that of parietal cells, and the "stage of gastric chief gland formation (secondary gland formation)" to that of chief cells. That is to say, if it were true that ontogenesis repeat phylogenesis the mucous cells would be old, while the chief cells would be young phylogenetically.

* Existence of the undifferentiated cells can we electronmicroscopically prove in gastric epithelium at any generations including the embryos. At the surface of gastric ulcer, the development of the regenerative epithelium which stem from such undifferentiated cells at the margin of ulcer is morphologically same as the development of the gastric epithelium in the embryo. There are to certify as follows: such a continuity of undifferentiated cells starts from the earliest gastric epithelium of embryo and it persists as the cells in "generative cell zone" of the gastric epithelium in adult animal. Therefore, at the ulcer regeneration also the ontogenesis is repeated.

** Gastric epithelium cells can be divided into three groups according to their functions:

function-(1)···Ability for mitosis and proliferation.

function-(2)···Ability to form gastric glands (pit+chief gland).

function-(3)···Ability to produce secretory substance.

* The phenomenon that the undifferentiated cells increase in number and become densely populated at "the stage of plane basal membrane" indicates clearly these undifferentiated cells have the function-(1.)

Soon afterward the majority of undifferentiated cells transform into columnar cells and they make the groups of about a score cells and become to contain PAS positive granules. The cells located in the middle of a parachute shape group of these colmnar cells are more matured, while the cells located nearer to the periphery of a bundle of the columnar cells or nearer to the gastric pit are lesser matured, it can be assumed that they are replenished from the undifferentiated cells. Namely, at an early stage before gastric pits are completed, some of the columnar cells themselves lose the function-(1), they come to possess the function-(3) without ever acquiring the function-(2.)

Since the gastric glands (pit+chief gland) for the most part are consisted of the undifferentiated cells at the earliest stage of glands the undifferentiated cells

have both the function-(1) and function-(2.) Subseguently, parietal cells and mucous cells appear among the undifferentiated cells composing the gastric pits, therefore, parietal cells and mucous cells have ability to enclose mutually gland lumen, they possess simultaneously the function-(2) and the function-(3). While we can't clarify electronmicroscopically whether the parietal cells and the mucous cells have the function-(1) or not.

* In relations to function of the undifferentiated cells, there are two different conceptions: The one that these cells possess the function-(1) by nature and the function-(2) appears later in the process of their growth. The other that they possess both the function-(1) and the function-(2) from the beginning, but depending upon the environmental conditions the function-(2) is inhibited from appearing.

The first opinion means that there are the grades of cell's growth even among the undifferentiated cells of gastric epithelium. This idea can't be completely ruled out because of the morphological differences between the undifferentiated cells of early embryonic stage and those cells of the terminal stage, especially the difference between their nuclear membrane is remarkable. For this reason, in the regeneration of gastric ulcer it would be thought that the youngest undifferentiated cells that possess only the function-(1) in all the undifferentiated cells at the margin of ulcer line gradually over ulcerous surface and subsequently get the function-(2).

The second theory has probability, the reason is that the regenerativc cells at the initial stage of gastric ulcer are derived from those undifferentiated cells that constructed gastric glands on the margin of ulcer, and repeat the process which pursue at gastric epithelium of embryo on the ulcerous surface. They naturally have the function-(2), but extracellular conditions (ulcerous surface etc.) can be thought to have inhibited the appearance of the function-(2).

** In any case, the regeneration of gastric ulcer is commenced by the undifferentiated cells, and go through same process as course which the undifferentiated cells of early embryonic stage passed by. From this fact that the ontogenesis is repeated at the regeneration of gastric ulcer, it may safety be said that there would be no essential difference between the characters of the undifferentiated cells observable in the gastric glands of adult animals and the characters of the undifferentiated cells of gastric epithelium at the initial embryonic stage. Therefore, in the physiologic gastric epithelium tissue at any generations, it seems certain that "the pathway of the differentiations of gastric epitheium cells" as shown in Fig. 2 are repeatedly carried out.

** From the fact that the beginning of differentiation to a certain gastric epithelium cell is recognized for a tiny change in the fine structures of the undifferentiated cell's cytoplasm and subsequently the transformations of its cytoplasmic organoids gradually strengthen toward the fixed direction to be a certain mature cell, there can be understood that the irregular shapes in the cytoplasm of a patho-

logic gastropithelium cell, especially cancerous, arise from that its early cytoplasmic organoids are inhibited on the way to their development or don't progress to the definite direction for their normal growing.

## VI. Acknowledgement

Grateful acknowledgement is made to prof. Sanae Tanaka and lect. Takuro Ogata, the Ist Surgical Department, Okayama University, Medical School, for their invaluable advice in various phases of this work.

This paper was partly presented at the 27th Congress of the Japanese Cancer Association in 1968. and at the 9th Congress of the Japanese Histochemistry Association in 1968.

## VII. References

1) B. Elizabeth Horne et al : Food habits and gastric morphology of the grass hopper mouse, J. Mammalogy, **45**(4) : 531-535, 1965.
2) Masatake Imai et al : Histological and histochemical investigations on the stomachs in japanese monkey and some other kinds of animals, Okajimas Fol. Anat. Jap., **40**(4~6) : 481-495, 1965.
3) Kirk, E.G. : On the histogenesis of gastric glands, Amer. J. Anat., **10**(4) : 474-520, 1911.
4) Helander, H. E. : Ultrastructure of gastric fundus glands of refed mice, J. Ultrastructure Res., **10** : 160-175, 1964.
5) Susumu Ito et al : The fine structure of the gastric mucosa in the mouse, J. of Cell Biology, **16**:541-557, 1963.
6) R.J. Stephens and C.J. Pfeiffer : Ultrastructure of the gastric mucosa of normal labolatory ferrets, J. Ultrastructure Res., **22** : 45-62, 1968.
7) Yoshiaki Yuri : Study on the material fixation for electronmicroscope, J. of Electronmicroscope Association, **19**(1) : 58-60, 1963.
8) Tomio Matsumoto : The electronmicroscopic studies on the characteristics of the gastric gland cells, Nat. Def. Med. J., **19**(2) : 37-44, 1972.
9) Tomio Matsumoto : Electronmicroscopic studies on the pyloric gland cells, Nat. Def. Med. J., **20**(8) : 311~316 1973.
10) Tomio Matsumoto : Studies on the regenerative process of gastric ulcer, Nat. Def. Med. J., **188** : 311-318, 1971.

## 和文抄録

# ラット胎児の胃上皮細胞の分化と成長過程についての電子顕微鏡的研究

松　本　富　夫

ラット胎児の胃上皮の成長過程における細胞の微細構造の変化から，その分化を探った。胃上皮の生長過程には，3つの大きな変遷がある。

その1期は，未分化細胞が平面な基底膜の上に並列に並び，腺構造を全く作らない時期である。胎児令2週頃から，この未分化細胞の多くが，円柱状に移り，つづいて分泌顆粒を持ちはじめ，粘液分泌系の細胞へと進む。

2期は胎児令2.5週頃から始まり，多数の並列に並ぶ円柱状細胞群の中の所々に，互に壺状に配列しようとする傾向を持つ未分化細胞が顕著になる，つまり1次腺たる胃小窩の形成が始まる。この時すでに，未分化細胞様の形態を保ってはいるが，胞内に空洞を持った細胞が見られる，つまり壁細胞の分化の最初は，未分化細胞の微細構造の一部の小さな変化としてとらえられる。この空洞は，ミトコンドリアの増加に平行して，融合を繰り返し，細胞内細管に成長し，壁細胞は成熟する。つまり小変化が一定方向に増強する。

3期は，胎児令3週頃から始まる．すなわち胃小窩底から，2次腺たる胃主腺が出芽，成長し，主細胞が分化する時期である。ラットの場合は，この期が，離乳する生後4週頃まで続く。

胃潰瘍においても，その修復過程は，上述の胎児における胃上皮の生長過程と同様の過程を繰り返す。このことから，どの世代にも常に，個体発生の部分である胃上皮発生過程を繰り返す能力を有する細胞が存在し，この細胞は，どの世代にも常に存在している未分化細胞である可能性が大きい。

また，正常胃腺においても，細胞補給過程として，胎児に見られる過程と本質的には同じ細胞分化過程が繰り返えされていると考えられる。

### Abbreviation

BM……Basal Membrane
CC……Chief Cell
CM……Cell Membrane
Cr……Cristae
D……Desmosome
eGP……Early Gastric pit
eIcc……Early Intracellularcanaliculli
ER……Endoplasmic Reticulum
FR……Free Ribosome
FS……Free Surface
G……Golgi Apparatus
GCG……Gastric Chief Gland
GP……Gastric Pit
Icc……Intracellularcanaliculli
L……Lumen
M……Mitochondria
MC……Mucous Cell
Mv……Microvilli
Mt……Mitosis
N……Nucleus
NM……Nuclear Membrane
No……Nucleolus
Np……Nucleoplasm
P……Polysome
PC……Parietal Cell
rER……Rough Endoplasmic Reticulum
SC……Submucosal Cell
SG……Secretory Granule
Sm……Submucosa
SMC……Surface Mucous Cell
TB……Terminal Bar
UC……Undifferentiated Cell
ySMC……Young Surface Mucous Cell

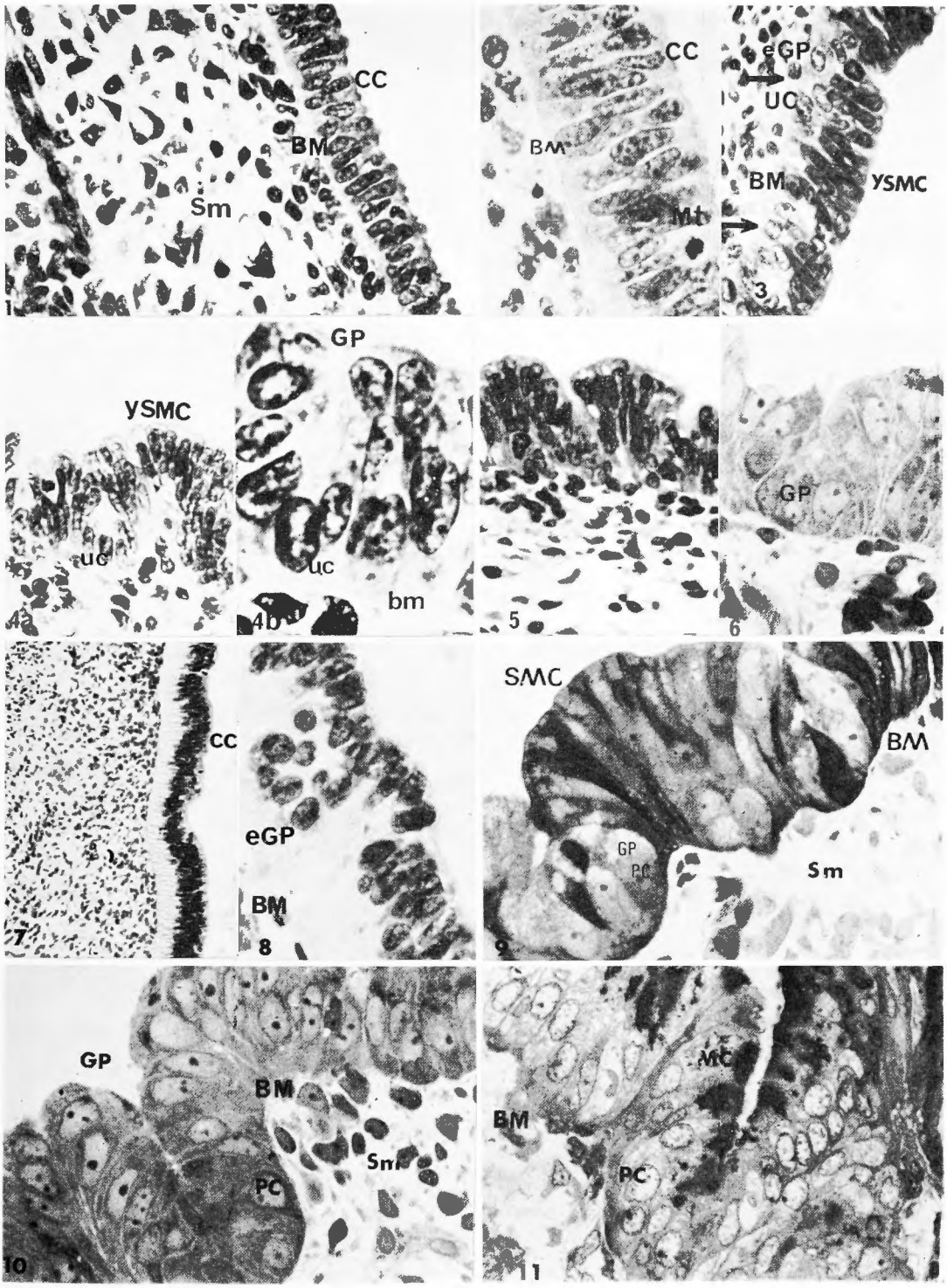
CC
BM
Sm
1
CC
BM
Mt
eGP
UC
BM
YSMC
3
YSMC
uc
4a
GP
uc
bm
4b
5
GP
6
CC
7
eGP
BM
8
SMC
BM
GP
PC
Sm
9
GP
BM
Sm
PC
10
MC
BM
PC
11

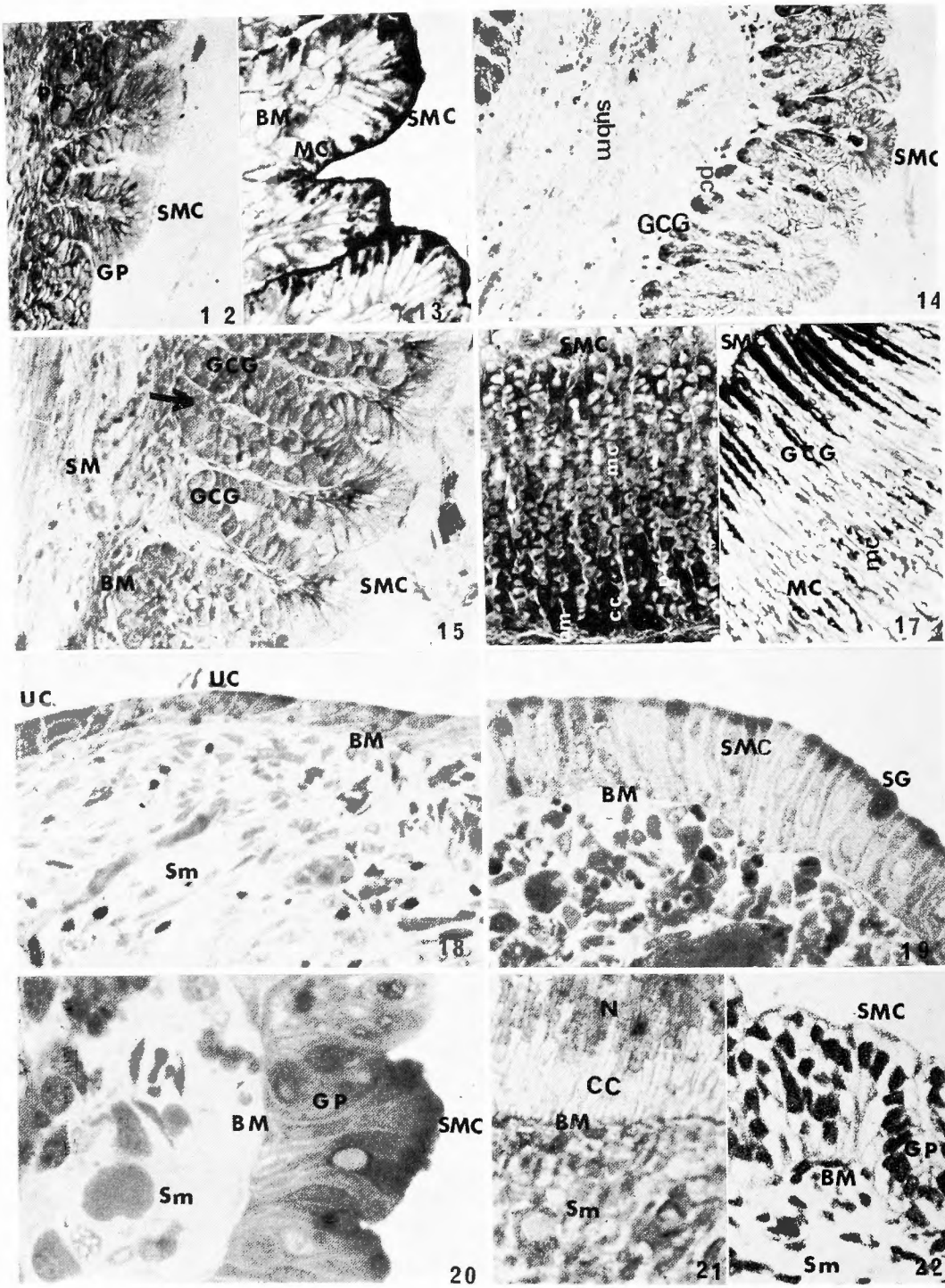
SMC
GP
12
BM
SMC
MC
13
submucosa
pc
GCG
SMC
14
GCG
SM
GCG
BM
SMC
15
SMC
mc
cc
Sm
SMC
GCG
pc
MC
17
UC
UC
BM
Sm
18
SMC
SG
BM
19
GP
BM
SMC
Sm
20
N
CC
BM
Sm
21
SMC
GP
BM
Sm
22

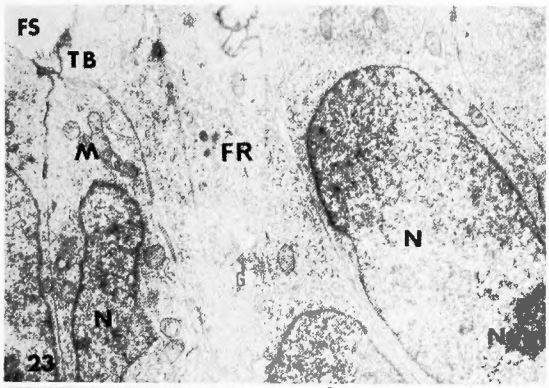
FS
TB
M
FR
N
N
N
23

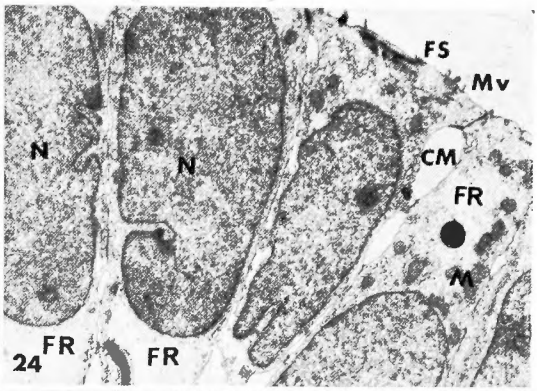
FS
Mv
N
N
CM
FR
M
FR
FR
24

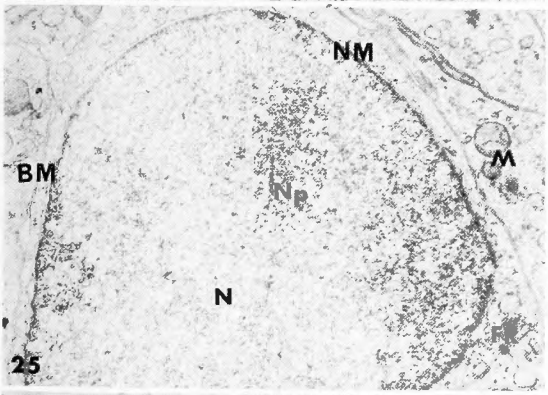
NM
M
BM
Np
N
25

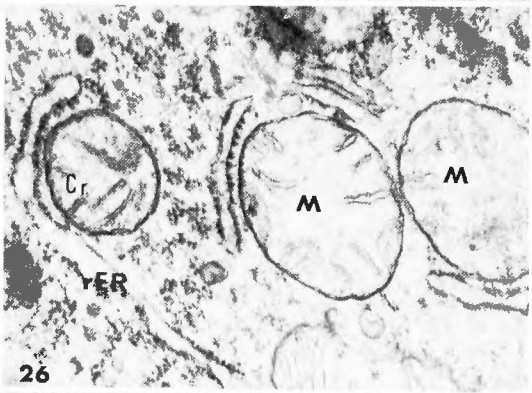
Cr
M
M
rER
26

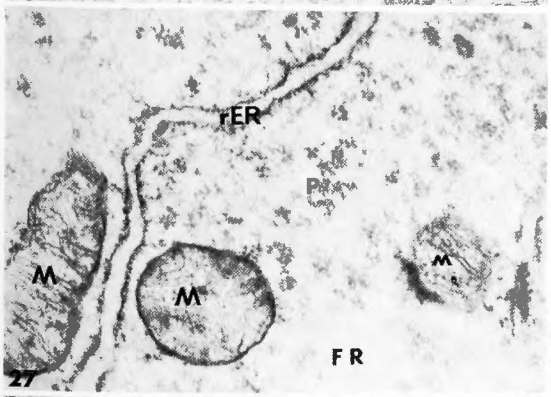
rER
P
M
M
M
FR
27

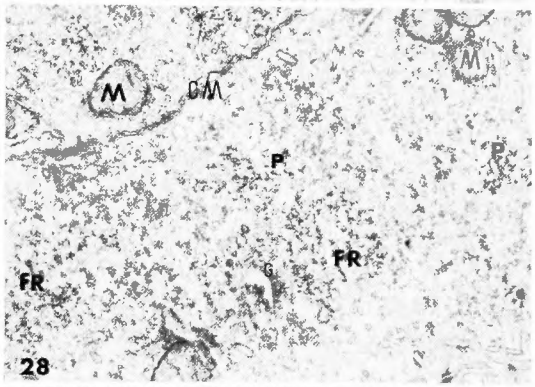
M
CM
M
P
P
FR
FR
28

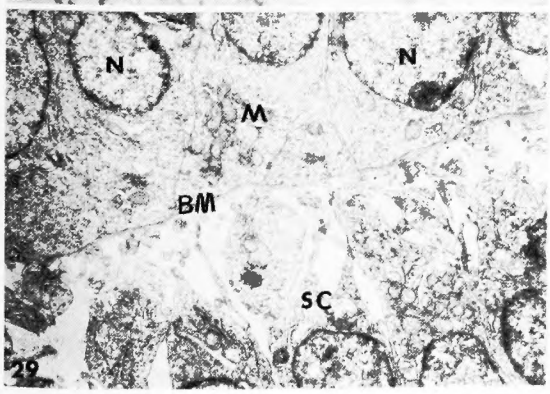
N
N
M
BM
SC
29

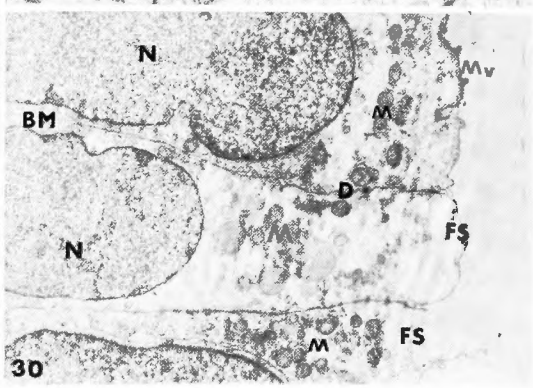
N
Mv
BM
M
D
FS
N
M
FS
30

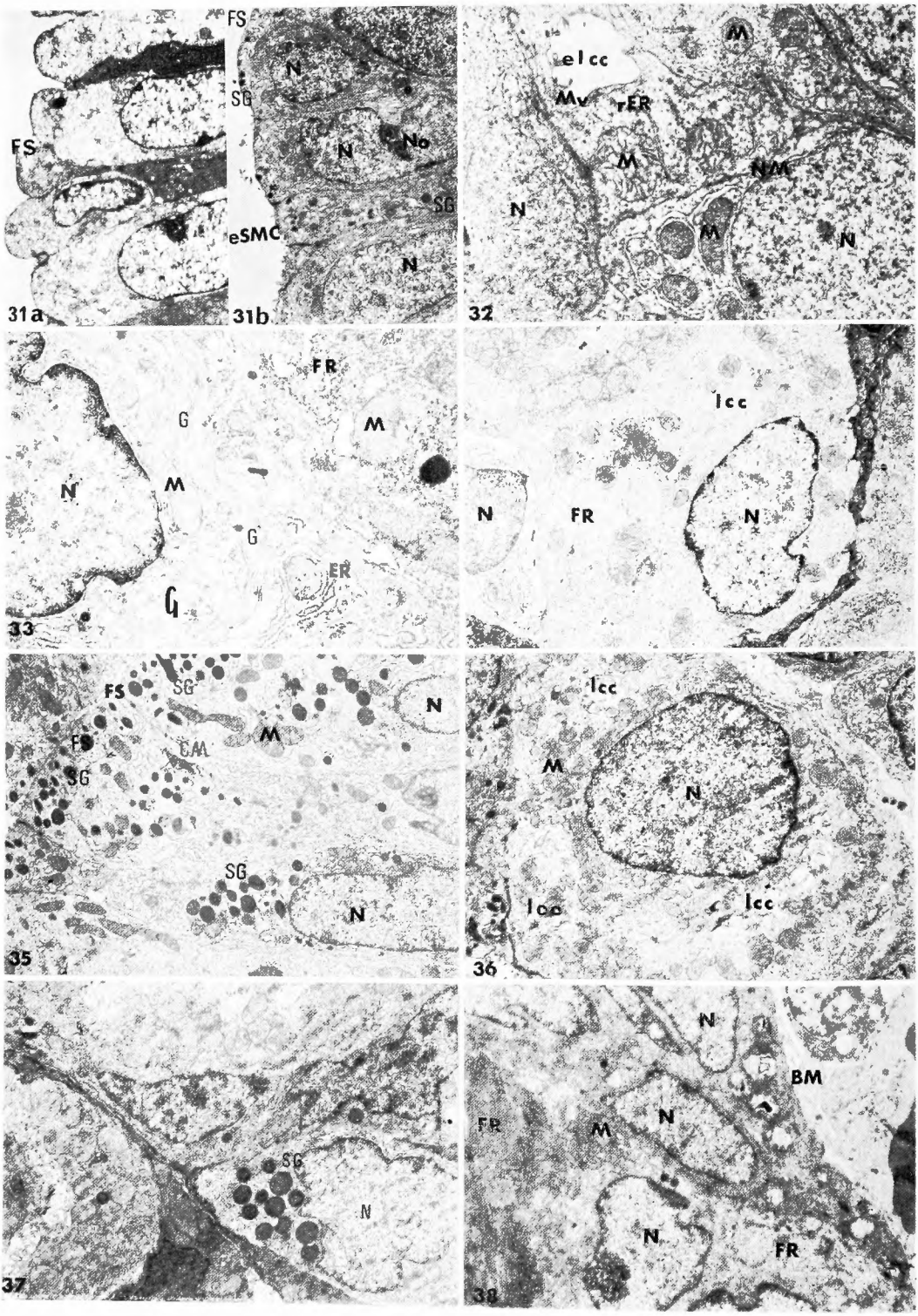
FS
FS
31a
FS
N
SG
N
No
SG
eSMC
N
31b
M
elcc
Mv
rER
M
NM
N
M
N
32
FR
G
M
N
M
G
ER
G
33
Icc
N
FR
N
FS
SG
N
FS
CM
M
SG
SG
N
35
Icc
M
N
Icc
Icc
36
SG
N
37
N
BM
FR
M
N
N
FR
38

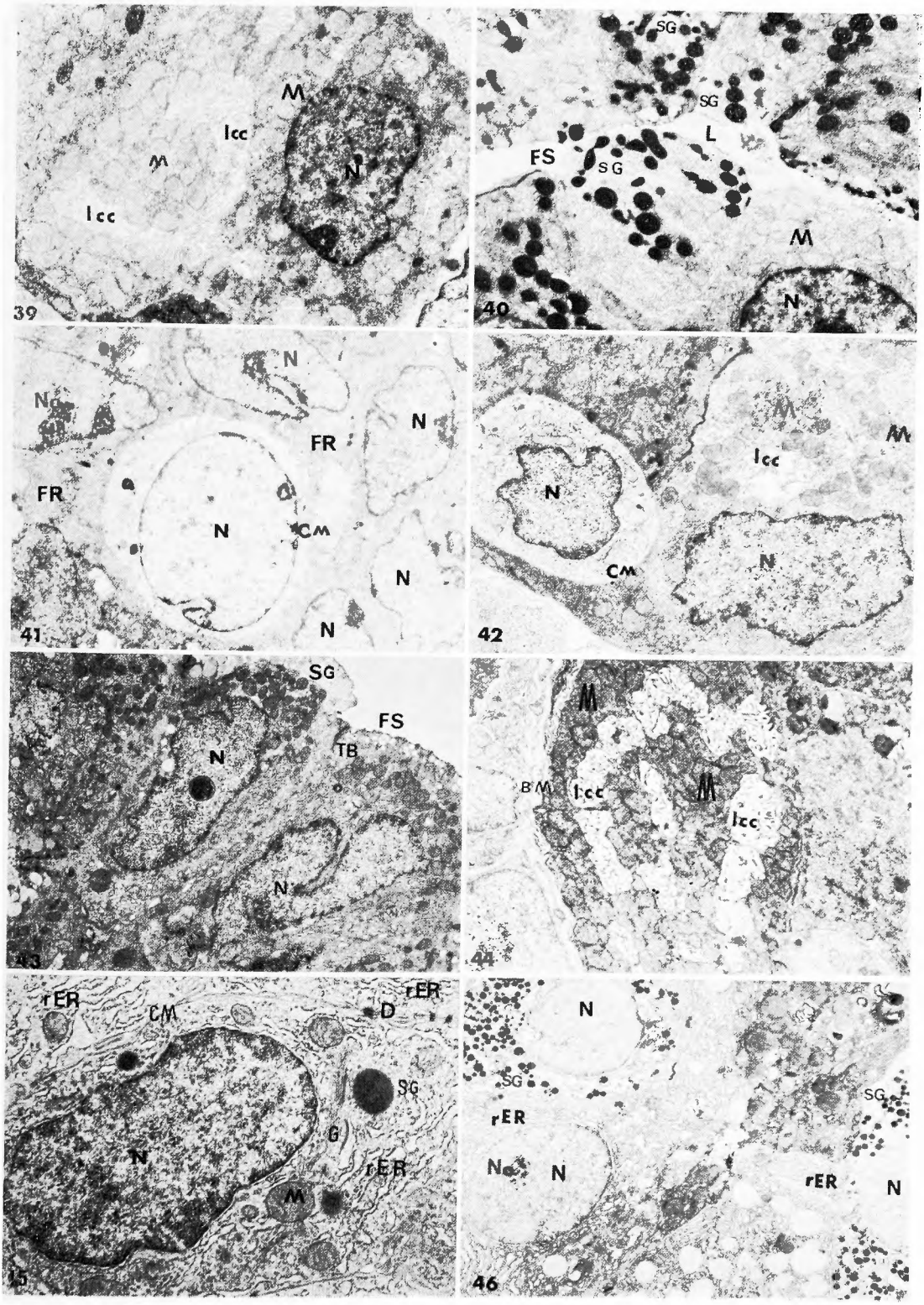
M
Icc
M
N
Icc
39
SG
SG
L
FS
SG
M
N
40
N
Nc
N
FR
FR
N
CM
N
N
41
M
M
Icc
N
CM
N
42
SG
FS
N
TB
N
43
M
BM
Icc
M
Icc
44
rER
CM
D
rER
SG
G
N
rER
M
45
N
SG
rER
SG
Nc
N
rER
N
46

**Explanation for Micrograph.**

1 and 2. Epithelium on gravid day 15.
The cells with a large nucleocytoplasmic ratio are distributed on the plane basal membrane in a monolayer. (HE, X400, X1000)

3. Early gastric pits on gravid day 16.
Some cells tend to align in an urn shape, the arrows indicate the early gastric pits. (HE, X400)

4a. Epithelium on gravid day 17.
Some of columnar cells get already a few secretory granules, and have a tendency to make the group of several themselves. (HE, X400)

4b. Gastric pit on gravid day 18. (HE, X1000)

5. Epithelium on gravid day 19.
Bundle of columnar cells show a parachute-shape. (HE, X400)

6. Epithepium on gravid day 20.
Through a electronmicroscope there can be recognized many parietal cells in gastric pit. (Toruisineblue, X400)

7. Epithelium on gravid week 7 of human embryo.
Most of their nuclei are located near their free surface, and their nuclei take well methylenblue. (ME, X400)

8. Early gastric pit on gravid week 9 of human embryo. (HE, X400)

9. Gastric epithelium on gravid week 11 of human embryo.
The epithelium are filled with mature parietal cells in the gastric pits and mature surface mucous cells. (Tb, X1000)

10. The epithelium on gravid day 21. (Tb, X1000)

11. PAS positive cells: surface mucous cells and mucous cells on gravid day 22. (PAS, X1000)

12. Eithelium on one day after birth.
The parietal cells are found for deep acidophilic, large cells and mucous, undifferentiated and endocrine cells for basophilic cells. (ME, X400)

13. Mucous cells on 3 days after birth.
PAS positive cells are extensively distributed now. (PAS, X1000)

14. Parietal cells on 3 days after birth.
At the pit's bottom or the gland neck and the apex of early gastric chief gland the parietal cells are for sudan BB positive cells. (SudanBB, X400)

15. Gastric glands on 4 days after birth.
In some places more than one gastric chief gland arrow sprout from the bottom of a gastric pit. (ME, X1000)

16. Gastric glands on 31 days after birth. The deepest one fourth of gland is occupied mainly by chief cells, parietal cells are noticed for eosinophilic cells. (ME, X400)

17. Epithelium on 31 days after birth.
At the deeper areas of the glands also there can be seen PAS positive cells. (PAS, X400)

18, 19, 20. The regenerative cells of human gastric ulcer.
The ontogenesis of gastric epithelium which was performed in embryo are repeated at the regeneration of ulcer. (Tb, X1000)

21 and 22. Epithelium on gravid week 8 and 12 of human embryo (ME, HE, X1000, X400)

23. Undifferentiated cells on gravid day 14.
The cells which are oval~elliptical and have a large nucleoplasmic ratio epuip with a little desmosomes and advanced terminal bars, neither infolding nor interdigitation in their cell membrane. (X5000)

24. Undifferentiated cells on gravid week 7 of human embryo.
The greater part of nuclear membrane has smooth spherical surface, sometimes with a deep invagination. (X5000)

25. Undifferentiated structure on gravid day 14.
The nuclear fine gnanules form small aggregates, which become crossed with another,

and make networks. But being smaller and denser, they're recognized to be homogenous. (X7000)

26. Mitochondria on gravid day 14.
Mitochondria with poor crista on the cut surface are less than 5% on the section of cytoplasm, and their shape and size are not uniform. (X10000)

27. Rough ERs on gravid day 14.
R-ERs are less than 2% and short ones are distributed separately, their shape varies from tubular to vacuolar structure. (X10000)

28. Polysomes, ribosomes and Golgi apparatus on gravid day 15
Polysomes, fiber and other free ribosomes are distributed evenly. The Golgi vacuoles are often swollen. (X10000)

29. Basal membrane area of gastric early epithelium.
Basal membrane are recognized for the crosses of short fine filaments, hardly connected with the submucous tissue. (X7000)

30. Columnar cells on gravid day 15.
The cell keeps the many characteristics which be undifferentiated in it's ultrastructures. (X5000)

31a and 31b. Columnar cells (young surface mucous cells) on gravid day 16 and 17.
In contact with free surface a few secretory granules with high electron density distribute. (X3000, 5000)

32. Early parietal cell on gravid day 17.
It's the first time that the cells showing the cut surface of early intracellular canaliculli with some microvilli appear. (X7000)

33. On gravid day 18. The early mucous cell.
The cell which possesses a few secretory granules and well developed Golgi appratus. (X7000)

34. Young parietal cells on gravid day 18.
Their cytoplasm appears electronmicroscopically light because of the scarcity of free ribosomes, and their nuclear fine granules show already a tendency to aggregate onto the inner nucleus membrane. (X7000)

35. On gravid day 19 surface mucous cells
Their nuclei diverge from their free surface, and secretory granules are increased at the supranuclear area. (X5000)

36. Young parietal cell on gravid day 19.
According to the developments of Icc and mitochondria, the cell transfoms from the sphere to the cuboid. The discontinuous early Icc line around it's nucleus. (X7000)

37. Early mucous cell on gravid day 19.
They're seen among many parietal cells. (X5000)

38. Undifferentiated cells on gravid day 19.
They present variegated shapes and a few waves of nuclear membrane. (X5000)

39. On gravid day 20 parietal cells.
Parietal cell with numerous mitochondria and well developed Icc shows the aggregations of nuclear fine granules for the chromatin concentration in its nucleus. (X5000)

40. Mucous cells on gravid day 20.
The shape and size of their secretory granules are not uniform in comparison with the surface mucous cells'. (X5000)

41. Undifferentiased cells and young basal clear cell on gravid day 20.
The cell membrane of basal clear cell expands like a balloon. (X5000)

42. Basal clear cell on gravid day 21.
It equip with a few desmosomes but terminal bar on smooth cell membrane, and it's free ribosomes and other organelle are less so that the cytoplasm is markedly light. Their nucleus membrane often shows a few waves of large amplitude. (X5000)

43. On gravid day 22 surface mucous cells. (X5000)

44. Mature parietal cell on gravid day 22.
Free ribosomes and other organelle being compressed by numerous mitochondria become

denser, resulting in a darker tone of its cytoplasm. In places of canaliculus there can be seen "canaliculus pillar". (X7000)

45. The cell containing more rERs on gravid day 22.
There can be observed rERs arranged concentrically around the nuclear membrane. (X7000)

46. On 31 days after birth chief cells and basal granular cells.
Chief cell's nucleoplasm is kept to be homogenous for longer time. In basal granular cell's granules there're the continuous degrees from that has a high electron density and clear limit to low and dim margin. (X5000)