

## Posterior Interosseous Nerve Palsy as a Complication of Monteggia Fractures

KIYOSHI YAMAMOTO, YOSHIAKI YANASE and MITSUO TOMIHARA

Department of Orthopaedic Surgery, Faculty of Medicine, Kyoto University

(Director : Prof. Dr. TETSUO ITO)

ATSUSHI FUJITA, YASUO SAIDA and ICHIRO KOHNO

Department of Orthopaedic Surgery, Ohtsu Red Cross Hospital

Received for Publication Nov. 20, 1976

Acute palsy of the posterior interosseous nerve as a complication of fresh MONTEGGIA fractures have been noted by several authors<sup>1)4)7)10)12)14)</sup> BOYD and BOALS<sup>4)</sup> in 1969 reported five cases of posterior interosseous nerve palsy out of 159 cases of MONTEGGIA fractures. This is a relatively rare complication in this injury, although SMITH<sup>10)</sup>, STEIN<sup>14)</sup> and ADACHI<sup>1)</sup> reported high incidence of this condition. So-called tardy or delayed palsy of the posterior interosseous nerve as a result of non-treated or maltreated MONTEGGIA fractures has been reported by only two authors, ADAMS and RIZZOLI<sup>2)</sup> in 1959 and LICHTER and JACOBSON<sup>6)</sup> in 1975. This is a extremely rare condition in clinical practice.

### Anatomy

The posterior interosseous nerve is a motor branch of the radial nerve. The radial nerve divides into a terminal motor (posterior interosseous or deep radial nerve) and a terminal sensory (superficial radial nerve) branch, usually at the level of the radiocapitellar joint. The posterior interosseous nerve enters the substance of the supinator muscle and passes dorsolaterally around the radial head between the two layers of the supinator (superficial and deep head). It gives off motor branches to the extensor carpi radialis brevis and the supinator at the level of the radial head. After emerging from the supinator, it divides into multiple motor branches. The basic pattern of division consists of two major components—those innervating the extensor digitorum communis, the extensor digiti minimi proprius and the extensor carpi ulnaris and those supplying the abductor pollicis longus, the extensor pollicis longus and brevis, and the extensor indicis proprius. It is the area where the posterior interosseous nerve, as mentioned above, passed dorsolaterally around the radial head where it is most susceptible to a traction or compression type injury. A nerve lesion in continuity occurs at this level, when the radial head is dislocated anteriorly or anterolaterally in the MONTEGGIA fractures. There is an inverted arch through which the posterior interosseous

---

Key words : Posterior interosseous nerve palsy, Monteggia fracture.

Present Address · Dept. of Orthop. Surg., Faculty of Medicine, Kyoto Univ. 54 Shogoin  
Kawara-cho, Sakyo-ku Kyoto, Japan 〒 606

nerve enters the supinator. This arch is formed by the proximal border of the superficial head of the supinator and called the Arcade of FROHSE. SPINNER<sup>11)</sup> in 1968 reported that this arch was fibrous or tendinous in 30 per cent of the adult specimens. When this arch is fibrous or tendinous, the posterior interosseous nerve may be easily entrapped by this arch (supinator syndrome).

### Materials

In recent ten years, nine cases of the posterior interosseous nerve palsy with MONTEGGIA fractures have been seen in our clinic. Seven out of them were of acute type. Three cases complicating BADO, Type-1 were of incomplete palsy and four with BADO, Type-3 were of complete palsy (Table 1). There were two cases of tardy or delayed palsy. The age at initial injury was eight years and interval to onset of palsy was over twenty years in both cases (Table 2). In a case of a 28-year-old female, she had been combined with incomplete ulnar nerve palsy, so-called cubital tunnel syndrome.

### Case Presentation

Case R. S., a seven-year-old boy. On January 12, 1975, he fell from a horizontal bar and was struck on his left elbow, resulting in BADO, Type-3 MONTEGGIA fracture with

Table 1. Acute Type of Injury

Case	Age	Mechanism of Injury	Injury	Degree of Injury
1. R. S.	7	Fall from a horizontal bar.	MONTEGGIA fr. BADO, Type 3	Complete
2. K. O.	5	Fall from a horizontal bar.	MONTEGGIA fr. BADO, Type 1. (atypical type)	Incomplete
3. T. Na.	6	Fall from a bicycle	MONTEGGIA fr. BADO, Type 3.	Complete
4. T. Ni.	6	Fall from a bicycle	MONTEGGIA fr. BADO, Type 3,	Complete
5. M. N.	24	Front seat passenger in auto accident	MONTEGGIA fr. BADO, Type 1.	Incomplete
6. T. M.	30	Side-swiped injury	MONTEGGIA fr. BADO, Type 1. (atypical type)	Incomplete
7. T. T.	4	Fall from a horizontal bar	MONTEGGIA fr. BADO, Type 3.	Complete

Table 2. Tardy or Delayed Type of Injury

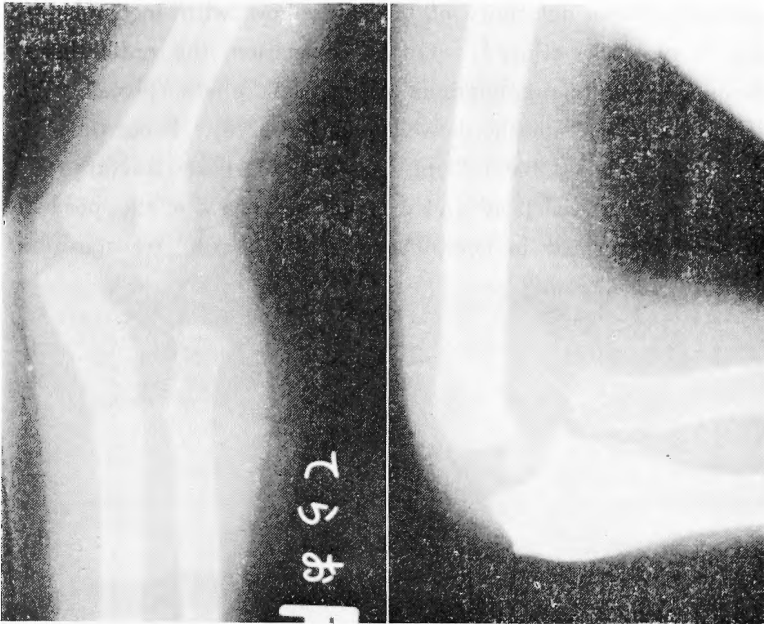
Case	Age	Age at the initial injury	Interval to onset of palsy (Yrs.)	Degree of palsy
1. T. K.	28	8 (MONTEGGIA fr. BADO, Type 3)	20	Incomplete
2. T. Y.	32	8 (MONTEGGIA fr. BADO, Type I, atypical)	24	Complete

complete posterior interosseous nerve palsy. The fracture-dislocation was satisfactorily reduced by a near-by orthopaedic surgeon on the same day. At the initial examination at Kyoto University Hospital thirteen weeks after injury, the nerve deficit was still complete, though the fracture already united (Fig. 1). Fourteen weeks after injury, the nerve was explored and examined. The nerve was perfectly crushed by the reduced radial head. After resection of crushed nerve about 2.5cm long, end-to-end suture was performed. By six months after nerve suture, full return of function had been obtained.

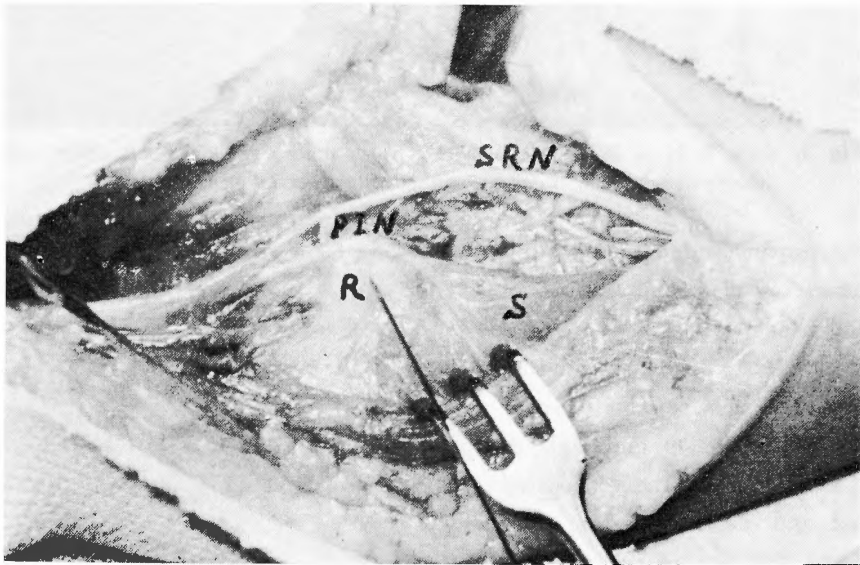


Fig. 1. Case R. S., a 7-year-old boy. A typical drop finger deformity.

Case T. T., a four-year-old boy. On August 21, 1975, he fell from a horizontal bar and was struck on the inner aspect of his right elbow. He was treated by a bone-setter immediately after injury. His mother had noticed that his thumb and fingers could not be extended just after injury. On the same day, the long arm cast was applied after manual reduction and continued for four weeks. After removal of cast, the motor disturbance of his thumb and fingers remained unchanged, and his mother became aware of the abnormal appearance of his elbow. Initial examination at Kyoto University Hospital six weeks after injury revealed a prominence at the anterolateral portion of the elbow and complete posterior interosseous nerve palsy. Roentgenograms also revealed a maltreated BADO, Type-3 MONTAGGIA fracture (Fig. 2). Open reduction of the dislocated radial head combined with wedge osteotomy of the bowed ulna and external neurolysis of the posterior interosseous nerve were performed eight weeks after injury. The nerve was stretched and compressed anterolaterally over the dislocated radial head (Fig. 3). By three months after operation, complete recovery of motor function had been obtained.



**Fig. 2.** Case T. T., a 4-year-old boy. A maltreated Monteggia fracture (Bado, Type-3).



**Fig. 3.** Case T. T. Operative findings (PIN ; posterior interosseous nerve, SRN ; superficial radial nerve, R ; dislocated radial head, S ; supinator muscle).

Case T. K., a 28-year-old female. She consulted Kyoto University Hospital on June 3, 1967, complaining of a weakness in her left hand developing over a period of two years. Extension of the long, ring and little fingers was particularly weak. She had had a history of Monteggia fracture treated by a bone-setter 20 years ago. Physical and neurological

examination revealed a varus deformity of the left elbow with incomplete posterior interosseous and ulnar nerve palsy (Fig. 4). On full pronation, the radial head was felt to be practically subcutaneous. Roentgenograms of the left elbow revealed a anterolaterally dislocated radial head and a laterally bowed ulna (Fig. 5). From these roentgenograms, the initial injury was concluded BADO, Type-3 closed MONTEGGIA fracture. On June 6, 1967, resection of the dislocated radial head and external neurolysis of the posterior interosseous and ulnar nerve were performed in combination with anterior transposition of the ulnar

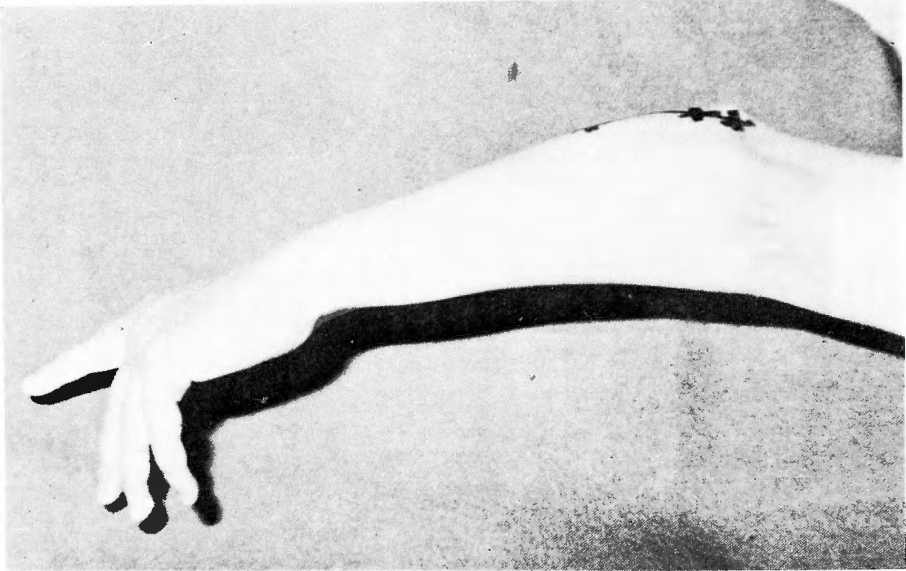

Fig. 4. Case T. K., a 28-year-old female. A varus deformity of the left elbow with incomplete posterior interosseous and ulnar nerves palsy.

nerve. The proximal edge of the supinator muscle, so-called the Arcade of FROHSE, had been destroyed by pressure of the dislocated radial head protruding in this area. The posterior interosseous nerve had become slender and tight as it was stretched over the dislocated radial head and its surrounding scar tissue. By one year after surgery, partial return of function had been obtained and she was satisfied with results of operation because of no progression of the weakness in her left hand.

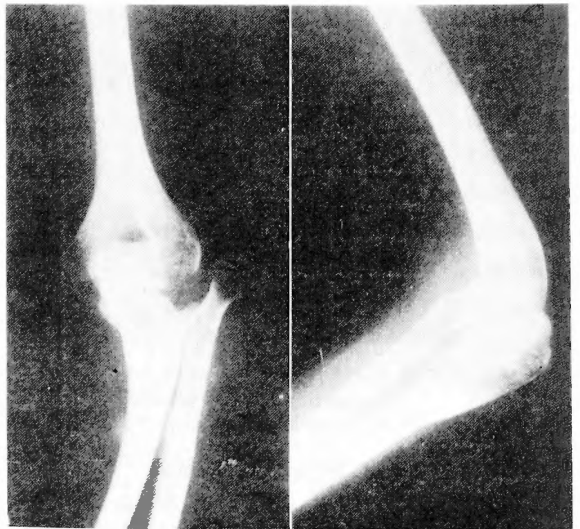

Fig. 5. Case T. K. A anterolaterally dislocated radial head and a laterally bowed ulna.

### Results

Excellent results were obtained in all acute cases with or without nerve operation (Table 3). In three cases with incomplete palsy, early spontaneous recovery had been seen in two cases within eight weeks after reduction, and late spontaneous recovery in one case by 24 weeks after reduction. The later was the case of side-swiped injury with extensive damage to the soft tissue of the forearm. There were four cases of nerve operation, three external neurolysis and one nerve suture. Within 24 weeks, full return of function had been obtained in these four cases. The onset of recovery in the case of nerve suture had been seen within twelve weeks, and full return of function by 24 weeks after surgery.

**Table 3.** Results ; Acute Type of Injury

Case	Age(yrs.)	Type of Injury	Interval to Nerve Op.	Procedure	Recovery
1. R. S.	7	BADO, Type 3 with complete PIN palsy	14 wks.	Nerve suture	Complete (24 wks.)
2. K. O.	5	BADO, Type 1 with incomplete PIN palsy	(—)	(—)	Complete (8 wks.)
3. T. Na.	6	BADO, Type 3 with complete PIN palsy	4 wks.	Neurolysis	Complete (16 wks.)
4. T. Ni.	6	BADO, Type 3 with complete PIN palsy	2 wks.	Neurolysis	Complete (12 wks.)
5. M. N.	24	BADO, Type 1 with incomplete PIN palsy	(—)	(—)	Complete (8 wks.)
6. T. M.	30	BADO, Type 1 with incomplete PIN palsy	(—)	(—)	Complete (24 wks.)
7. T. T.	4	BADO, Type 3 with complete PIN palsy	6 wks.	Neurolysis (open reduction)	Complete (12 wks.)

**Table 4.** Results ; Tardy or Delayed Type of Injury

Case	Age(yrs.)	Type of Injury	Interval to Nerve Op.	Procedure	Recovery
1. T. K.	28	BADO, Type 3 with incomplete PIN palsy	2 yrs.	Neurolysis	Incomplete (48 wks.)
2. T. Y.	32	BADO, Type 1 with complete PIN palsy	(—)	(—)	Tendon transfer

Results of cases with tardy or delayed palsy are shown in Table 4. As the palsy had been complete for more than one year in Case T. Y., tendon transfer was adopted without nerve operation. In tardy or delayed type of injury, degree of palsy and interval to onset of palsy are very important factors in the choice of treatments. When the palsy is incomplete and progressive, neurolysis will be probably indicated. Tendon transfer, however, appears to be the procedure of choice, when severe dysfunction continues for a long period.

### Discussion

Excluding a direct trauma to the nerve, the mechanisms of this injury are assumed that the posterior interosseous nerve is stretched or compressed, and may be entrapped at the Arcade of FROHSE in adults. The posterior interosseous nerve palsy may be occasionally associated with BADO, Type-1, 3 and 4 MONTEGGIA fracture in which the radial head is dislocated anteriorly, laterally and anterolaterally. This assumption will be supported by the fact that in prior reports<sup>8)9)</sup> of BADO, Type-2 with posterior dislocation of the radial head, no nerve injuries were reported.

In present series the nerve injuries were caused by BADO, Type-1 and 3 of MONTEGGIA fracture. In acute type of nerve injury with BADO, Type-1, all of three cases were of incomplete palsy (Fig. 6). There have been only several reports about the nerve injury with BADO, Type-1, although this type of injury is fairly common in MONTEGGIA fractures. From an anatomical point of view the anteriorly dislocated radial head may play a minor role of severe damage to the posterior interosseous nerve. On the other hand, BADO, Type-3 is relatively rare in MONTEGGIA fractures and this type of injury occurs exclusively in children. BADO in 1969 mentioned that radial nerve paralysis is very frequent in this type of injury. All of four cases with acute and complete palsy were seen in childhood, as shown in Figure 7. This fact tends to indicate that lateral or anterolateral dislocation of the radial head may be a major cause of severe damage to the posterior interosseous nerve.

According to SUNDERLAND'S anatomical study of the peripheral nerve<sup>15)</sup>, nerve fibers may be more easily severed by stretching or compression when the nerve trunk is composed

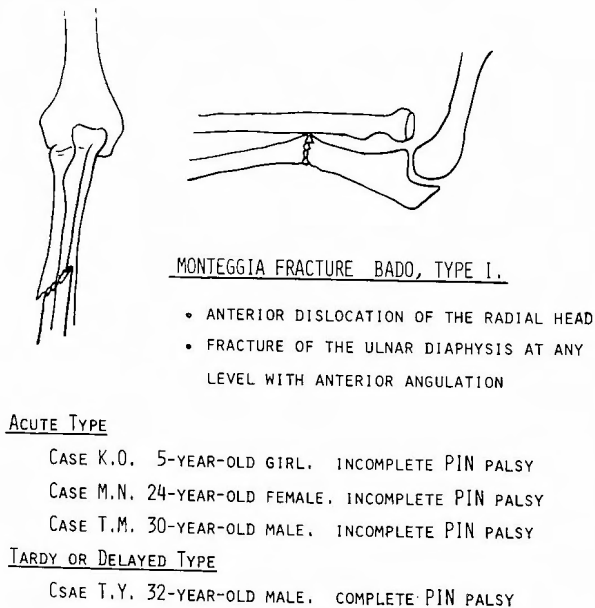
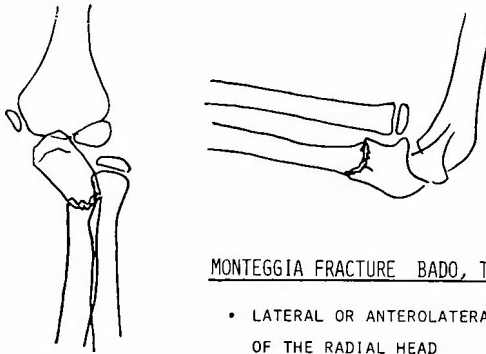


Fig. 6.



MONTEGGIA FRACTURE BADO, TYPE 3.

- LATERAL OR ANTEROLATERAL DISLOCATION OF THE RADIAL HEAD
- FRACTURE OF THE ULNAR METAPHYSIS

ACUTE TYPE

- CASE R.S. 7-YEAR-OLD BOY. COMPLETE PIN PALSY
- CASE T.NA. 6-YEAR-OLD BOY. COMPLETE PIN PALSY
- CASE T.NI. 6-YEAR-OLD BOY. COMPLETE PIN PALSY
- CASE T.T. 4-YEAR-OLD BOY. COMPLETE PIN PALSY

TARDY OR DELAYED TYPE

- CASE T.K. 28-YEAR-OLD FEMALE. INCOMPLETE PIN PALSY

Fig. 7.

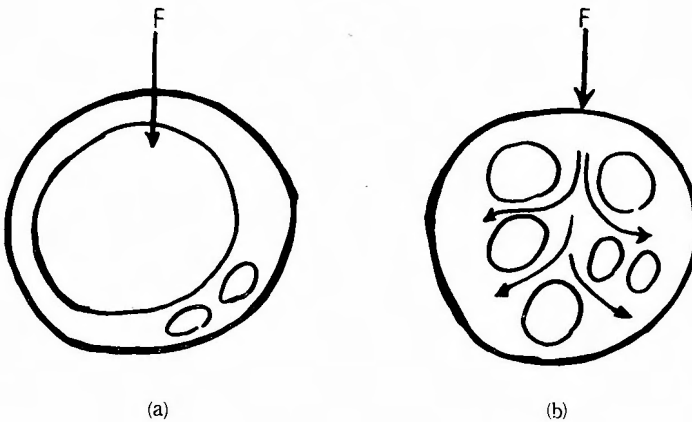
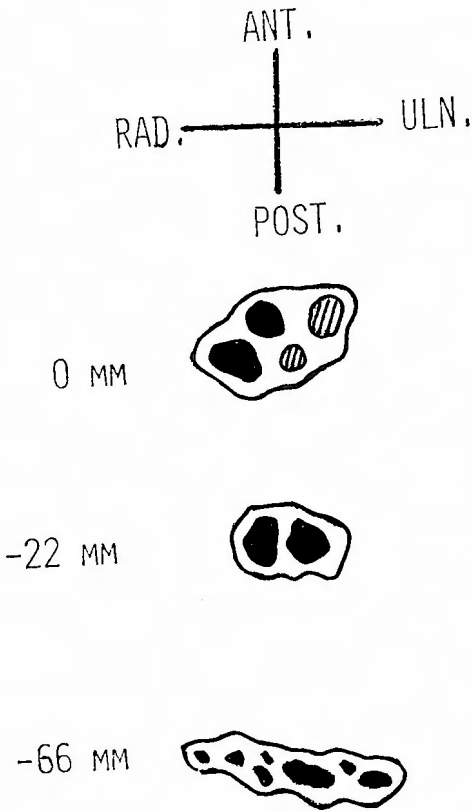


Fig. 8-a, Fig. 8-b. (Sunderland, S., 1968)

of large and closely packed funiculi with little supporting connective tissue (Fig. 8-a). Where, on the other hand, peripheral nerves are composed of a large number of small funiculi with greater amount of interfunicular tissue, they may be more favourably constituted to withstand stretching or compression (Fig. 8-b). The funicular pattern of the posterior interosseous nerve can be extracted from TAMURA's intraneural topographic atlases<sup>16)</sup> (Fig. 9). The funicular pattern of the nerve at the level of the Arcade of FROHSE is extremely simple and the funicular area is relatively large. This intraneural topographic fact may be responsible for the vulnerability of the posterior interosseous nerve.





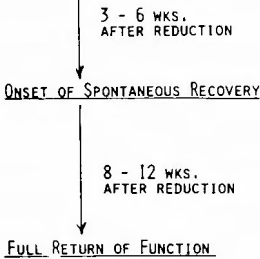
**Fig. 9.** A transverse section from a PIN in the elbow and forearm (distance from an epicondylar line ; ⊙ supinator fibers, ● posterior interosseous fibers) (Tamura, K., 1969)

Tardy or delayed type of palsy may be included in the category of the entrapment neuropathy. The vulnerability of the posterior interosseous nerve at the proximal edge of the supinator have been stressed by KOPELL and THOMPSON in 1963 and SPINNER in 1968. Both of the unreduced radial head in old MONTEGGIA fracture and the existence of the Arcade of FROHSE may play an important role in an entrapment point and affect the nerve in distant future.

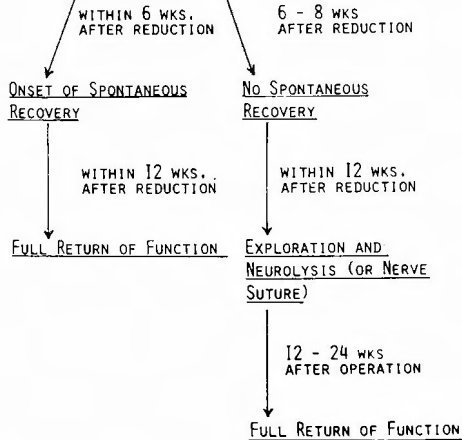
The treatment and prognosis of the acute type of the nerve injury is shown systematically in Figure 10. In most of acute cases, full return of function will be expected within twelve weeks after reduction of fracture-dislocation. If onset of spontaneous recovery can not be observed within eight weeks after reduction, nerve operation would be indicated within twelve weeks after reduction. In the case of nerve suture, complete recovery of motor function will be also expected by 24 weeks after surgery.

ACUTE TYPE OF INJURY

INCOMPLETE PIN PALS



COMPLETE PIN PALS



**Fig. 10.** Treatments and Prognosis

### Summary

- 1) Nine cases of the posterior interosseous nerve palsy caused by MONTEGGIA fractures were presented and discussed.
- 2) Complete palsy of the posterior interosseous nerve may be more frequently accompanied with the injury of Bado, Type-3 in childhood.
- 3) The dislocated radial head should be exactly reduced to prevent the occurrence of tardy or delayed palsy of the posterior interosseous nerve.
- 4) The mechanisms responsible for this palsy are assumed that the nerve is stretched or compressed over the dislocated radial head, and may be entrapped at the Arcade of FROHSE in adults.
- 5) The prognosis of this nerve injury is very excellent in acute case. Full return of function will be expected within twelve weeks after reduction or by 24 weeks after nerve operation.

### Acknowledgement

The authors wish to express the gratitude to Prof. TETSUO ITO for his instruction and encouragement through this study.

This paper was presented at the Post-Congress of Fifth Western Pacific Orthopaedic Association Congress on October 6, 1976 in Sapporo.

### References

- 1) Adachi, N., Hirayama, R., and Kakihana, T. : Dislocation and fracture-dislocation of the elbow joint. *Orthop. Surg. (Japanese)*, **25** : 56, 1974.
- 2) Adams, J. R., and Rizzoli, H. V. : Tardy radial and ulnar nerve palsy. *J. Neurosurg.* **16** : 342, 1959.
- 3) Bado, J. L. : The Monteggia lesion. *Clin. Orthop.*, **50** : 71, 1967.
- 4) Boyd, H. B., and Boals, J. C. : The Monteggia lesion. A review of 159 cases. *Clin. Orthop.* **66** : 94, 1969.
- 5) Kopell, H. P., and Thompson, W. A. L. *Peripheral entrapment neuropathies.* William & Wilkins Co. Baltimore, 1963.
- 6) Lichter, R. L., and Jacobson, T. : Tardy palsy of the posterior interosseous nerve with a Monteggia fracture. *J. Bone Joint Surg.*, **57-A** : 124, 1975.
- 7) Naylor, A. : Monteggia fractures. *Brit. J. Surg.*, **29** : 327, 1942.
- 8) Paval, A., Pitman, J. M., Lance, E. M., and Wade, P. A. : The posterior Monteggia fracture. A clinical study. *J. Trauma*, **5** : 185, 1965.
- 9) Penrose, J. H. : Monteggia fracture with posterior dislocation of radial head. *J. Bone Joint Surg.*, **33-B** : 65, 1951.
- 10) Smith, F. M. : Monteggia fractures. An analysis of twenty-five consecutive fresh injuries. *Surg. Gynec., and Obstet.*, **85** : 630, 1947.
- 11) Spinner, M. : The arcade of Frohse and its relationship to posterior interosseous nerve paralysis. *J. Bone Joint Surg.*, **50-B** : 809, 1968.
- 12) Spinner, M., Freundlich, B. D., and Teicher, J., : Posterior interosseous nerve palsy as a complication of Monteggia fracture in children. *Clin. Orthop.*, **58** : 141, 1968.
- 13) Spinner, M. : *Injuries to the major branches of peripheral nerves of the forearm.* W. B. Saunders Co. Philadelphia, London, Toronto, 1972.
- 14) Stein, F., Grabias, S. L., and Deffer, P. A. : Nerve injuries complicating Monteggia lesions. *J. Bone Joint Surg.*, **53-A** : 1432, 1971.
- 15) Sunderland, S. : *Nerves and nerve injuries.* E & S. Livingstone LTD. Edinburgh, London, 1968.
- 16) Tamura, K. : The funicular pattern of Japanese peripheral nerves. *Arch. Jap. Chir.*, **38** : 35, 1969.

## 和文抄録

## Monteggia 骨折に合併した後骨間神経麻痺について

京都大学医学部整形外科学教室 (主任：伊藤鉄夫教授)

山本 潔, 梁瀬 義章, 富原 光雄

大津赤十字病院整形外科

藤田 仁, 斉田 坦男, 光野 一郎

Monteggia 骨折に合併あるいは随伴する後骨神経麻痺は比較的珍しいものであり、特に骨折後数10年を経過して発症する遅発性麻痺の報告は極めて稀である。われわれは過去10年間に新鮮例7例、遅発例2例を経験したので、それらの治療経過とともに若干の考察を加えて報告した。これを要約すると

1. 後骨間神経の完全麻痺は小児にみられる Monteggia 骨折の Bado, Type 3 においてより頻発すると考えられる。

2. 不完全麻痺は Bado, Type 1 によくみられるが、神経麻痺に対する治療を要しない場合が多い。

3. 橈骨小頭脱臼は確実に整復して、遅発性麻痺の発生を防止する必要がある。

4. 本症の発症機転は前外方あるいは外方に脱臼した橈骨小頭によりそれに近接して走行する後骨間神経が牽引あるいは圧迫されるものと考えられる。特に成人では Frohse の Arcade 部分で神経が絞扼される可能性がある。

5. 本症の予後は急性例では極めて良好であり、3カ月以内に完全回復をみるものが多い。完全麻痺で神経剝離術あるいは神経縫合術が施行された例でも約6カ月で完全回復が期待できる。遅発性麻痺における治療法の選択は麻痺の程度、麻痺の期間によるが、不完全麻痺ならば神経剝離術、完全麻痺ならば腱移行術が適応となる。