Arch Jap Chir 46 (6), 657～680, Nov., 1977

原　　著

An Experimental Study on the Artificial Intestinal Valve by Telescoping Anastomosis

HAN-LONG ZHENG

The Second Department of Surgery, School of Medicine, Kyoto University
(Director : Prof. Dr. YORINORI HIKASA)
Received for Publication Aug. 13, 1977

I. Introduction

Massive resections of the intestine have been performed with rapidly increasing frequency since the first clinical success of KOEBERLE[1] in 1881. Malabsorption resulting from involvement of the ileocolonic junction in the resection, however, seriously affects the prognosis of pediatric as well as adult patients[2-9]. Applicability of the ileocecal junction, on the other hand, as an antireflux mechanism in the reconstruction of the urinary and gastrointestinal tract has been confirmed both experimentally and clinically by many workers[10-16]. Hence various kinds of artificial intestinal valve have been created and tested either to compensate loss of the ileocolonic junction or to serve as an antireflux mechanism in urological and gastrointestinal surgery[17-30].

Almost all of the reports dealing with artificial intestinal valves so far published have resorted to roentgenological and/or bacteriological methods in estimating the function of the valve. No quantitative analysis of an artificial intestinal valve ever appeared on the literature. The author evolved a new type of artificial intestinal valve with telescoping anastomosis in dogs, and evaluated its valvular function manometrically by means of perfused open-tip catheters with the ileocolonic junction served as controls.

II. Preliminary Study

A. Valve Construction

Four mongrel dogs of both sexes weighing from 6.5 kg to 14 kg were used. An intestinal valve was constructed at the descending colon with the same technique as will be detailed later in the following chapter.

The smallest dog in the group died on the 6th postoperative day because of anastomotic

Key words : Intestinal valve, Telescoping anastomosis, Manometry.
Present address : Department of Surgery, Kitano Hospital, 3-Nishiōgimachi, Kita-ku, Osaka, 530 Japan.

rupture. In the remaining three dogs, soft formed stool was preceeded by diarrhea for about a month after the operation. Valvular function was tested in DOG ♯1 roentgenologically by means of barium enema (Fig. 1). The colon distal to the valve was filled and clearly visualized with contrast material. No barium was seen, however, to pass upwards across the valve even when the barium containing bag was raised 100 cm high above the canine anal level. The test suggested that the valve could withstand about 100 cmH_2O of pressure as an antireflux mechanism.

Fig. 1. Barium enema of DOG ♯1. Sixty seven days after the telescoping valve was constructed in the descending colon. Note no contrast material reflux is seen across the valve.

Autopsy and histological examination were done on DOG ♯1 and ♯4. Intraperitoneal cavity was clear. Colon proximal to the valve showed a slight dilatation as compared with distal colon in DOG ♯1, but not so in DOG ♯4. Histological findings of the anastomosis were as follows. The telescoped portion of the colon curled back on itself to heal mücosa-to-mucosa to the upper end of the recipient segment. Union of the telescoped and recipient colon was achieved mainly by the growth of connective tissues. The mucosal continuity at the anastomotic site was not yet seen on the specimen taken 48 and 67 days postoperatively. Both the circular and longitudinal muscle layers thickened considerably. The most distinguishing finding was marked proliferation of the submucosal tissue at the distal end of the invaginated colon.

B. Manometry

To provide fundamental informations for analysing manometric records, the following experiments were undertaken on the canine intestine under direct vision. Manometric equipments were arranged just in the same way as will be described later.

1) Determination of Perfusion Rate of the Pressure Detecting Catheter

A pressure detecting polyethylene tube was inserted into a segment of the intestine and perfused with saline at various flow rates. The maximal rate without affecting the base-line was found to be 6 μl/sec.

2) Pressure Curves in Relation to the Length and Course of the Intestine (Fig. 2)

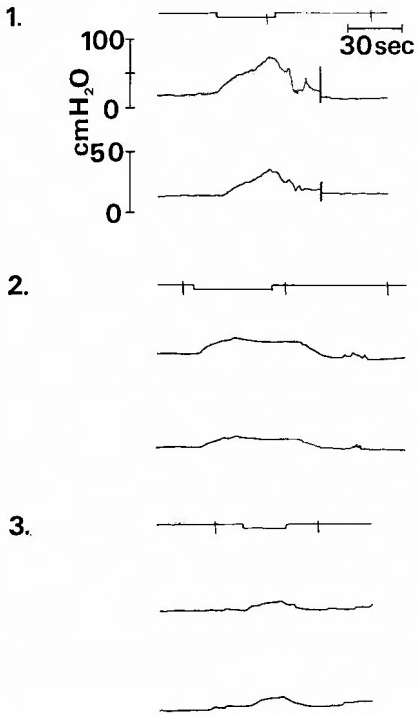

Fig. 2. Pressure curves in relation to the length and course of the intestinal segment. 1. Short segment (10cm). 2. Long segment (40cm). 3. U-shaped intestinal loop. Marker indicates duration of infusion. In each pair of records, the upper curve repesents pressure from the infused portion, and the lower curve from the uninfused portion of the segment. Tracings are substantially identical under these three situations regardless whether the portion is infused or not.

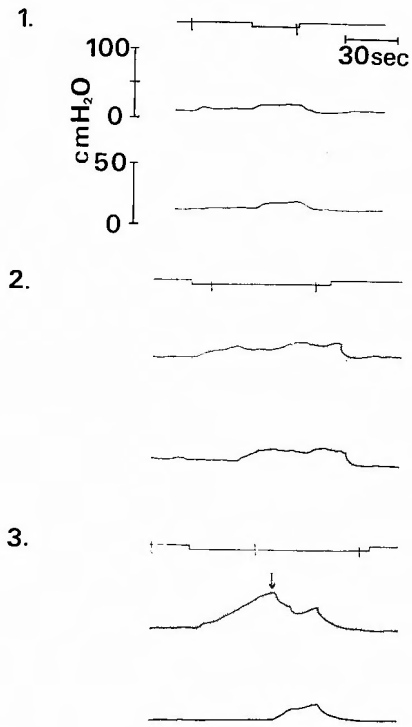

Fig. 3. Pressure curves in stenosis models. 1. Partial stenosis. 2. Moderate stenosis. 3. Complete oculusion. Marker indicates duration of infusion. In each pair of records, the upper curve represents pressures from the infused segment and the lower curve from the uninfused segment of the intestine. Recognize the similarity between Fig 3-3 and Fig 4-2. See text for further legend.

Two catheters were inserted opposite to each other into an intestinal segment, and warm saline was infused into the segment through a #8 Nelaton catheter. In a short segment (10 cm), there was a rapid rise in pressure curves following the infusion, whereas in a long segment (40 cm), the rise of pressure was quite slow and gradual. Arrangement of the segment in U-shape did not affect substantially results obtained above.

3) Pressure Curves in Stenosis Models (Fig. 3)

Partial stenosis of the intestine was made by applying a forceps to the middle of the segment. In this situation onset of pressure rise in the non-infused portion of the segment followed with a distinct time lag that of the infused portion. Both pressure curves were, however, almost identical in figure. In complete obstruction of the intestine, two compartments of the segment were entirely separated by the forceps. Saline infusion into one compartment naturally had no effect at all on the other one ; pressure tracing from

the infused compartment raised steadily as infusion proceeded, pressure in the other side of the forceps remained as low as the base-line level. On removal of the forceps, there was always marked base-line elevation on the pressure record from the uninfused segment, which was accompanied by concurrent flattening or transient fall of the pressure from the infused segment. Manometry of the ileocolonic segment yielded similar pressure curve (Fig. 4) to those of complete intestinal obstruction models. Another observation on the ileocolonic segment confirmed that no fluid was recovered from uninfused segment unless base-line elevation of the same segment took place. The author considered, therefore, that the point at which saline pass across the junction could be precisely determined on the pressure records even without the help of fluoroscopy.

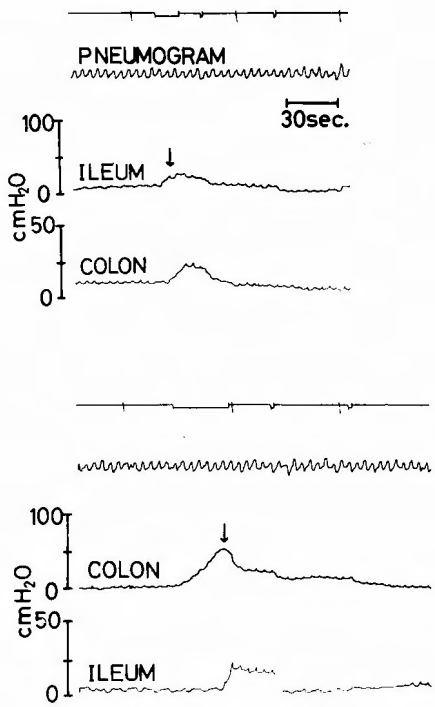

Fig. 4. Pressure records of the canine ileocolonic junction. 1. Isoperistaltic infusion of saline. 2. Antiperistaltic infusion of saline. Arrows indicate pressure amplitude at which saline passes across the junction. Note drooping phenomenon of the curve from the infused segment at the point of saline passage.

III. Materials and Methods

One hundred and 17 healthy mongrel dogs of both sexes weighing from 6 kg to 18 kg were used in this study. Among them 38 animals served as controls, and 75 dogs were prepared with an intestinal valve and investigated morphologically as well as functionally. In another 4 dogs, Roux-en-Y cholecystojejunostomy with the telescoping valve in the defunctionalized limb was performed to probe the clinical feasibility of the valve.

A. Valve Construction

After 24 hr fasting, animals were operated on under pentobarbital anesthesia. The ileum was severed at 50 cm proximal to the ileocolonic junction. The proximal end of the intestine was detached from the mesentery and invaginated into the distal intestine. Telescoping anastomosis (Fig. 5) was performed with 4-0 chromic catgut. Eight interrupted sutures usually completed the anastomosis, and special care was taken not to include the mucous layer into stitches. The length of telescoped intestine for construction of the valve was measured and expressed in relation to intestinal diameter as one diameter length (group V1), two diameter lengths (group V2), and three diameter lengths (group V3). No less than two weeks prior to manometric evaluation, animals underwent a second operation. A 20 cm portion of the intestinal segment, with the artificial valve at its middle, was excluded

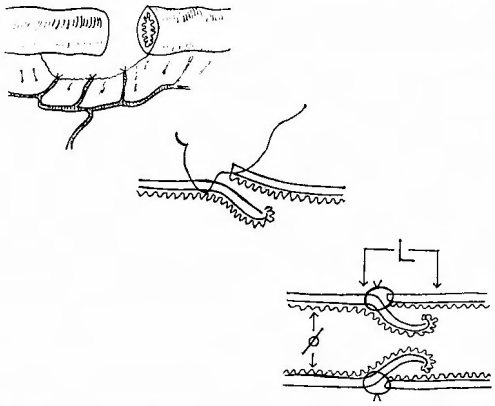

Fig. 5. Construction of the telescoping valve. L: length of the intestine to be telescoped for valvular formation. ϕ diameter of the intestine.

Table. 1. Arrangement of Animal Groups

Artificial Intestinal Valves :

- V1 Valve constructed with one diameter length of the intestine.
- V2 Valve constructed with two diameter lengths of the intestine.
- V3 Valve constructed with three diameter lengths of the intestine.

Controls :

- C1 Ileocolonic junction.
- C2 Sphincteroplasty of the ileocolonic junction.
- C3 End-to-end ileoileostomy.
- C4 Simple ileal loop.
- C5* Ileocolonic junction under laparotomy.

*All groups except C5 are prepared with Thiry-Vella fistulae.

from the gastrointestinal tract and brought through the abdominal wall as a Thiry-Vella fistula without undue angulation or tension (Fig. 6). Intestinal continuity was restored with an end-to-end ileoileostomy after Gambee's original method.

B. Preparation of the Control Groups

Five control groups, consisting of 3 to 10 dogs each, were arranged as follows (Table 1). A 20 cm of the intestinal segment was excluded from the intestinal

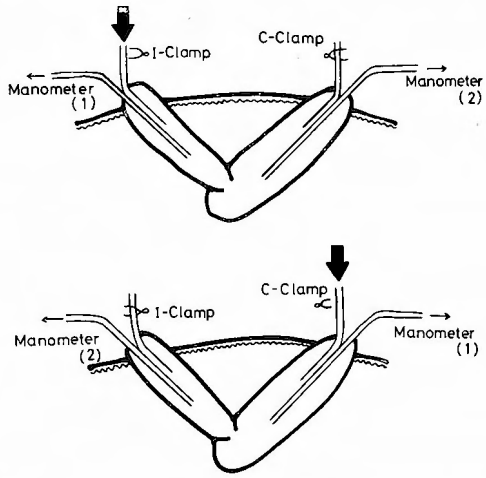

Fig. 6. Manometry by use of the Thiry-Vella's fistula. Manometer (1) records pressures from the infused segment, and Manometer (2) from the uninfused segment. Arrows indicate infusion of saline.

tract to make a Thiry-Vella fistula in groups Cl through C4 : group Cl, the ileocolonic segment with the ileocolonic junction at its middle ; group C2, the same as above except that a Heinecke-Mikulitz fashion of sphincteroplasty was performed on the ileocolonic junction ; group C3, the segment with an end-to-end anastomosis at its midpoint ; group C4, the intact ileal segment. Intestinal reconstruction and postoperative care in these animals were entirely the same as in the experimental groups. In last group C5, manometry of the ileocolonic junction was carried out under direct vision, while the dog's abdomen was kept open.

C. Functional Study

Animals were anesthetized intravenously with 25 mg/kg of pentobarbital sodium, and

a tube was inserted into the trachea to permit pulmonary ventilation with room air (Harvard APPARATUS Respiration Pump Model 614). Manometric assembly consisted of a rubber catheter (o. d. 5 mm ; i. d. 3 mm) and open tip polyethylene catheter (o. d. 2.75 mm ; i. d. 1.5mm), which was perfused at a constant rate of 5 to 6 μl/sec with an infusion pump (Truth AII). The assembly was manipulated through the proximal and distal stoma of the Thiry-Vella fistula, respectively, into the intestinal segment, and so positioned that the tips of the two recording catheters were 5 cm proximal and distal to the artificial intestinal valve. The stomas were then closed with pursestring sutures. Intraluminal pressures on either side of the valve were simultaneously traced through transducers (Nihon-koden Recticorder RJG 3024). Physiological saline (38°C) was infused at a mean rate of 0.53 ml/sec through the rubber catheter alternately into the proximal and distal intestine (Fig. 6). The pressure curve on manometer (1) rose gradually concomitant to the infusion. As had already been confirmed by preliminary experiments, saline passage across the valve into the other side of the segment was indicated by a distinct base-line elevation of the pressure trace on manometer (2), accompanied by flattening or transient fall in the pressure curve on manometer (1). This point of amplitude of pressure record on manometer (1) was calculated either as isoperistaltic pressure (IPP) or antiperistaltic pressure (APP), according to the direction of infusion. Pressure measurements were repeated 10 times for both IPP and APP in each animal. A total of 283 IPP and 285 APP measurements were recorded in control groups, and 289 IPP aand 297 APP in experimental groups. Animals were also subdivided into short-term and long-term follow-up groups, and valvular function was compared in relation to follow-up period. Continuity of the mucous layer at the anastomosis was restored around the second postoparative month in most cases. The author chose this period as the short-term follow-up, which averaged 67.3 days (range : 55-83) after the valve was formed. In long-term groups, manometry was carried out on the 191.6th day (range : 103-353) postoperatively. Animals were killed on completion of manometry and were checked for the status of the catheters in it. In case inappropriate positioning of cathetertips or any other troubles were found, the dog was excluded from study. Statistical analysis of the data was performed with the Student t test for paired and unpaired values. Values presented are mean ± SE of means.

D. Morphological Study

1) Caliber Changes

Intestinal diameters 3 cm oral and anal to the valve were gauged at the second operation. Measurements were made in 7 dogs of group V1, 4 dogs of group V2, and 8 dogs of group V3.

2) Microangiography

Vascular contribution in the healing process of telescoping anastomosis and valve formation was studied microangiographically. The examination was performed 1, 2, 3, 4 weeks, and 10 months after the valve had been formed by telescoping two diameter lengths of the intestine. Following pentobarbital anesthesia, heparin 300 U/kg and papaverin HCL 0.1 g/kg were administered to the dog intravenously. One hour later, the intestinal segment including the valve was perfused through the cannulated mesenterial artery with warm 0.9 % saline (37-40°C) for 30 min at a rate of 70-100 ml per min per 100 gr of tissue. A

mixture of barium sulfate 100 gr, gelatin 10 g, and 0.9 % saline 250 ml (30-40°C) was prepared as contrast medium, which was injected manually through the cannulated mensenterial artery and vein. Thirty to 50 ml of the contrast medium was required for adequate filling of the entire vascular bed of 30 cm of the intestinal segment. The specimen was stored in a refrigerator and then fixed in 10 % neutral formalin for 24-48 hr on a cardboard. It was sectioned at 3 mm thickness and radiographed on SAKURA LITH CONTACT FILM. The apparatus employed was SOFTEX. X-ray tube was used with a film-focus distance of 40 cm. The exposure time was 75 sec at 25 kV and 10 mA.

3) Histological Study

Three kinds of staining, Mallory-Azan, Van-Gieson, and Hematoxylin Eosin staining, were used in histological examination of each valve.



Fig. 7. Application of the telescoping valve to Roux-en-Y cholecystojejunostomy. The valve was placed at the middle of 20 cm of the jejunal Y-limb. The choledochus was severed near its termination between ligatures.

E. Application of the Artificial Valve to Roux-en-Y Cholecystojejunostomy

On laparotomy, the choledochus was divided between ligatures. The jejunum was severed at the site 10 cm distal to the Treitz's ligament. The proximal end of the jejunum was brought up to be anastomosed with the gallbladder. A side-to-side cholecystojejunostomy was performed with one-layer running suture using 4-0 atraumatic catgut. A telescoping valve constructed with two diameter lengths of the intestine was placed at the middle of the jejunal Y limb (Fig. 7). Intra-and postoperative managements were the same as those in other experimental groups. All cholecystojejunostomy dogs were kept under close observations on their clinical courses, including general findings, appetite, occurrence of jaundice, and property of the stool.

IV. Results

A. Operative Mortality and Complications

1) Control Groups

Out of 38 operations, there were eight postoperative deaths as shown in Table 2. During manometric procedures, some troubles were encountered as anesthetic overdosis, inadvertent perforation or tearing off or the Thiry-Vella loop with the catheter. Five animals were excluded from the study on this account.

2) Experimental Groups

Anesthetic deaths as well as cases without autopsy were excluded from the analysis.

Fourty deaths occurred out of 75 valve constructions. Among these deaths, 26 dogs (34.7%) were found to have some pathological conditions intraperitoneally ; 20 dogs (26.7%) related to the telescoping anastomosis and 6 animals unrelated to the valve (Table 3). Two cases of intestinal obstruction due to lodged foreign bodies in the valve were included in the deaths above mentioned (Table 4). One was a large hair phytolith, and the other a stone 3.0×2.5×2 cm in size. Valves constructed with two diameter lengths of the intestine showed the highest incidence (35.7%) of anastomotic troubles. The average survival period of animals with anastomotic perforation was 23 days (range : 20-30), and with obstruction was 11.7days (range : 3-18) in this group. Two ileoileal, and two ileocecal invaginations, all found distal to the valve, constituted the main cause of deaths unrelated to the telescoping anastomosis. They developed over a period of 15 to 34 days with an average of 22.8 days postoperatively.

Table. 2. Mortality and Complications in Controls*

Group	N	Anastomic Leakage	Invagination	Others	Manometric Troubles
C1	15	1	1	0	3
C2	4	0	0	1**	0
C3	4	0	0	0	1
C4	5	0	0	1***	1
C5	10	0	0	0	0

* Anesthetic deaths are excluded.
** Persisted watery diarrhea.
*** Death of undetectable cause.

Table. 3. Mortality and Complications in Artificial Intestinal Valves*

Group	N	Deaths of Intra-peritoneal Origin	Deaths of Extra-peritoneal Origin	Manometric Troubles
V1	23	6	4	3
V2	28	12	5	1
V3	24	8	5	2

* Anesthetic deaths are excluded.

B. Functional Results

Manometry was accomplished in control series of 29 dogs and valve series of 29 dogs. The data are summarized in Table 5.

Table. 4. Deaths of Intraperitoneal Origin in Artificial Intestinal Valves

	V1	V2	V3
Related to Valve :			
Perforation	1	6	3
Obstruction	1	3	3
Foreign Body	1	1	0
Volvulus	1	0	0
	4	10	6
Unrelated to Valve :			
Invagination	1	2	1
Volvulus	0	0	1
Foreign Body	1	0	0
	2	2	2

Table. 5. Pressure Recordings* in Artificial Intestinal Valves and Controls

Group	N	IPP**	APP***	P
V1	10	20.1±1.9	27.6±3.2	$0.001<p<0.01$
V2	10	25.0±2.0	39.0±3.8	$p<0.005$
V3	9	19.5±2.4	34.0±4.6	$0.01<p<0.02$
C1	10	20.4±2.2	39.7±5.1	$0.001<p<0.01$
C2	3	8.1±1.1	7.1±0.5	$0.2<p<0.5$
C3	3	9.2±2.5	12.1±3.0	$p>0.5$
C4	3	10.6±1.5	9.8±1.8	$p>0.5$
C5	10	14.4±2.1	24.4±5.1	$0.02<p<0.05$

* Values are presented as mean±SE of mean cmH_2O above ambient.
** Isoperistaltic pressure.
*** Antiperistaltic pressure.

1) Control Groups

Among five control groups, mean APP was significantly larger than mean IPP in group Cl and C5. In other three groups the pressure values were almost always as low as resting pressures of the ileal and colonic segment regardless of the direction of saline infusion. In group Cl, 98 IPP and 100 APP yielded mean IPP of 20.4 ± 2.2 cm H_2O and 39.7 ± 5.1 cm H_2O, the latter being twice greater than the former. The difference between mean IPP and APP in this group was statistically significant. Ninety nine IPP and APP were calculated in group C5. Mean IPP and APP were 14.4 ± 2.1 and 24.4 ± 5.1 cm H_2O, respectively. Though the discrepancy between the mean IPP and APP remained statistically significant, the amplitudes of pressure were remarkably reduced in this laparotomy group C5 as compared with the Thiry-Vella group C1.

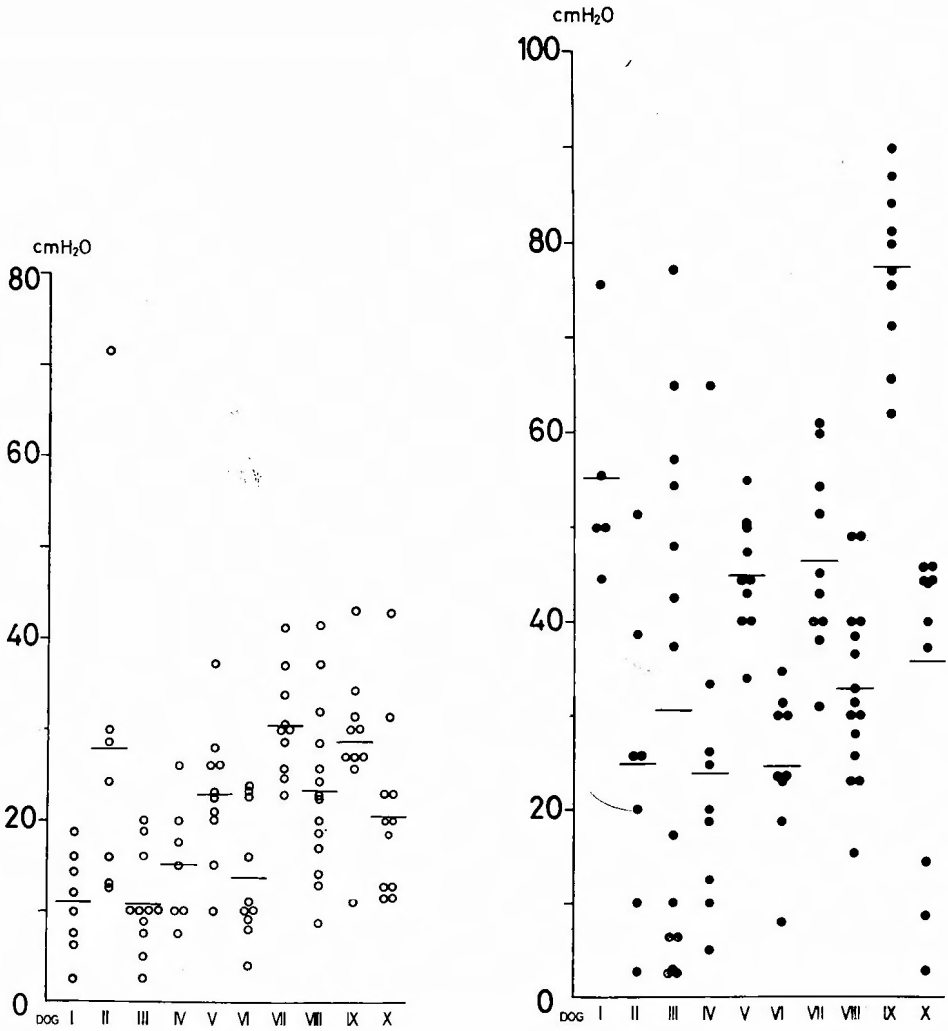

Fig. 8. Distribution of isoperistaltic pressure values (left) and antiperistaltic pressure values (right) of the ileocolonic junction in 10 control dogs. Bar represents mean IPP or APP in each animal.

Out of 98 IPP in group C1, there were only five occasions in which higher pressure than the mean APP 39.7 cmH_2O was required for the saline to pass across the junction from the ileum to the colon. Whereas 21 of 100 APP were found to be lower than the mean IPP 20.4 cmH_2O (Fig. 8).

2) Experimental Groups

In all three experimental groups, mean APP was significantly greater than mean IPP as shown in Table 5. The mean discrepancy between APP and IPP in each group were 7.5, 13.9, and 14.5cmH_2O in numerical order of experimental groups, whereas that of control group C1 was 19.2 cmH_2O. Statisitical analysis showed that the mean discrepancy in experimental group V1 was significantly smaller than that in group C1 ($p<0.05$) in contrast to other two experimental groups ($p>0.5$). Group V2 yielded the largest mean IPP and APP among the experimental groups, and the values were the most similar to those of control group C1.

Valvular function in terms of follow-up period is summarized in Table 6. The difference between short-term and long-term follow-up as to the amplitude of both mean IPP and APP in all experimental groups was statistically nonsignificant.

Table. 6. Analysis of Artificial Intestinal Valvular Function in Relation to Follow-up Period

Group		Short-Term	Long-Term	P
V1	N	3	7	
	IPP*	22.4±2.2	19.1±2.5	$p>0.5$
	APP**	31.0±5.9	26.1±3.6	$p>0.5$
V2	N	5	5	
	IPP	26.4±3.1	23.6±2.4	$0.2<p<0.5$
	APP	44.5±5.4	33.4±4.1	$0.2<p<0.5$
V3	N	4	5	
	IPP	23.1±3.4	18.0±3.1	$p>0.5$
	APP	37.1±5.0	31.4±7.1	$p>0.5$

* Isoperistaltic pressure, cmH_2O.
** Antiperistaltic pressure, cmH_2O.

Table. 7. Intestinal Caliber Changes* on Either Side of Artificial Valve

Group	V1	V2	V3
N	7	4	8
Oral	2.1±0.10	2.3±0.14	2.0±0.14
Anal	1.9±0.14	1.8±0.09	1.7±0.14
P	$0.025<p<0.05$	$0.05<p<0.1$	$0.2<p<0.5$

* Values are presented as mean ± SE of mean cm.

C. *Morphological Results*

1) Caliber Changes

No significant dilatation of the proximal part of the intestine was found except in group V1. Observations in group V2 were, however, too few to allow final conclusions as to the caliber changes (Table 7).

2) Microangiography (Fig. 9)

The 1st week: Mucosal capillaries covering the valve become thinner and more irregular as the valve tip is closer. Serosal capillaries are markedly dense and congested. The submucosal plexus is engorged, and at the valve tip it communicates with serosal vessels by way of dilated intermuscular vessels.

The 2nd week : Inflammatory proliferation of serosal capillaries of the valve are subsiding. Mucosal capillaries are restoring their alignment. The most striking feature in

this period is well developed intermuscular vessels connecting serosal capillaries to submucosal plexus. Blood supply of the distal valve is reinforced thus through augmentation of intermuscular channels.

The 3rd week : Strengthened communications between serosal vessels and the submucosal plexus are well established. The vascular bed of the latter is much dilated. Serosal vessels of the valve also join, at the site of anastomosis, with the submucosal network of the distal intestine. This is already seen at the 2nd week, but is not manifest until the 3rd week.

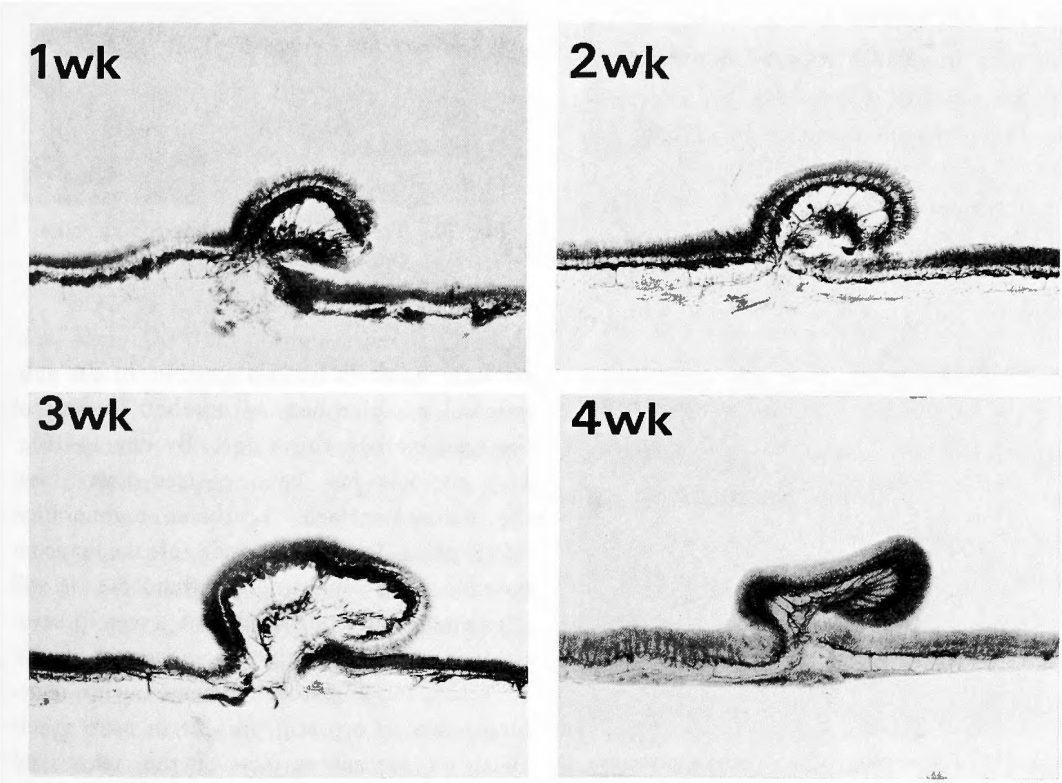

Fig, 9. Microangiography of the telescoping valve. See text for legend.

The 4th week : Vascular communications are complete between serosal vessels, the submucosal plexus of the valve, and submucosal vessels of the distal intestine. The submucosal plexus of the valve remains expanded, and takes the appearence of so-called "compressible venous cushions" of the ileocecal junction.

3) Histological Findings

The telescoped intestinal wall curls back on itself as a result of contraction of the longitudinal muscular layer, on which slides distally the circular muscular layer together with the submucosa, and the mucosa. The mucosal end of the invaginated segment is thus brought closer to that of the recipient bowel. By the end of the 2nd week, inflammatory reactions of all the layers of the telescoped segment disappear, and an intestinal valve resembling macroscopically the ileocolonic junction is formed. Mucosal regeneration arise from both ends of the invaginated and the recipient segment, and proceed anally and

orally, respectively, on the granulation tissue bridging the two segments. Regenerating mucosal ends meet each other around 60 days after operation. The union of the longitudinal muscular layer at the site of anastomosis is quite variable with specimens ; some achieve it as soon as day 14, and others never. The entire process (Fig. 10) will be detailed in the below.

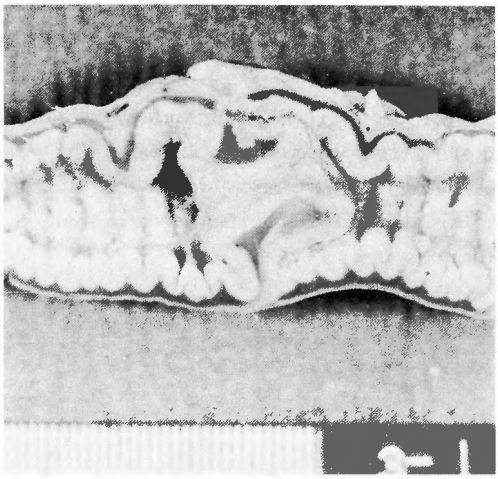

Fig. 10. Transection of the telescoping valve. One hundred and fifty-two days after operation.

Changes in the Telescoped Segment :

(1) Mucosa and submucosa

Degeneration of mucosal epithelial cells is marked on day 7 in the distal portion of the invaginated segment, and it deteriorates into ischemic necrosis in the vicinity of the end of the segment. The oral end of the recipient intestine is also covered with the necrotic epithelium. Congestion in the submucosal vascular bed is another finding of the specimen in this stage. By day 14 (Fig. 11), necrosis has been cleared away from the mucosal surface. Epithelial regeneration takes place from both ends of the mucosa towards each other. The submucosa is still edematous and congested, but lesser in severity as compared with the specimen of day 7. Active inflammatory processes with neovascularization are still present in some specimens on serosal surface of the telescoped portion of the intestine. On day 21, regeneration of lining cells proceeds and submucosal congestion is subsiding. Infalmmatory response on the serosa of the telescoped segment is replaced by granulation tissue, which in course of time was covered by a new epithelial lining. Around day 60, mucosal continuity at the site of telescoping anastomosis is restored in most cases.

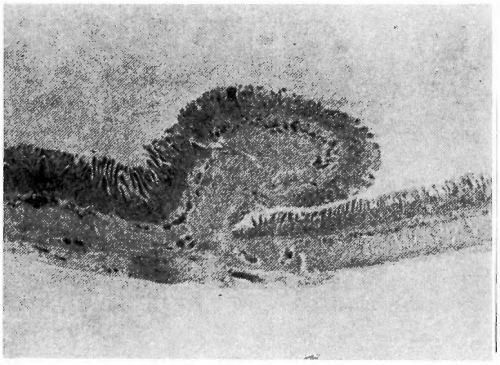

Fig. 11. Telescoping valve 2 weeks postoperatively. See text for legend. H. E. stain, ×10.

(2) Muscular layer and Meisner's plexus

By the 2nd week, the muscular layer is edematous and muscle fibers are atrophic. In the 3rd week, muscle fibers regain gradually their viability. Neither muscular atrophy nor edema of muscular coats is seen. The longitudinal muscular layer of the invaginated segment retracts, and the circular layer comes down at the tip of the telescoped segment to hold the longitudinal layer between two layers of the circular muscle. Meisner's ganglion cells are reviving, but still appear somewhat atrophic. Two months after the operation, the muscle fibers and Meisner's ganglion cells of the telescoping valve are seen quite normal

and viable.

Healing Process at the Site of Anastomosis :

The recipient segment and the invaginated segment are simply connected by edematous connective tissue on day 7. There is lymphocytic infiltration with scattered foreign body giant cells within this connective tissue. Inflammatory response is no more present in the 2nd week. Continuity of the outer longitudinal muscular layer may already be seen on day 14 (Fig. 11), but in some cases, variable amount of granulation tissue separates two segments for longer periods. The circular muscular layer never restore its continuity at the site of telescoping anastomosis (Fig. 12).

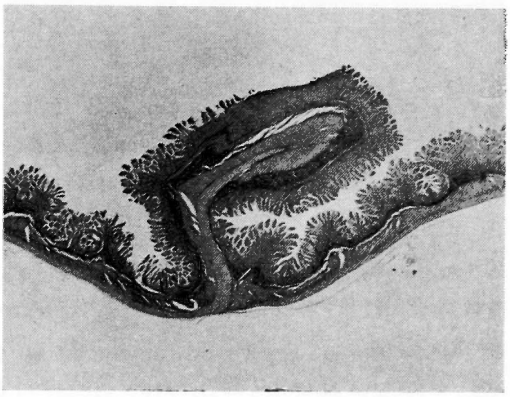

Fig. 12. Telescoping valve 119 days after construction. Mucosal covering of the site of anastomosis is complete. The longitudinal muscular layer is sandwitched by the circular muscular coat at the tip of the valve. Meisner's ganglion cells are all viable. Note the continuity of the longitudinal muscular layer at the site of anastomosis. Van-Gieson stain, ×10.

D. The Telescoping Valve in the Antiperistaltic Jejunal Limb of Roux-en-Y Cholecystojejunostomy

DOG #5 : Acholic diarrhetic stool persisted since the 14th postoparative day, and the dog died without jaundice 22 days after the operation. On laparotomy, there were severe inflammation and adhesions at and around the cholecystojejunostomy. Marked bile stasis within the gallbladder was noted as a result of stricture of the anastomotic stoma. DOG #6 : Died on the 13th postoperative day with rupture of the cholecystojejunostomy. DOG #7 : Postoperative course of this dog was quite uneventful with voracious appetite. On day 167, unusual loss of appetite was noticed, and two days later, he lay dead. A bamboo stick 9 cm long was found on autopsy, wrapped in the major omentum just ventral to the first portion of the duodenum. The exact site of perforation could not, however, be determined. The antiperistaltic jejunal loop adhered to the liver at the site of telescoping anastomosis, and there was jejunal dilatation proximal to the valve. DOG #8 : The dog survived in good conditions as long as 228 days postoperatively, when he died with unknown cause. The peritoneal cavity was entirely clear. No jejunal dilatation proximal to the valve was found in the Y limb.

Histological investigation was made on DOG #7. The liver appeared normal (Fig. 13). Neither proliferation of connective tissue nor biliary stasis was seen in and around the portal triad. Arrangment of the liver cells was quite in order.

V. Discussion

A. Methodological Considerations on Manometry

Manometry has been an useful tool for the study of intestinal physiology since the end of the last century. Three methods are available to record pressure from the gastro-

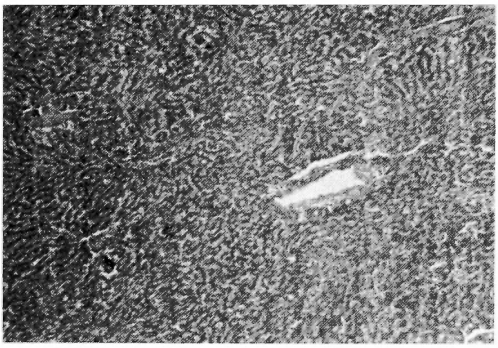

Fig. 13. Liver in Roux-en-Y cholecysto-jejunostomy with valve. One hundred and sixty-ninth postoperative day. No pathologic finding at all. See text for further legend. H. E. stain, ×100.

intestinal tract : 1) balloon system, 2) open-tip catheter system, and 3) miniature transdcuer system. Limitations of balloon methods[31-35], however, became clearer as methodology advanced. 1. The balloon may act as an obstructing body resulting in artifacts. 2. The size, shape, and elasticity of the balloon may affect pressures obtained. 3. The balloon system records intraballoon pressures rather than intestinal intraluminal pressures. Although all manometric methods have their own limitations, knowledge up to date has revealed that the open-tip catheter system with constant perfusion is the most reliable pressure monitoring method of the gastrointestinal tract[36-40], when the miniature transducer is as yet too expensive and not suitable for practical use. Pressure changes within the digestive canal as well as yield pressure of the sphincteric area are recorded by this system with a high reproducibility in the same individual. The optimal perfusion rate in manometry of a given part of the digestive tract still remains controversial with a wide range of 0.17 to 80 μl/sec[32-38][41-44]. The author chose the rate of 5-6 μl/sec for the current investigation through preliminary experiments.

B. Manometric Characterisitcs of the Canine Ileocolonic Junction

Since BAUHIN's description[45] in 1579 of the "ileocecal valve", two main functions have been attributed to this peculiar area of the junction between the small and large bowels. First, it regulates the transit of intestinal nutrients so as to assure adequate absorption. Second, it serves, at the same time, to prevent colonic contents from regurgitating back into the ileum[46-47]. There are not a few reports in the literature dealing with the antireflux pressure of the ileocolonic junction. Cadavers were found to withstand pressures of 10 mm Hg to 60 cmH_2O[48-49]. The junction was also reported to resist a mean pressure of 36.6 cm H_2O in 25 patients having barium enema[50]. Data in animal experiments showed a wide discrepancy among investigators. The canine ileocolonic junction has been found to tolerate a pressure of 50 cmH_2O[48] and 13.4 cmH_2O[50] with no leakage of water through to the small intestine. Most of the previous observations so far published were, as reviewed above, on postomortem specimes and/or experimental animals with their adbomen opened. Lack of reliable data as to the manometric characteristics of the ileocolonic junction has led the author to perform a series of controlled investigation on 29 dogs. To facilitate manometric study of the ileocolonic junction in vivo and without laparotomy, the author excluded the junction from the gastrointestinal tract and brought it through the abdominal wall as ileal and colonic fistulae. The efficacy of the exclusion of the ileocecal region as Vella's fistula in physiological and pharmacological researches of this area was already suggested by TOENNIS[51] in his excellent paper published 50 years ago. IPP and APP as measured in the current experiments do not represent mere function of ileal or colonic segments in the Thiry-Vella fistula, but specific function of the ileocolonic junction. For, statistically

significant difference between IPP and APP was found exclusively in group C1, in which the ileocolonic junction remained intact. Sphincteroplasty completely abolished the originally existed difference between IPP and APP, and converted an ileocolonic segment to nothing more than a simple ileal loop.

Detailed analysis of author's data disclosed that of a total of 198 measurements, 5.1 % of ileal infusions developed higher IPP than mean APP, while 21 % of colonic infusion resulted in APP much lower than mean IPP. Though the role of the ileocolonic junction in preventing retrograde flow seems well established, it must be emphasized that regurgitation does occur at times with little difficulty and the junction is competent in no more than 80 % of sequences as an antireflux mechanism. KELLY, et al[52]. performed series of manometric study on canine ileocolonic junction prepared just as in this study. They reported that the junction responded to ileal and colonic distention with balloons in such four manners as relaxation, relaxation followed by contraction, contraction, and no response. With ileal distention, relaxation was component of 79.4 % of 131 responses, whereas contraction alone occurring only in 11.5 % and no response in 9.2 %. With colonic distention, junctional zone contraction was the most prevalent pressure change and developed in 70.5 % of 88 responses, whereas relaxation participated in 18.2 % and no responses in 22.2 %. Results almost in the same line with KELLY's were obtained in 5 patients by COHEN, et al.[53] The results of the author and these workers suggest that about 10 % of ileal distentions cause the junction to constrict while approximately 20 % of colonic distentions lead it to dilate. Infusion of saline into the intestine in author's experiments might have also served as distending stimuli as in KELLY's study, and the ileocolonic junction responded to it with either active contraction or relaxation.

C. *Intraluminal Pressures of the Gastrointestinal Tract*

Gastrointestinal pressures so far published with the constant perfusion method are as follows. Human ileocecal junction has a high pressure zone of 20.3 mmHg above mean colonic pressure[53], while that of the dog amounted to 19.7 ± 1.43 cmH_2O above atmospheric pressure (non-perfusion system)[54]. Pressure changes from the small and large intestine usually reach a height of 10-30 mmHg and 10-20 mmHg, respectively, and only rarely exceed 50 mmHg[55-56]. Despite much work on gastrointestinal manometry, antireflux capability of junctional areas has never been elucidated except in a few studies on the ileocolonic junction under laparotomy or postmortem specimens[48-50][57]. The author has succeeded in creating an intestinal valve by telescoping two diameter lengths of the intestine, which is almost identical to the ileocolonic junction manometrically. A study on pathophysiologic effects of bowel distention on intestinal blood flow[58] showed that above an intraluminal pressure of 30 mmHg, blood was shunted through functional or anatomic arteriovenous communications depriving the bowel mucosa. It is, therefor, not only unnecessary but may even be harmful to a living subject when a valve or sphincter sustains an intraluminal pressure above 30 mmHg for a long period. Ischemic ulcerative lesions of the intestinal tract ensue proximal to the valve or sphincter. The mean IPP of the telescoping valve is also compatible with the biliary pressure without causing cholangiovenous reflux[59]. HUANG, et al.[60] found that the thoracic duct lymph and hepatic vein blood remained free of organisms as long as the pressure in the common duct was kept below 200 mmH_2O.

Table. 8. Summary of Intestinal Valves from English Literatures (1942-1976)

	AUTHOR	TYPE OF VALVE	METHOD	EVALUATION
1942	J. A. Glassman	Mucosal Ileocecal Valve	Experimental	X-ray, Bacteriology, Hydromanometery
1948	L. W. Peterson and W. H. Cole	Flap Valve and Infolding Valve	Experimental and Clinical	Macroscopic Observation
1949	J. I. Perl	Intussuscepted Conical Valve	Experimental	
1951	D. E. Basso	Intussucepted Conical Valve	Experimental	X-ray, Icteric Index, Histology
1961	K. Torbey and W. R. Waddell	Denervated Ileal Segment	Experimental	Cineradiography, Histology, Manometery ?
1964	L. H. Stahlgren, et al.	Jejunal Pleating	Experimental	Absorption, Transit Time
1967	W. R. Schiller, et al.	Ablation of the Longitudinal Layer	Experimental	Weight loss and Survival rate
1969	F. W. Akroyd, et al.	Ileal Mucosal Valve	Experimental	Venous ammonia, Bacteriology
1970	W. R. Waddell, et al.	Jejunocolic Valve	Clinical	
1972	J. D. Richardson and W. O. Griffen Jr.	Ileocecal Valve Substitute, mucosal	Experimental	Absorption, Transit Time, Bacteriology
1973	F. Hidalgo, et al.	Intestinal Muscular Layer Ablation	Experimental	Absorption, Transit Time, Survival rate
1975	S. Tobik, et al.	Gastroesophageal Mucosal Valve	Experimental and Clinical	Cineradiography, Esophageal pH, Pressure
1976	H. Zheng, et al.	Telescoping Valve	Experimental	Microangiography, Electromanometry

The blood culture became positive when pressure exceeded 250 mmH_2O, and the number of E. Coli isolated was exponentially proportional to subsequent pressure increments. The use of the telescoping valve in biliary reconstruction is thus justified.

D. Artificial Intestinal Valve and Reversed Segment

Two main approaches are available either to delay gastrointestinal transit time so as to enhance intestinal absorption, or to prevent retrograde flow of the gastrointestinal contents so as to avoid bacterial contamination of proximal part of the digestive tract. One is insertion of a certain length of reversed intestinal segment, and the other is placement of an artificial intestinal valve in the remaining gastrointestinal tract.

The first recorded experiment with reversed segment of intestine in laboratory animals was performed by HALSTEDT and later reported by MALL[61]. It was not untill 1962 when GIBSON[62] published the first clinical success of this procedure. He reversed 7.5 cm of an intestinal segment in 84-year-old woman subjected to 90 % of massive bowel resection. The length of reversed segments in laboratory animals with long-term survival so far published varies from 3 to 10 cm, and reversal of 25 cm usually caused intestinal obstruction[63-65]. In clinical treatments of massive bowel resection and severe dumping sydrome, 7 to 17 cm segments[66-71] have been employed with reportedly favourable results. Some problems inherent in the reversed segment are : 1) The narrow margin which exists between a beneficial delay in transit which is within a physiological range, and a delay in transit which decreases absorption due to intestinal obstruction[22]. 2) Blood supply to the involved segment may be tenuous especially when massive resection is necessitated by an underlying splanchnic vascular insufficiency. 3) Healing of two or three anastomic lines when this techique is applied. Infection and perhaps, limited capacity to seal off and heal the wounds

are hazardous in the depleted patients[26]. 4) A barrier function against bacterial contamination canot be expected of a reversed segment. The function probably is important in all resections involving the ileocecal junction[27]. In view of those problems listed above, the author prefers the artificial intestinal valve to the reversed segment, and attempts to circumvent these problems with the use of the valve.

Table 8 is a summary of intestinal valves so far appeared on English literatures. Experiments on animals subjected to 50-90 % of bowel resection showed significantly higher survival rates and weight gain than controls in groups with the mucosal vavle[27-28], jejunal pleating[22], and ablation of the longitudinal muscular layer[23]. The principle of the intussuscepted valve has been recently revived by KOCK[72-77] to construct continent ileostomies in his total colectomy patients with excellent results[74-76]. Mucosal valve has been rather popular both in laboratory and clinical use. The techique dates back to 1942 when GLASSMAN[17] performed a series of expriment to create a valve resembling the ileocecal valve. HIDALGO[28] prepared this type of valve on 10 dogs with 80 % of the intestine resected. All the control dogs died within 5 months from malnutrition, whereas 5 in the treated group survived more than 5 months in a good nutritional state. The macroscopic study showed, however, progressive reduction of the invaginated mucosal fold to one third or one fifth of its original size ; in two cases it looked like a circular mucosal nubbin.

Through perusal of the literature, the author has not encountered any intestinal valve which had been thoroughly evaluated manometrically. Pressure gradient along the gastrointestinal tract is the main factor of the progression of intestinal contents. The function of any mechanism regulating the transit, be it a sphincter or a valve, should be considered from manometric point of view.

E. Factors Influencing the Function of an Artificial Valve

Spontaneous regression with time as HIDALGO[28] described, compromises final results of an artificial valve. A long-term follow-up study is indispensable in a search for a satisfactory artificial intestinal valve. The telescoping valve was followed up as long as 358 days. Though amplitudes of both IPP and APP in all experimental groups tend to decrease in long-term follow-up, the decrement was within such a degree as statistically non-significant. The author considers that participation of the muscular layer in an artificial valve is important when a stable valvular function is required. A valve without support of the muscular layer is liable not only to be reversed in direction by onset of high pressures in the distal intestine, but also to regress with time.

Proliferation of the submucosal tissue is a marked histological feature of author's valve. It is presumably attributable to relative ischemia[77] which might be present at the tip of the valve. The author expected this thickened submucosal layer to act as a helpful adjunct to valvular mechanism when he had first became aware of it. According to STIEVE[78-79], there usually is a stretch of venous plexus at the external opening and the junction of two hollow viscera, e.g. the pharyngoesophageal junction, cervical region of the uterus, prostatic urethra (colliculus), bladder neck (uvula of the bladder), and anus. The venous plexus filled with blood serves as a "compressible venous cushion" to keep these visceral openings tightly closed in cooperation with the sphincteric musculature, and on the other hand, when deprived of blood, to give way to passage of visceral contents. The human ileocecocolic junction was studied energetically by CARRVALHO, et al.[80-81] from morphofunctional point of view. They confirmed STIEVE's description, and found an enlargement of the venous bed and an increase in thickness of the tela submucosa in the terminal ileum towards the ileal papilla. The increase of the venous bed reachs it maximum about 2 to 3 cm oral to the papilla or in it. They regarded these findings as suggestive of a control

of the "compressible venous cushions" type, acting in the closing mechanism of the ileal outlet. All the above mentioned works support the author's initial speculation on the role of the submucosal tissue of the valve.

Devascularization of the telescoped intestinal segment was inevitable in construction of the valve with author's method. Too long an extent of devascularization naturally leads to necrosis and sloughing of the portion. In the current study, three different lengths of the devascularized intestine were chosen for construction of the valve. Manometric data revealed that the two diameter lengths group V2 was the most excellent as the artificial intestinal valve, while the one diameter length group V1 the poorest. The three diameter lengths group V3 stood just between these two groups. The explanation follows. Sloughing of the distal end of the telescoped segment occurred where it was beyond the scope of coverage by intramural circulation. Thus a shorter viable intestine than originally intended actually took part in valve formation. The event was well corroborated microagiographically and was found most frequently and markedly in the last group V3. Extent of mesenterial devascularization compatible with intestinal viability has been studied in man and laboratory animals. According to YUKI[82] and UEMURA[83], complete devascularization less than 4 to 6 cm caused no intestinal perforation in the dog. BOST[84] presented 3 cases in which patients suffered complete detachment of segments of the small intestinal mesentery varying in length from 4 to 8 inches (10 to 20 cm). The mesentery was resutured and omentum wrapped about it, after which the patients made an uneventful recovery. He also reported three experiments of this type in dogs, 2 of which survived after resection of 6 to 8 inches (15 to 20 cm) of mesentery. NOER[85] divided the intestinal arteries and arcuate vessels plus all the vasa recta to a 15 cm loop of the dog. Circulation of the loop in question was followed cinephotographically by injecting india ink into the superior mesenterial artery. Good filling of the devascularized loop was obtained in every case by way of intramural circulation alone. He concluded that intramural circulation was of far greater importance in revascularization than had hitherto been supposed. These reports strongly suggest that about 5 cm of such intestinal segment survives as treated in the present experiment for valve construction. The length corresponds almost to twice the mean intestinal diameter of the dogs used in this study. Here is one of the explanations why group V2 yielded the most similar results to those of the ileocolonic junction. Difference of species precludes, however, ready transfer of the results in animal experiments to clinical application. Intramural vascular communications of the human intestine have variably been described to be richer than those of the dog by one worker[86], while poorer by another[87] The optimal intestinal length to be telescopeed for construction of an effective valve remains to be further investigated clinically, based on these experimental data.

F. Healing Process of Telescoping Anastomosis

Conventional Albert-Lembert's two-row anastomosis and end-on suture are two trends of intestinal anastomosis currently in popular use. Telescoping anastomosis differs from those above mentioned techniques in that end-on apposition is entirely neglected between any corresponding layers of the intestinal wall to be sutured. The invagination principle itself is time-honoured. In the 11th century, the era of medieval medicine, preformed stents, such as a cylinder of hollow elder wood, a segment of goose trachea or dried animal intestine, were used to reduce the intestinal anastomotic obstruction which GALEN[88] so strongly feared. Invagination of the proximal intestine into the distal cut end served as an autologous stent. The earliest documented success of small bowel approximation was achieved by RAMDOHR[88] with telescoping anastomosis. The procedure has been periodically revived as new and been used clinically in various gastrointestinal reconstructions[89-91].

The experimental research history of the procedure, however, lagged far behind its clinical use. McCAUGHAN[92] is said to be the first to have performed experimental studies on this method. CUTHBERTSON[93] found that there was, in the rat, an inflammatory response mainly on the peritoneal surface of the invaginated portion of the bowel. This inflammation proceeded to granulation tissue formation, which contracted at an early stage so that the mucosal surface are gradually brought into apposition. Complete healing was not apparent until the twenty-fourth day. LINN, et al.[94] evaluated the use of the procedure with and without mucosal dissection for large and small bowel anastomoses of the dog. They concluded that invagination method of one inch intestine with mucosal dissection always compared favourably in function and appearence to controls. There still are deficient informations as to the healing process and function of telescoping anastomosis. Besides, attempt has never been made to construct with this procedure an equivalent of the ileocolonic junction except KIMBAROUSKI[91] to the knowledge of the author.

The author considers the following as characteristics of healing process of the anastomosis in question as compared with end on suture and conventional two-row invertion method. 1) The union of the sutured intestine was achieved first by the granulation bridge between the cut end of the recipient loop and the serosa of the invaginated loop. Mucosal continuity of the anastomotic site was reestablished on this connective tissue around the 60th postoparative day. In the interval, the inflammatory response and subsequent shrinkage of the serosa as well as of the longitudinal muscular layer, of the intussuscepted portion resutled in curling back of the portion and completion of the valve. 2) Proliferation of the submucosal vascularity was a marked feature on microangiographic study. Whatever the etiology may be, the consequence simulates the so-called "compressible venous cushion" present at the junction of two hollow organs in the human body[78-81], and serves to reinforce the closing mechanism of the newly created intestinal valve. 3) Obstruction and leakage are the most ominous complications of any kind of intestinal anastomosis. One inch of intussusception was reported without obstruction both in humans and dogs[89][94]. But, the longer the intussuscepted portion, the higher the risk for obstruction. The risk can be greatly reduced with deliberate selection of the length of the invaginating intestine for respective cases. Complications related to this type of anastomosis amounted to as high as 26.7% in author's series. Further efforts should be made in lessening complications without affecting valvular function. Validity of mucosal dissection of the recipient loop[44] is to be tested in accelerating healing process and enhancing safety of the procedure. Results of application of the valve to the ascending jejunal limb of Roux-en-Y cholecystojejunostomy have greatly encouraged its clinical use as an antireflux mechanism, though bacteriological studies remains to be performed. Since the valve resembles closely the ileocolonic junction manometrically in both iso- and antiperistaltic directions, the author believes that it is not only available in reconstruction of the gastrointestinal tract anywhere an antireflux mechanism or a bacterial barrier is required, but also may be useful in delaying transit time so as to increase intestinal absorption in patients subjected to massive resection of the bowel.

VI. Summary

1) An artificial intestinal valve was constructed with telescoping anastomosis in dogs, and its function was studied manometrically under pentobarbital anesthesia. Open-tip catheters with continuous perfusion system were used in intraluminal pressure measurements.

2) The canine ileocolonic junction served as controls. Mean isoperistaltic pressure and antiperistaltic pressure of the junction were calculated to be 20.4 ± 2.2 cmH_2O and 39.7 ± 5.1 cmH_2O, respectively. It is noteworthy that the junction failed to function as an

antireflux mechanism about once in every five antiperistaltic saline infusions.

3) The intestinal valve constructed by invaginating two diameter lengths of the intestine yielded the most similar result to those of the ileocolonic junction. Mean isoperistaltic pressure in this experimental group V2 was 25.0 ± 2.0 cmH_2O, and mean antiperistaltic pressure was 39.0 ± 3.8 cmH_2O.

4) Caliber changes on either side of the valve were assessed more than two months after the intial operation. Valvular function was compared between short-term groups (two months after operation) and long-term groups (six months more after operation). Neither significant intestinal dilatation proximal to the valve nor significant reduction of valvular function with lapse of time was found.

5) The union of telescoping anastomosis was achieved by granulation bridge between the serosa of the invaginated intestine and the cut end of the recipient loop. Mucosal continuity at the site of anastomosis was reestablished around 60 days postoperatively.

6) Emphases were made on the importance of participation of the muscular coat as well as on the important role of the submucosal vascular bed in construction of an effective valve.

7) The rate of complications in telescoping anastomosis was higher than in end-on suture or conventional two-row inverting suture. There is still room for improvements before the procedure is widely recommended for clinical applications. The risk may, however, be minimized with deliberate selection of the length used for creation of the valve. Validity of mucosal dissection of the recipient loop was suggested as one of the means to ensure the anastomosis without damaging valvular function. The goal to be attained is an artificial intestinal valve completely free from any complications. Its IPPs are always kept below 20 cmH_2O and APPs reach as high as 40 cmH_2O, but preferrably not exceed 50 mmHg (66 cmH_2O).

8) The valve formed with telescoping anastomosis is well qualified to fuction as an equivalent of the ilecocecal junction in the human body. It works on the one hand as an antireflux mechanism, and serves on the other hand, by delaying transit, to increase intestinal absorption in patients deprived most of their bowel.

Acknowledgements

The author is grateful to Prof. Dr. Yorinori Hikasa for his kind advices and corrections of the manuscript. Thanks are expressed to Dr. Kisaku Satomura and Dr. Kaoru Kumada. Their instructions and suggestions throughout the study have always been useful and encouraging to the novice author. Dr. Satoshi Onishi is remembered with hearty gratitudes. Without his sincere cooperation and endurance, the work would have hardly been a reality. The author also appreciates Dr. Nobuhiko Takigawa's skillful help in microangiographic study, and is much indebted to Dr. Yasuhiro Honda for his aid in histological investigation.

References

1) Koeberlé E . Résection de deux mètres d'intestin grêle. Bull Acad Med **45** : 128, 1881.
2) Singleton AO and Redmond DC Ⅱ Ileocecal resection and small bowel transit and absorption. Ann Surg **159** : 690-694, 1964.
3) Johansen H and Nylander G: Ileo-colic transit in rats subjected to ileo-caecal resection. Acta Chir Scand **135** 455-458, 1969.
4) Gazet J-C The surgical significance of the ileocecal junction. Ann Roy Surg Eng **43** : 19-38, 1968.
5) Chen, K. : Masive resection of the small intestine. Surgery **65** : 931-938, 1969.
6) Resenberg J C and DiDio LJA : Anatomic and clinical aspects of the junction of the ileum with the large intestine. Dis Col Rect **13** : 220-225, 1970.
7) Richardson JD : The importance of the ileocecal valve in intestinal absorption. Texas Rep Med **28** : 408-409, 1970.

8) Wilmore DW : Factors correlating with a successful outcome following extensive intestinal resection in newborn infants. J Pediat **80** : 88-95, 1972.
9) Reid IS : The significance of the ileocecal valve in massive resection of the gut in puppies. J Pediat Surg **10** : 507-510, 1975.
10) Gilchrist RK, Merricks JW et al : Construction of a substitute bladder and urethra. Surg Gyn Obst **90** : 752-760, 1950.
11) Lee CM : Transposition of a colon segment as a gastric reservoir after total gastrectomy. Surg Gyn Obst **92** : 456-465, 1951.
12) Hunnicutt AJ : Replacing stomach after total gastrectomy with right ileocolon. Arch Surg **65** : 1-11, 1952.
13) Najarian, JS, Murray DH et al : Utilization of the ileocecal valve as a substitute for the "cardioesophageal sphincter" Surg Forum **7** : 344-348, 1956.
14) Fuleihan FM and Cordonnier, JJ : Use of the ileocolic sphincter in urinary diversion: Preliminary observations in dogs. Surg Forum, **20** : 535-537, 1969.
15) Francesco PS, Zaini P et al : Use of the canine ileocolic valve to prevent reflux. J Urol **107** : 372-376, 1972.
16) Sullivan H, Gilchrist RK et al : Ileocecal substitute bladder : Long-term followups. J Urol **109** : 43-45, 1973.
17) Glassman JA : An artificial ileocecal valve. Surg Gyn Obst **74** : 92-96, 1942.
18) Peterson LW and Cole WH : Use of the defunctionalized loop of jejunum in biliary and pancreatic surgery. Arch Surg **56** : 445-458, 1948.
19) Perl JI : Intussuscepted conical valve formation in jejunostomies. Surgery **25** : 297-299, 1949.
20) Basso DE : The efficacy and applicability of an intussuscepted conical valve in preventing regurgitation and leakage of intestinal contents. Ann Surg **133** : 477-485, 1951.
21) Torbey K and Waddell WR : Function of the colon after removal of anal sphincters and replacement by denervated ileal segments. Ann Surg **154** : 424-431, 1961.
22) Stahlgren LH, Roy, RH et al : A mechanical impediment to intestinal flow —— Physiological effectson intestinal absorpti on. JAMA **187** : 41-44, 1964.
23) Schiller WR, DiDio LJA et al : Production of artificial sphincters. Ablation of the longitudinal layer of the intestine. Arch Surg **95** : 436-442, 1967.
24) Ackroyd FW, Giles G et al : Ileal mucosal valve to prevent reflux at the ileorectal anastomosis in the colon exclusion operation for hepatic encephalopathy. Surg Forum **20** : 356-357, 1969.
25) Pearson FG, Henderson RD et al: An operative technique for the control for eflux following esophagogastrostomy. J Thorac Cardiov Surg **58** : 668-677, 1969.
26) Waddell WR, Kern Jr et al : A simple jejunocolic "valve" for relief of rapid transit and the short bowel syndrome. Arch Surg **100** : 438-444, 1970.
27) Richardson JD and Griffen WO Jr : Ileocecal valve substitutes as bacteriologic barriers. Am J Surg **123** : 149-153, 1972.
28) Hidalgo F, Cortes M L et al : Intestinal muscular layer ablation in short-bowel syndrome. Arch Surg **106** : 188-190, 1973.
29) Moors DE, Collins WE et al : An intestinal valve in urinary diversion. J Urol **109** : 824-827, 1973.
30) Schneider KM and Ewing RS : The continent Vesicostomy. J Pediat Surg **10** : 221-224, 1975.
31) Quigley JP and Brody DA : A physiologic and clinical consideration of the pressures developed in the digestive tract. Am J Med **13** : 73-81, 1952.
32) Texter EC and Smith HW et al : Intraluminal pressures from the upper gastrointestinal tract. Gastroenterology **32** : 1013-1024, 1957.
33) Rinaldo JA and Levey JF : Correlation of several methods for recording esophageal sphincter pressures. Am J Dig Dis **13** : 882-890, 1968.
34) Texter EC, Chou C et al : Methods for studying gastrointestinal motor activities. In Physiology of the gastrointestinal tract, edited by the same authors, Saint Louis, The C V Mosby Company 1968, p 86.
35) Shepherd JK and Diamant NE : Mecholyl test : A comparison of balloon kymography and intraluminal pressure measurement. Gastroenterology **63** : 557-563, 1972.
36) Harris LD and Pope CE II : "Squeeze" vs. resistance : An evaluation of the mechanism of sphincter competence. J Clin Invest **43** : 2272-2278, 1964.
37) Winans CS and Harris LD : Quantitation of lower esophageal sphincter competence. Gastroe-

nterology **52** : 773-778, 1967.

38) Pope CE II : A dynamic test of sphincter strength Its application to the lower esophageal sphincter. Gastroenterology **52** 779-786, 1967.

39) Pope CE II Effect of infusion on force of closure measurements in the human esophagus. Gastroenterology **58** : 616-624, 1970.

40) Wienbeck M : The present status of esophageal manometry. Acta Hepato-Gastroenterol **23** : 59-67, 1976.

41) Cohen S and Harris LD Lower esophageal sphincter pressure as an index of lower esophageal sphincter strength. Gastroenterology **58** : 157-162, 1970.

42) Butterfield DG, Struthers JE Jr et al : A test of gastroesophageal sphincter competence. The common cavity test Dig Dis **17** 415-421, 1972.

43) Hollis JB and Castell DO : Amplitude of esophageal peristalsis as determined by rapid infusion. Gastroenterology **63** : 417-422, 1972.

44) Bloom AA, Stekelman M et al : Resting pressures in the lower esophageal sphincter. Am J Dig Dis **19** . 1120-1123, 1974.

45) DiDio LJA, Anderson MC The "sphincters" of the digestive system, Baltimore, The Williams & Wilkins Company 1968, p 152.

46) Johansen H and Nylander G : Analysis of the ileocecal emptying mechanism in the rat. Acta Chir Scand **134** : 296-302, 1968.

47) Davenport HW : Ileocecal sphincter. In Physiology of the disgestive tract. Devenport, H. W., Chicago, Year Book Medical Publishers, 3rd Ed 1971, p 67-68.

48) Walcker FI : Die Bedeutung der Bauchinischen und appendikulären Klappe. Experimentalle und anatomische Untersuchungen. Langenbecks Arch für klin Chir **170** : 706-721, 1932.

49) Wakefield E G and Friedell M T : The structural significance of the ileocecal valve. JAMA **116** 1889-1893, 1941.

50) Rendleman DF Anthony JE et al : Reflux pressure studies on the ileocecal valve of dogs and humans. Surgery **44** 640-643, 1958.

51) Tönnis W · Die Funktion der Valvula ileocoecalis. Pflügers Arch ges Physiol **204** 477-482, 1924.

52) Kelly ML Jr, Gordon EA et al : Pressure responses of canine ileocolonic junctional zone to intestinal distention. Am J Physiol **211** 614-618, 1966.

53) Cohen S, Harris L D et al : Manometric characteristics of the human ileocecal junction zone. Gastoenterology **54** 72-75, 1968.

54) Kelly ML, Gordon EA et al Pressure studies of the ileocolonic juntional zone of dogs. Am J Physiol **209** 333-339, 1965.

55) Painter N and Truelove SC The intraluminal pressure patterns in diverticulosis of the colon. Part I. Resting patterns of pressure. Gut **5** 201-207, 1964.

56) Deller DJ and Wangel AG : Intestinal motility in man : I. A study combining the use of intraluminal pressure recording and cineradiography. Gastroenterology **48** 45-57, 1965.

57) Ulin AW Die Funktion der Valvula ileocoecalis. Pflügers Arch ges Physiol **204** : 477-482, 1924.

58) Boley SJ, Agraw l GP et al : Pathophysiologic effects of bowel distention on intestinal blood flow. Am J Surg **117** 228-245, 1969.

59) Harry WM, Rigler LG et al : Experimental studies on biliary regurgitation during cholangiography. Gastroenterology **9** : 64-80, 1947.

60) Huang T, Bass JA et al : The significance of biliary pressure in cholangitis. Arch Surg **98** 629-632, 1969.

61) Mall F Reversal of the intestine. John Hopkins Hosp Rep **1** : 93-110, 1896.

62) Gibson LD, Carter R et al Segmental reversal of small intestine after massive bowel resection. Successful case with follow-up examination. JAMA **182** : 952-954, 1962.

63) Singleton AO and Rowe EB : Peristalsis in reversed loops of bowel. Ann Surg **139** : 853-857, 1954.

64) Stahlgren LH, Umana G et al : A study of intestinal absorption in dogs following massive small intestinal resection and insertion of an antiperistaltic segment. Ann Surg **156** 483-492, 1962.

65) Baldwin-Price JK and Singleton AO : Reversed intestinal segments in the management of anenteric malabsorption syndrome. Ann Surg **161** : 225-230, 1965.

66) Madding GF, Kennedy PA et al Clinical use of anti-peristaltic bowel segment. Ann Surg **161** . 601-604, 1965.

67) Thomas JF and Jordan GL : Massive resection of small bowel and total colectomy. Use of reversed segment. Arch Surg **90** : 781-786, 1965.
68) Shepard D : Antiperistaltic bowel segment in the treatment of the short bowel syndrome. Ann Surg **163** 850-855, 1966.
69) Fink WJ and Olson JD : The massive bowel resection syndrome. Treatment with reversed segments. Arch Surg **94** : 700-706, 1967.
70) Sawyers JL and Herrington JL Jr : Superiority of antiperistaltic jejunal segments in management of severe dumping syndrome. Ann Surg **178** : 311-321, 1973.
71) Pertsemlidis D and Kark AE : Antiperistaltic segment for the treatment of short bowel syndrome. Am J Gastroenterol **62** : 526-530, 1974.
72) Kock NG : Intra-abdominal "Reservoir" in patients with permanent ileostomy. Arch Surg **99** : 223-231, 1969.
73) Kock NG : Continent ileostomy. Progr Surg **12** : 180-201, 1973.
74) Beahrs OH, Kelly KA et al : Ileostomy with ileal reservoir rather than ileostomy alone. Ann Surg **179** : 634-638, 1974.
75) Kock NG, Darle N et al : The quality of life after proctocolectomy and ileostomy: A study of patients with conventional ileostomies converted to continent ileostomies. Dis Col Rect **17** : 287-292, 1974.
76) King SA Quality of life : The continent ileostomy. Ann Surg **182** : 29-32, 1975.
77) Morson BC : Histopathology of intestinal ischemia. In Vascular Disorders of the Intestine, edited by Boley SJ, Schwartz SS et al L. F., New York Meredith Corporation 1971, p 103-107.
78) Stieve H : Über die Bedeutung venöser wundernetze für den Verschluss einzelner Öffnungen des menschlichen Körpers. Deutsch Med Wochenschr **54** : 87-90, 1928.
79) Stieve H Über den Verschluss des menschlichen Afters. Ztschr mikro Anat Forsch **21** : 642-653, 1930.
80) Carrvalho CAF, Faintuch JJ et al . Morphofunctional study on the veins of the tela submucosa of the ileocecocolic junction. Acta Anat **83** : 248-261, 1972.
81) Carrvalho CAF, Costacurrta L et al : Beitrag zur Kenntnis der Submucosavenen der menschlichen Valva ileocäcalis. Anat Anz Bd **135** 495-503, 1974.
82) Yuki T : An experimental study on esophageal replacement with the small intestine. J Hiroshima Med Ass **6** : 623-666, 1958.
83) Uemura H Effects of intestinal arterial ligations on the supplied intestine. Jap J Surg Soc **64** : 559-589, 1963.
84) Bost TC Mesenteric injuries and intestinal viability. Ann Surg **89** : 218-221, 1929.
85) Noer RJ · Revascularization following experimental mesenteric vascular occlusion. Arch Surg **58** : 576-589, 1949.
86) Noer RJ : The blood vessels of the jejunum and ileum : A comparative study of man and centain laboratory animals. Am J Anat **73** 293-322, 1943.
87) Myers MB and Cherry G Use of vital dyes in the evaluation of the blood supply of the colon. Surg Gyn Obst **128** : 97-102, 1969.
88) Getzen LC : Intestinal Suturing. Part I : The development of intestinal sutures. In Current Problems in Surgery, Chicago, Year Book Medical Publishers, August, 1969.
89) Pringle JS : Method of end-to-end anastomosis in the small intestine. Brit Med J **2** 256, 1945.
90) Prioleau WH Rectosigmoid anastomosis by invagination in chronic inflammatory conditions. J Internat Coll Surgeons **13** : 388-393, 1950.
91) Ferrara BE Colorectal anastomosis by invagination. Dis Col Rect **9** : 113-115, 1966.
92) McCaughan JM Axial enteroenterstomy by a telescopic cuff method using a single row of continuous sutures · An experimental study. Surgery **37** 446-454, 1955.
93) Cuthbertson AM Healing of end-in-end anastomosis. Aust N J Surg **29** : 246-249, 1960.
94) Linn BS, Reisman TM et al. Intestinal anastomosis by invagination A historical review of a "new" technic with controlled study of its potential. Ann Surg **167** : 393-398, 1968.
95) Tobik S and Lukasiewicz S et al : An attempt at forming an effective gastresophageal mucosal valve. Surgery **77** : 225-230, 1975.
96) Zheng H, Onishi S et al : Manometric evaluation of an artificial intestinal valve. Arch Surg **111** : 578-581, 1976.

和文抄録

Telescoping anastomosis による人工腸弁の実験的研究

京都大学医学部外科学教室第2講座（指導：日笠頼則教授）

鄭　漢　龍

予備実験を含めて，雑種成犬121頭を用い，小腸に腸弁を作成し，その機能的評価，並びに，形態学的検索を行った．更に，腸弁の臨床応用への試みとしてModel 実験を付加した．

方　法

1）**腸弁の作成**：回盲部より約50cm口側にて回腸を切断．腸間膜を離断した口側腸管を肛側腸管内に挿入し，Telescoping anastomosis を行なった．一定期間を経て，腸弁を含めた約20cmの腸管を Thiry-Vella 腸瘻として曠置した．その約2週間後に，内圧測定により腸弁の機能を評価した．

2）**内圧測定**：装置は Open-tip polyethylene Catheter (o. d. 2.75mm, i. d. 1.5mm, infusion rate 5～6μL/sec), Transducer（低圧用 Nihonkoden LP U0.1), 及び Nihonkoden Recticorder RJG 3024. 実験群を，腸弁直径の1倍（V1), 2倍（V2), 及び3倍以上（V3）の3群に分け，腸弁機能の経時的観察を行う目的で，各群を更に，短期観察群（術后平均67.3日）と長期観察群（同191.6日）に2分した．対照としては以下の5群を用いた．即ち，回盲部（C1), 回盲部に形成術を加えたもの（C2), 端々吻合腸管（C3), 無処置腸管（C4）の4群を，各々 Thiry-Vella 腸瘻として曠置し，更に，第5群には開腹下に回盲部の直接内圧測定を行ったもの（C5）を加えた．

3）**形態学的検索**：Thiry-Vella 腸瘻作成時に，腸弁の口・肛側の腸管径を記録した．又，H-E, Van-Gieson, Mallory-Azan 染色，並びに Microangiography を用いて，腸弁と吻合部の創傷治癒の経時的過程を追求した．

4）**Model 実験**：Roux-en-Y Cholecystojejunostomy を4頭の犬に施行し，Y脚中央に腸弁を作成し，術後経過及び肝組織像を検討した．

結　果

1）**形態に関して**：Telescoping anastomosis 後，内筒は粘膜面から漿膜面へ向って外反し，内・外筒の粘膜層は漸次接近する．吻合2週目で，腸弁の肉眼的形態は整う．吻合部の創癒合は結合織の増生により達成せられ，その表面を新生粘膜が口・肛側双方より伸展し，ほぼ60日目に粘膜癒合が完成する．Microangiography により証明された粘膜下血管の増生は，Telescoping anastomosis による腸弁の特長の1つであり，弁機能発現に貢献するものと考えられる．

2）**機能に関して**：2倍直径挿入群（V2）が，内圧測定上最も優秀であり，回盲接合部によく近似する．即ち，順圧・逆圧はこの V2 群で 25.0±2.0 及び 39.0±3.8cmH_2O であり，回盲接合部のそれらは 20.4±2.2 及び 39.7±5.1cmH_2O である．腸弁の口側腸管には有意の拡張は認めず，且つ，長期 follow-up においても，弁機能に有意な変化は認められなかった．

結　語

1）消化管内差が内容輸送の原動力であるとすれば，消化管の全ての括約又は逆流防止装置の機能評価は内圧面より行なわれるべきである．

2）Reversed Segment との対比では，逆流防止作用と，それに伴う細菌汚染防止機能において，腸弁が勝ると考えられる．

3）Telescoping anastomosis による腸弁は，順圧・逆圧共に，回盲接合部に近似するので，大量腸切除術後の消化吸収能の向上及び各種消化管再建における逆流防止装置として応用出来る．Cholecytojejunostomy の Model 実験の結果はこの考えの妥当性を裏付けるものである．

4）本腸弁は端々吻合法に比して，動物死亡率はいまだ高く，腸弁自体に起因する死亡が全実験群平均26.7％に認められた．V2群では35.7％と更に高い．外筒の粘膜抜去その他による吻合の安全性向上が臨床応用上の課題である．