

Improvement of Femoral Head Coverage by Chiari-Osteotomy

WOLFGANG KÜSSWETTER, YASUSUKE HIRASAWA*

The Department of Orthopaedic Surgery, University of Würzburg, Federal Republic of Germany
(Director: Prof. Dr. A. RÜTT)

Received for Publication, Oct. 16, 1984.

Summary

In a macerated female pelvis, a CHIARI osteotomy was performed and medial displacement of the distal pelvic segment in a range between 0 and 2,5 cm was simulated. In relation to the medial displacement, the displacement of the hip joint in cranio-caudal direction, the width of the symphysis and the CE-angles were measured.

Parameters for planning of an operation were worked out.

Preface

In 1953, CHIARI suggested a simple pelvic osteotomy for the improvement of the acetabulum and reported in 1956 his first results with this operation. Since then, this procedure has become very popular.

The operation consists of a division of the innominate bone just above the acetabular roof and displacement of the distal pelvic segment in the medial direction. Enlargement of the acetabular roof is achieved by this movement which interposes the joint capsule between the lateral part of the femoral head and the osteotomy surface of the os ilium pointing downward to the femoral head. By enlargement of the roof of the acetabulum, the weight bearing surfaces in the hip joint are increased, the articular pressure is decreased and thereby the weight transmission between acetabulum and femoral head is improved.

In comparison to the compound periacetabular osteotomies having been published by Le COEUR (1965), MAGNER (1965), HOPF (1966), SUTHERLAND (1972), STEEL (1973) and TONNIS (1981), the simple osteotomy carried out in CHIARI's technique is a smaller operation. But this method also leads to considerable changes in the biomechanics of the hip joint and to deformation of the pelvis. Systematic examinations of the extent of the change in relation to the achieved improvement of the acetabulum have not yet been carried out. For the planning of the operation, the evaluation of the operation results and the estimation of the deforming of the pelvis caused by the operation, it seems to be desirable from a practical-clinical point of view to ascertain data, which allow of conclusions concerning the changes in the acetabulum and the pelvis which are due to the operation.

Key words: Chiari-osteotomy, Displacement of hip joint, CE angle.

索引語: Chiari 骨盤骨切り術, 骨盤変形度, CE角.

* Visiting Professor (Present address: Dept. Orthopaedic Surgery, Kyoto Prefectural University of Medicine)

Reprint request: Prof. W. Küsswetter, Department of Orthopaedic Surgery, University of Würzburg, König-Ludwig-Haus, 8700 Würzburg, F.R.G.

Material and Methods

The examinations of the simple pelvic osteotomy according to CHIARI were carried out on a macerated, normally developed, natural female pelvis. Also included were the femoral heads belonging to it, which were centred in the acetabula in 5° external rotation. The symphysis was fixed with a nylon wire ligature. The fixed position of the pelvis and the femoral heads was obtained by using foam rubber which allowed X-rays to pass through. The marking of the osteotomy lines was made by means of a chrome wire (Fig. 1). According to HOPF (1966), the postmortal rigidity of the ligaments and the symphysis in autoptic pelvic specimens prevent any tilting or torsion of the pelvis or deformation of the symphysis. Therefore, we preferred for our examinations the model mentioned above.

On the left side of the pelvis, an osteotomy was carried out according to the technique stated by CHIARI (CHIARI 1953, 1956, 1974). The plane of incision ran from the acetabular edge, rising slightly to dorsal to the incisura ischiadica. To make this clearer on the X-ray plate, the line on the lower segment was marked by chrome wire. The lateral edge of the acetabular margin was marked on the distal and proximal segment by a chrome wire tip 1 mm thick, so that the displacement of the distal segment to medial in relation to the proximal segment could be measured exactly. The turning point of the symphysis was simulated by a nylon thread fixed in the middle of both pubic bones.

The medial displacement of the distal segment of the pelvis was carried out in steps in positions of 0,5–1–1,5–2–2,5 cm. In each of these positions an a.p. pelvis X-ray in Bucky table technique was made with a focus-film-plate distance of 1 m.

For each of the given medial displacement values, the distanced between the pubic bones in the osseous pelvis was ascertained as the real distance between the upper symphyseal edges of the pubic bones (Fig. 2).

On the a.p. pelvis X-ray the following values could be determined:

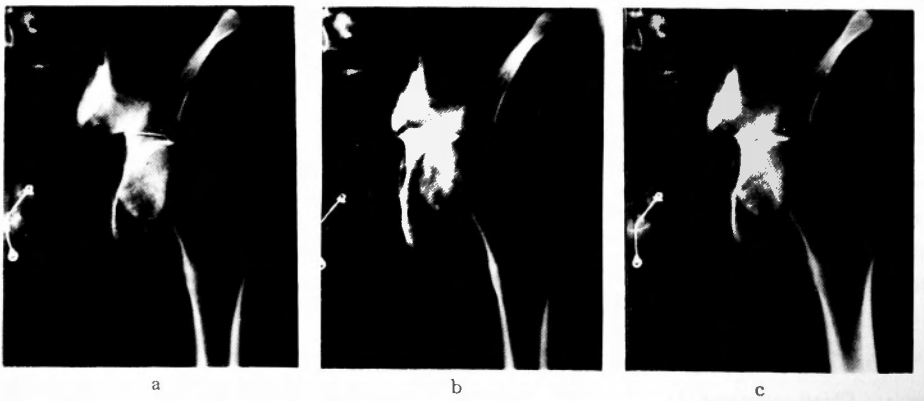


Fig. 1a-c. By medialization of the distal segment of the pelvis in steps, the increasing coverage of the femoral head by the proximal segment of the pelvis can be shown.
The original acetabulum is gradually steepened.

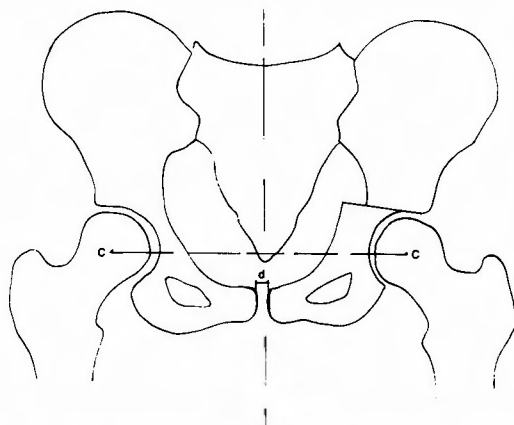


Fig. 2. Radiological measurement of the symphyseal distance "d"
Determination of the level of the femoral head centers.

1. The displacement of the hip joint in cranial-caudal direction by comparison of the level of the femoral head centres (Fig. 2).
2. The CE-angle of WIBERG to the original acetabular margin as an expression of the original development of the acetabulum. The measurement was carried out by means of an X-ray ischiometer, whereby the chrome wire marking on the acetabular margin of the distal segment as well as the femoral head centre was used to determine the CE-angle (Fig. 3).
3. The CE'-angle of WIBERG to the new acetabular margin as an expression of the post-operative improvement of the acetabulum. Beside the femoral head centre, the chrome wire markings on the acetabular margin of the proximal fragment were used as a point of relation (Fig. 3).

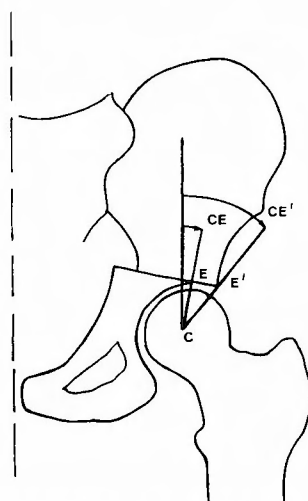


Fig. 3. Drawing of the CE angle (the original acetabular margin) and of the CE' angle (to the new acetabular margin)

Results

Symphyseal distance "d"

In all positions of medial displacement, we found an almost constant distance between the upper symphyseal edges of the pubic bones of about 1 cm, which corresponded to the original pre-operative value (Fig. 4).

Displacement of the hip joint in the cranial-caudal direction

A proximal or distal displacement of the hip joint could not be proved in any of the positions of medial displacement. The femoral head centres of the operated and non-operated sides always lay on the same level.

CE-angle to the original acetabular margin

With increasing medial displacement, the CE-angles determined in the a.p. pelvis exhibited a decrease in comparison to the original acetabular margin. The original CE-angle of 34° decreased to 18° with a medial displacement of 2.5 cm. This means a decrease of 47,1% (Fig. 5).

CE' angle to the new acetabular margin

The development of the CE' angle to the new acetabular margin exhibited a continual rise with increasing medialization of the distal segment of the pelvis. The development is therefore

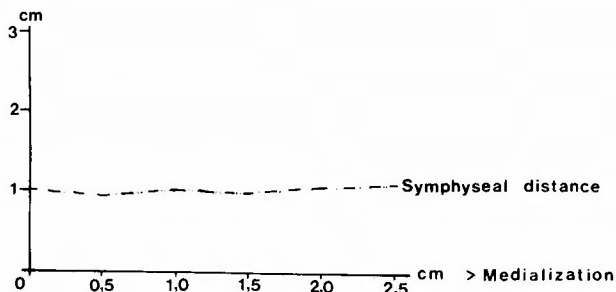


Fig. 4. Development of the symphyseal distance according to increasing medialisation of the distal pelvic segment.

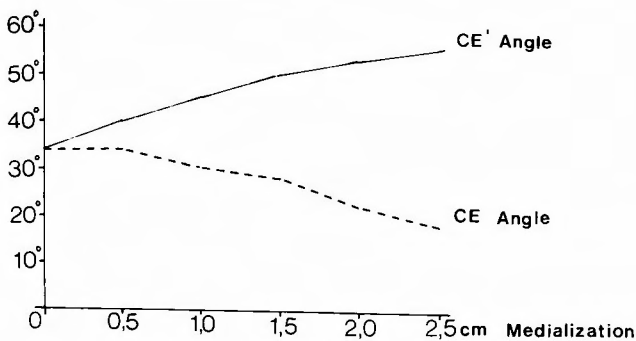


Fig. 5. Development of the CE angle and the CE' angle according to increasing medialization of the distal pelvic segment.

just the opposite to that of the CE angle to the original acetabular margin. With a medial displacement of 2,5 cm, we could observe an increase in the CE angle to the new acetabular margin of 61,8% (Fig. 5).

Discussion

The improvement of the acetabulum is achieved in CHIARI's simple pelvic osteotomy by moving the distal segment of the pelvis in the medial direction, whereby the lower cut-surface of the proximal segment of the pelvis protrudes as a new acetabular roof. This medial displacement is in reality a tilting movement around an axis, which runs in the centre of the symphysis from ventral to dorsal (A. N. WITT 1982) (Fig. 6). This tilting effect produces only little displacement of the symphysis even when the distal pelvic segment is medialized as far as 2,5 cm. The comparison of the CE angle to the original acetabular margin with the CE' angle to the new acetabular edge, however, makes this tilting effect clear (Fig. 5). The CE angle to the original acetabular edge becomes smaller as the medial displacement increases, i.e. the original acetabulum is steepened (Fig. 1). As a result of this, the conditions of weight transmission within the area of the cartilage covered joint surfaces become worse. The extent of the steepening of the acetabulum can be shown from the decrease of the CE angle which represents a measure for the coverage of the femoral head by the acetabulum:

With a medial displacement of 2,5 cm the CE angle exhibits a decrease of nearly one half of the original CE angle.

On the other hand, the improvement of the total acetabulum is documented very well by the increase of the CE' angle to the new acetabular edge. Here we could observe an increase up to 61,8% compared to the original figure.

These results mean that after a CHIARI pelvic osteotomy the transmission of weight of the hip joint takes place mainly in the area of the new acetabular roof which is not covered by cartilage. According to CHIARI, the interposed joint capsula is acting as a buffer tissue.

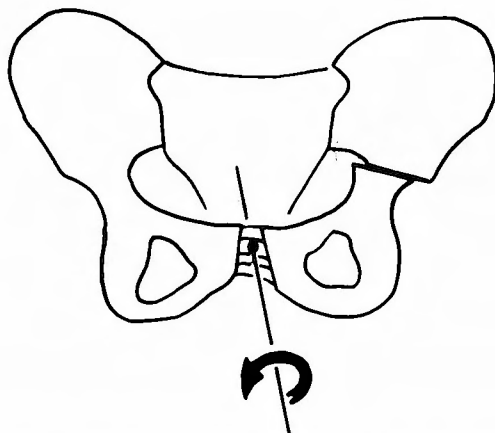


Fig. 6. Tilting movement of the distal pelvic segment

Bearing in mind that an enlargement of the new acetabular roof, thus achieved, leads to an increased steepening of the original acetabulum and thereby to unsatisfactory biomechanical conditions in the cartilage covered part of the acetabulum the intention of the operation can not simply be to gain a new acetabular roof as big as possible. The aim should be, however, to medialize the distal pelvic segment just as far as the femoral head gains sufficient coverage in its weight bearing part. Thus the medialization and the steepening of the acetabulum are reduced to the necessary minimum gaining an optimal increase of the weight bearing area in the joint at the same time.

Due to the fact that there is nearly a linear proportion between medial displacement and CE angle, the measured standard values allow quite an exact estimation preoperatively how far the distal pelvic fragment has to be displaced medially to achieve an optimal result.

References

- 1) Chiari K: Beckenosteotomie zur Pfannendachplastik. *Wien Med Wschr* **103**: 707, 1953.
- 2) Chiari K: Ergebnisse mit der Beckenosteotomie als Pfannendachplastik. *Z Orthop* **87**: 14-, 1956.
- 3) Chiari K: Medial Displacement Osteotomy of the Pelvis. *Clin Orthop* **98**: 146, 1974.
- 4) Hopf A: Hüftpfannenverlagerung durch doppelte Beckenosteotomie der Hüftgelenkdysplasie und Subluxation bei Jugendlichen und Erwachsenen. *Z Orthop* **101**: 559-, 1966.
- 5) LeCoeur F: Osteotomie isthmique de bascule Intern Symp Beckenosteotomie-Pfannendachplastik. Thieme, Stuttgart, 1965.
- 6) Steel HH: Triple Osteotomy of the Innominate Bone. *J Bone and Joint Surg* **550A**: 343-, 1973.
- 7) Sutherland DH, Greenfield R: Double Innominate Osteotomy. *J Bone and Joint Surg* **59-A**: 1082-, 1972.
- 8) Tönnis D, Behrens K, Tscharani F: Eine neue Technik der Dreifachosteotomie zur Schwenkung dysplastischer Hüftpfannen bei Jugendlichen und Erwachsenen. *Z Orthop* **119**: 253-, 1981.
- 9) Tönnis D: Indikation und Ergebnisse der Dreifach-Osteotomie nach Tönnis. *Vortr Intern Orthop Symp Würzburg*, 3. 7. 82 Thieme, Stuttgart, im Druck.
- 10) Wagner H: Korrektur der Hüftgelenkdysplasie durch die sphaerische Pfannendachplastik. Intern Symp Beckenosteotomie-Pfannendachplastik, Hrsg. G Chapchal Thieme, Stuttgart 1965.
- 11) Wiberg G: Studies on the dysplastic acetabula and congenital subluxation of the hip joint with special reference to the complication of osteoarthritis. *J Bone and Joint Surg*. 15, 16, 1939.
- 12) Witt AN: Gelenknahe Osteotomien bei der Dysplasiehüfte des Adoleszenten und jungen Erwachsenen. Thieme, Stuttgart, 1983.

和文抄録

Chiari の骨盤骨切り術による骨盤の変形についての研究

Würzburg 大学整形外科教室 (主任 : A. Rütt 教授)

W. Küsswetter, Y. Hirasawa

成熟女子の骨盤標本を用いて Chiari の骨盤骨切り術を行い、股関節部の上下方向への移動状態、恥骨部の中、CE 角の変動などについて追跡した。末梢側骨盤部の内側移動は 0~2.5 cm の範囲で行った。

それによると新しく形成された臼蓋には軟骨部がなく、その間に介在する関節包が干渉役を果たすことに

なり、また内側移動の程度と新しく生じた CE 角の間には互に相関々係を示すことがわかった。術前に末梢側骨盤部の移動程度を決定する際に、股関節部の上下方向への移動・恥骨結合間距離の変動、CE 角の変化などは考慮すべき重要な因子であることがわかった。