

Pelvic Deformity after Simple Pelvic Osteotomy

WOLFGANG KÜSSWETTER, HORST MAGERS, YASUSUKE HIRASAWA*

The Department of Orthopaedic Surgery, University of Würzburg, Federal Republic of Germany
(Director: Prof. Dr. A. RÜTT)

Received for Publication, Oct. 16, 1984.

Summary

The extent of pelvic deformity after simple pelvic osteotomies according to CHIARI's or SALTER's osteotomy was determined on a macerated, normally developed, natural and mature female pelvis. While the pelvic inlet plane is altered after a CHIARI pelvic osteotomy, it is essentially the centre and exitus of the pelvis which are transformed into a funnel shape after SALTER innominate osteotomy. These changes can query spontaneous labour.

Preface

The orthopaedic surgeon has a variety of operations at his disposal for the treatment of hip dysplasia, which aim at improving the dysplastic acetabulum. Of these, the simple pelvic osteotomy in CHIARI's (1953) or SALTER's (1961) technique respectively was most quickly adopted and is today the most frequently performed operation on the hip joint in order to improve the acetabulum (SCHREIBER and SPILLMANN 1982). Both techniques are indicated between early childhood and middle age, whereby the indication for CHIARI pelvic osteotomy has moved to the age group of juveniles and young adults. As hip dysplasia or congenital hip dysplasia occurs in the proportion 6 : 1 in female, both operations are mainly performed on the female pelvis. The frequent occurrence of bilateral dysplasia often requires bilateral operations, from which considerable pelvic deformation can result. Systematic examinations of the problem of deformation caused by these operations have not been made until now. There was, therefore, a practical clinical interest in finding out how the female pelvic was deformed by these two orthopaedic operations, and to examine what effects these pelvic deformations could have on the birth canal.

Biomechanical principle of CHIARI-osteotomy (1953, 1956)

The innominate bone is divided, starting from the acetabular margin and rising gently to the incisura ischiadica. After osteotomy, the distal pelvic segment is swung around an axis running from ventral to dorsal in the centre of the symphysis. By means of the displacement of the distal segment to medial, the lateral parts of the femoral head, which were hitherto not covered by the displaced shallow acetabulum, are now covered by the osteotomy surface of the

Key words: Pelvic osteotomy, Anthropoid pelvis, Funnel pelvis

索引語: 骨盤骨切り術, 骨盤形態異常, 出産障害.

* Visiting Professor (Present address: Dept. Orthopaedic Surgery, Kyoto Prefectural University of Medicine)

Reprint request: Prof. W. Küsswetter, Department of Orthopaedic Surgery, University of Würzburg, König-Ludwig-Haus, 8700 Würzburg, F.R.G.)

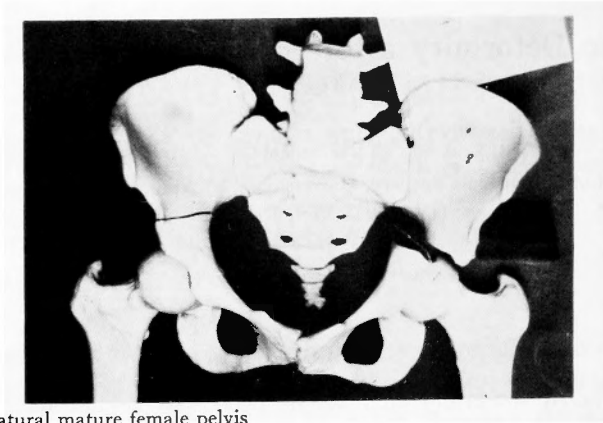


Fig. 1a. Natural mature female pelvis
A Chiari-osteotomy has been performed. The distal pelvic segment has been shifted medially.

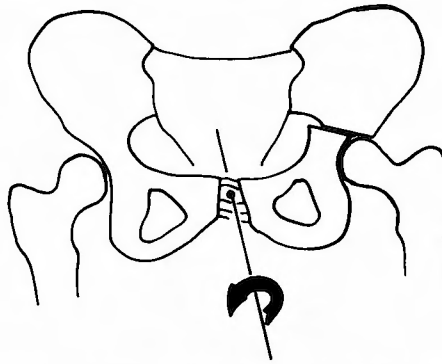


Fig. 1b. Biomechanical principle of Chiari's osteotomy: The distal pelvic fragment is rotated around an axis running from ventral to dorsal in the centre of the symphysis.

proximal pelvic segment. The operation leads to an enlargement of the acetabulum with its weight bearing area and thus to a decrease of pressure, which, in its turn, improves the transfer of weight-bearing from the acetabulum to the femoral head (Fig. 1a and b).

Biomechanical principle of SALTER osteotomy (1961)

The technique consists of a division of the innominate bone on the level of the spina iliaca ventralis inferior, and a tilting of the distal pelvic fragment with the acetabulum to lateral, ventral and distal by opening up the osteotomy site into a wedge shape. The displacement is maintained by a wedge-shaped autogenous bone graft from the iliac crest. The rotational movement of the distal pelvic segment takes place around an axis between the symphysis and the tip of the wedge-shaped osteotomy site in the area of the incisura ischiadica. The turning of the acetabulum around this axis enlarges the acetabular roof with its weight bearing area by means of which the distribution of weight-bearing between the acetabulum and the femoral head becomes optimal (Fig. 2a and b).

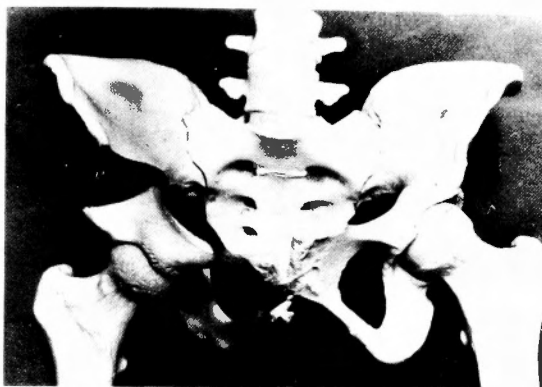

Fig. 2a. Natural mature female pelvis
A Salter-osteotomy has been performed and opened up into a wedge shape.

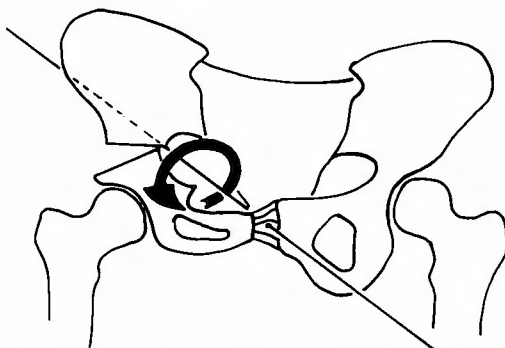


Fig. 2b. Biomechanical principle of Salter osteotomy: The distal pelvic segment is rotated around an axis between the symphysis and the tip of the wedge shaped osteotomy site in the area of the incisura ischiadica.

Material and Methods

We selected a macerated, normally developed, natural and mature female pelvis for our examinations.

On the left side of the pelvis, an osteotomy according to CHIARI's method was performed (CHIARI 1953, 1956, 1974). The point of intersection of the symphysis was simulated by a nylon thread in the centre of both pubic bones. The medial displacement of the distal segment was undertaken step by step in positions of 0,5–1–1,5–2–2,5 cm. (Fig. 1a).

An osteotomy according to SALTER's method was performed on the right half of the pelvis (SALTER 1961, 1966, 1976) from the centre of the spina iliaca anterior inferior in a straight line to the incisura ischiadica. The osteotomy was then opened up to lateral, ventral and caudal in typical manner, whereby attention was paid that corticalis lay on corticalis in the area of the incisura ischiadica. The respective angles of osteotomy were given by prefabricated plastilin wedges, which allow X-rays to pass through, of 10°, 20°, 30° and 40° (Fig. 2a).

For each of the positions of the pelvic osteotomy in the CHIARI and SALTER techniques, real measurements of the pelvis were obtained by means of sliding calipers with a Nonius scale

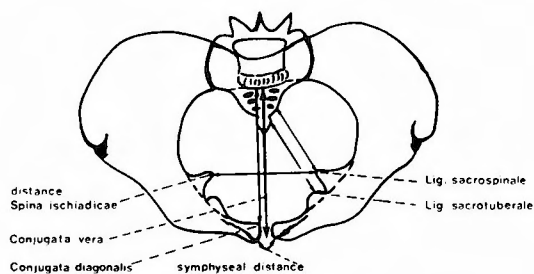


Fig. 3. Real measurements of the pelvis

(Fig. 3):

1. The distance between both spinae ischiadicae
2. The distance between the insertions of the ligamentum sacro-tuberale
3. The distance between the ligamentum sacro-spinale
4. The distance between the upper symphyses
5. The conjugata vera
6. The conjugata diagonalis.

Results

Pelvic osteotomy according to CHIARI:

In the area of the symphysis, there is no essential change in the distance, when a CHIARI osteotomy is performed (Fig. 4a). The conjugata vera (10,3 cm) and the conjugata diagonalis (11,4 cm) do not undergo a change either.

On the other hand, the oval of the cross-section of the pelvis running from side to side becomes smaller according to the extent of the medial displacement (Fig. 4a). Because of this, a pelvis whose oval shape ran formerly from side to side can become a pathological pelvis whose oval shape runs from back to front, a so-called anthropoid pelvis. The high longitudinal presentation would preclude a spontaneous birth (KIRCHHOFF 1958).

The CHIARI pelvic osteotomy creates no changes in the bone formation of the birth canal in the area of the centre and exit of the pelvis which would make child-bearing more difficult. The distance between the insertion of the ligamentum sacro-tuberale and sacro-spinale is subject to only small changes (Fig. 4a). Therefore one can assume that the associated slackening of the pelvis-tendon connection can be compensated by shrinkage in the months after the operation. The same is valid for the muscles of the floor of the pelvis, so that no lasting disadvantages may be expected here.

Innominate osteotomy according to SALTER:

Innominate osteotomy causes not only a deformation of the pelvis, but also changes in its tendon connections. The more the distal pelvic segment is tilted forward, outward and downward, an increasing enlargement of the upper distance between the symphyses takes place (Fig. 4b). If one follows the conception of KIRCHHOFF (1949) that a stretching of the symphysis

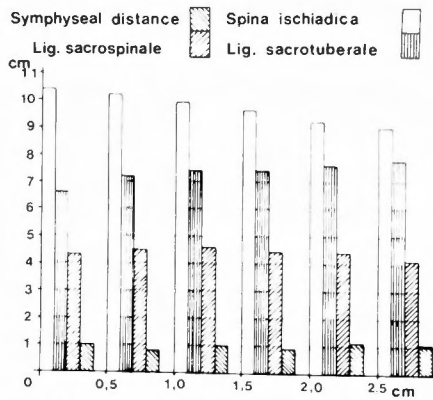


Fig. 4a. Measurements after Chiari-osteotomy

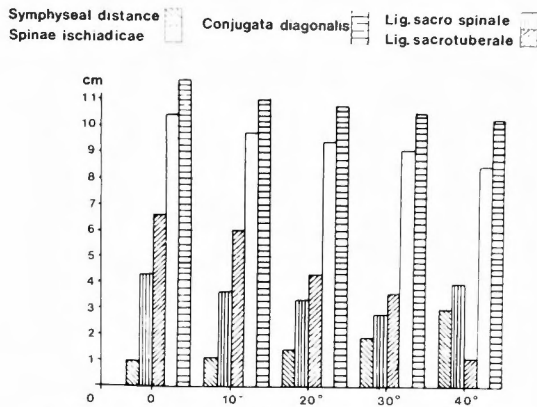


Fig. 4b. Measurements after Salter-osteotomy

of up to 1 cm in a child or a grown-up is possible, real angles of osteotomy of over 10° would lead to either a partial or a complete rupture of the symphysis.

In our measurements, we were able to establish that the figures for the conjugata diagonalis became smaller as the real angle of osteotomy increased. In the same way, the distance between the insertion of the ligamentum sacro-tuberale became steadily smaller. The same tendency can be observed in the ligamentum sacro-spinale up to an osteotomy angle of 30°. Thereafter, the length of this tendon increases.

Our examinations point to the fact that no changes in the pelvic inlet plane occur after a SALTER innominate osteotomy. The almost linear decrease of the conjugata diagonalis up to an angle of osteotomy of 40° by 1 cm can be ignored, as the conjugata vera undergoes no shortening (10,3 cm).

In the centre of the pelvis which corresponds to the distance between the spinae ischiadicae, a shortening of 1,3 cm takes place when the real angle of osteotomy amounts to 30°. In the centre of the pelvis, however, a shortening of 1,5 cm can prevent natural birth, as inner rotation and descent of the head are impeded (KIRCHHOFF 1949). If innominate osteotomy with an osteotomy angle of 30° were performed on both sides, this would create a pelvic deformity which

would no longer allow natural birth (Fig. 4b).

At the plane of the pelvic outlet, the length of the ligamentum sacrotuberale is the measurement relevant for child-bearing. This length is decreased by 3 cm if the angle of osteotomy is 30°. If it is decreased by only 2 cm, i.e. if the angle of osteotomy is larger than 15°, a natural birth is no longer possible as the rotation of the head is impeded thus leading to a transverse position.

Summarizing, we can say that the changes in the birth canal as a consequence of *SALTER* osteotomy result in a funnel shaped pelvis (*BORELL* and *FEINSTROM* 1981).

In the practical application of the technique, a real angle of osteotomy of more than 30° will not be exceeded because of considerations concerning the bio-mechanics of the hip joint. There are also changes in the pelvis for angles of osteotomy in the area of 0–30°, which can mean an obstacle to child-bearing. This is especially valid for the bilateral application of the operating technique.

Discussion

The data which we have determined relate only to the measurements of the pelvis on which they were carried out. From the practical clinical point of view, it is desirable to set up a general gynaecological assessment of the birth canal for those patients who have undergone a simple pelvic osteotomy according to *CHIARI* or *SALTER*. Among the methods stated in the literature (*KAUFFMANN* and *BOSCH* 1957, *HOCHULI* and *KAUFMANN* 1959, *ISHII* 1977), an a.p. pelvis in the position according to *MARTIUS* appears to be the most suitable in the first pregnancy (Fig. 5a). From the data of the X-ray (virtual values) the real value of the pelvic inlet plane can be calculated according to the *KIRCHHOFF* formula—

$$x = \frac{b \cdot x'}{a} \quad (\text{Fig. 5b})$$

a = distance between the focus and the x-ray plate

b = distance between the focus and the pelvic inlet plane of the patient

x' = measurement of the x-ray (virtual).

The greatest diameter of the child's head can be measured before birth by ultra-sound, and then compared with the real values calculated from the X-ray plate. If the greatest diameter of the child's head is smaller than the calculated real values in the centre and the exitus of the pelvis, a natural birth is possible. If the greatest diameter of the child's head is larger, a Cesarean section is indicated.

Both osteotomy techniques cause a deformity of the birth canal and thus problems for natural childbirth. Whilst the pelvic inlet plane is altered after a *CHIARI* pelvic osteotomy—the oval of the cross section of the pelvis running from side to side becomes a oval shape running from back to front (anthropoid pelvis)—it is essentially the centre and exitus of the pelvis which are transformed into a funnel shape after *SALTER* innominate osteotomy. Both authors (*CHIARI* 1956, *SALTER* 1976) report that their patients gave birth normally, but they do not go into any detail. The assessment of the post-operative pelvic deformity as an impediment to normal

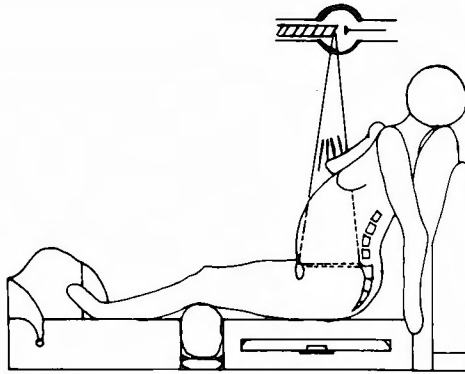


Fig. 5a. Martius x-ray technique for a.p. pelvis

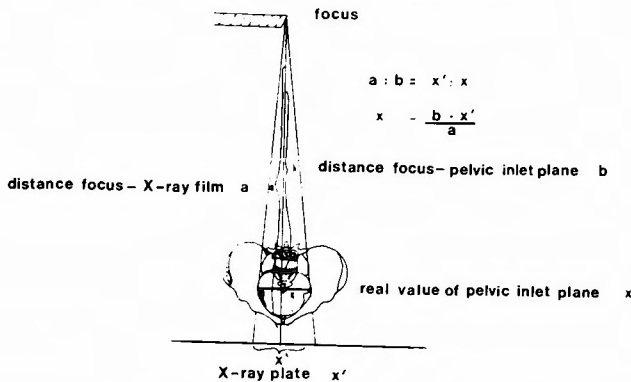


Fig. 5b. Kirchoff formula

childbirth is substantially dependent on the extent of the medial displacement, or rather the angle of osteotomy. Single observations point to the fact that a spontaneous remodelling in the course of development of the pelvis can take place in certain cases on whom osteotomies had been performed at an early age. The publication of ISHII (1978) about corresponding results stemming from experiments on animals underline these observations. In many cases, simple pelvic osteotomy is performed on children aged between 1 1/2 and 6, at a time following which the normal development of the birth canal from the childish "back to front" oval to the "side to side" oval of the adult woman capable of child-bearing takes place (KIRCHHOFF 1949). In order to assess the post-operative development, children who have undergone an osteotomy should have an X-ray plate taken in the Martius position in the prepuberty phase—at 10–11 years as well as a post-operative X-ray. To find out whether an impediment of natural childbirth in adult women exists after CHIARI or SALTER osteotomy an a.p. pelvis in the Martius technique should be carried out before pregnancy. The data gained from this X-ray as to the birth canal can be compared later with the greatest diameter of the head of the foetus in the ultra-sound picture and allow an exact assessment as to the possibility of a natural birth.

For the orthopaedic surgeon, there is the necessity to tell their female patients preoperatively about the later gynaecological consequences of pelvic osteotomy and to point to the necessity of

gynaecological control examinations. The gynaecologist ought to know about the possible consequences of this orthopaedic operation in order to assess labour risks correctly for the patients concerned.

References

- 1) Borrell U, Fernström J: Das weibliche Becken. in: Handbuch der Gynäkologie und Geburts-hilfe, Bd. 11/1, Hrsg. O Käser, V Friedberg, KG Ober, K Thomsen, J Jander, Thieme Stuttgart, 4: 1-4. 25, 1935.
- 2) Hochuli E, Kaufmann P: Die röntgenologische Beckenmessung Gynaekologica 148: 295, 1959.
- 3) Ishii Y: Zur Indikation der Beckenosteotomie. Ein Vergleich mit der Beckenosteotomie nach CHIARI. Z. Orthop. 116: 776, 1978.
- 4) Kaufmann P, Bösch K: Zur Methode der röntgenologischen Beckenmessung. Geb. Fra. 17: 413, 1957.
- 5) Kirchhoff H: Die postnatale Entwicklung des weiblichen Beckens. Zbl. Gyn. 71: 1051, 1949.
- 6) Kirchhoff H: Neue Erkenntnisse auf dem Gebiet der Röntgen-diagnostik in der Geburtshilfe. Geb. Fra. 5: 401, 1953.
- 7) Kirchhoff H: Aetiologie und Diagnostik des hohen Grad-standes. DMW, 83: 1651, 1958.
- 8) Martius H: Die geburtshilflichen Operationen. Thieme, Stuttgart, 1962.
- 9) Salter RB: Innominate osteotomy in the treatment of congenital dislocation and subluxation of the hip. J Bone and Joint Surg. 43-B: 518, 1961.
- 10) Salter RB: Role of innominate osteotomy in the treatment of congenial dislocation and subluxation of the hip in the older child. J Bone and Joint Surg. 48-A: 1413, 1966.
- 11) Salter RB: The first fifteen years personal experience with innominate osteotomy in the treatment of congenital dislocation and subluxation of the hip. Clin. Orthop. 98: 72, 1976.
- 12) Schreiber A, Spilimann A: Die Beckenosteotomie nach CHIARI, ihre Indikation und Technik, ihre Komplikation sowie ihre Ergebnisse anhand einer Landzeitstudie. in: Gelenknahe Osteotomien bei der Dysplasiehüfte des Adoleszenten und jungen Erwachsenen. Hrs. A Rütt, W Küsswetter, Thieme Stuttgart, 1983.

和文抄録

骨盤骨切り術による骨盤の変形に関する研究

Würzburg 大学整形外科学教室 (主任: A. Rütt 教授)

W. Küsswetter, H. Magers, Y Hirasawa

臼蓋形成の不良な例 (dysplastic acetabulum) に対して、以前より骨盤骨切り術がよく行われ、その代表的なものとして Chiari による水平骨盤骨切り術と Salter による寛骨骨切り術 (innominate osteotomy) がある。

本研究においては Chiari および Salter による骨盤骨切り術による骨盤の変形の程度について、正常に発育した成熟女子の骨盤標本 (浸漬骨) を用いて検索した。

Chiari の骨盤骨切り術によって骨盤入口部における変形 (anthropoid pelvis) が認められた。Salter による寛骨骨切り術によっては骨盤の漏斗状の変形が認められた。これらの骨盤の変形は正常分娩のさまたげになる可能性もあり、手術によって生ずる骨盤の変形の程度について、術前に十分に検討しておく必要があることを示唆した。