

Case Report

Acute epidural hematoma due to spinal venous angioma: A case report

Shiro Chitoku, M.D.^{a,*}, Iwao Nishiura, M.D.^a, Miyuki Fukuda, M.D., PhD^b,
Shigeru Amano, M.D., PhD^c

^a Center of the Spinal Surgery, Nipponbashi Hospital, Osaka-shi, Osaka, Japan

^b Department of Neurosurgery, Kyoto University, Kyoto-shi, Kyoto, Japan

^c Sakuragaoka Pathological Diagnostic Clinic, Kusatu-shi, Shiga, Japan



ARTICLE INFO

Keywords:

Acute spinal epidural hematoma
Venous angioma
Surgical treatment

ABSTRACT

Background: Spinal epidural cavernous angioma was reported about 4% of all spinal epidural tumors, mostly generating as a primary lesion in the vertebral bone. Spinal epidural hematoma (SEDH) due to angioma without primary origin was very rare, which reported in the English literatures was only 10 cases including our case. The main symptoms were numbness and pains and motor weakness owing to the acute compression signs of cord and roots. Emergency surgical treatment was required for the good surgical results.

We present a rare case of cervical acute epidural hematoma due to ruptured venous angioma.

Case presentation: A 78-year-old man, who suffered from sudden severe right suboccipitalgia., and sent to our hospital. He also noticed progressive numbness and motor weakness over his bilateral upper and lower extremities after the onset. Cervical CT and MRI showed acute intracanal hematoma over the right side of the cervical spine at C2 to C6. Emergency operation was performed 13 h after the onset. His sensory and motor symptoms were disappeared quickly after the operation. Pathological examination revealed spinal epidural hematoma due to venous angioma.

Conclusion: This case presented with acute progressive deterioration of paresis and sensory disturbance, and required emergency operation. Early diagnosis and emergency surgical treatment are essential for the therapy of acute spinal epidural hematoma due to venous angioma.

1. Introduction

Spinal epidural hematoma due to the vascular lesion is a rare disease that is mainly found in the thoracic spine and presents slow growth [1–3]. Spinal epidural cavernous angioma was reported about 4% of spinal epidural tumors, mostly generating as a primary lesion in the vertebral bone [4]. However, reported cases of acute epidural hematoma due to primary epidural angioma were very rare. Epidural angioma usually shows slowly progressive symptoms along with the growth of the lesion, and it has been reported to have a good surgical outcome. Upon reviewing the reported cases of acute epidural hematoma due to angioma [2,5–12], only 50% of the cases showed full recovery from the neurological deficits. We discuss the factors associated with good surgical results of spinal acute epidural hematoma due to angioma.

1.1. Case presentation

A 78-year-old man had been treated with anti-platelet drug for cerebral infarction since 62 years of age. He also took drugs for hypertension and diabetes mellitus. He suddenly suffered from severe right suboccipitalgia. He was taken to our hospital by ambulance. CT scan at emergency room revealed no intracranial hemorrhage. Neurological examination at emergency room revealed no clear neurological deficit except for the severe pain at cervical and occipital portion. He was treated with infusion and anti-inflammatory drug. He noticed numbness over his right upper extremity 6 h after the onset, and his numbness was gradually deteriorated with paresis and pain over his right upper extremity 8 h after the onset. Cervical MRI was performed, and indicated acute epidural hematoma over the right side of the cervical spine at C2 to C6. Emergency operation was performed 13 h after the onset.

Abbreviations: CT, computed tomography; MRI, magnetic resonance imaging; MMT, manual muscle test; AEDH, acute epidural hematoma; JOA, Japan orthopedic association

* Corresponding author at: Division of Neurosurgery, Shiraniwa Hospital, 6-1-10 Shiraniwadai, Ikoma-shi, Nara 6300136, Japan.

E-mail address: chitoku.s@allpines.jp (S. Chitoku).

<https://doi.org/10.1016/j.inat.2017.11.007>

Received 20 July 2017; Received in revised form 17 September 2017; Accepted 12 November 2017

2214-7519/ © 2017 The Authors. Published by Elsevier B.V. This is an open access article under the CC BY-NC-ND license (<http://creativecommons.org/licenses/by-nc-nd/4.0/>).

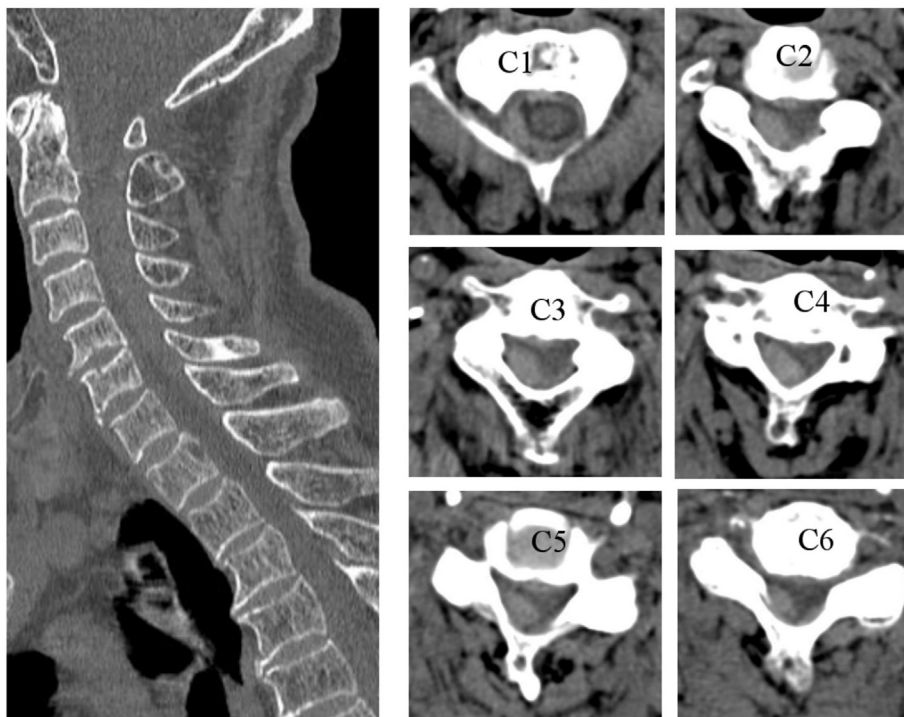


Fig. 1. CT showed an isodensity epidural mass over the right dorsal side that compressed the dural sac.

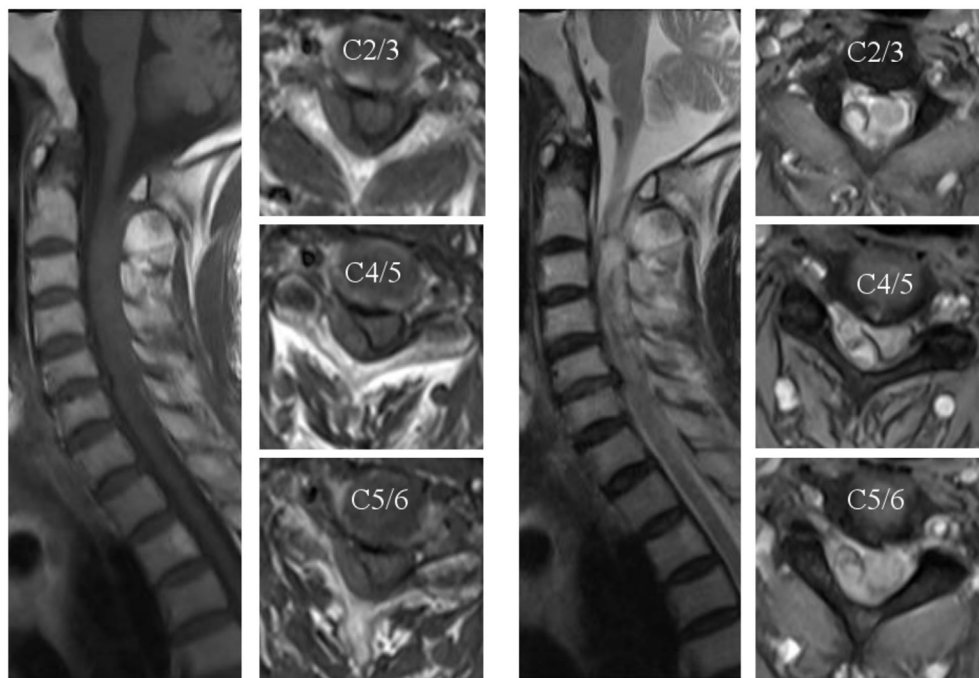


Fig. 2. MRI T1-weighted images (Left) and T2-weighted images (Right) indicated acute epidural hematoma with isointensity on T1-weighted image, and iso-/relatively high intensity on T2-weighted image.

1.2. Hematological data

Hematological examination was performed 9 h after the onset. All the hematological datum, bleeding time, coagulation datum was obtained 11 h after the onset, which revealed within normal limits.

1.3. Preoperative neurological findings

His clinical symptoms had been deteriorating. He presented bilateral paraplegia (MMT: 1/5) and severe paresis over the right upper paresis (MMT 1/5), and moderate paresis over the left upper extremity (MMT 3/5). As for sensory function, severe numbness over the right

upper extremity, and moderate numbness over the bilateral lower extremities and left upper extremity. Deep tendon reflex were severe hypo-active over the right upper extremity and bilateral lower extremities. He reported urinary disturbance. The severity of compressed region at cervicothoracic junction evaluated using the Japan Orthopedic Association (JOA) scoring system was 4/17.

1.4. Radiological findings

Cervical CT showed a relatively high-density mass at C2 to C6 (Fig. 1). Cervical MRI indicated thick epidural hematoma over the right dorsal side at the C2–C6 level, which compressed the cervical cord and roots (Fig. 2).

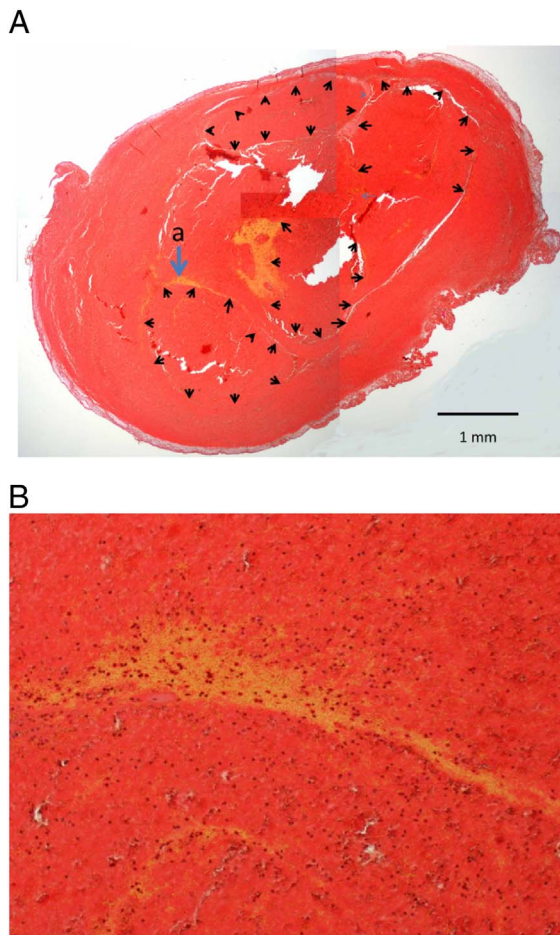


Fig. 3. A Multiple venous vessels with marked dilatation were ruptured. B. Vascular lesion consisted of smooth muscle tissue, stained by elastica van Gieson.

1.5. Operation

Right hemilaminectomy from the C2 to C6 level was performed. Thick epidural hematoma and epidural vascular lesion were dissected from the cranial side, and totally removed as an en bloc lesion. Because of the fragile epidural vascular lesion, a careful coagulation technique

was required for excision of the hematoma and vascular lesion. Operation was completed 16 h after the onset.

1.6. Pathological findings (Fig. 3A,B)

Small hematoma, sized 6.6 × 4.3 mm, was encapsulated with thin fibrous connective tissue and was composed of multiple dilated vessels with rupture. Because elastica van Gieson stain revealed the vessel walls had thin smooth muscle tissue, the lesion was diagnosed as hematoma due to ruptured venous (cavernous) hemangioma. The hematoma lacked fibrotic thickening of the capsule and surrounding tissue. No hemosiderin deposition showing persistent hemorrhage was also found. These findings showed this lesion was fresh and probably ruptured within 24 h. Easy and fair operation was due to thin capsule and no adhesion. Thus the operation was performed quickly after onset of hemorrhage in the venous hemangioma.

1.7. Postoperative course

The right hemiparesis completely disappeared within one day after the operation. Recovery from the sensory disturbance also occurred within one week. Post-operative JOA score was improved 17/17. Post-operative radiological studies revealed complete removal of hematoma and no deformity of vertebral bones around the surgical area (Fig. 4).

2. Discussion

Our case presented with acute deterioration of paresis and sensory disturbance due to epidural hematoma, which was caused by ruptured epidural angioma. We examined the patient soon after the appearance of new neurological symptoms, which lead to the correct diagnosis and quick treatment. Excellent results closely related with these speedy diagnosis and operation.

Generally, epidural angioma presents with slow growth, so the gradual appearance of symptoms is synchronized with the mass effect [1,2]. It is frequently generated on the dorsal side (93%) at the thoracic level (80%) [1,2]. Sudden deterioration is rare. About 5% of angioma cases present with acute subdural hematoma [1]. The patient in the present case suffered from sudden cervical pain and progressive right hemiparesis, which deteriorated within 8 h after the onset.

Concerning about the radiological examination, MRI was useful. Dural tail sign and rim of low signal intensity are reported for the MRI findings of angioma. Generally, radiological findings of angioma show

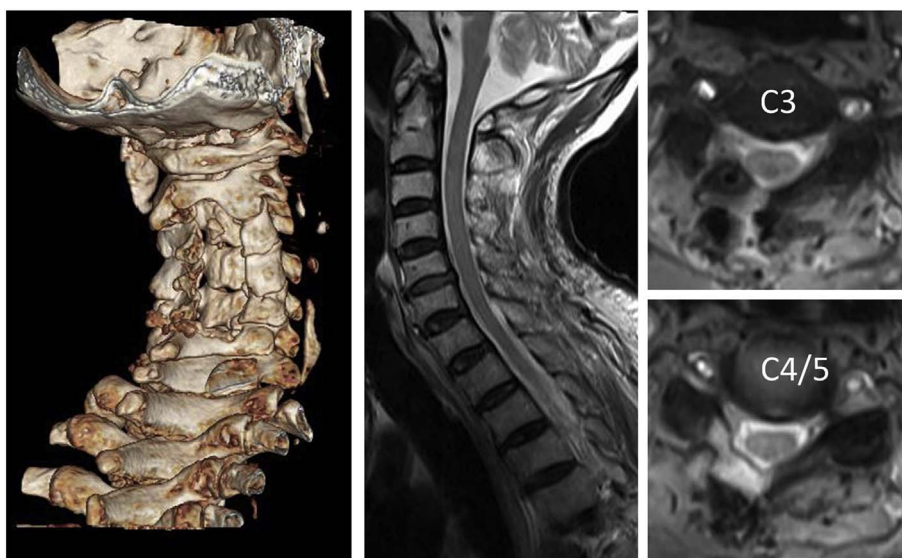


Fig. 4. Left: Three dimensional reconstructed image of cervical bone CT. Middle: MRI sagittal view on T2weighted image. Right: MRI axial views on T2weighted images. Post-operative CT showed hemilaminectomy over the right side from C2 to C7 (left). Post-operative MRI demonstrated total removal of epidural hematoma and good decompression over the surgical area(middle and right).

Table 1
Summary of acute spinal epidural hematoma due to epidural angioma.

Acute epidural hematoma due to epidural angioma										
No	Year	Author	Age/sex	Symptom	Level	Radiological examination	Operation method	Duration	Prognosis*	Pathological diagnosis
1	1979	Richrdson [4]	36/M	sudden pain and paresis over the L-shoulder and arm	C6–C7	Myelogram: partial defect	Laminectomy	1D	Good	Cavernous angioma
2	1986	Ogawa [5]	68/M	sudden paraparesis and total sensory loss below T5	T2–T5	CT: heterogeneous lesion over the Rt T2–5	Laminectomy	80 h	Fair: partial recovery	Cavernous angioma
3	1991	Hillman J ⁶	64/F	sudden paraparesis, back pain at mid thoracic	T4–T6	Myelogram: complete block at T5	Laminectomy	30 h	No change	Cavernous angioma
4	1994	Graziani N ²	41/F	Acute cervical pain + C7/motor deficit	C6–C7	T1,T2,Gd:enhanced	Laminaectomy + foraminotomy	1D	Excellent	Cavernous angioma
5	1997	Padovani R [7]	39//M	sudden cervicgia, tetraparesis, urinary retention	C3–C4	Xp, myelography, angiography: no vascular lesion	Laminec, total removal	1D	Good	Cavernous angioma
6	2005	Sanro A [8]	55/M	Acute worsening of R-lower ext. radicular pain, and foot paresis, hyporeflexia of ATR	T12-L1	T1:high, T2: high+relative high	Laminectomy	2D	Excellent	Cavernous angioma
7	2006	Jo BJ [9]	48/M	Acute radiculopathy	C3–C4	CT:high,T1:iso,T2:peri = high,cent = low, Gd: peripheral enhancement	hemilaminectomy	5D	Excellent	Cavernous angioma
8	2010	Sarikaya-Seiwert S ¹⁰	9/F	sudden R-radiculopathy and paresis of upperextremities	C7-T2	T1:iso,T2:high	laminectomy	1D	Excellent	Cavernous angioma
9	2013	Khalatbari MR [11]	74/F	acute severe paraparesis	T5–T9	T1,T2:mixed, Gd heterogeneous enhanced	laminectomy	3D	Fair: partial recovery	Cavernous angioma
10	2013	Present case	78/M	acute progressive radiculopathy and myelopathy	C2–C6	T1:iso,T2:high	laminectomy	13 h	Excellent	Venous angioma

Abbreviations: C = cervical, D = day, F = female, hrs = hours, I = lumbar, IE = lower extremity, M = male, RP = radicular pain, T = thoracic, T1 = T1 weighted image, T2 = T2 weighted image, W = week, *: excellent = full recovery from preoperative deficit, good = mild neurological deficit remained after post operative state, fair = partial recovery.

various changes depending on the bleeding sequences [13]. Lee categorized the MRI image of epidural angioma into four types: type A for a cyst-like mass with T1 hyperintensity, type B for a cyst-like mass with isointensity mass, type C for a solid hypervascular mass, and type D for an epidural hematoma. Based on this categorization by Lee, our case was type D, which is difficult to detect the angioma under acute bleeding state, because of the compression by the hematoma. MRI examination with enhanced medium was effective for the detection of spinal angioma, because the contrast medium enhances the vascular lesion. However, we should examine the patients promptly under careful neurological check in case of acute spinal EDH [13].

Neurological symptoms gradually progress along with the growth of the angioma, which compresses the cord and roots. Surgical outcomes of slowly progressing angiomas are better than those with acute deterioration of their symptoms [1]. About 60% of angioma cases with acute deterioration were reported to result in a poor prognosis [1]. As for the surgical treatment of spinal epidural angioma in acute stage, a gentle coagulation and dissection technique under a microscope is recommended to control the intraoperative bleeding.

For the safety during the spinal surgery and improving the surgical result, the neurophysiological monitoring is useful. It can help for the early detection of neurological deficits of spinal cord, cauda equine, and nerve root caused by the surgical procedures. Not only high risk spinal surgery, but also other low risk spinal operations, all spinal surgical procedures are recommended to perform under the appropriate neurophysiological monitorings [14,15]. We could not use the neurophysiological monitoring in this case, because of such emergency situation at midnight. However, we should make effort to establish the standard intraoperative monitoring system for the all spinal surgery including the emergency operation.

In our case, the patient took Propidogrel as a therapy of cerebral infarction. It usually takes about three to five days to recover normal platelet function following propidogrel withdrawal [16]; thus, surgeons have sometimes faced the problem of a lack of control of prolonged and diffuse bleeding from muscle and bone during emergency operations [17]. In our case, the patient took an anti-platelet drug; however, his preoperative bleeding time and coagulation function were within normal limits. We successfully performed en bloc resection of the epidural angioma and the hematoma.

Table 1 summarizes the reported cases of acute epidural hematoma due to ruptured epidural angioma [2,5–12]. We selected the 10 cases of acute epidural hematoma due to epidural angioma confirmed by pathological examination and for which the details of the pre- and postoperative clinical course are described. Patient age ranged from nine years old to 78 years old (mean, 51 years old). There were six males and four females. Five patients showed sudden severe neurological symptoms, and five patients presented with acute deterioration of their symptoms. All patients underwent surgical treatment. The numbers of lesions located at cervical, cervico-thoracic, thoracic and thoracolumbar regions were 5, 1, 3 and 1, respectively. The level of the lesion ranged from one to four vertebral levels (mean, 1.7 levels). The duration from onset to the operation ranged from thirteen hours to five days (mean, 2 days). As for the operation, all patients underwent prompt operation after consultation with a spinal surgeon. The surgical outcome of acute epidural hematoma due to angioma was not good. Table 1 indicates that cases with excellent, good, fair and poor outcomes numbered five, two, two and one, respectively. Fifty percent of the patients suffered from postoperative sequelae. It is difficult to predict a poor prognosis; however, the sudden appearance of motor symptoms, duration of onset to surgery and mass effect of the lesion are important factors for postoperative results. Sixty percent (three out of five) of the patients who underwent operation over 24 h after the onset showed sequelae. Fifty-seven percent of the patients (four out of seven)

whose MRI showed a lesion at over 2 vertebral levels had a postoperative neurological deficit. Moreover, 80% (four out of five) of the patients with sudden sensory-motor symptoms also presented with postoperative sequelae.

Concerning about the treatment, surgical treatment is recommended as soon as possible. Operation within 24 h after the onset helps to prevent postoperative sequelae [18,19]. Some cases of naturally improved acute epidural hematoma have been reported [20]; however, recurrence was reported in the case of epidural hematoma due to ruptured epidural angioma [3]. Because it is difficult to make a diagnosis of epidural vascular lesion with thick acute epidural hematoma, we concluded that surgical treatment and pathological examination should be performed quickly for good recovery from neurological deficits.

3. Conclusions

Because of the rebleeding from the vascular lesions such as angioma, surgical treatment should be performed as soon as possible for the good prognosis of acute epidural hematoma.

References

- [1] N. Aoyagi, K. Kojima, H. Kasai, Review of spinal epidural cavernous hemangioma, *Neurol. Med. Chir. (Tokyo)* 43 (2003) 471–475.
- [2] N. Graziani, P. Bouillot, D. Figarella-Branger, H. Dufour, J.C. Peragut, F. Grisoli, Cavernous angiomas and arteriovenous malformations of the spinal epidural space: report of 11 cases, *Neurosurgery* 35 (1994) 856–863.
- [3] B.C. Huffmann, U. Spetzger, M. Reinges, H. Bertalanffy, A. Thron, J.M. Gilsbach, Treatment strategies and results in spinal vascular malformations, *Neurol. Med. Chir. (Tokyo)* 38 (Suppl) (1998) 231–237.
- [4] R. Wyburn-Masson, *Vascular Abnormalities and Tumors of the Spinal Cord and Its Membranes*. London Kimpton, (1943), pp. 24–95.
- [5] R.R. Richardson, L.J. Cerullo, Spinal epidural cavernous hemangioma, *Surg. Neurol.* 12 (1979) 266–268.
- [6] T. Ogawa, T. Kikuchi, S. Ikeuchi, S. Sanada, T. Nakajima, I. Anno, CT findings in acute spinal epidural hematoma caused by a ruptured cavernous angioma, *No Shinkei Geka* 14 (1986) 687–691.
- [7] J. Hillman, O. Bynke, Solitary extradural cavernous hemangiomas in the spinal canal. Report of five cases, *Surg. Neurol.* 36 (1991) 19–24.
- [8] R. Padovani, N. Acciarri, M. Giolioni, R. Pantieri, M.P. Foschini, Cavernous angiomas of the spinal district: surgical treatment of 11 patients, *Eur. Spine J.* 6 (1997) 298–303.
- [9] A. Santoro, M. Piccirilli, R. Bristol, V. di Norcia, M. Salvati, R. Delfini, Extradural spinal cavernous angiomas: report of seven cases, *Neurosurg. Rev.* 28 (2005) 313–319.
- [10] B.J. Jo, S.H. Lee, S.E. Chung, S.S. Paeng, H.S. Kim, S.W. Yoon, et al., Pure epidural cavernous hemangioma of the cervical spine that presented with an acute sensory deficit caused by hemorrhage, *Yonsei Med. J.* 47 (2006) 877–880.
- [11] S. Sarikaya-Seiwert, K. Gierga, R. Wessalowski, H.J. Steiger, D. Hänggi, Solitary spinal epidural cavernous angiomas in children presenting with acute neurological symptoms caused by hemorrhage, *J. Neurosurg. Pediatr.* 5 (2010) 89–93.
- [12] M.R. Khalatbari, K. Abbassioun, A. Amirjmschidi, Solitary spinal epidural cavernous angioma: report of nine surgically treated cases and review of the literature, *Eur. Spine J.* 22 (2013) 542–547.
- [13] J.W. Lee, E.Y. Cho, S.H. Hong, H.W. Chung, J.H. Kim, K.H. Chang, et al., Spinal epidural hemangiomas: various types of MR imaging features with histopathologic correlation, *Am. J. Neuroradiol.* 28 (2007) 1242–1248.
- [14] R.R. Lall, R.R. Lall, J.S. Hauptman, C. Munoz, G.R. Cybulski, T. Koski, et al., Intraoperative neurophysiological monitoring in spine surgery: indications, efficacy, and role of the preoperative checklist, *Neurosurg. Focus.* 5 (2012) E10.
- [15] J.H. Park, S.J. Hyun, Intraoperative neurophysiological monitoring in spinal surgery, *World J. Clin. Cases.* 16 (2015) 765–773.
- [16] N. Heye, Is there a link between acute spinal epidural hematoma and aspirin? *Spine* 20 (1995) 1931–1932.
- [17] T.A. Nguyen, J.G. Diodati, C.P. PHARMD, Resistance to Clopidogrel: a review of the evidence, *JACC* 45 (2005) 1157–1164.
- [18] R.C. Seet, E.C. Lim, E.P. Wilder-Smith, B.K. Ong, Spontaneous epidural hematoma presenting as cord compression in a patient receiving clopidogrel, *Eur. J. Neurol.* 12 (2005) 811–812.
- [19] K.J. Song, K.B. Lee, The poor outcome of the delayed diagnosis of acute spontaneous spinal epidural hematoma: two cases report, *J. Korean Med. Sci.* 20 (2005) 331–334.
- [20] S. Wagner, M. Forsting, W. Hacke, Spontaneous resolution of a large spinal epidural hematoma. Case report, *Neurosurgery* 38 (1996) 816–818.