TWO CASES OF AN INTRASCROTAL CYSTIC MASS MIMICKING A TESTICULAR TUMOR AND REVIEW OF THE LITERATURE

Tomonori MINAGAWA[1], Naoki HIRABAYASHI[1], Masayuki FURUHATA[1], Tomoya SATO[1] and Toshikazu OKANEYA[2]

[1]*The Department of Urology, Saku Central Hospital*
[2]*The Department of Urology, Nagano Municipal Hospital*

A 39-year-old man had a 15-year history of an enlarging, firm, nontender mass on the right side of the scrotum after perineal trauma. Right high inguinal orchiectomy was performed, and the histopathological diagnosis was chronic hematocele. A 50-year-old man had a 2-year history of an enlarging, firm, nontender mass on the left side of the scrotum. Left high inguinal orchiectomy was performed. The histopathological diagnosis was a thick membranous hydrocele associated with chronic epididymitis. There were various clinical and histopathological similarities between the two cases. We discuss other intrascrotal cystic masses similar to our cases along with a review of the literature.

(Hinyokika Kiyo **52** : 311-314, 2006)

Key words : Chronic hematocele, Cholesterol granuloma, Chronic expanding hematoma

INTRODUCTION

A firm nontender intrascrotal mass is usually diagnosed as a testicular tumor, because intrascrotal pseudotumors are uncommon. Here we report a case of chronic hematocele and a case of thick membranous hydrocele, both of which resembled testicular tumors. These two conditions are compared clinically and pathologically, and other intrascrotal cystic masses similar to our cases are also discussed along with a review of the literature.

CASE REPORTS

Case 1

A 39-year-old man presented with a 15-year history of an enlarging, firm, nontender mass on the right side of the scrotum. He also had a history of perineal trauma during adolescence. The mass was asymptomatic, except for local discomfort caused by its size. Physical examination revealed that the right side of the scrotum was occupied by a firm nontender mass, which was more than 15 cm in diameter. The bilateral spermatic cords and the left testis were palpable, but the right testis could not be detected. Blood levels of markers for testicular tumors were within the normal range. Sonography revealed a round mass comprising two separate components of different echogenicities. The sonographic appearance suggested that the mass contained both fluid and a precipitate. Computed tomography revealed a cystic scrotal mass covered by a thick membrane and right testis compressed by the cystic mass. Right high inguinal orchiectomy was performed, since it was difficult to exclude a testicular tumor. On macroscopic examination, the resected mass was

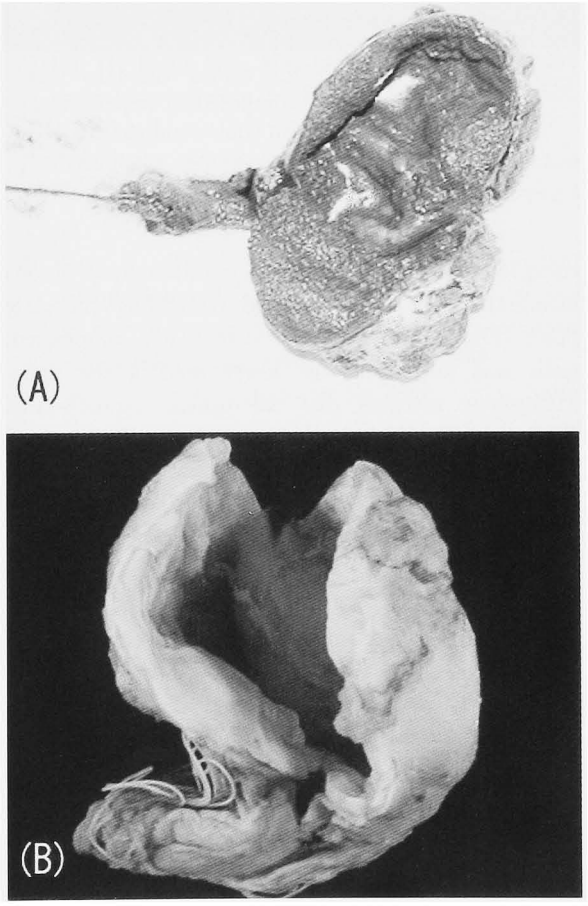

Fig. 1. (A) Case 1 : the mass was encapsulated within the tunica vaginalis by a fibrous membrane and contained fluid resembling chocolate sauce. (B) Case 2 : the mass was encapsulated within the tunica vaginalis by a fibrous membrane and contained clear yellow fluid.

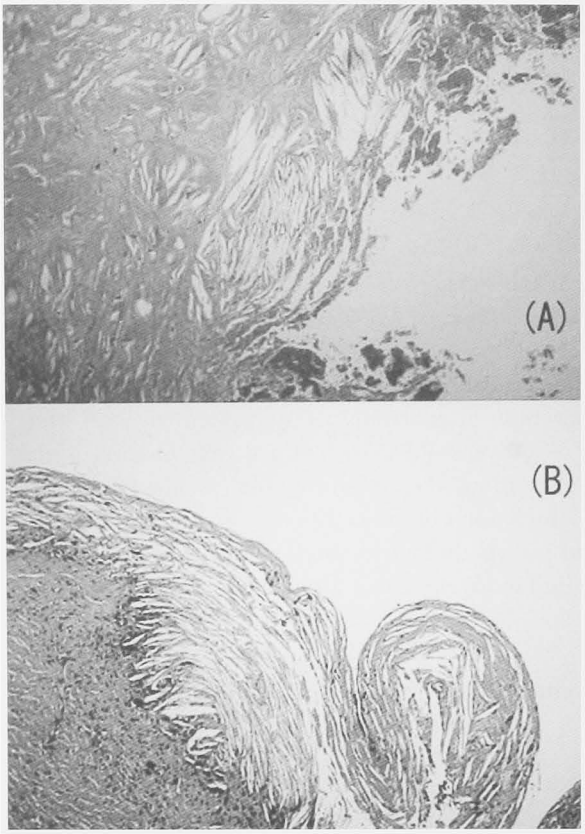

Fig. 2. (A) Case 1: the tunica vaginalis was thickened and composed of hypocellular fibrous tissue with cholesterol clefts. (B) Case 2: the tunica vaginalis was thickened and also composed of hypocellular fibrous tissue with cholesterol clefts.

encapsulated within the tunica vaginalis by a fibrous membrane and contained fluid resembling chocolate sauce (Fig. 1A). A grossly normal, but compressed, testis was located at the lower pole of the mass. Microscopy revealed that the tunica vaginalis was thickened, being composed of hypocellular fibrous tissue that contained collections of amorphous eosinophilic material and cholesterol clefts (Fig. 2A). The pathological diagnosis was chronic hematocele. The remaining testis was normal.

Case 2

A 50-year-old man presented with a 2-year history of an enlarging, firm, nontender mass on the left side of the scrotum. He has no history of perineal trauma or acute epididymitis. The scrotal swelling was detected by a routine physical examination when he was hospitalized for surgery on the palate. The mass was firm and measured 6 cm in diameter. The bilateral spermatic cords were palpable, as was the right testis, but the left testis could not be detected. Blood levels of markers for testicular tumors were within the normal range. Sonography revealed a hyperechoic mass in the scrotum. Computed tomography showed a cystic scrotal mass covered with a thick membrane and did not reveal the left testis. We performed left high inguinal orchiectomy because we could not exclude the possibility of a testicular tumor. Macroscopically, the resected mass was encapsulated within the tunica vaginalis and was surrounded by a thick membrane, while the cyst contained clear yellow fluid (Fig. 1B). Microscopy revealed that the tunica vaginalis was thickened and composed of hypocellular fibrous tissue with cholesterol clefts (Fig. 2B). There was also evidence of mild chronic epididymitis. Accordingly, the pathological diagnosis was hydrocele with mild chronic epididymitis.

DISCUSSION

Chronic hematocele is defined as a collection of blood that lies between the lamina visceralis and the lamina parietalis of the tunica vaginalis. On the other hand, chronic expanding hematoma can occur at many locations, including the chest, abdomen, thigh, and scrotum, and these lesions often resemble neoplasms[1]. Chronic expanding hematomas have a fibrous capsule surrounding old blood clots and the capsule arises from a strong membrane or fascia, such as the pleura, peritoneum, tensor fascia lata, or tunica vaginalis. On histopathological examination, cholesterol crystals can be found embedded in the walls of the hematoma. Chronic expanding hematoma is characterized by its persistence and continues to enlarge for more than one month after the initial episode of hemorrhage due to trauma or surgery. The mechanism underlying the expansion of such hematomas is still unclear. Lavadie et al. have proposed that breakdown products derived from erythrocytes, hemoglobin, leukocytes, and other blood components induce mild inflammation that leads to increased vascular permeability, resulting in intermittent bleeding from dilated microvessels beneath the fibrous capsule[2]. Fredlander et al. attributed continued expansion of the hematoma to an increase in the osmotic pressure gradient due to the breakdown of blood products comprising the lesion[3]. However, the threshold at which expansion commences is still unknown. A chronic expanding intrascrotal hematoma was previously reported only by Reid et al.[1], where as, chronic hematocele is often reported. Chronic hematocele resembles chronic expanding hematoma in clinical course and pathological findings. Therefore, these two entities might be considered as variants of the same condition.

The hydrocele of our case 2 was unusual and mimicked a testicular tumor. Lowental et al. previously reported a cholesterol granuloma of the tunica vaginalis, which was similar to our case 2 both clinically and histopathologically[4]. Cholesterol granuloma of the tunica vaginalis is a very rare inflammatory condition and cystic lesion containing yellowish clear fluid[5,6]. Cholesterol granuloma is also occasionally found in the middle ear[7]. It is composed of fibrogranulomatous tissue that contains numerous cholesterol crystals and foreign body giant cells. In our case 2, giant cells were not seen. However, giant cells

are not specific findings for cholesterol granuloma. A thick membranous hydrocele as in our case 2 might be the same condition as cholesterol granuloma.

The clinical course and the pathological features of our case 1 are similar to those of case 2 and cholesterol granuloma. However, the lesion in case 1 contained old blood clots, while that in case 2 contained clear yellowish fluid. The lesion of our case 2 may have been associated with infection because of the presence of mild chronic epidedymitis. Despite the possible difference of etiology, i.e., trauma or infection, cases 1 and 2 were very similar in terms of their clinical course and pathological features, with chronic inflammation being an essential feature in both patients.

In conclusion, chronic hematocele as in our case 1, thick membranous hydrocele as in our case 2, cholesterol granuloma of the tunica vaginalis, and chronic expanding hematoma of tunica vaginalis are similar in clinical course and histopathological findings. Due to the rarity of each entity, their clinicopathological features have not yet been fully clarified, but they can all be considered as variants of the same condition with a different etiology.

In the literature, only high inguinal orchiectomy was performed in the patients with an intrascrotal cystic mass as in our cases because it was difficult to exclude a testicular tumor preoperatively. Tumor resection without orchiectomy or with partial orchiectomy has not been reported. A differential diagnosis can be made from malignant mesothelioma of tunica vaginalis testis clinically and radiologically[8]. Malignant mesothelioma is often diagnosed as hydrocele preoperatively due to the cystic change and is similar to our case 2. It is difficult to distinguish malignant mesothelioma of the tunica vaginalis from other benign cystic masses as in our cases preoperatively, but malignant mesothelioma of tunica vaginalis testis grows rapidly. Slow growth as in our cases can be one finding for suspecting a benign lesion. In such cases, tumor resection without orchiectomy after intraoperative pathological diagnosis can be a treatment option. In our cases, high inguinal orchiectomy was performed, but retrospectively it could have been possible to spare the testis.

REFERENCES

1) Reid JD, Kommareddi S, Lankerani M, et al. : Chronic expanding hematomas : a clinicopathologic entity. JAMA **244** : 2441-2442, 1980
2) Lavadie EL and Glover D : Physiopathogenesis of subdural hematoma : Part 1, Histological and biochemical comparison of subcutaneous hematoma in rats with subdural hematoma in man. J Neurosurg **45** : 382-392, 1976
3) Friedlander HL and Bunp RG : Chronic expanding hematoma of the calf. J Bone Joint Surg Am **50** : 1237-1241, 1968
4) Lowenthal SB, Goldstein AMB and Terry R : Cholesterol granuloma of tunica vaginalis simulating testicular tumor. Urology **18** : 89-90, 1981
5) Wollheim HH : Ein Beitrag zur Lehre von den Pseudogeschw lsten der Tunica vaginalis propria testis. J Urol Chir **26** : 66-73, 1929
6) Lin JI, Tseng CH, Marsidi PJ, et al. : Cholesterol granuloma of right testis. Urology **14** : 522-523, 1979
7) Friedmann I : Epidermoid cholesteatoma and cholesterol granuloma. Ann Otol Rhinol Laryngol **68** : 57-79, 1959
8) Plas E, Riedl RC and Pflvger : Malignant mesothelioma of the tunica vaginalis testis : review of the literature and assessment of prognostic parameters. Cancer **83**, 2437-2446, 1998

(Received on June 23, 2005
Accepted on October 13, 2005)

和文抄録

精巣腫瘍と鑑別が困難であった陰嚢内嚢胞性腫瘤の2例とその類縁疾患に関する文献的考察

皆川　倫範[1]*，平林　直樹[1]，古畑　誠之[1]
佐藤　智哉[1]，岡根谷利一[2]
[1]佐久総合病院泌尿器科，[2]長野市民病院泌尿器科

症例1：39歳，男性．15年前から徐徐に増大したが放置した．2004年5月に当院を受診した．腫瘤は経15 cmで両側精管と左精巣を触れるが右精巣を触れない．腫瘍マーカーは正常範囲内であった．CTでは造影効果を認めない陰嚢内嚢胞性病変を認めた．右高位精巣摘除術を施行した．手術では腫瘤の剥離は容易であった．摘出標本は厚い皮膜に覆われた嚢胞性病変で中身はチョコレートソース様の液体で満たされていた．病理診断は陳旧性血瘤であった．症例2：50歳，男性．2年前から徐徐に陰嚢内容が増大したが放置した．2004年．当科を受診した．腫瘤は6 cmほどで両側の精管をふれ右の精巣も触れるが左の精巣をふれない．腫瘍マーカーは正常範囲内であった．CTでは造影効果を認めない陰嚢内の嚢胞性病変を認めた．左高位精巣摘除術を施行した．手術では腫瘤の剥離は容易であった．摘出標本は厚い被膜に覆われた嚢胞性病変で中身は透明な黄色の液体で満たされていた．病理診断は慢性精巣上体炎と壁肥厚を伴った陰嚢水腫であった．われわれは精巣腫瘍と鑑別が困難な外傷性の陳旧性血瘤と壁肥厚を伴った陰嚢水腫を経験した．それらを臨床的・病理組織学的に比較し，それらの類縁と思われる疾患について文献的に考察した．

（泌尿紀要 **52**：311-314，2006）

* 現：長野市民病院泌尿器科