Acta Urol. Jpn. 36: 471-473, 1990

TRAUMATIC DISLOCATION OF THE TESTIS: A CASE REPORT

Jiro Ishikawa, Atsushi Sengoku and Kei-ichi Umezu
From the Department of Urology, Kobe National Hospital
Hiroshi Eto and Masuyoshi Harada
From the Department of Urology, Shin-Suma Hospital
Sadao Kamidono
From the Department of Urology, Kobe University School of Medicine

We report a case of a traumatic dislocation of the testis in a 17-year-old male. He noticed lack of right scrotal contents three months after a motorcycle accident. The right testis, located at the inguinal subcutaneous region, was surgically replaced into the scrotum. The biopsy specimen of the dislocated testis showed partial atrophy of the seminiferous tubules that resulted in impaired spermatogenesis. Our case represents the 57th case of traumatic dislocation of the testis reported in Japan.

Key words: Dislocation, Testis, Motorcycle accident

INTRODUCTION

Traumatic dislocation or luxation of the testis is a rare event first described by Claubry[1] in 1818. To date, less than 60 cases have been reported in Japan. We report an additional case, which occurred by a motorcycle accident, and briefly review the literature.

CASE REPORT

A 17-year-old male complained of lack of right scrotal contents. Three months previously, he had been in a motorcycle accident with brain contusion. He claimed the right testis to be in the scrotum before the accident. Physical examination revealed a fixed right testicle in the right inguinal region. Ultrasound sonography showed no evidence of rupture or atrophy of the dislocated testis (Fig. 1). Manual manipulation of the displaced testicle was unsuccessful. Under lumber anesthesia, a right inguinal incision was made, and the testis was found to be between the external oblique muscle and Scarpa's fascia. Fibrous adhesion was carefully detached. Examination of the testis showed no laceration of the tunica albuginea. The right testis was brought down into the scrotum after testicular biopsy. The histological examination of the dislocated testis revealed hyalinization and atrophy in one fifth of all the seminiferous tubules resulting in reduced spermatogenesis (Fig. 2).

Postoperative course was uneventful and the patient was discharged on the eighth postoperative day.

DISCUSSION

Testicular dislocation is defined as displacement of a normally-located testicle out of the scrotum. The majority of cases occur at the time of trauma. Alyea[2] classified dislocation of the testis into three types ; superficial, internal, and compound dislocation. Superficial dislocation is further classified into pubic, superficial inguinal, penile, perineal and crural types depending on the anatomical location of the dislocated testis. Internal dislocation is also classified into inguinal, femoral, and abdominal types. In compound dislocation, the testis is extruded through a scrotal laceration.

To the best of our knowledge, 57 cases of dislocation of the testis have been

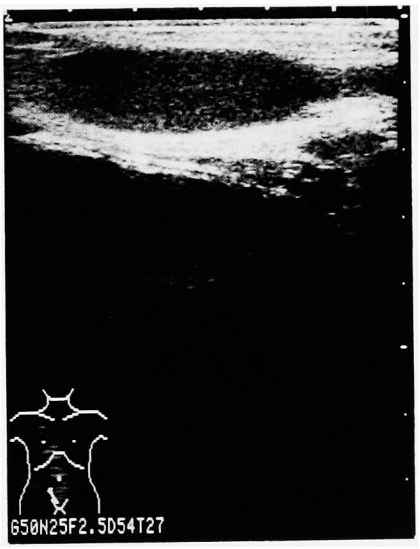

Fig. 1. Ultrasound sonography revealed the dislocated right testicle with no signs of rupture.

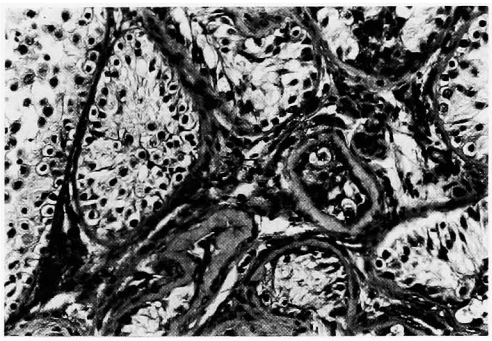

Fig. 2. Testicular biopsy specimen revealed the hyalinization of the basement membrane of the seminiferous tubules resulting in their atrophy in about one fifth of them.

reported in Japan including our case[3-9]. Thirty-one cases were superficial dislocation, 6 cases internal dislocation, 19 cases compound dislocation, while the type of dislocation was not described in the remaining one case. Of the 31 cases of superficial dislocation, 26 cases were superficial inguinal type, being the most common type.

Among the 22 cases reported after 1970, motorcycle accidents are the most common cause of the testicular dislocation (9 cases out of 22).

Treatment of the dislocation should be replacement of the testis by operation or manual procedure.

Morgan[10] reported that the dislocated testis could be corrected non-operatively within 4 days of injury provided the initial edema is minimal and fibrosis does not occur. However, operative reduction has been performed in most cases. This may be partly due to the delay of detection of the dislocated testis. Most patients with traumatic dislocation of the testis have multiple injuries, thus the dislocated testis is usually overlooked by doctors unless the patient himself is aware of it. Testes of the traumaic patients, especially those caused by motorcycle accidents, should be examined carefully at the initial stage.

Early detection is important to avoid disturbance of the spermatogenesis in the affected testis, because a long standing increase of temperature around the dislocated testis may result in atrophy of the seminiferous tubules as observed in our case. The possibility that the right testis has been originally located at the inguinal region or that the right testis was movable testis should be considered in our case, because the spermatogenesis was so much compromised.

REFERENCES

1) Claubry E: Observation sur une retrocession subite des deux testicules dans l'abdoman, a la suite d'une violente compression de la partie inferieure de la paroi abdominale par une roue de chassette. J Gen Med Chir Pharm **64**: 325-330, 1818
2) Alyea E: Dislocation of the testis. Surg Gynaecol Obstet **49**: 600-616, 1929
3) Sato Y, Onoe Y and Yamamoto C: A case of testicular compound luxation with penis fracture. J Clin Urol **31**: 259-263, 1976 (in Japanese)
4) Hoshino H, Tanaka M, Hihara T, Goto K and Inokuchi S: A case of testicular luxation. Jpn J Urol Surg **1**: 1085-1087, 1988 (in Japanese)
5) Yanagisawa T, Ksesguch T and Suzuki T : A case of traumatic luxation of the testis. Jpn J Urol Surg **2**: 179-182, 1989 (in Japanese)
6) Minamikata S: A case of compound disloca-

tion of the testis and penis (abstr). Jpn J Urol **75**: 720, 1984 (in Japanese)
7) Ito H and Okano J: A case of traumatic dislocation of the testis (abstr). Jpn J Urol **79**: 381, 1988 (in Japanese)
8) Aida Y and Imon S: A case of traumatic dislocation of the testis (abstr). Jpn J Urol **79**: 2054, 1988 (in Japanesee)
9) Hirai K, Kamihara A, Izumi T and Takasaki N: A case of traumatic dislocation of the testis (abstr). Jpn J Urol **80**: 478, 1989 (in Japanese)
10) Morgan A: Traumatic luxation of the testis. Br J Surg **52**: 669-672, 1965

(Received on June 23, 1989
Accepted on August 5, 1989)

和文抄録

外傷性精巣脱出症の1例

国立神戸病院泌尿器科（医長：梅津敬一）
石川　二朗，仙石　　淳，梅津　敬一
新須磨病院泌尿器科（医長：原田益善）
江藤　　弘，原田　益善
神戸大学医学部泌尿器科学教室（主任：守殿貞夫教授）
守　殿　貞　夫

17歳の男子にみられた外傷性精巣脱出症の1例を報告する．患者はオートバイ事故3カ月後，右陰嚢内容の欠如を自覚し，泌尿器科受診，外傷性精巣脱出症と診断された．手術時，右精巣は鼠径部皮下に存在しており，これを陰嚢内に整復した．脱出精巣の生検組織像では精細管の部分的な萎縮があり，造精能は低下していた．自験例は本邦第57例目である．

（泌尿紀要 **36**：471-473，1990）