A CASE OF PROSTATE CANCER WITH A LARGE ABDOMINAL MASS EFFECTIVELY TREATED WITH A HIGH DOSE OF DIETHYLSTILBESTROL-DIPHOSPHATE

Masami Wakisaka and Hidetoshi Takagishi

From the Department of Urology, Social Insurance Funabashi Chu-Oh Hospital

A case is reported about a 75-year-old man with a large abdominal lymph node metastasis caused by prostate cancer effectively treated by a high dose of diethylstilbestrol-diphosphate. The usefulness of diethylstilbestrol-diphosphate for prostate cancer patients with lymph node metastasis is emphasized.

(Acta Urol. Jpn. 39: 849-851, 1993)

Key words: Prostate cancer, Abdominal mass, Diethylstilbestrol-diphosphate

INTRODUCTION

Although staging pelvic lymphadenectomy show that small lymph node metastases of prostate cancer is very common, large pelvic lymph node metastases is very rare. Herein, we report a case of prostate cancer with a large abdominal mass.

CASE REPORT

A 75-year-old man entered the hospital on June 10, 1991, with urinary retention and one week's history of dysuria. The patient was 158 cm tall and weighed 59 kg. Rectal examination revealed that he had an enlarged prostate without nodularity. A fist size unmovable hard mass was palpable in the left lower abdomen. Urethrography showed that the prostatic urethra was extremely elongated and that the bladder was shifted extremely upward to the right. Drip infusion pyelography (DIP) revealed that the left lower ureter was displaced medially and that the bladder was pressed towards the right side (Fig. 1. left). The computerized tomographic (CT) scan disclosed a large mass with a high density in the left pelvis and small masses with a high density in the right pelvis (Fig. 2. left). The bone scan revealed no metastasis, although an abnormal accumulation was observed in the ninth thoracic vertebra. The serum prostatic acid phosphatase (PAP) level was 32 ng/ml and the serum prostatic specific antigen (PSA) level was 285 ng/ml. The alkaline phosphatase level was normal. A transperineal needle biopsy of the prostate confirmed the diagnosis of poorly differentiated adenocarcinoma (Fig. 3). The patient was given a high dose of diethylstilbestrol-diphosphate for 28 days (total 28 gm). Castration was not performed. Although abdominal masses had become markedly smaller, they could still be observed by

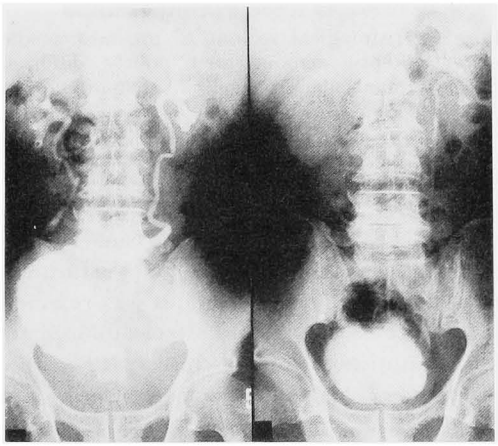

Fig. 1. DIP (left) showed that the lower left ureter was shifted medially. A slight hydronephrosis was observed in the left kidney. DIP (right), with which the patient was examined, one year after initial treatment, showed normal left ureter and bladder

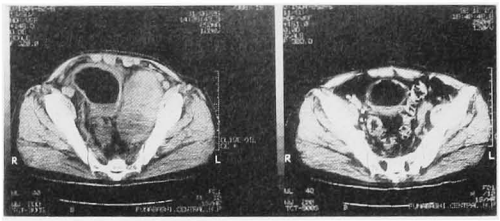

Fig. 2. CT scan (left) revealed a large high density mass on the left and small masses on the right were observed in the pelvis CT scan, one and half year after treatment (right). Note markedly diminished left pelvic lymph node. Right pelvic masses were completely diminished

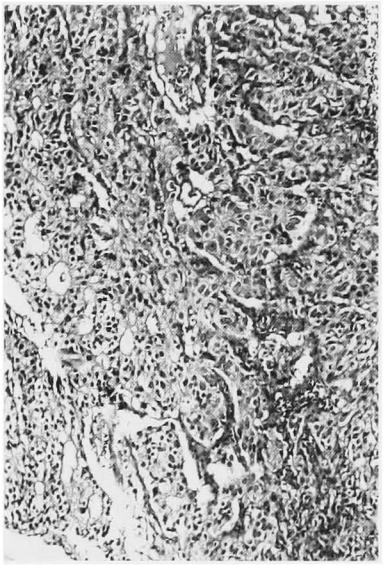

Fig. 3. Histological seciont of prostate needle biopsy demonstrated poorly differentiated adenocarcinoma. Hematoxylin & Eosin stain; ×100

CT scan. Therefore, a laparotomy was performed. The left mass was tightly clumped against surrounding tissue. Lymph node resection could not be performed. A portion of the lymph nodes was resected (Fig. 4). Diethylstilbestrol-diphosphate was administered at the dose of 12 gm for 14 days. The tumor marker (PAP and PSA) became normal on August 19. Because the residual urinary volume was still 600 ml, the patient was taught how to install the catheter by himself. Estramustine phosphate (560 mg/day) was followed after diethylstilbestrol-diphosphate treatment. The patient was discharged on September I.

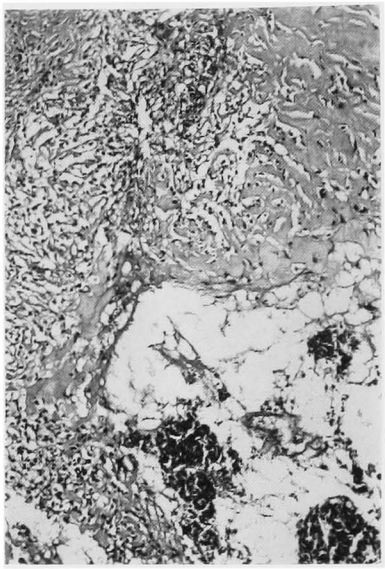

Fig. 4. Histological section of resected lymph node revealed fibrous tissue and necrosis which strongly indicated cytotoxic effect of diethylstilbestrol-diphosphate. Hematoxylin & Eosin stain; ×100

The patient was well on the follow-up examination, one year and 10 months later. The DIP showed a normal bladder and a normal left ureter (Fig. 1. right). CT scan showed that the abdominal masses had become extremely small (Fig. 2. right). The residual urinary volume became 60 ml.

DISCUSSION

Previously estrogen treatment was reported to be effective in treating prostate cancer, but the survival rate was lowered by cardiovascular diseases[1]. Since then, in Western countries, estrogen has not been used so frequently for prostate cancer. By contrast, in Japan a high dose of diethylstilbestrol-diphosphate has been used in cases of advanced prostate cancer with good results[2,3]. There has been less occurrence of cardiovascular diseases in Japan than in the West[2,3]. In addition, previously we showed that diethylstilbestrol had a dose-dependent effectiveness no Noble rat prostatic tumor[4]. This led us to believe that diethylstilbestrol has a direct cytotoxic effect only on prostatic tumor cells. Based

on these findings, we used a large dose of diethylstilbestrol-diphosphate on our patient, and obtained a very good response.

Nakagawa et al. and Masuda et al. reported 17 cases of prostatic carcinoma with large abdominal lymph node metastasis[5,6] We collected another three cases including ours[7,8], making 21 cases in total. An interesting point was that large lymph node metastases were markedly shrunken through estrogen treatment and that some lymph nodes had almost completely diminished[5,6]. Although it is important to control both lymph node and bone metastasis, the frequency of pelvic lymph node metastasis was obscure until staging pelvic lymphadenectomy was begun. The staging operation detected a high incidence of pelvic lymph node metastasis in the early stages of prostate cancer[9]. Because, as we reported here, diethylstilbestrol-diphosphate was markedly effective in treating large lymph node metastasis, smaller lymph nodes should be more responsive to estrogen. High dose diethylstilbestrol-diphosphate treatment would assure a better prognosis than androgen deprivation therapy in the early stages of prostate cancer, if used suitably (i.e. for a short period) in combination with total prostatectomy or radiation therapy.

REFERENCES

1) The Veterans Administration Cooperative Urological Research Group: Treatment and survival of patients with cancer of the prostate. Surg Gynecol Obstet **124**: 1011-1017, 1967
2) Shinkawa T, Ohfuji T, Osada Y, et al.: Adverse effects during endocrine therapy for prostatic carcinoma with a high dose of estrogen. Urol Int **40**: 103-106, 1985
3) Akimoto S, Akakura K, Fuse H, et al.: Endocrine therapy of stage D2 prostatic carcinoma. Jpn J Urol **79**: 1-10, 1988
4) Wakisaka M, Drury RE and Kadohama N: Growth inhibition by diethylstilbestrol and relapse of the Noble rat prostatic tumor. Acta Urol Jpn **34**: 107-115, 1988
5) Nakagawa H, Miyazaki S and Ito N: A case of carcinoma of prostate presenting as abdominal mass. Acta Urol Jpn **34**: 1811-1814, 1988
6) Masuda T, Yamada T, Nagahama K, et al.: Prostratic cancer presenting as palpable lymph node metastasis: Report of three cases. Acta Urol Jpn **38**: 1269-1272, 1992
7) Mittapalli MH and Brinker JE: Unusual presentation of carcinoma of prostate. Br J Urol **56**: 435-436, 1984
8) Harada M, Tokuda N, Tsubaki H, et al.: Prostatic carcinoma presenting as an abdominal mass: A case report. Acta Urol Jpn **38**: 1399-1402, 1992
9) McLaughlin AP, Saltzstein SL, McCullough DL, et al.: Prostatic carcinoma: Incidence and location of unsuspected lymphatic metastases. J Urol **115**: 89-94, 1976

(Received on February 15, 1993
Accepted on May 8, 1993)

和文抄録

Diethylstilbestrol-diphosphate が著効を示した，巨大腹部リンパ節転移を伴った前立腺癌の1例

社会保険船橋中央病院泌尿器科
脇 坂 正 美，高 岸 秀 俊

症例は75歳，男性．尿閉を主訴に来院．左下腹部に手挙大のリンパ節転移を伴う，前立腺癌であった．大量の diethylstilbestrol-diphosphate が著効を示した．巨大骨盤リンパ節転移を伴った前立腺癌を蒐集してみると21例となり，その特徴は，女性ホルモン剤がきわめて有効なことであった．

（泌尿紀要 **39**：849-851，1993）