Acta Urol. Jpn. Vol. 31
No. 8, August 1985

RETROPERITONEALIZATION FOR QUICK SPLENIC SALVAGE DURING TRANSPERITONEAL NEPHRECTOMY

Yoshihide OGAWA, Shinji IWATA, Yoshio KAWACHI and Ryuichi KITAGAWA

From the Department of Urology, School of Medicine, Juntendo University

(Director: Prof. R. Kitagawa)

During intraperitoneal nephrectomy, the spleen may be injured inadvertently. Splenic salvage is mandatory in this situation ; however, it requires some skill and extra time to control the bleeding. The authors present a very simple technique to replace the organ and retroperitonealize it in the nephrectomized fossa after some suture ligations have been placed in the major bleeding site.

Key words: Splenic trauma, Nephrectomy, Renal cell carcinoma, Retroperitonealization

Transabdominal, transperitoneal radical nephrectomy through an upper midline incision is the most common procedure to remove renal cell carcinoma. The most common complication of this approach has been reported to be injury to the spleen[1]. The most common practice is to remove the traumatized spleen; not many surgeons can spend time to repair the injured spleen. There is, however, no question about the high risk of postsplenectomy sepsis; therefore, splenic salvage is mandatory in almost all such cases[2]. However, there is no simple method to salvage the traumatized spleen and to control persistent oozing. In this communication, we report a successful attempt to salvage a traumatized spleen by placing it into the postnephrectomized fossa in order to give some form of pulp compression ; this procedure may also serve to prevent any adverse long-term problems.

CASE REPORT

A 50-year-old female reported complaints of gross hematuria and left-flank pain. IVP revealed a deformed calyceal system in the left kidney. Renal angiography demonstrated a hypervascular tumor, 8×7 cm in size. She was referred to our hospital for further evaluation and treatment. The results of routine laboratory examinations were within normal limits. CT scan revealed the presence of a well-encapsulated renal tumor without any pericapsular invasion or venous thrombosis (Fig. 1). After the diagnosis of renal cell carcinoma, she underwent nephrectomy under general anesthesia. The renal vessels were approached and ligated below the Treitz's ligamentum. After completion of the vascular ligation, the kidney was approached retroperitoneally by reflexing the descending colon; it was thus mobilized successfully. Dur-

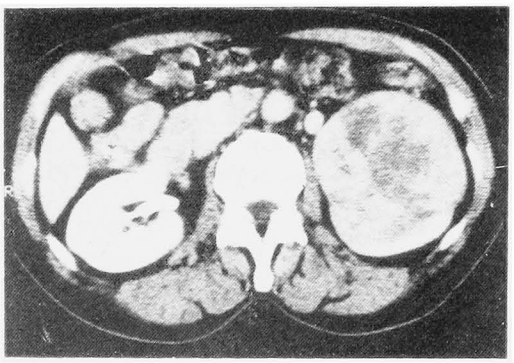

Fig. 1. CT scan taken before surgery and revealing the presence of a renal mass, which seemed to be a well-encapsulated renal tumor with an amorphous low-density area inside.

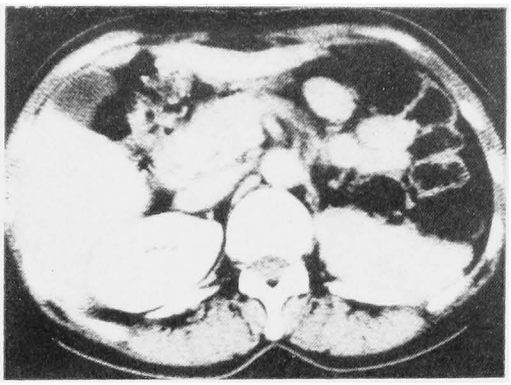

Fig. 2. CT scan taken 3 months after surgery and revealing the spleen located in the retroperitoneal space. The organ had not changed in size compared with previous photography.

ing this procedure, however, the surface of the spleen was torn by a retractor, and some bleeding developed. Major bleeding was controlled by suture ligation with chromic catgut. Although some oozing persisted, it could be controlled by compression. After nephrectomy and lymphadenectomy were completed, the spleen was mobilized by dividing the splenic ligamentum and the short gastric vessels, placing then in the renal fossa, and covering then with the peritoneum. This procedure gave compression adequate to control the bleeding. The retroperitoneal space was closed, with the drainage tube left in the fossa. Surgery was finished with a blood loss of only 670 g, and no blood transfusion was necessary. The postoperative course was uneventful, and a pathology examination revealed negative lymphnodes. Six months after surgery, she leads an uneventful life. CT scan revealed no local tumor recurrence and the spleen was normal in size (Fig. 2).

DISCUSSION

The first suggestion that there is a close relationship between splenectomy and subsequent serious infection was made by King and Schumacker in 1952[3]. It was accepted first that severe infections occurred more frequently in some infants and children who had undergone splenectomy than in the normal population. Then, Singer in 1973 concluded that postsplenectomy sepsis can be anticipated in all patients, regardless of age or the reason for the removal of the spleen[4]. This is generally accepted, and so splenic salvage is considered mandatory in any case.

It was acknowledged that injury to the spleen used to require splenectomy, no matter what the type, size, or location of the injury. The first report of successful suture repair of a splenic injury was made by Mishalany in 1974[5]. Bleeding from the fractured spleen was controlled by suture approximation, sometimes incorporating the omentum. In 1974 a topical hemostatic agent was used to control the capsular avulsion by Morgenstern[6]. Splenorrhaphy has been shown to be safe when there is adequate mobilization, suture approximation, ligation of the segmental vessels, partial splenectomy, application of topical hemostatic agents, or omentum coverage. Quite recently Markison introduced a new method using a stapled Teflon mesh wrap for rapid splenic salvage[7]. However, this procedure is not perfect because there is a possibility of adverse long-term problems, such as delayed rupture, expanding hematoma, or traumatic cyst formation. At the present time, our method seems best because it is quick enough to control bleeding and safe enough to prevent such long-term troubles.

REFERRENCES

1) Swanson DA and Borges PM: Complications of transabdominal radical nephrectomy for renal cell carcinoma. J Urol **129**: 704, 1983
2) Oakes DD: Splenic trauma. Cur Prob Surg **18**: 346, 1981
3) King H and Schumacker HB Jr : Splenic studies I. Susceptibility to infection after splenectomy performed in infancy. Ann Surg **136**: 239, 1952
4) Singer DB : Post-splenectomy sepsis. In : Perspectives in Pediatric Pathology. Edited by Rosenberg, HS Chicago : Year Book Medical Publishers, Inc., vol. 1, pp 285~311, 1973
5) Mishalany H: Repair of the ruptured spleen. J Pediatr Surg **9**: 175, 1974

6) Morgenstern L : Microcrystalline collagen used in experimental splenic injury. Arch Surg **109**: 44, 1974
7) Markison R . Stapled Teflon mesh wrap for rapid splenic salvage. Surg Rounds **6** : 55, 1983

(Accepted for publication, December 17, 1984)

和文抄録

腎摘時の脾外傷に対する後腹膜化による修復

順天堂大学医学部泌尿器科学教室
小川由英
岩田真二
川地義雄
北川龍一

50歳女性の左腎細胞癌摘出術中に脾外傷を経験した．その際に，脾の裂創部を縫合したが止血は十分でなかった．そこでその出血部を圧迫する目的で脾を腎摘後の後腹膜腔に移動した．この脾臓の後腹膜化により十分な止血効果が得られた．術後6ヵ月のCTにても脾の萎縮，血腫などを認めていない．

経腹式腎摘の際経験する脾外傷に対して，圧迫止血可能な場合は，脾を後腹膜腔に移動することにより，手早く簡単に修復が可能であった．