Acta Urol. Jpn. 34: 1733-1739, 1988

RENAL TRANSPLANT BLOOD FLOW EVALUATION BY ULTRASONIC DUPLEX SCANNING

Takahiro AKIYAMA, Tokumi ISHII, Tsukasa NISHIOKA,
Tadashi UEMURA, Seiji KUNIKATA, Hidenori KANDA,
Shigeo KANEKO, Takeshi MATSUURA and Takashi KURITA

From the Department of Urology, Kinki University School of Medicine
(Director: Prof. T. Kurita)

The transplant blood flow was measured renal transplantation by ultrasonic duplex scanner composed of pulsed Doppler flowmeter and real-time B-mode linear scanner in 32 patients. The blood flow information could be obtained from anywhere of interest within the renal transplant. Then blood flow in 3 regions including renal hilum. central echoes and renal parenchyma were measured. The parenchymal peripheral blood flow was not always similar to the hilar central blood flow. Parenchymal blood flow was the most correlated with graft function and decreased remarkably during acute rejection episode. This method enabled detection of occurrence of acute rejection in the course of post-cadaver transplant ATN. Prolongation of Δt (acceleration time) in Doppler spectrogram from parenchyma was also reliable evidence for the deterioration of graft function.

Ultrasonic duplex scanning is a useful method in managing post-transplantation patients because intrarenal hemodynamics can be evaluated by this method.

Key words: Renal transplantation, Doppler, Ultrasonic duplex scanning, Blood flow

It is a well known fact that blood flow of renal transplant deteriorates during rejection, posttransplant ATN (acute tubuler necrosis) and renal arterial or venous thrombosis. Therefore, measurement of blood flow in the transplanted kidney is useful to evaluate these events[1,2]. It has been reported that transplant arterial blood flow could be successfully detected by ultrasonic pulsed Doppler technique (Sampson et al.)[3,4], and analysis of Doppler flow pattern was a great help to diagnose rejection crisis (Arima et al.)[5,6]. Although this technique gave us beneficial information for the management of posttransplantation patients, it still has several problems, such as difficulties in detecting transplant blood flow and identifying these signals as intratransplant flow.

Recently an ultrasonic duplex scanner combined pulsed Doppler flowmeter with real-time B-mode scanner was developed. Doppler signal of blood flow could be detected exactly by placing a sampling area on the pulsatile echo of vessel wall depicted on B-mode ultrasonogram simultaneously. Then origins of individual Doppler signals were identified accurately and easily. We could differentiate information of intrarenal blood flow from the misreaded informations of extrarenals blood flows. Furthermore Doppler flow informations obtained from various intrarenal regions such as renal hilum, central echoes and renal parenchyma were also available for further analysis. We herein evaluate the clinical usefulness of this method for the management of posttransplant patients.

MATERIALS AND METHODS

Subjects consisted of 32 patients received renal transplantation since September 1983 in Kinki University Hospital. Fifteen patients received transplants from living related donors and 17 patients received from cadaver donors. In the 32 patients 14 were males and 18 were females. Their ages ranged from 11 to 50 years old.

The equipment used in this series is a duplex system composed of ultrasonic pulsed Doppler flowmeter and real-time B-mode linear scanner with line scan recorder (TOSHIBA SAL-50 A/SDL-OIA system, Tokyo). B-mode scanning was performed by a linear electric scanner with a frequency of 5 MHz and a frequency of the local oscillation was 4.39 KHz. Doppler mode scanning was performed by directional pulsed Doppler transducer with a frequency of 2.268 MHz and a frequency of the local oscillation was 4/6 KHz. Both probes were incorporated in unit and a Doppler beam was emitted with an indent angle of 55 toward B-mode tomogram (Fig. 1). Doppler signals were usually displayed as frequency spectrograms.

A probe was put on the transplanted side of lower abdomen with a patient in a supine posture. Then, real-time B-mode tomograms revealed the allografted kidney, underlying renal hilar vessels and common or external iliac vessels, respectively. The tomogram of allograft consisted of collecting system and renal parenchyma. Main renal artery and their intrarenal branch arterys could be easily identified because of pulsatile movement of wall echoes of these vessels. Subsequently a pathway of Doppler beam and the mark indicating sampling area of Doppler signal were adjusted onto the pulsatile echo. Doppler signals from optional vessels were displayed as frequency spectrograms and recorded while listening to the Doppler output through a loudspeaker for monitoring. We routinely recorded the spectrograms obtained from external iliac artery and vein, renal hilar artery and vein, large branch arteries in central echo and peripheral branch arteries in parenchymal echo.

These spectrograms were analysed in two ways. One is to rank the spectrograms into six grades in the order of flow pattern. The criteria for classification is shown on Fig. 2. This criteria was made by reference to the differences of the shapes of systolic and diastolic components based on our previous experiences of examinations. Grade I is a normal pattern and grade II is almost normal pattern but lacks the top of systolic peak. Grade III is a pattern diminishing diastolic phase and grade IV is a pattern where the end

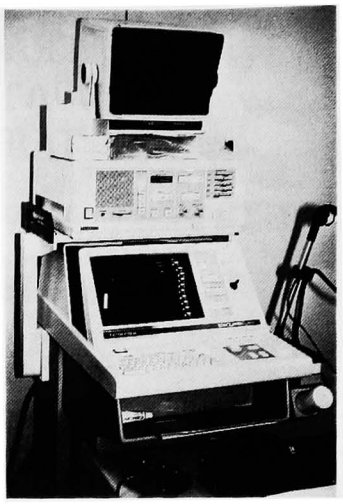

Fig. 1. Ultrasonic duplex scanner.

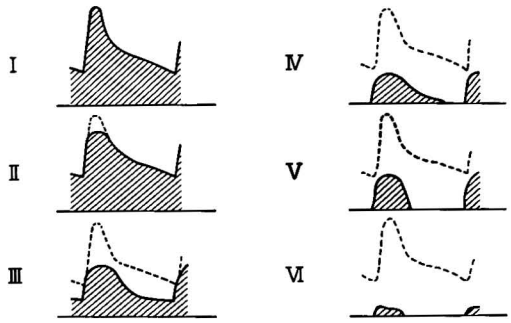

Fig. 2. Criteria for classification of flow pattern.

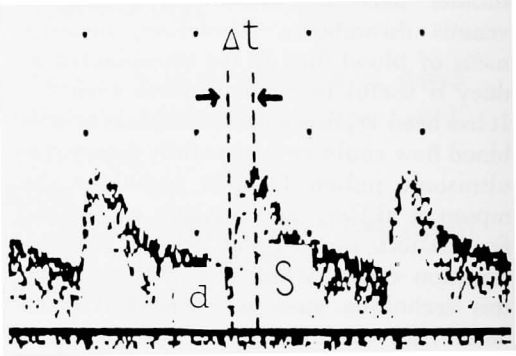

Fig. 3. Illustration for parameters of Doppler spectrogram

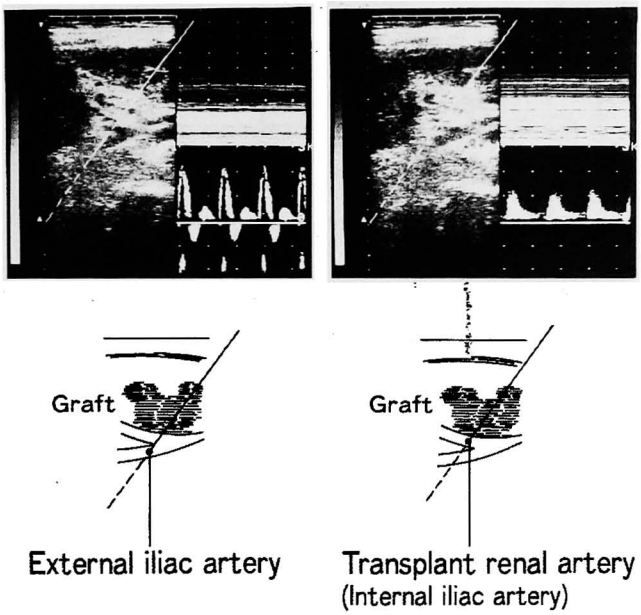

Fig. 4. An example of spectrograms from external iliac artery (left) and transplant renal artery (right).

of diastolic phase is interrupted. Grade V is a pattern which lacks diastolic phase entirely and Grade VI is a trace of signal arising only from the vibration of vessel wall. Another method for analysing spectrograms is to measure two parameters of flow pattern such as acceleration time and diastolic / systolic ratio as described by Arima et al.[5] (Fig. 3). Acceleration time (Δt) is the interval from the start of systolic forward phase to the moment of peak flow velocity. Diastolic/systolic ratio was the ratio of terminal diastolic flow velocity to systolic peak flow velocity.

RESULTS

An example of images displayed by this equipment is shown on Fig. 4. Doppler signal extracted from external iliac artery on a B-mode image demonstrates a typical pattern composed of three phases common to major arteries (left side) and signal from internal iliac artery followed by graft renal artery demonstrates an unique pattern composed only of systolic and diastolic phases defective in a reverse flow phase ; this means the pattern of end artery of its own (right side). This proves that the origin of individual signals can be accurately



Fig. 5. Spectrograms of arterial blood flows in intrarenal various regions.

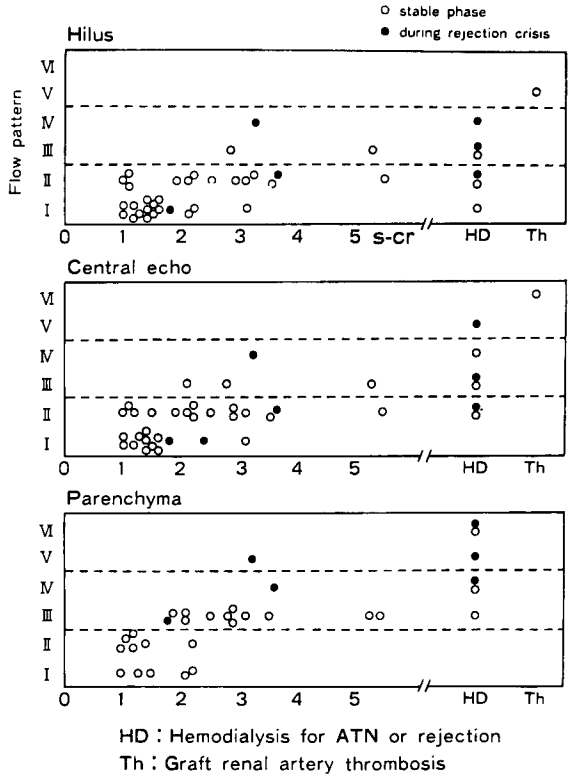

Fig. 6. Correlations between the flow patterns (grade I-VI) and graft functions (serum creatinine values, mg/dl).

identified by the duplex scanning. An example of Doppler spectrograms of arterial blood flows in renal hilum, central echo and parenchyma is shown on Fig. 5. Although all of them had similar patterns, the parenchymal Doppler is not so strong as others because peripheral blood flow velocity is slower.

The results of 41 examinations were analysed with the criteria described above and the patterns of their spectrograms correlated with their graft functions (Fig. 6). The grade of pattern became worse with a correlation to graft function in every region. This tendency appeared to be remarkable especially in parenchymal region. Only in the parenchymal region poor patterns below grade III were observed in patients with poor graft function over 1.5 mg/dl of serum creatinine values. Furthermore poor patterns in the parenchyma were prominent in a course of rejection crises (closed circles).

Table 1. Comparison of Doppler flow patterns in intrarenal various regions in patients with acute and chronic rejection.

Patient	State	Graft function (S. Cr mg/dl)	Doppler flow pattern		
			Hilum	Central echo	Parenchyma
1	acute rejection	1.8	I	I	III
2	"	2.2	I	II	I
3	"	3.2	IV	IV	V
4	"	3.6	II	II	IV
5	"	HD	III	III	IV
6	" (with ATN)	HD	II	II	V
7	chronic rejection	5.2	III	III	III
8	"	2.8	III	III	III
9	"	HD	IV	V	VI

It may suggest a poor cortical circulation within the graft during rejection. Then, Doppler patterns in rejection in this series were investigated dividing into two groups by the types of rejection (Table 1). Patterns in parenchyma were worse than those in hilus and central

echoes in 5 of 6 patients with acute rejection. On the other hand Doppler patterns were similar among intrarenal various regions and generally poor in 2 of 3 patients with chronic rejection. An example of serial examinations in patient with posttransplant ATN is illustrated in Fig. 7. Within a period of ATN, lasting about one month, this patient encountered episodes (11th day and 25th day) of acute two rejection accompanied with clinical symptoms. Doppler pattern became worse only in parenchyma in accord with episodes of rejection.

Two parameters of Doppler spectrograms were investigated and correlated with graft functions. Correlations between Δt (acceleration time) and graft function were seen in all regions within renal transplant (Fig. 8). Prolongation of Δt accompanying with a deterioration of graft function seemed to be more obvious in parenchyma. Another parameter, d/s ratios, had rarely correlated with graft function.

DISCUSSION

An application of ultrasonic Doppler flow technique to clinical renal transplantation had been reported since 1978 by Arima et al.[5,6] They analysed Doppler flow patterns into several component and could predict the prognosis of rejection[6] and posttransplant ATN[7]. The authors tried to develop this diagnostic technique by using the ultrasonic duplex system in combination with simultaneous B-mode scanning[8,9], and ssucceeded in obtaining the blood flow informations from anywhere of interest within the renal transplant with a help of this equipment. Successful measurement of the blood flow in the main

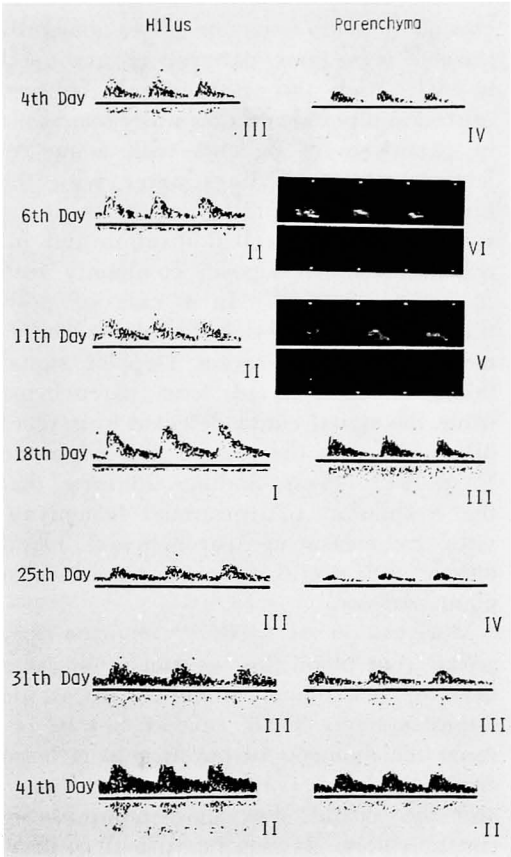

Fig. 7. An example of serial examinations in a patient with posttransplant ATN.

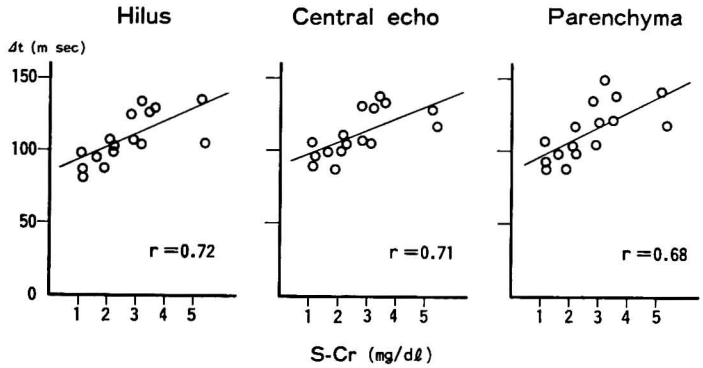

Fig. 8. Correlation between acceleration time (t) and graft function (serum creatinine value) in intrarenal various regions.

renal artery and its peripheral branch arteries revealed several interesting findings, that is, the peripheral blood flow was not always similar to the central blood flow. The peripheral flow patterns were not as good as the central flow patterns in the allografts with poor function. Parenchymal flows in rejection crises generally showed very poor patterns of grade III to VI. And this discrepancy between central and peripheral flow was remarkable in particular in patients with acute rejection. These findings agree with the histopathological findings such as interstitial edema with cell infiltration and intravascular fibrin deposits commonly seen in acute rejection. In a case of posttransplant graft arterial thrombosis confirmed by repair operation Doppler signal failed to be detected from parenchyma while the signal could detected from renal hilum although the pattern showed grade V to VI. These findings indicate that the evaluation of intrarenal hemodynamics by measuring parenchymal blood flow is very useful to manage posttransplant patients.

Moriyasu et al (1984)[10] reported that portal vein blood flow volume could have been measured quantitatively by ultrasonic duplex system. Their success may be because the diameter of portal vein is large enough to be measured on B-mode image and the portal flow show non-pulsatile constant flow. It may be difficult to measure the renal transplant blood flow volume by this method alone. It will be possible in near future by the further development of this method.

REFERENCES

1) Lewis DH, Bergentz SE, Brunius U and Gelin LE: Blood flow in kidney transplants: studies at exploration of a previously transplanted kidney, with special reference to rejection. Ann Surg **168**: 803-809, 1968
2) Henry WL, Kountz SL, Cohn R, Robinson SL and Harrison DC: Changes in pulsatile blood flow in autograft and homograft kidneys during rejection. Transplantation **7**: 545-553, 1969
3) Sampson D: Ultrasonic method for detecting rejection of human renal allotransplants. Lancet **2**: 976-978, 1969
4) Sampson D, Abramczyk J and Murphy GP: Ultrasonic measurement of blood flow changes in canine renal allografts. J Surg Res **12**: 388-393, 1972
5) Arima M, Ishibashi M, Usami M, Sagawa S, Mizutani S, Sonoda T, Ichikawa S, Ihara H and Nagano S: Analysis of the arterial blood flow patterns of normal and allografted kidney by the directional ultrasonic Doppler technique. J Urol **122**: 587-591, 1979
6) Arima M, Takahara S, Ihara H, Ichikawa Y, Ishibashi M, Sagawa S, Nagano S, Takaha M and Sonoda T: Predictability of renal allograft prognosis during rejection crisis by ultrasonic Doppler flow technique. Urology **19**: 389-394, 1982
7) Ihara H, Arima M, Ikoma F, Ichikawa Y, Ishibashi M, Sagawa S, Takaha M and Sonoda T: Clinical study on function reversibility of cadaveric renal allografts. Prediction of function reversibility with monitoring of hemodynamics of the grafts by ultrasound Doppler technique. Jpn J Urol **75**: 1619-1630, 1984
8) Akiyama T, Nishioka T, Ishii T, Uemura T, Kunikata S, Kanda H, Kaneko S, Matsuura T and Kurita T: Measurement of renal transplant blood flow by ultrasonic duplex system combined Doppler flow meter with B-mode scanner. Jpn J Urol **77**: 523-529, 1986
9) Nishioka T, Ishii T, Uemura T, Kunikata S, Kanda H, Kaneko S, Matsuura T, Akiyama T and Kurita T · Measurement of renal transplant blood flow by ultrasonic duplex system combined Doppler flowmeter with B-mode scanner (2nd report). Classification of the arterial blood flow patterns. Jpn J Urol **78**: 907-911, 1987
10) Moriyasu F, Ban N, Nishida O, Nakamura T, Koizumi S, Sakai M, Kanematsu Y, Miyake T and Uchino H: Quantitative measurement of portal blood flow in patients with chronic liver disease using an ultrasonic duplex system composed of pulsed Doppler flowmeter and B-mode electroscanner. Gastroenterologia Jpn **19**: 529-536, 1984

(Accepted for publication January, 21, 1988)

和文抄録

ドプラ断層法による移植腎血流評価

近畿大学医学部泌尿器科学教室（主任：栗田孝教授）
秋山　隆弘，石井　徳味，西岡　伯
植村　匡志，国方　聖司，神田　英憲
金子　茂男，松浦　健，栗田　孝

パルスドプラ血流測定装置と B モードリニア電子スキャン超音波断層像測定装置を組み合わせた複合装置 duplex system で腎移植自験32症例の移植腎血流を測定した．腎門部，中心エコー部，実質エコー部の3領域につき別個にドプラ血流パターンを検討した結果，実質内末梢血流の良否がドプラパターン，Δt (acceleration time) のいずれで評価しても，移植腎機能の良否と相関することが判明した．また，本法は死体腎移植後 ATN 期間中の拒絶反応の発見にも有用であった．

（泌尿紀要　**34**：1733-1739，1988）