Acta Urol. Jap. Vol. 22
No. 8, December 1976

TRANSSACRAL APPROACH FOR REPAIR OF VESICOPROSTATORECTAL FISTULA

Kimitaka SAKAMOTO, Yoshiharu HIRATSUKA
and Asami ARIYOSHI

From the Department of Urology, Fukuoka University School of Medicine, Fukuoka, Japan
(Chief: Prof. K. Sakamoto, M. D.)

The repair of a rectourinary fistula has been regarded as difficult. A variety of surgical techniques has been proposed, including the rectal pull-through operation described by Young and Stone, direct exposure and repair through a perineal incision, transrectal repair and transsacral approach[1~8]. However, no ideal method of repair has yet been devised, as evidenced by the numerous approaches. Although the transsacral approach has provided a satisfactory exposure when other methods have failed or were deemed impracticable, only a few urologic surgeons have used it[7,8].

The case herein reported is one in which none of the standard approaches appeared suitable for the repair of an intractable vesicoprostatorectal fistula. In such an instance the transsacral approach may offer an appropriate alternative.

CASE REPORT

M. A., FUH No. 26065, a 21-year-old male, was admitted to an emergency hospital with anal bleeding after receiving a stab wound by a kitchen-knife on July 25, 1974. The entry wound was at the left suprapubic region and there was no exit wound. A laparotomy was immediately done but bleeding point could not be detected at that time. The postoperative course was stormy with continuous rectal bleeding requiring a diverting ileostomy and wound infection requiring open drainage on several occasions. Despite of indwelling catheter, urine persisted to pass via the rectum. The standard suprapubic method of fistula repair was then done on December 13, 1974, but this attempt failed. The patient was discharged in January 30, 1975 on continuous catheter drainage.

He was referred to the Fukuoka University Hospital on March 27, 1975 for definitive care of his intractable vesicoprostatorectal fistula. Physical examination revealed a moderately nourished and developed man in no acute distress. Significant findings included a well-healed ileostomy in the ileocecal region, many scars with muscle defects on the lower abdomen (Fig 1) and a fistulous tract palpable in the left lobe of the prostate. Laboratory studies

Fig. 1. A well-healed ileostomy in ileocecal region and many old scars with muscle defects on lower abdomen.

Fig. 2. Cystogram shows fistulous connection between bladder neck and rectum.

A

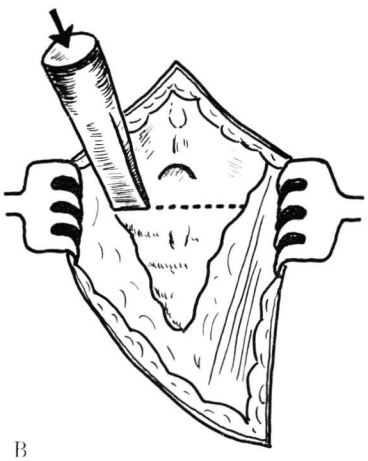

B

Fig. 3. Transsacral approach to bladder neck.
A: Incision is made from caudal dimple downward over coccyx and laterally around anus with patient in modified proctoscopic position.
B: After sacrum and coccyx are exposed, distal sacrum is divided by an osteotome.

were within normal limits except for infected urine. A KUB film did not show any abnormality and an IVP was not remarkable. A cystogram showed a fistulous connection between the bladder neck and rectum. Contrast medium was escaping through the fistula to the rectal space (Fig. 2). Cystoscopy revealed a fistulous opening with marked edematous swelling just above the bladder neck near the left ureteric orifice.

On April 11, 1975, the vesical neck, prostate and posterior urethra were exposed through a sacral incision as described by Parry and Dawson[9]. The patient was placed in the modified proctoscopic position under epidural anesthesia (Fig. 3,A). The incision was made from the dimple of the caudal canal, extended downward over the coccyx and curved to the right around the anus, medial to the ischial tuberosity. The sacrum was divided approximately 1 cm below the sacral canal (Fig. 3, B). The rectovesical fascia was dissected to separate the rectum from the posterior surface of the prostate and the vesical neck. The rectum was retracted medially. The fistula could be exposed quite satisfactorily under the direct vision. Then, fistulectomy and closure of the bladder neck and the rectal wall were carried out in 2 or 3 layers using 3–0 chromic catgut. A Foley catheter and a Penrose drain were inserted. The rectum was placed in its normal posi-

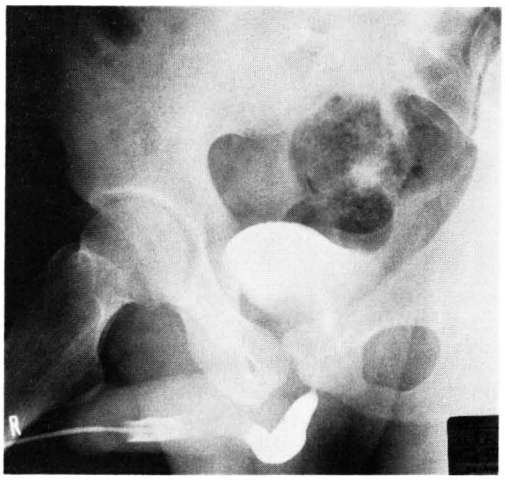

Fig. 4. Retrograde urethrogram reveals complete closure of fistula.

tion. The musculofascial layers and the skin were closed with interrupted suture.

Convalescence was uneventful and the urethral catheter was removed 11 days postoperatively. He has resumed full urinary control without voiding problems. On May 13, 1975, the ileostomy was closed and he was discharged on May 30, 1975. Follow-up examination after 9 months revealed complete closure of the fistula (Fig. 4).

DISCUSSION

The surgical procedures for repair of traumatic rectourinary fistula including operative injury have been devised and the perineal approach has been usually recommended[1~3]. In the case herein reported, however, none of the standard approaches seemed suitable because of scarred tissue following the previous operations and, also, because of site of the fistulous tract.

The transsacral approach has provided satisfactory exposure when other methods have failed or were deemed impracticable, as indicated by Limbert and Hakala[7,8]. This route is not familiar to urologists but gives excellent visualization of the fistula and is completely reliable to close. Therefore, the transsacral repair results in prompt, primary healing of the fistula.

SUMMARY

Management of a case of traumatic vesicoprostatorectal fistula was presented wherein the previous operations failed. The transsacral approach for the repair provided excellent exposure and reliable closure of rectourinary fistula.

REFERENCES

1) Smith, A. M. and Veenema, R. J.: Management of rectal injury and rectourethral fistulas following radical retropubic prostatectomy. J. Urol., **108**: 778, 1972.
2) Goodwin, W. E., Turner, R. D. and Winter, C. C: Rectourinary fistula: principles of management and a technique of surgical closure. J. Urol., **80**: 246, 1958.
3) Culp, O. S. and Calhoon, H. W.: A variety of rectourethral fistulas: experiences with 20 cases. J. Urol., **91**: 560, 1964.
4) Kilpatrick, F. R. and Mason, A. Y.: Post-operative recto-prostatic fistula. Brit. J. Urol., **41**: 649, 1969.
5) Dahl, D. S., Howard, P. M. and Middleton, R. G.: The surgical management of rectourinary fistulas resulting from a prostatic operation: a report of 5 cases. J. Urol., **111**: 514, 1974.
6) Morgan, C., Jr.: Dorsal rectotomy and full thickness skin graft for repair of prostatic urethrorectal fistula. J. Urol., **113**: 207, 1975.
7) Limbert, D. J.: Transcoccygeal repair of prostatorectal fistula. J. Urol., **100**: 666, 1968.
8) Hakala, T. R.: Parasacral approach for repair of vesicourethrovaginal fistula. J. Urol., **103**: 317, 1970.
9) Parry, W. L. and Dawson, C. B.: Transsacral prostatovesiculectomy: In Urologic Surgery ed. by Glenn, J. F. and Boyce, W. H., New Yrok: Harper & Row, pp. 378–391, 1969.

(Accepted 1976. 6. 2.)

和文抄録

経仙骨式到達法による膀胱直腸瘻閉鎖術

福岡大学医学部泌尿器科学教室（主任：坂本公孝教授）
坂本公孝・平塚義治・有吉朝美

膀胱あるいは尿道直腸瘻の閉鎖術式には各種の到達法がある．しかしいずれも一長一短があって絶対的なものはない．一般には Young および Stone の pull-through operation が推奨されているが，膀胱直腸瘻では狭い視野の奥深い部位での操作が要求され，確実に修復することは必ずしも容易ではない．

著者は，外傷によって膀胱頸部から前立腺左葉を貫通して直腸に至る瘻孔を形成し，しかも数次にわたる開腹手術，経膀胱的手術の既往を有する21歳男子症例に対し，経仙骨式到達法による瘻孔閉鎖術を施行したその結果，前立腺，膀胱頸部付近を容易に露出でき，瘻孔は直視下に確実に切除，縫合することが可能であった．

経仙骨式到達法は，このアプローチによる前立腺摘出術を施行している一部の専門家を除けば，まだ一般化していないが，腹式あるいは会陰式到達法で操作困難と予想される後部尿道ないし膀胱頸部付近の手術には用いられてしかるべき方法であると考えられる．