Fibropapillomatosis: A case in marine turtle reared in captivity in the Southern Philippines

RUTH S. LUCERO[1], PEDRO M. AVENIDO[1], SATURNINO C. PARCASIO[2], PETER LABIS[2], MATIAS J. LUCERO[2], FRANCIS KUNZTANTIN S. LUCERO[3], LEO Y. ANGLIONGTO[3] AND JULIAN R. SEGOVIA[3]
[1]*Southern Philippines Agri-business and Marine and Aquatic School of Technology, Malita, Davao del Sur 8012, Philippines*
[2]*Local Government Unit-Office of the Municipal Agriculture and Fisheries, Malita, Davao del Sur 8012, Philippines*
[3]*Dugong and Marine Turtle Conservation Project, Barangay New Argao, Malita, Davao del Sur 8012, Philippines*
Email: rs_lucero@yahoo.com
Telephone number: +639212011708

ABSTRACT
The study investigated the possible incidence of fibropapillomatosis in marine turtle reared in captivity at the SPAMAST Marine Research Station in New Argao, Malita, Davao del Sur. Pinkish lesions similar to fibropapilloma described earlier by Jacobson et al. (1989) were observed at the orbital area of the eye of a five year old olive ridley, indicative of fibropapillomatosis. The pinkish lesion progressed to 2 mm in three months time. Although confirmatory tests have not been conducted, the lesion is indicative of the incidence of fibropapillomatosis in marine turtles reared in captivity in Southern Philippines.

Keywords: fibropapillomatosis, marine turtle, epidermal pinkish lesion, orbital lesion

INTRODUCTION

Incidence of fibropapillomatosis affecting adult green sea turtles has been reported in the early 1930s (Lucke, 1938) and in the late 1970s in Grand Cayman, B.W.I. (Jacobson et al., 1989). It is a condition characterized by the presence of fibropapillomas consisting of both the cutaneous epidermal and dermal layers. Increased prevalence of the disease was reported in captured green turtles from the Atlantic Ocean, Brazil, the Indian Lagoon System of east central coastal Florida, U.S.A. and from the Hawaiian Islands (Matushima et al., 2001) and Cuban waters (Moncada et al., 2000). Uncertain reports associate chelonian herpesvirus with the incidence of fibropapillomatosis and in the 1990s, it was thought that severely affected marine turtles may face a deadly condition that may lead to its extinction.

Davao Gulf in the Southern Philippines harbors four of the seven species of marine turtles (Lucero et al., 2010). However, there is no available information as to the occurrence of fibropapillomatosis in the area. With the possible extinction that the disease may bring to these endangered marine turtles, there is the urgency to provide relative information on the incidence of fibropapillomatosis in this part of the region. This study was conducted to document and provide data on the incidence of fibropapillomatosis in marine turtle reared in captivity in the Southern Philippines.

MATERIALS AND METHODS

Study Site

The study was conducted at the SPAMAST Marine Research Station located at New Argao, Malita, Davao del Sur, Philippines (Figure 1).

Figure 1. Map of Davao del Sur showing the study site

The 3 km coastal stretch of New Argao is considered a nesting area for marine turtle.

Subjects of the Study

The two marine turtles (a hawksbill and an olive ridley) reared in the station were the subjects of the study. These turtles were nested and hatched within the coastal area of New Argao where the marine research station is located. Immediately after hatching, a sample hatchling from each batch was reared in the station. The rest of the hatchlings were released to the sea.

Rearing Process

A circular rubber tub with a diameter of 95 cm and a height of 15 cm served as the rearing tank. Each hatchling was individually reared in a tank. The feeding regime includes squid and occasionally freshwater tilapia. The water in the tub was changed daily.

Historical Records

Historical records of the turtles considered as subject of the study were obtained from a previous publication of Lucero, et al. (2010).

Physical Examination and Diagnosis

The turtles reared in captivity at the SPAMAST Marine Research Station located at New Argao, Malita, Davao del Sur, Philippines were examined. Individual information as to the weight, species, carapace size and age were noted. Presence of lesions and manifestations of any external signs of the disease similar to what have been described by Jacobson, et al. (1989) were recorded.

Photo Documentation

Photographs of turtles used in the study and affected by fibropapillomatosis were taken using Canon PC1144 Digital IXUSi camera.

RESULTS AND DISCUSSION

Historical Data

The historical record of the two turtles utilized in the study (Turtle 1 and Turtle 2) showed that Turtle 1 is a 3 year old hawksbill obtained from a batch of 124 eggs that hatched on September 16, 2007. Turtle 2 is a 5 year old olive ridley obtained from a batch of 111 eggs that hatched on March 1, 2005. Both initially weighed approximately 15 grams.

Physical Examination and Diagnosis

The turtles in captivity were subjected to physical examination. Both were physically active. The hawksbill weighed 7.2 kg and has a carapace size of 42.5 cm long and 35 cm wide. No lesions were noticed externally on its body. The olive ridley weighed 12.5 kg and has a carapace size of 47.5 cm long and 40 cm wide. Examinations on its left eye showed pinkish circular lesion approximately 2 mm in diameter was found on the left orbital area of the eye (Figs. 2 and 3). Although both turtles had been reared in the same place and experienced the same rearing procedure, fibropapilloma occurred only for the olive ridley. Perhaps, the olive ridley may be more vulnerable to the disease than the hawksbill. In a study of Greenblatt et al. (2005) on marine turtles from seven geographic areas, fibropapilloma-associated turtle herpesvirus (FPTHV) infected three turtle species (*C. mydas, Caretta caretta, and Lepidochelys olivacea*). While these may be the most commonly infected species, fibropapillomatosis has been found in all sea turtle species (Williams Jr. E.H. et al., 2006).



Figure 2. Olive ridley (*Lepidochelys olivacea)* turtle, with fibropapilloma at the eye region

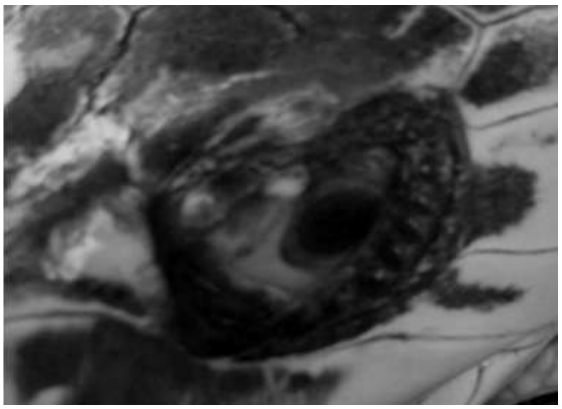

Figure 3. A close-up photo of the epidermal pinkish circular lesion (fibropapilloma) at the orbital area of the eye of an olive ridley.

As cited by Jacobson et al. (1989), clinical signs of affected turtles include multiple benign cutaneous fibroepithelial tumors which may be found at almost any site including soft and hard tissue parts. In this study, the single 2 mm circular pinkish lesion was observed at the epidermal layer of the upper left orbit of the eye. The affliction was slight and considered as still at the early stage, which is similar to the description of Bennett, P. et al (2000) (http://www.turtles.org/eyes/eyes.htm.). As the affliction advances, the discoloration and

swelling may turn into protuberances that manifest as tumors. The infection characterized by the pinkish circular lesion observed in the eye portion is similar to the fibroepithelial tumors described by Jacobson et al. (1989) and Bennett, P. et al (2000). The lesions were observed for about two months and perhaps have not yet affected the internal organs. No problems on floatation were observed.

The pinkish circular lesion observed at the orbital area is indicative of fibropapillomatosis affecting the olive ridley.

The study recommends that a confirmatory test be done on the diseased turtle.

ACKNOWLEDGEMENTS

The authors are grateful to the Lucero family of New Argao, Malita, Davao del Sur for the accommodation extended during the conduct of the study; the Local Government Unit of Malita-Office of the Municipal Agriculture and Fisheries and SPAMAST for the technical support. Special acknowledgment is extended to Dr. Paul Klein of the Department of Pathology and Laboratory Medicine of the University of Florida for facilitating the provision of literatures used in the study. The authors are sincerely grateful to Jacobson, E. R. et al. and Bennett, P. et al for the photos of fibropapilloma infected turtles which serve as guide in determining manifestation of the disease.

REFERENCES

Bennett, Peter, U. K. Bennett and George H. Balazs. The eyes have it: Manifestation of ocular tumors in the green turtle ohana of Honokowai, West Maui, Hawaii. http://www.turtles.org/eyes/eyes.htm. 2000.

Greenblatt, R. J., S. L. Quackenbush, R. N. Casey, J. Rovnak, G. H. Balazs, T. M. Work, J. W. Casey and C. A. Sutton. Genomic variation of the fibropapilloma-associated marine turtle herpesvirus across seven geographic areas and three host species. J. Virol. 79:1125-1132. 2005.

Jacobson, E. R., J. L. Mansell, J. P. Sundberg, L. Haijar, M. E. Reichmann, L. M. Ehrhart, M. Walsh and F. Murru. Cutaneous fibropapillomas of green turtles (*Chelonia mydas*). Journal Comparative Pathology, v. 101, p.39-52, 1989.

Lucero, M., S. C. Parcasio, M. Gencianeo, G. Parcasio, R. S. Lucero, P. M. Avenido, A. Moran, L. Y. Angliongto, R. Segovia and E. S. Lucero. Marine Turtle Stranding and Nesting in Malita, Mindanao, Philippines. Abstracts of the 6th International Symposium on SEASTAR2000 and Asian Biologging Science. Phuket Thailand, p. 35, 2010.

Lucke, B. Studies on tumors in cold-blooded vertebrates. Annual Report of the Tortugas Laboratory of the Carnegie Institute of Washington, v. 38, p. 92-94, 1938.

Matushima, E. R., A. Longatto Filho, C. Di Loretto, C. T. Kanamura, I. Sinhorini, B. Gallo and C. Baptistolle. Cutaneous papillomas of green turtles: a morphological, ultra-structural and immunohistochemical study in Brazilian specimens. Braz. J. Vet. Res. Anim. Sci. vol. 38, no.2 Sao Paulo. 2001.

Moncada, Felix and Adela Prieto. Incidence of Fibropapillomas in the Green Turtle (*Chelonia mydas*) in Cuban waters. Proceedings of the 19th Annual Symposium on Sea Turtle Conservation and Biology 19: 40-41. NOAA Technical Memorandum NMFS-SEFSC-443, 2000.

Williams Jr., E. H. and L. B. Williams. Early Fibropapillomas in Hawaii and Occurrences in All Sea Turtle Species: the Panzootic, Associated Leeches Wide-Ranging on Sea Turtles and Species of Study Leeches Should Be Identified. J. Virol., 80(9): 4643-4644, 2006.