Laparoscopic proximal gastrectomy with a hand-sewn esophago-gastric anastomosis using a knifeless endoscopic linear stapler

Authors' names: Hiroshi OKABE[1)], Kazutaka OBAMA[1)], Eiji TANAKA, Shigeru TSUNODA[1)], Masatoshi AKAGAMI[1)], Yoshiharu SAKAI[1)]

Affiliation:

1) Department of Surgery, Graduate School of Medicine Kyoto University

54 Kawahara-cho, Shogoin, Sakyo-ku, Kyoto, 606-8507, Japan

Corresponding Author: Hiroshi OKABE

Mailing address:

Department of Surgery, Graduate School of Medicine Kyoto University

54 Kawahara-cho, Shogoin, Sakyo-ku, Kyoto, 606-8507, Japan

E-mail address: hokabe@kuhp.kyoto-u.ac.jp

Telephone: +81-75-366-7595

Fax: +81-75-366-7642

Running head: Laparoscopic handsewn esophagogastrostomy

Word Count : 2321 words

Abstract

Proximal gastrectomy has been applied for selected patients with early upper gastric cancer, because of its potential advantages over total gastrectomy, such as preserving gastric capacity and fewer hormonal and nutritional deficiencies. Esophago-gastic anastomosis is a simple reconstruction method with excellent postoperative outcome, when gastroesophageal reflux is properly prevented. The esophagus is anastomosed to the anterior stomach wall with partial fundoplication to prevent esophageal reflux following open surgery. We developed a novel laparoscopic hand-sewn method to reproduce the anti-reflux procedure in open surgery. The esophagus is first fixed to the anterior stomach wall by a knifeless endoscopic linear stapler. This fixation contributes to maintaining a stable field for easier hand-sewn anastomosis and to complete the left side of the fundoplication at the same time. The novel technique was used to successfully perform complete laparoscopic proximal gastrectomy with a hand-sewn esophago-gastric anastomosis in ten patients without any postoperative complications. No patient had symptoms of gastroesophageal reflux over a median follow-up of 19.9 months. One patient developed anastomotic stenosis, which was resolved with endoscopic dilatation. The mean percent body weight loss at 12 months after surgery was 10.4%. Laparoscopic proximal gastrectomy with an esophago-gastric anastomosis using our novel technique would be a feasible choice and benefit selected patients with early upper gastric cancer.

Miniabstract

A novel laparoscopic method using a knifeless linear stapler was developed for hand-sewn esophago-gastrostomy. Laparoscopic proximal gastrectomy with the new technique would be a feasible choice for early upper gastric cancer.

Keywords: laparoscopic surgery, gastric cancer, esophago-gastric anastomosis, proximal gastrectomy

Introduction

Gastric cancer is one of the most common cancers worldwide. Many patients in Eastern Asia, where gastric cancer is one of the main causes of cancer death, are diagnosed with early disease. Although total gastrectomy is considered to be the standard operation for an upper gastric cancer, proximal gastrectomy has been applied for selected patients with early gastric cancer as a less invasive and function-preserving surgery. Proximal gastrectomy has potential advantages over total gastrectomy, such as preserving gastric capacity and fewer hormonal and nutritional deficiencies[1]., Reconstruction with either esophago-gastrostomy or jejunal interposition is done following proximal gastrectomy. Esophago-gastric anastomosis is a simpler procedure, resulting in shorter operation time. A retrospective survey using a questionnaire has shown esophago-gastric anastomosis has a better outcome with regard to abdominal symptoms than jejunal interposition [2]. However, a higher incidence of postoperative gastroesophageal regurgitation has also been reported and prevents its widespread use [3]. Although jejunal interposition is favored by some surgeons in this respect, the procedure is technically demanding and requires longer operation time [4]. Furthermore, late complications, such as jejunitis, stasis, and ileus, have been reported. Difficulty in endoscopic surveillance following jejunal interposition has also been indicated[5]. Therefore, no optimal reconstruction method after proximal gastrectomy has been established.

Several techniques of esophago-gastric anastomosis to esophageal reflux have been reported. The esophagus is recommended to be anastomosed to the anterior wall in the center of the stomach[6]. This results in the remnant stomach surrounding the dorsal half of the lower esophagus, increasing the pressure at the lower end of the esophagus and thereby preventing esophageal reflux by mechanisms similar to those of partial fundoplication. Although a gastroesophageal anastomosis can be done with a circular stapler, anastomotic stenosis could occur in 6 to 20% after few months or even later[7,8]. We have adopted hand-sewn anterior esophago-gastric anastomosis in open proximal gastrectomy because hand-sewn sutures produce less incidence of stenosis[9].

Laparoscopic surgery has been accepted as a standard option for early gastric cancer, especially in Japan and Korea. Laparoscopic proximal gastrectomy with esophago-gastrostomy would be an ideal minimal invasive approach for early upper gastric cancer, if gastroesophageal reflux is properly prevented. Laparoscopic esophago-gastrostomy using a linear stapler was first reported by Uyama et al. in 2001[10]. However, reflux esophagitis is still observed in nearly half of the patients[11].

This paper reports our novel laparoscopic procedure using a knifeless endoscopic linear stapler for easier creation of a hand-sewn anterior esophago-gastric anastomosis, which resulted in excellent postoperative function.

Patients and Methods

Patients

Ten patients (6 male and 4 female) underwent laparoscopic proximal gastrectomy at Kyoto University Hospital between August 2009 and December 2011. These patients had a median age of 67 years (range, 31-83 years) and a body mass index of 22.9 (range, 18.3-27.1). Nine patients were diagnosed with gastric cancer in the upper third of the stomach without lymph node involvement, and one patient was diagnosed with a gastrointestinal stromal tumor. Although early cancer is the recommended indication for proximal gastrectomy according to the Japanese gastric cancer treatment guidelines, two patients with small T2 tumor were included beyond the indication in this study[12]. The diagnosis was based on preoperative examinations including gastrointestinal endoscopy, an upper gastrointestinal series, and abdominal computed tomography. The 14th version of Japanese classification of gastric carcinoma was used[13].

Surgical technique

Proximal gastrectomy

The patient is placed in a modified lithotomy position. The first port is placed through the umbilicus using an open method. The laparoscope is inserted via the umbilical port, and four operating ports and a Nathanson liver retractor are placed as indicated in **Figure 1**. The surgeon stands on the patient's right side. The extent of lymph node dissection is basically D1+, according to Japanese gastric cancer treatment guidelines 2010 (version 3)[12]. The left side of the greater omentum is first separated and the left gastroepiploic vessels are divided to dissect lymph node (LN) station #4sb. The gastrosplenic ligament is separated, and the short gastric vessels are divided to harvest LN station #4sa. The lesser omentum is opened to enter the lesser sac. The perigastric vessels along the lesser curvature are cut at the point between the right and left gastric arterial arcade. The upper half of the lesser curvature is skeletonized toward the proximal side to remove LN station #3a. The exact location of the tumor is determined by an intraoperative endoscopy and the stomach is transected using an endoscopic linear stapler to secure the distal margin.

LN station #8a is dissected along the common hepatic artery, and LN stations #7, 9 and 11p are removed en bloc by a medial approach, which has been described elsewhere[14]. The gastrophrenic fold is divided along the right crus of the diaphragm towards the esophagus and the fundic portion of the stomach is fully mobilized from the retroperitoneum. The posterior vagal trunk is identified at the posterior side of the esophago-gastric junction. The celiac branch of the vagal trunk

is preserved, while the left gastric artery is divided to remove LN station #7. LN station #9 is dissected and separated from the crus of the diaphragm. The esophagus is completely isolated and transected by an endoscopic linear stapler. Finally, the gastric fundus is retracted caudally by the assistant, and LN station #11 is dissected along the splenic artery in a distal direction to complete the proximal gastrectomy. The specimen is removed through the extension of the umbilical port wound.

Esophago-gastrostomy

The center of the anterior wall of the remnant stomach is transversely opened for 3 cm, approximately 3 to 4 cm from the edge (**Fig 2A**). The gastric juice is suctioned thorough the opening to prevent any contamination. The left border of the esophageal edge is incised, and a naso-gastric tube is advanced through the opening to confirm the “true” esophageal lumen. The anvil side of a knifeless endoscopic stapler (ENDOPATH® ETS 45mm No Knife) is inserted into the hole at the remnant stomach. The cartridge side of the stapler is inserted into the esophagus using the naso-gastric tube as a guide. The knifeless stapler is used to fix the left side of the esophagus to the anterior stomach wall (**Fig 2B** and **3A**). The esophageal edge is opened and adjusted to the size of the previous 3 cm incision on the stomach. The right edge of the esophagus is partly left in most cases (Fig 2B). A posterior wall anastomosis is performed by continuous hand suturing using 3-0 Vicryl® (**Fig 2C** and **3B, 3C**). The anterior wall is also closed by continuous sutures (**Fig 3D**). After the completeness of the anastomosis is examined, a few reinforcement sutures are placed if required. The right side stump of the remnant stomach is anchored to the right crus of the diaphragm to prevent dislocation of the stomach (**Fig 2D** and **4A**). Finally, the right side of the lower esophagus is fixed to the stomach wall to complete a posterior 180 degree fundoplication (**Fig 2D** and **4B**).

Results

The patients’ backgrounds and surgical outcomes are listed in **Table 1**. All patients had tumors in the upper third of the stomach; nine patients had gastric cancer and one had a gastrointestinal stromal tumor (GIST). Seven patients with a clinical T1b tumor underwent D1+ lymph node dissection according to Japanese gastric cancer treatment guidelines (version 3). Lymph node station #11d was also removed in two patients with clinical T2 tumors. The patient with GIST had no lymph node dissection.

The mean operative time for ten patients was 299 min (range, 174 to 394 min), and the estimated blood loss was 65 g (range, 0 to 325 g). The mean duration for the reconstruction was 82 min. There was no conversion to open surgery. All patients recovered uneventfully without any complications

and were discharged between 8 and 18 days after surgery; the mean hospital stay was 15 days. However, the pathological examination revealed a positive surgical margin in one patient. Although the patient was diagnosed with clinical T1b disease (tumor invades as far as submucosa) before surgery, a diffuse infiltration of scattered poorly differentiated tumor cells to the serosa and to the surgical margin were revealed on pathological examination. The patient underwent laparoscopic completion gastrectomy on the 21st day after the initial surgery to achieve R0 resection.

The median follow-up period for other nine patients was 21.5 months (range, 5.6 to 32.4). One patient had anastomotic stenosis at four months after surgery, which was resolved by serial endoscopic dilatation of the anastomotic site. No patient exhibited symptoms suggesting acid reflux, such as heartburn, chest pain, or chronic cough. Proton pump inhibitor was administered for the first few months following surgery and then discontinued after confirmation of no endoscopic finding of reflux esophagitis. Eight patients had endoscopic follow-up at least once after surgery. Grade B esophagitis according to the Los Angeles classification was found in one patient 18 months after surgery, although she had no symptom of reflux. Postoperative endoscopic findings in a representative case are shown in **Figure 5**. The mean percent body weight loss in comparison to the preoperative weight in seven patients at 12 months was 10.4% (range, 4.5 to 14.3%).

Discussion

Although there is no high-level evidence of oncological safety based on large-scale randomized controlled trials, laparoscopic surgery for early gastric cancer has been widely accepted in Eastern Asian countries. An early gastric cancer lesion limited to the upper stomach is considered as a possible indication for proximal gastrectomy in open surgery. Proximal gastrectomy with esophago-gastrostomy has several advantages in patients with small lesions, such as shorter operative time, less postoperative body weight loss and nutritional deficiencies, in comparison to total gastrectomy[1]. Therefore, establishing a laparoscopic procedure for proximal gastrectomy with esophago-gastrostomy would be an ideal approach for patients with small early upper gastric cancer.

The major reason preventing wide introduction of laparoscopic proximal gastrectomy with esophago-gastric anastomosis is the lack of a secure method for laparoscopic anastomosis with an anti-reflux mechanism. The anastomosis is made at the anterior wall of the stomach in open surgery and the dorsal side of the esophagus is covered with the remnant stomach, in the same manner as in partial fundoplication[6,15]. Gastro-esophageal reflux is thereby prevented by the increased pressure at the lower end of the esophagus. Previous reports of laparoscopic esophago-gastrostomy

made the anastomosis by a linear stapler with hand-sewn closure of the entry hole[10,11]. Side-to-side anastomosis between the anterior gastric wall and the dorsal side of the esophagus diminishes the anti-reflux high pressure zone at the lower end of the esophagus.

We introduced laparoscopic hand-sewn anastomosis in order to keep the lower esophagus intact, and reproduce the open surgery anti-reflux procedure under laparoscopy. We first tried “pure” hand-sewn anastomosis. However, it was technically highly demanding because the esophageal stump was retracted into the mediastinum after transection and there was a strong tension between the esophageal end and the anterior gastric wall. In our new method, we first fixed the esophagus to the gastric wall using a knifeless linear stapler. This technique allowed easier manipulation of the esophageal stump and suturing for the anastomosis. This fixation also contributes to the mechanism of reflux prevention by completion of the left side of the fundoplication at the same time. Anastomosis with a similar shape may also be created with a circular stapler. However, it would be more difficult to manipulate a circular stapler in a limited space than a linear stapler. In addition, a circular stapler could result in higher rate of anastomotic stenosis, which is the most frequent complication following proximal gastrectomy, in comparison to a hand-sewn anastomosis[7,8]. Reconstruction with hand-sewn anastomosis took about 80 minutes in this study. However, the time required has been shortened to about 50 minutes by ten cases. It will get shorter as we gain more experience with the laparoscopic hand-sewn technique.

Preserving an abdominal esophagus and a larger stomach is important to maintain the capacity of the remnant stomach and to form an effective anti-reflux anastomosis. Therefore, the point of gastric transection should be determined precisely. We examined the lateral extension of cancer by preoperative endoscopy and placed clips at appropriate points with a negative biopsy. The resection margin was determined to include these clips using intra-operative endoscopy. However, the distal resection margin was positive in one patient. The tumor in this case was preoperatively diagnosed as T1b. However, the pathological examination revealed that scattered cancer cells were infiltrated into the muscular and the subserosal layer without mucosal involvement. Confirmation of negative surgical margin by examination of a frozen section during is recommended when proximal gastrectomy is applied for this histological type of lesion.

Although there was no postoperative complication, the mean length of postoperative hospital stay in this study seems little longer. One possible reason for this is that we did not apply a clinical pathway for patients with proximal gastrectomy. Some patients requested for longer stay in the hospital. No patient had reflux symptoms during follow-up period, although endoscopic examination revealed Grade B esophagitis in one patient. Another patient had mild symptoms of stenosis, which

was easily resolved with endoscopic balloon dilatations. The length of the incisions on the stomach is important for avoiding stenosis, because it determines the size of the stoma. The mean percent body weight loss at 12 months after surgery was 10%, which seems to be less than that of total gastrectomy[16,17]. Although the nutritional status was not examined in detail in this study, proximal gastrectomy may also benefit patients from the nutritional point of view. Careful and longer follow up of more patients is necessary to confirm these observations.

In summary, the short-term outcome of this novel technique of laparoscopic esophago-jejunostomy was excellent. Fixation of the esophagus to the anterior stomach wall by a knifeless linear stapler contributes to easier hand-sewn anastomosis and to completion of the fundoplication. We believe our method is a feasible choice for selected patients. However, careful and longer follow up of more patients is necessary to determine the advantage of our method.

Figure Legends

Figure 1

Port sites for laparoscopic proximal gastrectomy. A. 5 mm port; B. 12 mm port; C. Laparoscope through the umbilicus; D. 12 mm port; E. 12 mm port; F. A Nathanson liver retractor

Figure 2

Schematic outline of the reconstruction by an esophago-gastrostomy using a knifeless linear stapler and hand suturing. A. After a 3 cm incision is made on the anterior wall of the remnant stomach, a knifeless endoscopic linear stapler is applied between the stomach and the left side of the esophagus. A naso-gastric tube is used as a guide. B. The left side of the esophagus is fixed to the stomach wall. The stump of the esophagus is opened and adjusted to the size of the previous 3 cm incision on the stomach. The right edge of the esophagus is partly left in most cases. C. Posterior running sutures are performed. D. The anastomosis is completed by an anterior running suture. The gastric stump is anchored to the right crus of the diaphragm (white arrow). The posterior partial fundoplication is done by interrupted sutures (black arrows).

Figure 3

Intraoperative view during the esophago-gastric anastomosis. A. Application of a knifeless endoscopic linear stapler. B. A stay suture between the right edge of the esophageal opening and the hole on the remnant stomach. Note that the left side of the esophagus is fixed to the stomach wall by a previous step (white arrow heads). C. A posterior running suture is done from the left to the right edge. D. Completion of the anastomosis by an anterior running suture. E: esophagus, St: the remnant stomach

Figure 4

Anchoring the stomach and a posterior 180° fundoplication. A. Anchoring the stump of the remnant stomach to the right crus of the diaphragm. B. The posterior aspect of the lower esophagus is covered by the stomach wall by a few interrupted sutures. E: esophagus, St: the remnant stomach

Figure 5

A, B. A gastrographin study in a representative case on the 7th postoperative day. A. Smooth passage of gastrographin through the anastomosis. B. No reflux is seen in the head-down position.

C, D. Endoscopic views of the anastomosis at 6 months after surgery. C. No finding of gastroesophageal reflux at the lower esophagus. The staple line is not identified. D. A fundus-like space is seen behind the new esophagogastric junction.

Acknowledgements

We are deeply grateful to Shigeyuki Sakaguchi for creation of the schematic illustration of a hand-sewn anastomosis.

References

1 Hinoshita E, Takahashi I, Onohara T, Nishizaki T, Matsusaka T, Wakasugi K, et al. The nutritional advantages of proximal gastrectomy for early gastric cancer. Hepatogastroenterology 2001;48:1513-1516.

2 Tokunaga M, Hiki N, Ohyama S, Nunobe S, Miki A, Fukunaga T, et al. Effects of reconstruction methods on a patient's quality of life after a proximal gastrectomy: Subjective symptoms evaluation using questionnaire survey. Langenbecks Arch Surg 2009;394:637-641.

3 An JY, Youn HG, Choi MG, Noh JH, Sohn TS, Kim S. The difficult choice between total and proximal gastrectomy in proximal early gastric cancer. Am J Surg 2008;196:587-591.

4 Katai H, Morita S, Saka M, Taniguchi H, Fukagawa T. Long-term outcome after proximal gastrectomy with jejunal interposition for suspected early cancer in the upper third of the stomach. Br J Surg 2010;97:558-562.

5 Kikuchi S, Nemoto Y, Katada N, Sakuramoto S, Kobayashi N, Shimao H, et al. Results of follow-up endoscopy in patients who underwent proximal gastrectomy with jejunal interposition for gastric cancer. Hepatogastroenterology 2007;54:304-307.

6 Hirai T, Matsumoto H, Iki K, Hirabayashi Y, Kawabe Y, Ikeda M, et al. Lower esophageal sphincter- and vagus-preserving proximal partial gastrectomy for early cancer of the gastric cardia. Surg Today 2006;36:874-878.

7 Gould J, Garren M, Boll V, Starling J. The impact of circular stapler diameter on the incidence of gastrojejunostomy stenosis and weight loss following laparoscopic roux-en-y gastric bypass. Surg Endosc 2006;20:1017-1020.

8 Fisher B, Atkinson J, Cottam D. Incidence of gastroenterostomy stenosis in laparoscopic roux-en-y gastric bypass using 21- or 25-mm circular stapler: A randomized prospective blinded study. Surg Obes Relat Dis 2007;3:176-179.

9 Takeyoshi I, Ohwada S, Ogawa T, Kawashima Y, Ohya T, Kawate S, et al. Esophageal anastomosis following gastrectomy for gastric cancer: Comparison of hand-sewn and stapling technique. Hepatogastroenterology 2000;47:1026-1029.

10 Uyama I, Sugioka A, Matsui H, Fujita J, Komori Y, Hatakawa Y, et al. Laparoscopic side-to-side esophagogastrostomy using a linear stapler after proximal gastrectomy. Gastric Cancer 2001;4:98-102.

11 Sakuramoto S, Yamashita K, Kikuchi S, Futawatari N, Katada N, Moriya H, et al. Clinical experience of laparoscopy-assisted proximal gastrectomy with toupet-like partial fundoplication in

early gastric cancer for preventing reflux esophagitis. J Am Coll Surg 2009;209:344-351.

12 Japanese Gastric Cancer Association. Japanese gastric cancer treatment guidelines 2010 (ver. 3). Gastric Cancer 2011;14:113-123.

13 Japanese Gastric Cancer Association. Japanese classification of gastric carcinoma: 3rd english edition. Gastric Cancer 2011;14:101-112.

14 Okabe H, Obama K, Kan T, Tanaka E, Itami A, Sakai Y. Medial approach for laparoscopic total gastrectomy with splenic lymph node dissection. J Am Coll Surg 2010;211:e1-6.

15 Ichikawa D, Komatsu S, Okamoto K, Shiozaki A, Fujiwara H, Otsuji E. Evaluation of symptoms related to reflux esophagitis in patients with esophagogastrostomy after proximal gastrectomy. Langenbecks Arch Surg 2012

16 Bae JM, Park JW, Yang HK, Kim JP. Nutritional status of gastric cancer patients after total gastrectomy. World J Surg 1998;22:254-260; discussion 260-251.

17 Fein M, Fuchs KH, Thalheimer A, Freys SM, Heimbucher J, Thiede A. Long-term benefits of roux-en-y pouch reconstruction after total gastrectomy: A randomized trial. Ann Surg 2008;247:759-765.

Table 1. Patients' backgrounds and surgical outcomes

Clinical Parameters	N=10
Age	65 (31-83)
Sex (M/F)	6/4
Operative time (min)	299 (174-394)
Reconstruction (min)	82 (50-116)
Blood loss (g)	65 (0-325)
Lymph node dissection (D0/D1+/D2-10)*	1/7/2
Postoperative complications	0 (0%)
Mortality	0 (0%)
Length of postoperative hospital stay (days)	15 (8-18)

* D0 dissection was done for a patient with GIST.

Fig 1

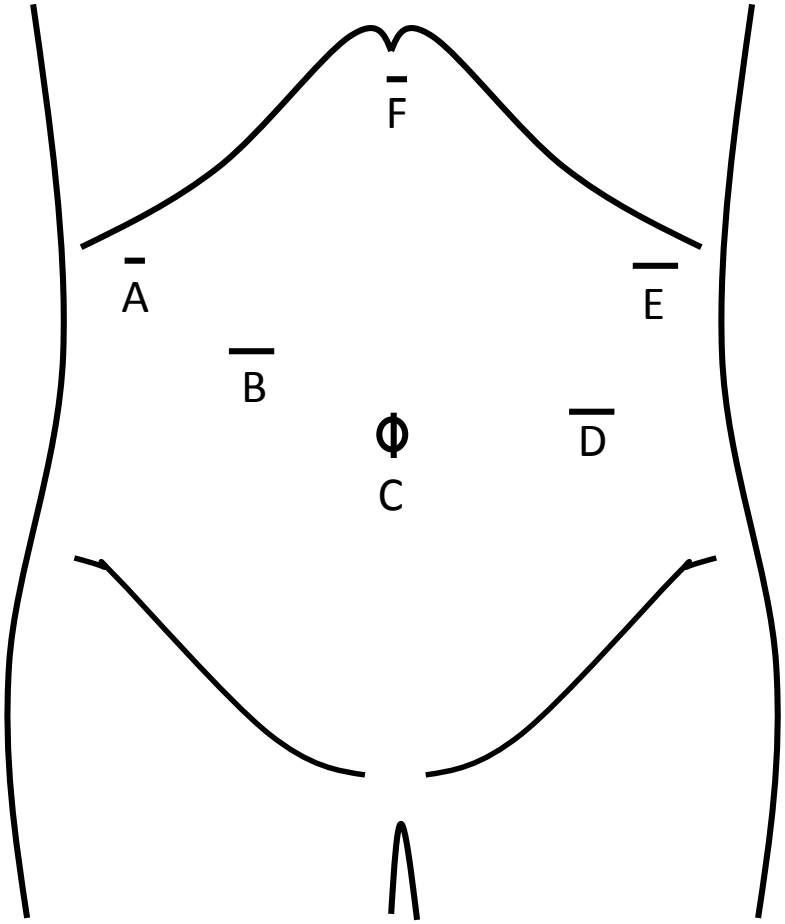

Fig 2

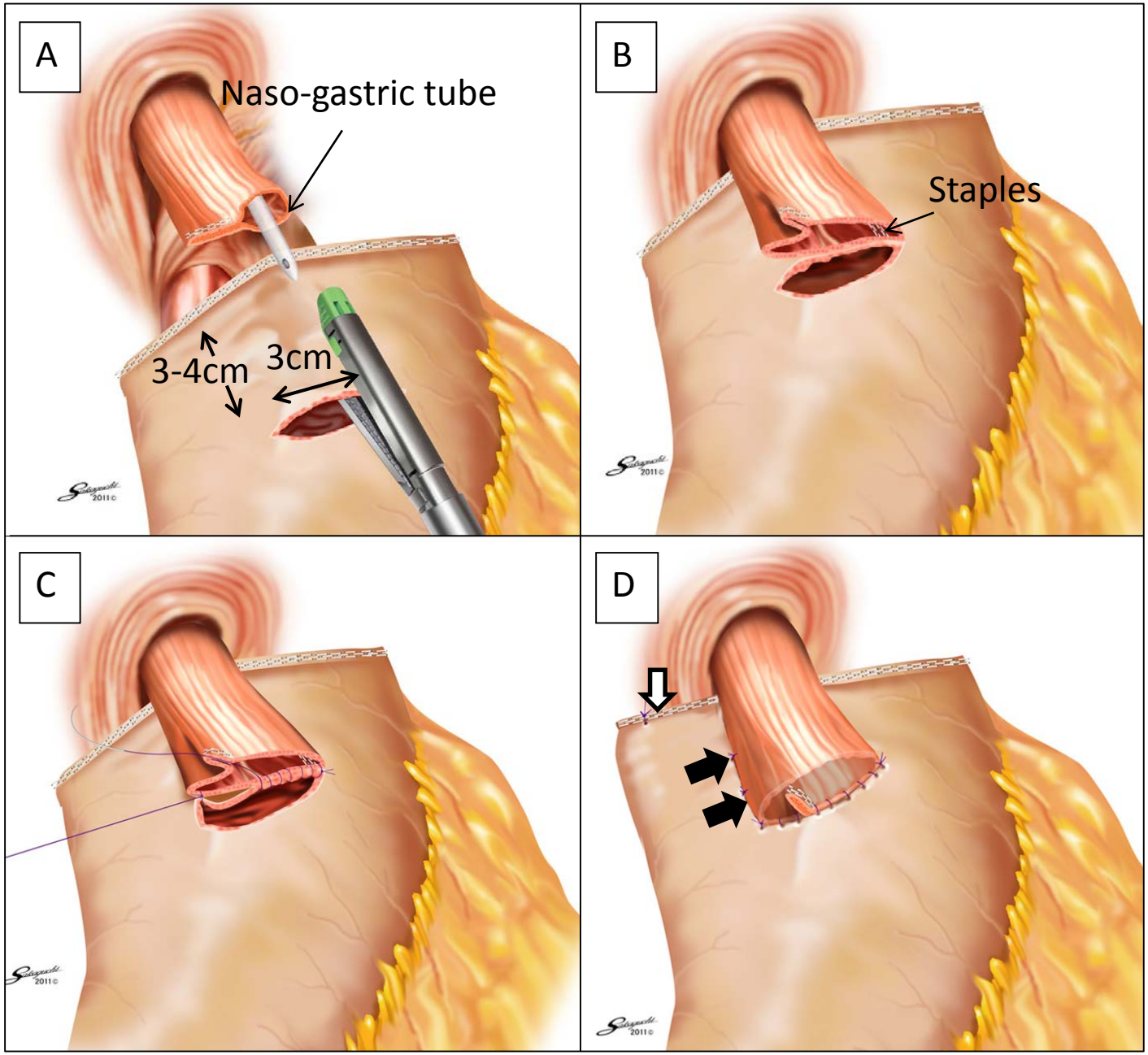

Fig 3

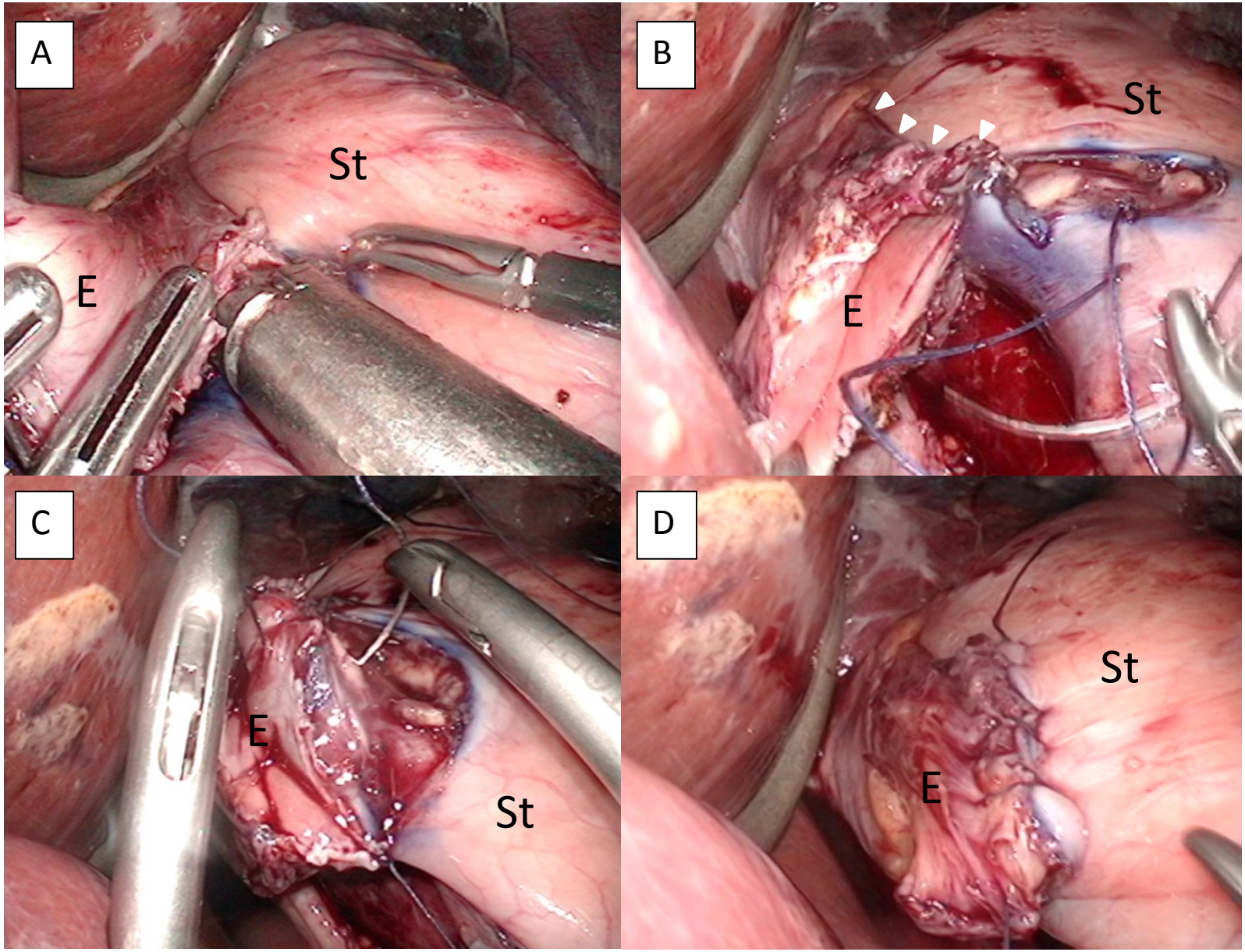

Fig 4

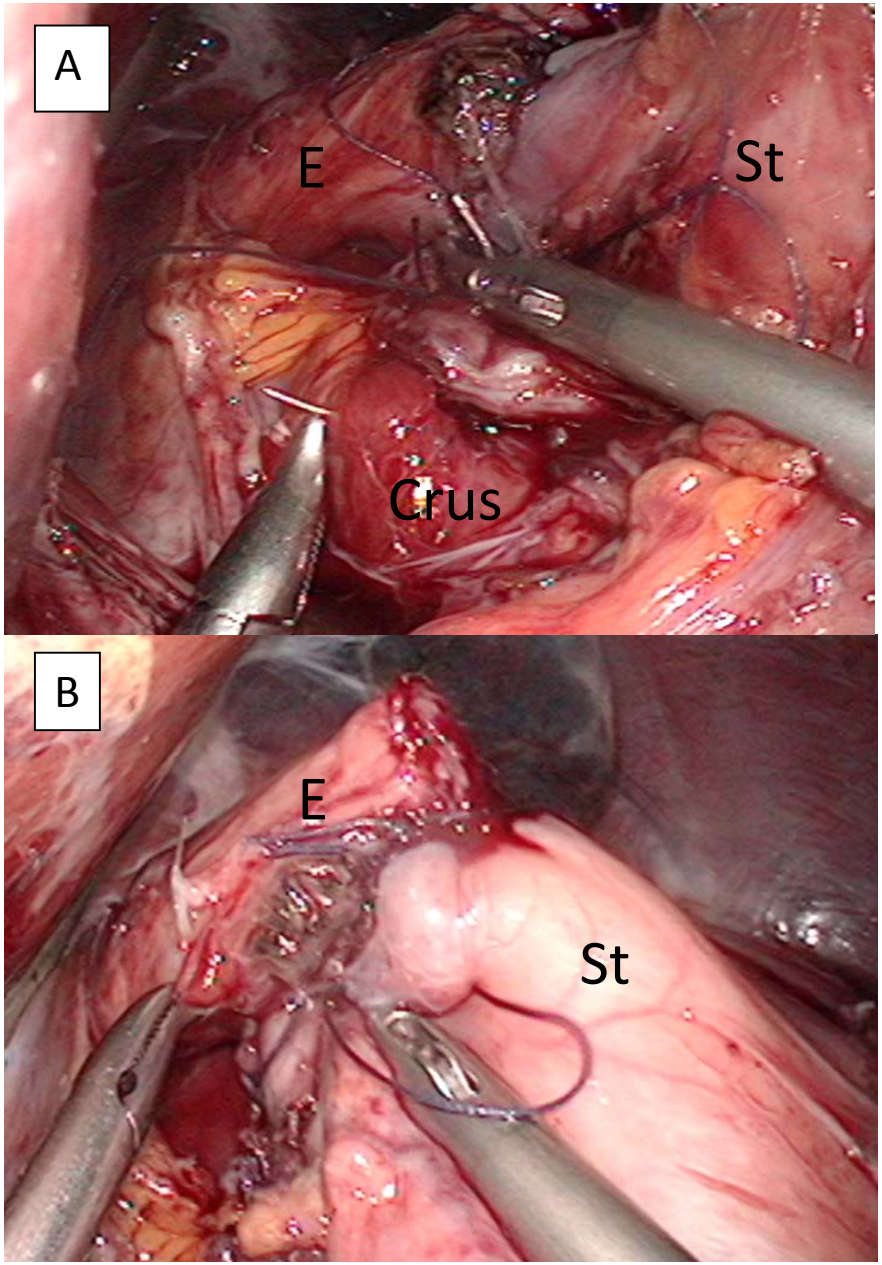

Fig 5