

# 左右不同脈ニ及ボス各種外科的治療ノ影響ニ就テ。

京都帝國大學醫學部眞下内科教室

織田正徳

京都帝國大學醫學部外科學教室

神部信雄

## Influence of Surgical Treatment of vascular Diseases upon Pulsus differens in the upper and lower Extremities.

(From the 3rd Medical Clinic and 1st Surgical Clinic of the Imperial University of Kyoto. (Directors: Prof. T. Mashimo, M. D. and Prof. R. Torikata, M. D.))

(With 15 tables in text and 2 figures)

By

Masanori Oda and Nobuo Kambe.

(内容抄録)

- 1) 著者等ガ外科的治療ノ前後ニ亙リテ各種症例ニ於ケル左右不同脈ヲ検索セル結果ハ次ノ如シ。
- 2) 特發脱疽、間歇跛行、Raynaud 氏病ノ如キ脈管障礙ニ於テハ治療前ニ左右不同脈ヲ認ム。
- 3) 各種疾患ニ於ケル左右不同脈ハ、外科的治療ニヨリテ變化ス。即チ中等度ノ症例ニ於テハ左右不同脈ハ平均サレ、場合ニヨリテハ左右反對トナル。然レドモ重症例ニ於テハ其差ヲ減ズルノミナリ。
- 4) 外科的治療ノ前後ニ於ケル左右不同脈ノ検査ニヨリテ治療法ノ効力ヲ決定シ得ラル。コレニ依レバ腰薦交感神經節切除術ハ他ノニツノ治療法(X線深部照射及ビ Leriche 氏手術)ニ優ル。後二者ノ中ニ於テハ寧ロX線深部療法(四肢末梢脈管障礙ニ對スル)ヲ優レリトナス。

### I. Introduction.

In the treatment of the vascular diseases of the extremities a great many methods, both medical and surgical, have been employed from early times up to the present. For the surgical operative treatment of such vascular diseases of the extremities, R. Leriche (1) first advocated periarterial sympathectomy in 1913 and thereafter the practical application of this method was generalized by the efforts of F. Brünig (2) and O. Stahl (3). Thenceforth a large number of authors all over the world have eagerly taken up the matter as an object of investigation and criticism. In 1925 T. Ohsawa (4) advocated lumbo-sacral and cervico-thoracal

sympathetic ganglionectomy instead of Leriche's periaarterial sympathectomy, in accordance with the suggestion of Dr. Hiromu Ito, Professor of orthopaedic surgery in the Imperial University of Kyoto. Recently H. Philip and I. Tunick (5) reported a new treatment for the vascular diseases in the lower extremities, viz. the application of deep Röntgen rays to the lumbar spine. A. Adson and G. Brown (6) treated patients suffering from vascular diseases of the lower extremities by combining the lumbar sympathetic ganglionectomy with Leriche's periaarterial sympathectomy and W. Oppel (7) advocated suprarenalectomy as a new surgical remedy for vascular diseases in the extremities.

M. Oda, one of the authors, has studied pulsus differens in the upper and lower extremities by means of the apparatus devised by himself (8) and published the results in his previous papers (9), (10). According to his results, pulsus differens is found either in the upper extremities or in the lower or in both in several vascular diseases such as spontaneous gangrene, claudicatio intermittens and Raynaud's disease, without any exception. It is rather noticeable that in nearly all the cases which have been treated by sympathectomia on the affected side, pulsus differens has been proved in both the upper and the lower extremities or only in the lower extremities.

In the present research the object of the authors was to investigate the effect on the vascular diseases of the treatments above mentioned, by observing the change in the pulsus differens.

## II. Results of the experiments.

The examinations were carried out in patients who were treated with sympathectomia or deep Röntgen therapy or a combination of these in the 1st surgical clinic from 1929 to 1930 under the guidance of Assist.-Prof. Dr. T. Ohsawa, the director being absent. Pulsus differens in the upper and lower extremities was examined by M. Oda's sphygmodyfferentiometer, the same pressure being applied to the arms and thighs before and after the surgical operation. In the case of the pulse curve, the authors examined the differences in three factors, namely the amplitude (P.D.), the form (F.D.) and the time (T.D.). The blood pressure of the examinees was always measured in the right brachium with Riva-Rocci's sphygmomanometer by Korothokow's auscultatory method, in the sitting posture,

Swan's first point was adopted for the maximum blood pressure and his fourth point for the minimum. The local temperature was estimated in the popliteal space on both sides. Such observations were repeated as long as the patients stayed in the clinic after the treatments and the change in the pulsus differens was compared with that in the clinical symptoms in the course of the diseases. It is very regrettable that in some cases the observations were interrupted by some unexpected sequelae of the operation, or by early dismissal from the hospital under unavoidable circumstances. The results of the observation, thus obtained, are shown in the following tables.

Table. I. (case 1) S. I., 32 years old, woman.

Clin. diagnosis: Spontaneous gangrene.

No. of examination	Date of examination	Blood press. (mmHg.)		Puls. diff. (arm)				Puls. diff. (thigh)			
		Max.	Min.	A.	D.	F.D.	T.D.	A.	D.	F.D.	T.D.
				R.	L.			R.	L.		
1	Oct. 25.	160	64	mm 6.5	mm 4.5	+	-	mm 2.8	mm 3.5	+	-
	Oct. 26.	Lumbo-sacral sympathetic gangliectomy was carried out.									
2	Nov. 8.	110	60	5.5	4.4	+	-	2.4	2.7	+	-
3	Nov. 14.	106	76	3.2	3.2	-	-	2.7	2.7	-	-
4	Nov. 22.	113	83	2.9	2.9	-	-	2.2	2.2	-	-
5	Dec. 13.	105	80	3.0	3.0	-	-	1.8	2.8	+	-
	Jan. 15. (1930)	Leriche's operation.									
6	Jan. 28.	102	72	5.4	3.7	+	-	3.0	2.4	+	-
7	Feb. 10.	93	67	7.9	8.5	+	-	6.1	5.8	+	-

## Course of the disease.

Before being admitted to the hospital, the patient suffered from pain and a cold sensation in the left middle finger in 1925 and the suffering finger was amputated. Claudication in the left lower extremity in 1927 and the fourth and fifth toes were amputated. The same complaint began on the opposite side in March 1928 and at that time the third and fifth toes were amputated.

Oct. 22. The patient was admitted to the clinic.

Oct. 25. A wound in the dorsal surface of the right foot (length: 1.5 cms,

breadth: 1.5 cms.)

- Oct. 26. Retroperitoneal lumbo-sacral sympathetic ganglionectomy was performed on both sides and the 4th and 5th lumbar ganglions and the 1st and 2nd sacral ganglions were removed.
- Nov. 8. The ulcerous wounds in both feet healed remarkably. Pulsus differens was examined.
- Nov. 14. The wound in the right foot healed entirely but in the left no notable change was seen. Pulsus differens was examined.
- Nov. 22. In the dorsal surface of the left foot, the bone was seen. Pulsus differens was examined.
- Dec. 13. The left 3rd toe coloured lividly and had a pulsating pain. Pulsus differens was examined.
- Dec. 18-30. Deep Röntgen therapy was applied dorso-ventrally and ventro-dorsally every other day. Dosis: 600 R. in the left lumbar region.
- Dec. 27. Slept well for the first time since the beginning of the illness.
- Jan. 12. Complained of sleeplessness and pain in the left foot.
- Jan. 15. L riche's operation was performed on the left side. Denudation 7 cms.
- Jan. 28. Pain in the left foot lessened. Pulsus differens was examined.
- Feb. 10. Re-formation of an ulcer on the surface of healed ulcer. Pulsus differens was examined.
- Feb. 20. Dismissal.

Table II. (case 2) E. T., 49 years old, man.

Clin. diagnosis: Spontaneous gangrene.

No. of examination	Date of examination	Blood press. (mmHg.)		Puls. diff. (arm)				Puls. diff. (thigh)			
		Max.	Min.	A. D.		F.D.	T.D.	A. D.		F.D.	T.D.
				R.	L.			R.	R.		
1	Dec. 20.	112	96	mm 4.5	mm 4.0	+	-	mm 6.5	mm 4.5	+	-
	Dec. 24-30. and Feb. 14-16. Deep Röntgen therapy.										
2	Dec. 30.	110	78	2.7	2.7	-	-	2.5	2.5	-	-
3	Jan. 18.	124	80	4.7	4.7	-	-	4.5	4.5	-	-

Course of the disease.

Before being admitted the patient had complained of a cold sensation and

pain at the tips of the left 1st and 2nd toes since 1927 and the wounds enlarged in 1930.

Dec. 17. The patient was admitted to the clinic.

Dec. 20. Pulsation in A. dorsalis pedis dextra was felt but no pulsation in the corresponding artery on the opposite side. Pulsus differens was examined.

Dec. 24-30. and Jan. 14-16. Perso-ventral and ventro-dorsal deep X-ray treatment was applied every other day. Dosis: 600 R.

Dec. 30. Pain lessened considerably and ulcerous wounds healed markedly. Pulsus differens was examined.

Jan. 18. Granulation somewhat cleaned. Pulsus differens was examined.

Feb. 6. Dismissal.

Table III. (case 3) C. M., 40 years old, man.

Clin. diagnosis: Spontaneous gangrene.

No. of examination	Date of examination	Blood press. (mmHg.)		Puls. diff. (arm)				Pulsus diff. (thigh)			
		Max	Min.	A.	D.	F.D.	T.D.	A.	D.	F.D.	T.D.
				R.	L.			R.	L.		
1	Jan. 21.	198	82	4.6	4.1	+	-	2.9	4.6	+	-
	Jan. 23.-Feb. 3. Deep Röntgen therapy.										
2	Feb. 10.			8.5	6.8	+	-	4.5	3.5	+	-
3	Feb. 28.			3.5	4.8	+	-	2.6	2.4	+	-
4	Mar. 5.	159	72	5.5	6.9	+	-	2.9	4.5	+	-

#### Course of the disease.

Before admittance, the patient had been operated on lumbo-sacral sympathetic ganglionectomy with removal of the left 4th lumbar- 1st sacral ganglions and the right 1st sacral ganglion on July 11; cervico-thoracal sympathetic ganglionectomy on both sides on July 21., 1928. Amputation of the right middle finger at the endophalangeal joint on Mar. 25; L'riche's operation on the right side on Nov. 26, 1929. Amputation of the right middle toe at metatarsophalangeal joint on Dec. 11, 1929.

Jan. 19. The patient was admitted to the clinic.

Jan. 21. Nail of the right middle finger lost. Pulsation in A. poplitea dextra

was normal, while weak pulsation could be proved on the opposite side; in *A. dorsalis pedis dextra* no pulse, but on the opposite side weak pulse was proved. *Pulsus differens* was examined.

Jan. 23.-Feb. 3. Deep Röntgen treatment was applied every other day.

Dosis: 600 R.

Feb. 10. Complained of sleeplessness on account of pain in the right foot and the whole morbid process in the right 2nd toe became a little worse. *Pulsus differens* was examined.

Feb. 15. Amputation of the right 2nd toe at the second metatarsophalangeal joint.

Feb. 28. *Pulsus differens* was examined.

Mar. 5. Pulsation in *A. poplitea dextra* was felt very faintly, that on the opposite side normal. Pulse in *A. dorsalis pedis dextra* was not proved but on the opposite side normal pulse felt in the homonymous artery. *Pulsus differens* was examined.

Table IV. (case 4) T. A., 36 years old, man.

Clin. diagnosis: Spontaneous gangrene.

No. of examination	Date of examination	Blood press. (mmHg.)		Puls. diff. (arm)				Puls. diff. (thigh)			
		Max.	Min.	A.	D.	F.D.	T.D.	A.	D.	F.D.	T.D.
				R.	L.			R.	L.		
1	Mar. 13.	126	73	6.9	7.4	+	-	5.0	7.5	+	-
	Mar. 17.	Lumbo-sacral sympathetic ganglionectomy was performed.									
2	Mar. 22.	116	68	4.4	5.3	+	-	2.9	3.7	+	-
3	Mar. 28.	120	60	8.0	9.0	+	-	4.9	4.9	-	-
4	Apr. 5.	122	65	8.0	6.5	+	-	6.0	4.6	+	-
5	Apr. 11.	109	59	9.2	10.0	+	-	4.9	6.0	+	-
6	Apr. 18.	110	65	7.0	5.1	+	-	6.0	7.0	+	-

Course of the disease.

Mar. 13. The patient was admitted to the clinic. *Pulsus differens* was examined.

Mar. 14. Ulceration at the tip of the left 2nd toe. Pulsation in *A. dorsalis pedis* on both sides palpable.

Mar. 17. Lumbo-sacral sympathetic ganglionectomy of the retroperitoneal type

was carried out with removal of the left 1st sacral ganglion.

Mar. 22. Pain lessened and the ulcerous wound cleaned. Pulsus differens was examined.

Mar. 28. No pain, the leg warmer. Pulsus differens was examined.

Apr. 5. No sign of epithelization. Pulsus differens was examined.

Apr. 11. The wound was covered with soft granulation and crust. Pulsus differens was examined.

Apr. 12-19. Deep Röntgen therapy was applied. Dosis: 600 R.

Apr. 18. No local spontaneous pain. Pulsus differens was examined.

**Table V.** (case 5) M. T., 51 years old, woman.

Clin. diagnosis: Gangrene from frostbite.

No. of examination	Date of examination	Blood press. (mmHg.)		Puls. diff. (arm)				Pulsus diff. (thigh)			
		Max.	Min.	A.	D.	F.D.	T.D.	A.	D.	F.D.	T.D.
				R.	L.			R.	L.		
1	Mar. 14.	105	54	mm 9.8	mm 9.8	—	—	3.0	3.8	+	—
	Mar. 17. Lumbo-sacral sympathetic ganglionectomy was carried out.										
2	Mar. 22.							3.5	2.1	+	—
3	Mar. 28.							3.0	2.8	÷	—
4	Apr. 5.							3.5	3.5	—	—
5	Apr. 11.							4.2	4.2	—	—

#### Course of the disease.

Since January 1930 had ulcers in the right foot.

Mar. 11. The patient was admitted to the clinic.

Mar. 14. Pulsation in A. dorsalis pedis was hardly palpable on both sides. Redness up to the middle of legs. Pulsus differens was examined.

Mar. 17. Retroperitoneal lumbo-sacral sympathetic ganglionectomy was performed on both sides with removal of the right 1st sacral and the left 5th lumbar and 1st sacral ganglions.

Mar. 22. Redness of the legs disappeared and they felt warmer. Temperature: R. 36.4°C L. 36.3°C. Pulsus differens was examined.

Mar. 28. Wounds nearly healed. Temperature: R. 36.3°C L. 35.7°C. Pulsus differens was examined.

Apr. 5. Temperature: R. and L. 36.0°C. Pulsus differens was examined.

Apr. 11. Temperature: R. 36.0°C, L. 36.1°C. Pulsus differens was examined.

Table. VI. (case 6) C. W. 31 years old, woman.

Clin. diagnosis: Raynaud's disease.

No. of examination	Date of examination	Blood press. (mmHg.)		Pulsus diff. (arm)				Pulsus diff. (thigh)			
		Max.	Min.	A.	D.	F.D.	T.D.	A.	D.	F.D.	T.D.
				R.	L.			R.	L.		
1	Mar. 14.	101	62	7.0	5.9	+	—	6.0	4.0	+	—
	Mar. 15.	Lumbo-sacral sympathetic gangliectomy was performed.									
2	Mar. 22.	103	72	3.0	3.5	+	—	4.0	3.0	+	—
3	Mar. 28.	94	64	7.5	6.0	+	—	7.9	4.5	+	—
4	Apr. 7.	95	65	6.8	6.0	+	—	9.7	5.1	+	—
5	Apr. 11.	92	55	6.2	5.6	+	—	6.9	6.0	+	—
	Apr. 11-24.	Deep Röntgen therapy was applied.									
6	Apr. 18.	91	58	7.0	5.5	+	—	5.6	6.5	+	—
7	Apr. 21.	95	65	6.1	5.9	+	—	5.0	6.5	+	—
8	Apr. 25	92	58	8.0	9.0	+	—	7.0	8.5	+	—

Course of the disease.

Since August 1928 the patient had suffered from analgesia in the feet before admittance.

Mar. 13. The patient was admitted to the clinic.

Mar. 14. Atrophia (—), cyanosis (—), feet cold. Pulsus differens was examined.

Mar. 15. Transperitoneal lumbo-sacral sympathetic gangliectomy was carried out on both sides with removal of the 5th lumbar and 1st sacral ganglions.

Mar. 22. Temperature: R. 35.2°C, L. 35.1°C. Pulsus differens was examined.

Mar. 28. Temperature: R. 35.7°C, L. 35.4°C. Pulsus differens was examined.

Apr. 7. Pain in both legs on walking. All toes cold. Temperature: R. 35.0°C, L. 35.2°C. Pulsus differens was examined.

Apr. 11. The left 1st toe was painful when exposal to cold. Temperature: R. 35.2°C, L. 35.5°C. Pulsus differens was examined.

Apr. 18. whole of feet cold. Pulsus differens was examined.



Apr. 21. No notable change. Pulsus differens was examined.

Apr. 25. Pulsus differens was examined.

Apr. 27. Dismissal.

**Table VII.** (case 7) R. S., 37 years old, man.

Clin. diagnosis: Claudicatio intermittens.

No. of examination	Date of examination	Blood press. (mmHg.)		Pulsus diff. (arm)				Pulsus diff. (thigh)			
		Max.	Min.	A.	D.	F.D.	T.D.	A.	D.	F.D.	T.D.
				R.	L.			R.	L.		
1	Nov. 21.	95	64	mm 10.0	mm 10.0	—	—	mm 10.0	mm 7.2	+	—
	Nov. 25.	Lumbo-sacral sympathetic ganglionectomy was carried out.									
2	Dec. 2.	92	55	8.2	8.2	—	—	6.0	3.3	+	—
3	Dec. 9.	91	60	8.5	8.5	—	—	4.5	3.9	+	—

Course of the disease.

Nov. 19. The patient was admitted to the clinic.

Nov. 21. Varix on the inside of the left leg. The left 1st, 2nd and 3rd toes coloured lividly. Pulsus differens was examined.

Nov. 25. Retroperitoneal lumbo-sacral sympathetic ganglionectomy was carried out on the left side with removal of the left 5th lumbar, 1st and 3rd sacral ganglions.

Dec. 2. The left foot felt warmer than the right. Pulsus differens was examined.

Dec. 9. Spontaneous pain disappeared entirely. Pulsus differens was examined.

Jan. 20. Dismissal.

**Table VIII.** (case 8) S. A., 42 years old, man.

Clin. diagnosis; Claudicatio intermittens.

No. of examination	Date of examination	Blood press. (mmHg.)		Pulsus diff. (arm)				Pulsus diff. (thigh)			
		Max.	Min.	A.	D.	F.D.	T.D.	A.	D.	F.D.	T.D.
				R.	L.			R.	L.		
1	Nov. 21.	114	86	mm 3.5	mm 3.5	—	—	3.2	2.8	+	—
	Nov. 30.	Lumbo-sacral sympathetic ganglionectomy was carried out.									
2	Dec. 5.	116	75	2.0	2.0	—	—	3.7	3.7	—	—
3	Dec. 13.	113	75	5.3	5.3	—	—	4.0	4.0	—	—
4	Dec. 30.	110	77	4.0	4.0	—	—	4.4	4.4	—	—

Course of the disease.

- Sep. 6. The patient was admitted to the clinic.
- Nov. 21. Pulsus differens was examined.
- Nov. 30. Retroperitoneal lumbo-sacral sympathetic ganglionectomy was carried out on the left side with removal of the left 1st sacral ganglion. The left 4th lumbar ganglion was only bruised.
- Dec. 5. The left foot felt warmer than the other. Temperature: R. 35.0°C, L. 35.7°C. Pulsus differens was examined.
- Dec. 13. No pain on walking. Pulsus differens was examined.
- Dec. 30. No notable change. Pulsus differens was examined.

**Table. IX.** (case 9) K. M., 27 years old, man.

Clin. diagnosis; Claudicatio intermittens.

No. of examination	Date of examination	Blood press. (mmHg.)		Pulsus diff. (arm)				Pulsus diff. (thigh)			
		Max.	Min.	A.		F.D.	T.D.	A.		F.D.	T.D.
				R.	L.			R.	L.		
		mm	mm	mm	mm			mm	mm		
1	Mar. 25.	118	55	10.0	10.0	—	—	10.0	11.0	+	—
		Mar. 26. Lumbo-sacral sympathetic ganglionectomy was performed.									
2	Apr. 1.	103	42	6.2	6.2	—	—	8.5	10.0	+	—
3	Apr. 7.	110	55	8.1	8.1	—	—	6.9	8.0	+	—
4	Apr. 14.	115	65	6.0	6.0	—	—	6.4	6.4	—	—
5	Apr. 21.	116	51	9.0	9.0	—	—	6.4	5.0	+	—
6	Apr. 25.	102	57	8.7	8.7	—	—	6.7	7.5	+	—
7	Apr. 28.	112	58	9.0	9.0	—	—	4.0	5.5	+	—

Course of the disease.

Before admittance the patient had complained of intermittent claudication since 1925.

- Mar. 22. The patient was admitted to the clinic.
- Mar. 25. No ulcerous wound. Pulsation in A. poplitea dextra was palpable while on the opposite side no pulse in the corresponding artery. Pulse in A. dorsalis pedis dextra was felt but in sinistra no pulse could be proved. Pulsus differens was examined.
- Mar. 26. Retroperitoneal lumbo-sacral sympathetic ganglionectomy was carried

out on both sides with removal of the right 1st sacral and the left 5th lumbar and 1st sacral ganglions.

- Apr. 1. No pain and cyanosis. Feet felt warmer than before. Temperature: R. 35.4°C, L. 35.6°C. Pulsus differens was examined.
- Apr. 7. Temperature: R. 35.6°C, L. 35.1°C. Pulsus differens was examined.
- Apr. 14. Temperature: R. 35.3°C, L. 35.4°C. Pulsus differens was examined.
- Apr. 21. Temperature: R. 35.0°C, L. 35.6°C. Pulsus differens was examined.
- Apr. 25. No notable chang. Pulsus differens was examined.
- Apr. 28. Pulsus differens was examined.

**Table. X.** (case 10) K. Y., 55 years old, man.  
Clin. diagnosis. Asthma bronchiale & aneurysma aortae.

No. of examination	Date of examination	Blood press. (mmHg.)		Puls. differens in the upper extrem.			
		Max.	Min.	A. D.		F.D.	T.D.
				R.	L.		
1	Mar. 14.	110	65	7.6	6.2	+	-
2	Mar. 22.	106	63	5.4	4.0	+	-
	Mar. 24. Cervical sympathetic ganglionectomy was carried out on the right side.						
3	Mar. 28.	106	58	9.0	7.8	+	-
4	Apr. 5.	102	65	8.0	5.4	+	-
5	Apr. 11.	124	80	4.9	3.8	+	-
	Apr. 12. Cervical sympathetic ganglionectomy was performed on the left side.						
6	Apr. 18.	117	78	4.5	3.8	+	-
7	Apr. 21.	124	78	4.1	3.8	+	-
8	Apr. 25.	128	85	4.6	4.6	-	-
9	Apr. 28.	128	90	2.8	2.0	+	-

(Pulsus differens was examined only in the upper extremities.)

#### Course of the disease.

Before admittance the patient was treated in the 3rd Medical Clinic without any recovery.

Mar. 13. The patient was admitted to the 1st Surgical Clinic.

Mar. 14. Sibilants and rales all over lungs.

Mar. 24. Cervical sympathetic ganglionectomy was carried out with resection

of ganglion cervicale medium and ganglion cervicale inferius on the right side.

- Mar. 28. Cough and sputa diminished markedly. Pulsus differens was examined.
- Apr. 5. All symptoms considerably better. Pulsus differens was examined.
- Apr. 8. Though sibilants and rales had diminished they were still audible all over lungs.
- Apr. 10. Abundant sibilants and rales especially in the left lung.
- Apr. 11. Pulsus differens was examined.
- Apr. 12. Cervical sympathetic ganglionectomy was performed on the left side with removal of ganglion steratum.
- Apr. 18. Rales in the middle anterior portion of lungs scanty. Pulsus differens was examined.
- Apr. 21. Light attack of dyspnoea. Pulsus differens was examined.
- Apr. 25. Pulsus differens was examined.
- Apr. 28. Pulsus differens was examined. Dismissal.

**Table. XI.** (case 11) K, N., 14 years old, boy.  
Clin. diagnosis: Gonitis tuberculosa dextra.

No. of examination	Date of examination	Pulsus differens in the lower extremities.							
		A.		D.		F.	D.	T.	D.
		R.	L.	R.	L.				
1	Jan. 27.	mm 5.0	mm 6.0			+			-
	Jan. 28.- Feb. 12. Treated with deep X-ray therapy.								
2	Feb. 16.	4.8	7.2			+			-
3	Feb. 28.	7.2	8.0			+			-
4	Mar. 5.	4.7	6.0			+			-

(Pulsus differens was examined only in the lower extremities.)

4. Course of the disease.

Before the deep Röntgen therapy the patient had undergone Leriche's operation on Nov. 6. 1929.

Jun. 26. The patient was admitted to the clinic.

Jan. 27. Temperature: R. 35.6°C, L. 35.1°C. Many wounds in the upper and lower parts of the right knee joint. Pulsus differens was examined.

- Jan. 28.- Feb. 12. Treated with deep X-rays every other day. Dosis: 300 R.  
 Feb. 15. No notable change in the wounds. Temperature: R. 35.2°C, L. 35.0°C.  
 Feb. 16. Pulsus differens was examined.  
 Feb. 27. Temperature: R. 35.2°C; L. 3.0°C.  
 Feb. 28. Puesus differens was examined.  
 Mar. 5. Temperature: R. 35.0°C, L. 35.2°C. Pulsus differens was examined.  
 Mar. 11. Dismissal without sufficient improvement under unavoidable circumstances.

**Table. XII.** (case 12) G. L. 13 years old, boy.

Clin. diagnosis: Gonitis tuberculosa dextra.

No. of examination	Date of examination	Pulsus differens in the lower extremities.					
		A.		D.		T.	
		R.	L.	F.	D.	T.	D.
1	Jan. 27.	mm 2.8	mm 3.5		+		-
	Jan 28.- Feb. 12.	Treated with deep Röntgen therapy.					
2	Feb. 10.	2.6	3.5		+		-
3	Feb. 16.	6.2	7.2		+		-
4	Feb. 28.	4.2	5.5		+		-
5	Mar. 5.	3.5	7.3		+		-

(Pulsus differens was examined only in the lower extremities.)

Course of the disease.

- Sep. 15. The patient was admitted to the clinic.  
 Jan. 27. At the upper part of the knee joint of the suffering extremity there were three wounds and they were covered with granulation. Each of them had a fistula. Temperature was under 35.0°C on both sides. Pulsus differens was examined.  
 Jan. 28.- Feb. 12. Deep Röntgen therapy was applied every other day. Dosis: 300 R.  
 Feb. 2. Temperature: R. 35.8°C, L. 35.9°C.  
 Feb. 10. Pulsus differens was examined.  
 Feb. 16. Temperature: R. 36.1°C, L. 35.8°C. Pulsus differens was examined.  
 Feb. 28. Temperature: R. 35.9°C, L. 35.0°C. Pulsus differens was examined.

Mar. 11, Dismissal.

**Table. XIII.** (case 13) S. H., 19 years old, woman.  
Clin. diagnosis: Osteomyelitis tuberculosa of the left tibia.

No. of examination	Date of examination	Pulsus differens in the lower extremities.							
		A.		D.		E.	D.	T.	D.
		R.	L.	R.	L.				
1	Feb. 7.	mm 5.1	mm 4.4			+			—
	Feb. 8.- 19. Treated with deep X-rays.								
2	Feb. 21.	6.0	5.3			+			—
3	Feb. 28.	6.9	4.4			+			—
	Mar. 5. Ito-Ohsawa's operation was carried out.								
4	Mar. 14.	5.5	3.8			+			—
5	Mar. 22.	6.5	5.5			+			—
6	Mar. 28.	7.0	6.4			+			—
7	Apr. 5.	5.5	4.5			+			—
8	Apr. 11.	2.6	3.7			+			—

(Pulsus differens was examined only in the lower extremities.)

Course of the disease.

Before our examination, the affected tibia had been trepanned on Feb. 4. 1929. Leriche's operation was carried out on the left side on Oct. 9. the same year.

Feb. 4. The patient was admitted to the clinic.

Feb. 7. There was a wound at the upper end of the left tibia covered with loose granulation tissue. Marked atrophy from disuse of the left extremity. Circumference: R. 27.7cm, L. 25.6cm.

Feb. 8.- 19. Deep Röntgen therapy was applied every other day. Dosis: 450 R.

Feb. 22. Complained of pain in the wound. Pulsus differens was examined.

Feb. 28. Temperature: R. 25.5°C, L. 35.8°C. Pulsus differens was examined.

Mar. 5. Retroperitoneal sacral sympathetic gangliectomy was carried out on the left side with resection of the 1st sacral ganglion. Pulsus differens was examined.

Mar. 22. Complained of pain in the wound again. Pulsus differens was examined.

Mar. 28. Temperature: R. 36.7°C, L. 36.4°C. Pulsus differens was examined.

Apr. 5. Temperature: R. 35.6°C, L. 37.1°C. Pulsus differens was examined.

Apr. 11. Temperature: R. 35.8°C, L. 36.4°C. Pulsus differens was examined.

**Table XIV.** (case 14) T. K., 30 years old, man.

Clin. diagnosis: Eczema in the right leg.

No. of examination	Date of examination	Pulsus differens in the lower extremities.			
		A.		D.	
		R.	L.	F. D.	T. D.
1	Jan. 18.	mm 14.8	mm 9.5	+	-
	Jan. 18. Zériche's operation was performed on the lower extremities.				
2	Feb. 1.	9.1	9.1	-	-
(Pulsus differens was examined only in the lower extremities.)					

Course of the disease.

Jan. 17. The patient was admitted to the clinic.

Jan. 18. Pulsus differens was examined.

Leriche's operation was carried out on the right side.

Jan. 22. Erosion markedly healed.

Jan. 28. Eczema completely healed.

Feb. 1. Pulsus differens was examined.

**Table XV.** (case 15) H. K., 27 years old, man.

Clin. diagnosis: Tuberculosis of the left ankle-joint.

No. of examination	Date of examination	Pulsus differens in the lower extremities.			
		A.		D.	
		R.	L.	F. D.	T. D.
1	Feb. 5.	mm 7.0	mm 2.6	+	-
	Feb. 5. Retroperitoneal lumbo-sacral sympathetic gangliectomy was performed on the left side.				
2	Feb. 16.	7.5	5.0	+	-
3	Feb. 28.	8.0	4.2	+	-
4	Mar. 7.	5.2	4.4	+	-
5	Mar. 14.	8.1	6.4	+	-
(Pulsus differens was examined only in the lower extremities.)					

Course of the disease.

Feb. 1. The patient was admitted to the clinic.

- Feb. 5. The left ankle-joint markedly swollen and in the upper part of malleolus lateralis there was a fistula. On this day retroperitoneal lumbo-sacral sympathetic ganglionectomy was carried out on the left side with removal of the 4th and 5th lumbar and the 1st sacral ganglions. Pulsus differens was examined.
- Feb. 16. The wound became oedematous. Pulsus differens was examined.
- Feb. 28. Oedema vanished entirely. Pulsus differens was examined.
- Mar. 7. Pulsus differens was examined.
- Mar. 14. Pulsus differens was examined.

### III. Summary and discussion.

The authors studied the influence of the surgical treatment applied to 4 cases of spontaneous gangrene, 1 case of gangrene from frostbite, 1 case of Raynaud's disease, 3 cases of claudicatio intermittens and 1 case of asthma bronchiale with aneurysma aortae upon pulsus differens in the upper or the lower extremities or both in the long course of the disease followed the treatment applied. According to their results pulsus differens was found in the four extremities before the surgical treatment in all the cases, and smaller amplitude of the pulse curve was found on the side on which the subjective complaints were more serious than on the other, with the exception of case 4, as was stated in M. Oda's previous reports. This pulsus differens in the four extremities proved before the surgical treatment, was influenced by the therapeutics applied, though the degree of the influence was different from case to case. By the therapeutics applied the difference in the pulses on both sides was diminished, equalised or reversed, and the cause of such alteration of the difference was the relative increase in the amplitude of the pulse curve and the increase in the dirotic property, showing dilatation of the blood vessel. In the mild cases either in the upper extremities or in the lower the difference in the pulses on both sides was equalised or reversed, while in the serious ones the difference in the pulses was not markedly altered, or only a slight diminution of the difference took place. Such a diminution of the difference took place ca. 7 days after operation or deep X-ray treatment, and 7-14 days after the pulses on both sides had become equal, if those treatm-



ents had a favorable effect upon these diseases. That is to say, the effect of the treatments applied is revealed at such an interval after the treatments have been carried out.

The change in the pulse volume on each side can be measured by M.Oda's sphygmodyfferentiometry method, which is very convenient and accurate for examining the change in the blood flow in the arteries on both sides. Hitherto the relief of pain has generally been used as a criterion by which to judge whether the treatment has resulted in improvement. A pain is caused by asphyxia due to interruption of the blood supply, however, objective and numerical estimation of the change in the blood flow may be a more rational method of judging the result of the treatments than the observation of subjective complaints such as pain.

Léris's periarterial sympathetic neurectomy, Ito-Ohsawa's lumbo-sacral (cervico-thoracal) sympathetic ganglionectomy or deep Rontgen therapy is employed to lessen the objective complaints, which are usually very serious, by increasing the blood flow in the suffering extremities. For this purpose R. Léris advocated his new procedure, adopting M. Jaboulay's (11) idea. After his first report had been published, many authors examined that method experimentally and clinically. Some of them such as Lehman (12), Wiedhopf (13) etc. stated that the results of their experiments showed that this operation had not a good effect, while some others such as F. Brünning & O. Stahl, F. Brünning, E. Campbell (14), A. Halstead & F. Christopher (15), Lehmann (16), H. Kümmel (17), J. Philipowicz (18), S. Schlesinger (19) etc. declared that it had.

In the course of the present investigation, Léris's operation was carried out only in one case, and it was found that the pulse once equalised by Ito-Ohsawa's lumbo-sacral sympathetic ganglionectomy in the upper extremities was again disturbed 3 days after Léris's operation, but 16 days after this operation the difference in the pulses was reversed, while the difference in the pulses in the lower extremities that occurred by relapse after lumbo sacral sympathetic ganglionectomy was diminished by Léris's operation.

Since T. Ohsawa published his new procedure A. Adson & G. Brown (20)

(21) have advocated it as a successful method of treating peripheral vascular diseases of the extremities. According to the results of the authors observation, lumbo-sacral sympathetic ganglionectomy is more favorable than Leriche's operation. The dilatation of the blood vessels on the operated side took place 6-12 days after the operation.

H. Philips & I. Tunick applied deep Röntgen therapy in the treatment of thromboangilitis obliterans (Bürger) and M. Nakata & E. Karatsu (22) also used it in treating spontaneous gangrene, and Monier-Vinard (23), Monier-Vinard, L. Delherm & H. Beau (24) and J. Boak (25) applied it in Raynaud's disease. The present authors applied deep X-rays to the lumbar ganglions in many patients who had pulsus differens. According to their results, the deep X-ray treatment diminished, equalised or reversed the difference in the pulses on both sides within a few days after the application.

The authors carried out Leriche's operation in a case of eczema in the lower extremities (case 14), with good effect. R. Leriche (26) applied his own procedure in this disease, obtaining good results.

T. Ohsawa used his lumbo-sacral sympathetic ganglionectomy for osteomyelitis of the extremities and L. Browntree & A. Adson (27) treated patients with polyarthritis of the lower extremities by bilateral lumbar sympathetic ganglionectomy and ramisection, obtaining good results. But no one has hitherto tried the deep X-ray treatment for arthritis of extremities showing pulsus differens as a result of atrophy from disuse, observing the influence of this treatment on the difference in the pulses. The authors applied the deep Röntgen therapy in such arthritis of the lower extremities. According to their results, pulsus differens in such cases was not affected, and they examined pulsus differens in the course of the disease for a time long after the treatment. In cases which had been subjected to lumbo-sacral sympathetic ganglionectomy, however, pulsus differens was affected, and the influence was just as in the case of the vascular diseases above mentioned, but in a smaller degree. Diminution of the difference in the pulses on both sides took place within 14 days after the operation.

The discrepancy between the results obtained by the deep X-ray treatment

and lumbo-sacral sympathetic ganglionectomy shows the value of these therapeutic methods. In the case of spontaneous gangrene, intermittent claudication or Raynaud's disease etc. the excitability of the sympathetic nervous system is raised and the effectiveness of the deep X-ray treatment in those cases was greater than that in control cases such as gonitis, osteomyelitis and tuberculosis of the ankle-joint.

With regard to the duration of the effect of these therapeutic methods, one must observe much longer.

#### IV. Résumé.

1) The authors studied pulsus differens in various cases before and after the surgical treatment applied for them with following results:

2) In the case of vascular diseases such as spontaneous gangrene, claudicatio intermittens or Raynaud's disease, pulsus differens exists as a symptom even before the treatment.

3) Pulsus differens is modified by the surgical treatment applied for these diseases. In mild cases, the difference in the pulses on both sides is equalised or reversed, while in serious ones, pulsus differens is only diminished.

4) By examination of pulsus differens before and after surgical treatment, the merits of the therapeutic methods employed can be decided. From this point of view, lumbo-sacral (cervico-thoracal) sympathetic ganglionectomy surpasses the other two. In the remaining two the authors prefer deep X-ray treatment for vascular diseases in the peripheral parts of the extremities as a therapeutic method.

The cordial thanks of the authors are due to Prof. T. Mashimo, and Assistant-Prof. T. Ohsawa for their kind guidance and encouragement.

---

Explanation of the photographs.

Fig. I. Case 1. Before treatment.

The amplitude and form of the pulse curves differ from each other, but time-difference is not proved.

(Pressure, 60 mm Hg.)

織田・神部論文附圖

Fig. 1




Fig. 2

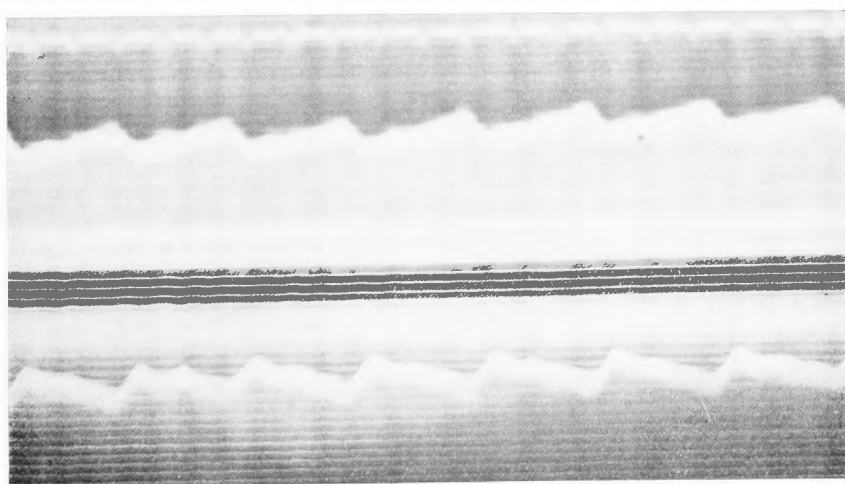


Fig. II. Case 1. 42 days after the performance of lumbo-sacral sympathetic gangliectomy on both sides with resection of the 4th and 5th lumbar and the 1st and 2nd sacral ganglions.

The right pulse curve is absolutely the same as the left in amplitude, form and time.

(Pressure, 60 mm Hg.)

In all the photographs, the upper curve denotes the pulse curve obtained from the right arm, the lower that of the left, and the time-marker shows 0.2 sec.

### Remarks.

In all tables

A.D.: denotes the difference in the amplitude of the pulse curves (Unit: mm.)

F.D.: denotes the difference of the form.

T.D.: denotes the time difference.

Max.: denotes the maximum blood pressure (mm. Hg.)

Min.: denotes the minimum blood pressure (mm. Hg.)

R. and L.: denote the right and the left side respectively.

### References.

- 1) **R. Leriche**; Press. méd., 25, 513. (1917) cit. The Journ. of the Amer. Med. Assoc., 89, 964. (1927)
- 2) **F. Brünig**; Klin. Wochenschr., 3, 2087. (1924)
- 3) **F. Brünig & O. Stahl**; Chirurgie des vegetativen Nervensystems, Berlin, 1924.
- 4) **T. Ohsawa**; Verhandl. d. japan. Chir. Gesellschaft. (1925) (Japanese)
- 5) **H. Philips & I. Tunich**; The Journ. of the Amer. Med. Assoc., 84, 1496. (1925)
- 6) **A. Adson & G. Brown**; Ibid., 84, 1908. (1925)
- 7) **W. Oppel**; Z.-org. f. d. ges. Chir., 16, 272. (1922)
- 8) **M. Ob**; Acta scholae med. Univers. Imper. Kioto., 12, 343. (1929)
- 9) **M. Oda**; Ibid., 12, 469. (1930)
- 10) **M. Oda**; Ibid., 12, 505. (1930)
- 11) **M. J. boulay**; Zentralbl. f. Chir., 138. (1900)
- 12) **Lehman**; Annals of surgery, 77, 30. (1923)
- 13) **Wiedhcoqf**; Beiträge zur klin. Chir., Tübingen. (1923) cit. J. A. M. A. 427. (1924)
- 14) **E. Campbell**; Surg. Gyn. & Obst., 38, 81. (1924)
- 15) **A. Halstead & F. Christophe**; J. A. M. A., 80, 173. (1923)
- 16) **Lehmann**; Klin. Wochenschr., 1, 2019. (1922)
- 17) **H. Kümmel**; Zentralbl. f. Chir., 50, 270. and 1434. (1923)
- 18) **J. Philipowicz**; Ibid., 50, 829. (1923)
- 19) **H. Sc I singei**; Münch. med. Wochenschr., 70, 102. (1923)
- 20) **A. Adson & G. Brown**; J. A. M. A. 92, 444. (1929)
- 21) **A. Adson & G. Brown**; Ibid., 94, 250. (1930)
- 22) **M. N. Kita & E. Karatsu**; Grenzgebiet, 3, 1541. (1929) (Japanese)
- 23) **Monier-Vinard**; Zentralbl. f. Chir., 59, 2425. (1929)
- 24) **Monier-Vinard, L. D lierm & H. Beau**; Gazette des hospitanox, 21, 389. (1929)
- 25) **J. Boak**; Wien. med. Wochenschr., 1, 563. (1929)
- 26) **R. Leriche**; Lyon chir., 6, 651. (1919)
- 27) **L. Browntree & A. Adson**; J. A. M. A., 88, 694. (1927)