
症 例

Malignant Lymphoma Arising in the Duodenum Combined with Gastric Lymphoma and Early Gastric Cancer: A Case Report

NAOKI UYAMA, NORIMICHI KAN, KAZUTOMO INOUE¹⁾, AYAO TORII, TORU KAJIYAMA, SHUNJI UEDA, MASAHIKO SAKAI, MASAROU TAJIMA²⁾ AND MASAYUKI IMAMURA¹⁾

¹⁾First Department of Surgery, Faculty Medicine, Kyoto University, Kyoto, Japan

²⁾First Department of Internal Medicine, Faculty Medicine, Kyoto University, Kyoto, Japan

Received for Publication, Dec, 27., 1994

Abstract

We report here a 65-year old man with primary duodenal malignant lymphoma combined with gastric lymphoma and early gastric cancer. Malignant lymphoma in the bulbous of the duodenum was suspected of by endoscopic biopsy during follow up of duodenal ulcer. Preoperative examination revealed an extension of malignant lymphoma from the bulbous to the stomach in combination with early gastric cancer. We performed a pancreaticoduodenectomy because the tumor invaded to the second portion of the duodenum. The postoperative course was uneventful and he received adjuvant chemotherapy following surgery. To our knowledge, this case is the first report of primary duodenal malignant lymphoma combined with gastric lymphoma and early gastric cancer.

Introduction

The incidence of primary gastrointestinal malignant lymphoma was reported to be 4.5% of all lymphomas¹⁾. Especially, lymphoma arising from the duodenum is rare, constituting 1.6-12% of primary gastrointestinal lymphoma^{2,3,4)}. Moreover, duodenal malignant lymphoma combined with early gastric cancer seems to be extremely rare. We report here a patient with duodenal malignant lymphoma associated with gastric lymphoma and early gastric cancer who underwent successful surgical resection.

On November 24, 1993, a 65-year-old man was admitted to the first department of surgery, Kyoto University, with suspicion of duodenal malignant lymphoma. Three years earlier, he consulted a doctor for upper abdominal pain and was diagnosed with duodenal ulcer stage A1 by endoscope and received anti-ulcer drugs. There after, he had undertaken endoscopic examination twice a year. In September, 1994, an abnormality of duodenal bulbous and pylorus of the stomach was noted on endoscopy and malignant lymphoma was suspected of by endoscopic biopsy. There-

索引用語: 十二指腸, 悪性リンパ腫, 早期胃癌, 超音波内視鏡

Key words: malignant lymphoma, gastric cancer, EUS

Present address: Department of Surgery, Toyooka Hospital, 6-35, Tachino Toyooka, Hyougo, 668, Japan.

fore, he was referred to our hospital. His history included subarachnoidal hemorrhage which was treated conservatively five years ago.

Physical examination was as follows. The patient was a well-developed, well-nourished man. The abdomen was soft and flat. There was no hepatomegaly, splenomegaly or lymphadenopathy.

Laboratory findings were as follows. Hematological examination was within normal limits. Biochemical test was normal. Tumor markers were normal except for serum CEA level which was slightly elevated.

On abdominal ultrasonography, no abnormal findings were noted except hyperechoic mass in the gallbladder suggesting cholelithiasis.

An upper gastrointestinal series revealed a slight deformity in the angle portion, a filling defect on the greater curvature of the antrum, and deformity and stenosis in the first portion of the duodenum (Fig. 1-A, B).

Endoscopy showed a IIc like lesion, 20 mm in diameter in the posterior wall of the midcorpus of the stomach, a shallow and irregular ulcer, 25 mm in diameter in the anterior wall of the angle portion, a small erosion in the antrum, and multiple reddish erosions in the first portion of the duodenum. Endoscopic biopsy showed well-differentiated tubular adenocarcinoma in the posterior wall of the midcorpus and non-Hodgkin lymphoma in the first portion of the duodenum (Fig. 2).

Endoscopic Ultrasonography demonstrated four findings; (1) thickening of the second layer in the cardia and on the lesser curvature in the upper part of the corpus. (2) the existance of a hypoechoic mass, 2-3 mm in diameter in the third layer in the posterior wall of the midcorpus and on the greater curvature of the lower part of the corpus. (3) the existance of an homogeneous hypoechoic mass extending in the angle portion from the anterior wall to the posterior wall. It was

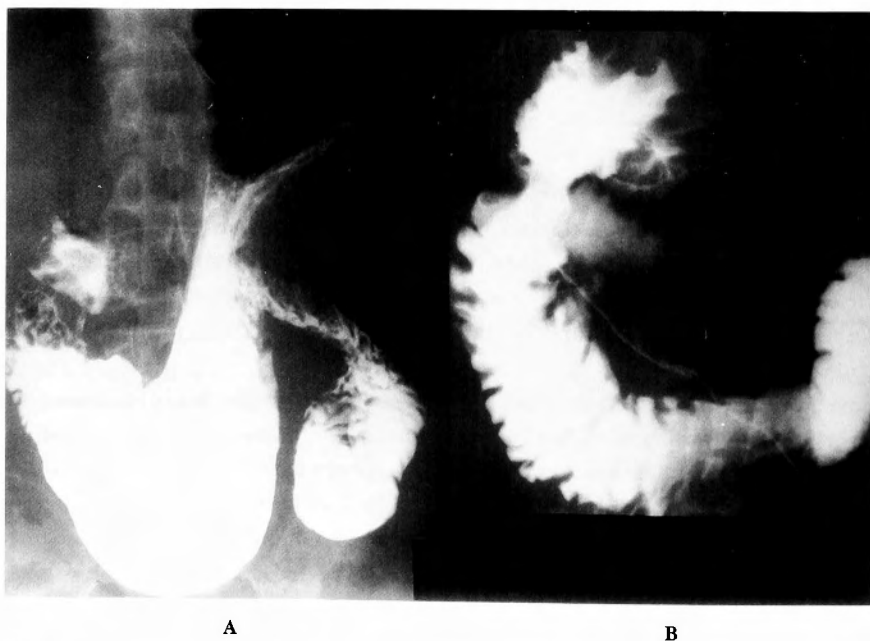


Fig. 1-A, B A; An upper gastrointestinal series in the stomach showing a slight deformity in angle portion and a filling defect on great curvature of the antrum. B; An upper gastrointestinal series in the duodenum showing deformity and stenosis in the first part of the duodenum.

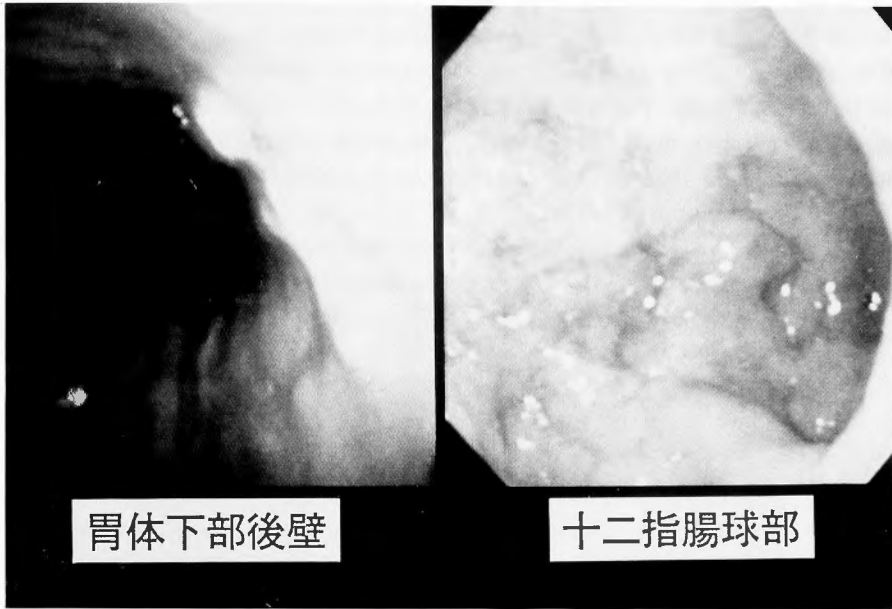


Fig. 2-A, B Endoscopic pictures of the posterior wall in the midcorpus and the duodenum. In the posterior wall of the midcorpus, II c like lesion is seen. In the duodenum, multiple reddish erosions are seen.

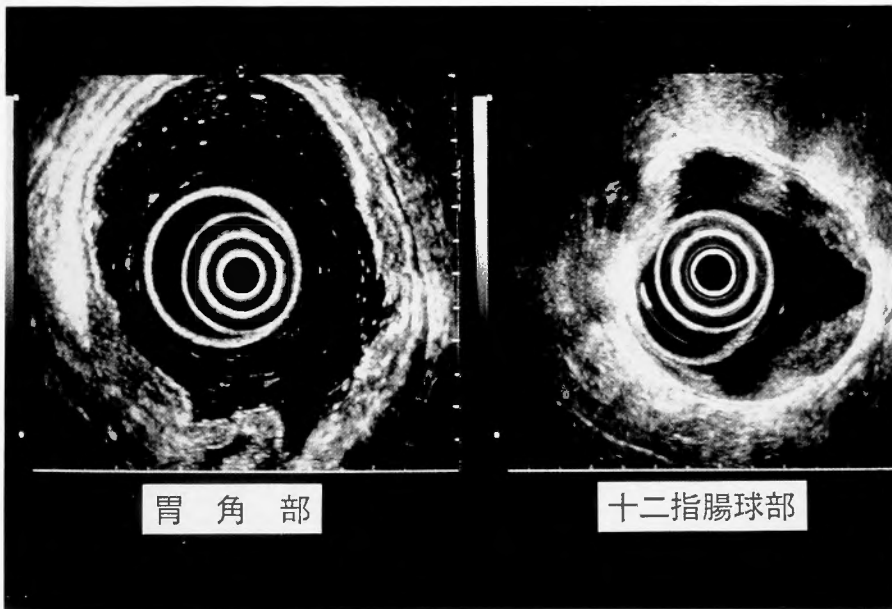


Fig. 3-A, B A; In the angle portion of the stomach, EUS showed a hypoechoic mass from the anterior wall to the posterior wall. B; In the duodenum, EUS showed a homogeneous hypoechoic mass in a half circle.

derived from the second layer, partially infiltrating to the fourth layer of the anterior wall. The lesions extended horizontally rather than vertically. Therefore, we considered this lesion malignant lymphoma. (4) the existence of a homogeneous hypoechoic mass, similar to that was found in angle portion, in the posterior wall of the antrum and in the first portion of the duodenum. It extended in a half circle in the duodenum (Fig. 3-A, B, C).

Computed tomography showed a calcified lesion in the gallbladder, which was thought to be cholelithiasis. There were no other abnormal findings including hepato-splenomegaly or enlarged abdominal lymph nodes.

Surgical findings were as follows: Exploration of the peritoneal cavity revealed that (1) the spleen and liver were normal. (2) in the gallbladder, stones were palpable (3) in the stomach, the cardia and E-C junction were normal on palpation. A tumor approximately 3 cm in diameter, which

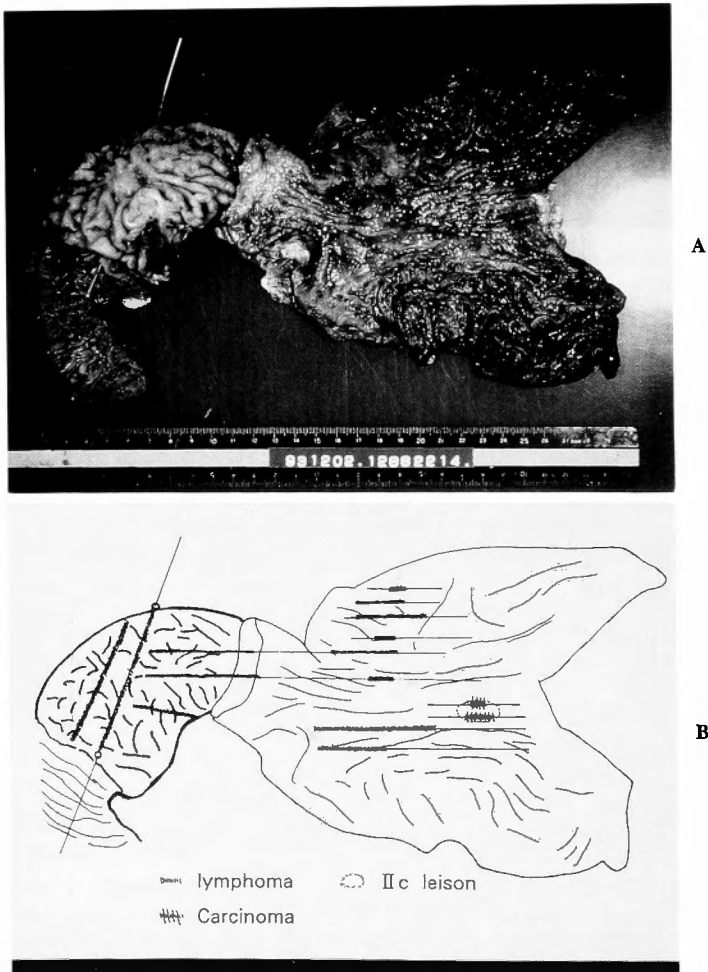


Fig. 4-A, B Macroscopic findings of the resected specimen. A II c like lesion was found in the posterior wall of the midcorpus and three submucosal tumor lesions were found in the antrum of the stomach. In duodenum, diffuse erosions and a circular thickened wall was found from pylorus ring to the upper part of the 2nd portion.

did not infiltrate to the serosa, was palpable on the lesser curvature of the antrum. (4) In the duodenum, we palpated a circular tumor mainly in the first portion, but partially extending to the second portion of the duodenum. (5) Lymph nodes were not enlarged on palpation and we did not touch the thickened mesentery and mesocolon. Based on the above findings, we performed a cholecystectomy and pancreaticoduodenectomy with three-fourths resection of distal stomach and we anastomosed the stomach, pancreas, and common bile duct to the jejunum in order, respectively, from the oral side.

The specimen excised from the greater curvature showed II c like lesion (2 cm in diameter) in the posterior wall of the midcorpus, two submucosal tumors (1.5 cm × 1 cm, 0.5 cm × 1.0 cm) in the anterior wall of the antrum and one submucosal lesion (0.5 cm × 0.5 cm) in the posterior wall of the antrum. In the duodenum, the specimen showed diffuse erosions from the pylorus ring to the upper part of the second portion (about 10 cm) with a circular thickened wall (Fig. 4).

Pathological specimen showed well differentiated tubular adenocarcinoma limited in the mucosa of the posterior wall of the midcorpus and a diffuse infiltration of lymphoma cells in the anterior and posterior wall of the antrum, in the duodenum and in the pancreas. This was diagnosed as diffuse, medium-sized, non-Hodgkin malignant lymphoma, B cell type because immunochemical study demonstrated that the tumor cell was B cell type lymphoma which had a monoclonality of κ chain, λ

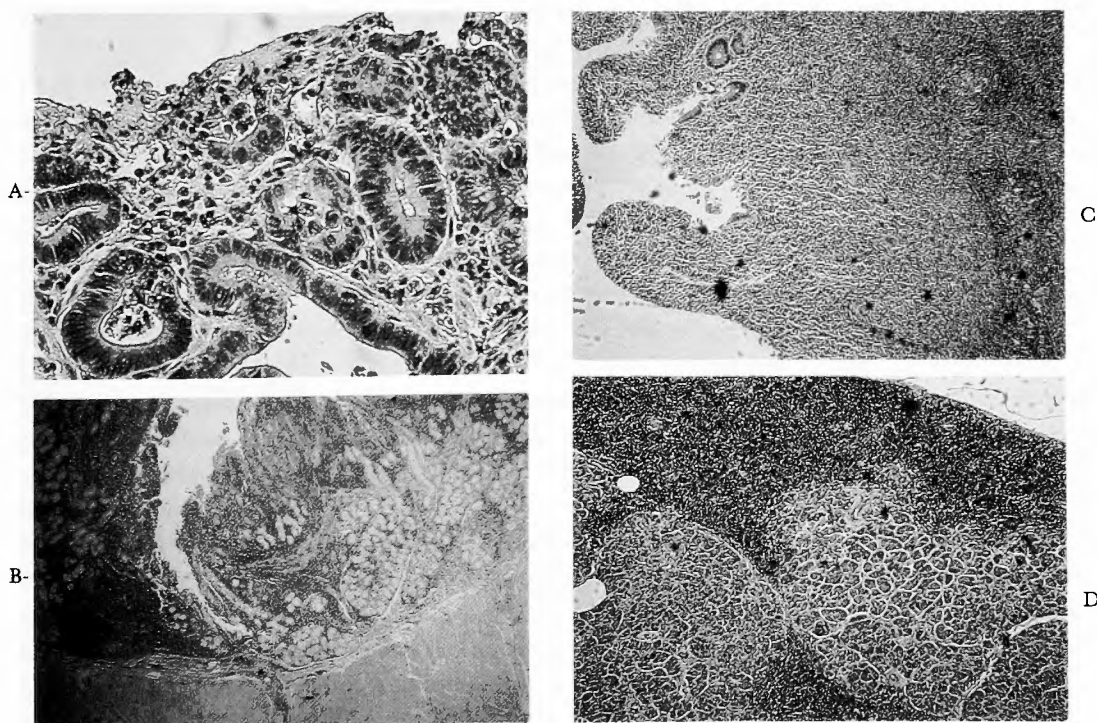


Fig. 5-A, B, C, D A; Microscopic picture of the posterior wall of the midcorpus. A well-differentiated tubular adenocarcinoma was seen. (H-E stain, ×400) B; Microscopic picture of the antrum in the stomach. Submucosal infiltration of the lymphoma is shown. (H-E stain, ×40) C; Microscopic picture of the duodenum. subserosal infiltration of the lymphoma is seen. (H-E stain, ×100) D; Microscopic picture of the pancreas. Lymphoma invading to the pancreas was seen. (H-E stain, ×400)

chain, μ chain and was positive for surface markers of HLA-DR, B1, B2 and B4 (Fig. 5-ABCD).

Postoperative course was satisfactory. On the 18th POD, ^{67}Ga -citrate was performed. It showed no abnormal accumulation. On the 33rd POD, postoperative chemotherapy (Etoposide, Methotrexate, Vindesine, Prednisolone) was begun.

Discussion

Sixty percent of primary gastrointestinal lymphoma is reported to arise in the stomach and 20% in the small intestine⁹⁾. The incidence of lymphoma arising in the duodenum is 1.6–12% of primary small intestinal malignant lymphoma. To our knowledge, 58 reports of lymphoma arising in the duodenum were published and there is only one report of primary duodenal malignant lymphoma combined with an early gastric cancer in Japan till 1993⁵⁾. Our case is extremely rare, since histological examination revealed a primary duodenal malignant lymphoma combined with gastric lymphoma as well as early gastric cancer.

The patient reported here apparently satisfied Dawson's criteria⁶⁾ for primary gastrointestinal malignant lymphoma. These criteria consist of five points: (1) absence of palpable superficial lymphadenopathy; (2) normal leukocytes and differential counts; (3) absence of enlarged mediastinal lymph nodes on chest X-ray; (4) no grossly demonstrable involvement beyond the affected segment of the intestine and its regional mesentric lymph nodes at the time of diagnosis; (5) absence of tumor involvement of the liver and the spleen.

The pathological specimen revealed that the tumor cells in the duodenum infiltrated to the subserosal layer and as the lesion neared the antrum, infiltration was more superficial. In the antrum, the tumor was located in the submucosal layer. In general, malignant lymphoma grows horizontally rather than vertically⁷⁾. Therefore, we considered that malignant lymphoma in this patient arose in the duodenum and extended to the antrum.

Concerning preoperative and postoperative diagnosis, preoperative biopsy and EUS diagnosis were nearly consistent with the postoperative diagnosis except for the lesion in the angle of the stomach, which was pseudonegative on preoperative biopsy. Biopsies sometimes result in pseudonegative findings for malignant lymphoma. We think that it is because biopsies can not clearly show the atypism of the cell, which is difficult to distinguish from the mesenchymal cell in mucosal layer, and the tissue of malignant lymphoma is so soft that it tends to be destroyed during biopsy. However, there are three points which are characteristic of EUS images showing malignant lymphoma⁷⁾. (1) The tumor infiltrates horizontally than vertically. (2) The tumor is often located in the 2nd and 3rd layer. (3) The tumor shows a homogeneous low density area. The EUS images of the angle and the antrum in this case fulfilled the above three points, demonstrating that EUS was useful in the diagnosis of malignant lymphoma.

Finally, we tried to determine the prognosis of this case. According to Klaus J. Lewin⁸⁾, the prognosis of the gastrointestinal lymphoma appears to correlate best with the stage of the disease rather than the histologic type. In this case, lymphoma had spread from the antrum to the 2nd portion with invasion to the pancreas, but there was no involvement of regional lymph nodes.

Using Ann Arbor classification for malignant lymphoma, this case was in stage II_E and the prognosis for this stage is not poor. (stage I_E; the extent of disease is confined to the viscus/stage II_E; the extent of disease is confined to the viscus and involvement of regional lymph nodes/stage IV; wide-spread) On the other hand, using the Contreary classification⁹⁾, this case is class III and the prognosis

Table 1-A A; Two-year survival rate according to Ann Arbor classification shown by Lewin. Stage I E; The extent of disease is confined to the viscus/Stage II E; The extent is confined to the viscus and involvement of regional lymph nodes/Stage IV; widespread.

Stage	Two-year survival rate
I E(17)	82%
II E(12)	71%
IV (6)	0%

() ; N

Table 1-B B; Five-year survival rate according to Contreary's classification. CLASS I; lymphoma confined to the bowel without extra intestinal involvement/CLASS II; mesentric nodes only/CLASS III; paraaortic node involvement or extension by contiguity to adjacent viscera.

	CLASS I	CLASS II	CLASS III
Overall (102)	59% (41)	72% (15)	24% (56)
Stomach (67)	60% (32)	80% (5)	39% (30)
Small intestine (24)	40% (6)	75% (6)	12% (12)

%; 5 year survival rate () ; N

Table 1-C C; Five year survival rate after curative and palliative resection shown by Contreary.

	Total	Curative resection	Palliative resection
Over all (102)	38%	64%	17%
Stomach (67)	42%	62%	23%
Small intestine (24)	27%	62%	0%

%; 5 year-survival rate () ; N

is rather poor. (class I; lymphoma confined to the bowel without extraintestinal involvement/class II; mesentric nodes only/class III; paraaortic node involvement or extension by contiguity to adjacent viscera.) However, according to Contreary, the prognosis of the case that undergoes curative resection is much better than the case without curative resection (Table 1-A, B, C).

Duodenal lesions are reported to carry a worse prognosis than other gastrointestinal lesions^{1,6,10} because the extension length of the lesion was already 5 cm or more when clinical symptoms appeared, and duodenal malignant lymphoma tends to infiltrate to other organs (especially, the colon and pancreas). Nevertheless, it seems likely that the prognosis of this patient may not be worse, since postoperative adjuvant chemotherapy as well as curative resection was performed. Careful follow-up of this patient must be done.

References

- 1) Ahmad z. Najem, John L. Polcano, Benjamin F. Rush Jr. et al: Primary non-Hodgkin's Lymphoma of the Duodenum. *Cancer* 54: 895-898, 1984.

- 2) Redentor JG, Pagtalunan, Charles W. Mayo, Malcolm B. Dockerty, et al: Primary malignant tumor of the small intestine. *Am. Jour. Surg.* 108: 13-18, 1964.
- 3) Marcuse PM, Stout AP, et al: Primary lymphosarcoma of the small intestine. *Cancer*, 3: 459-474, 1950.
- 4) Fu YS, Perizin: Lymphosarcoma of the small intestine. *Cancer*, 29: 645-659, 1972.
- 5) Ueno J, Yoshida A, Uyama Y, et al: Malignant Lymphoma of the Duodenum with Early Gastric Carcinoma. *Stomach and Intestine*. 17: 1269-1272, 1982.
- 6) IMP. Dawson JS. Cornes, BC. Morsons et al: Primary malignant Lymphoid tumors of the intestinal tract. *Br. Jour. Surg.* 49: 80-89, 1961.
- 7) Luigi Bolondi, Paolo Casanova, Gian Carlo Caletti, et al: Primary Gastric Lymphoma versus Gastric Carcinoma; Endoscopic US Evaluation. *Radiology*. 165: 821-826, 1987.
- 8) Klaus J. Lewin, Mahendra Ranchod, Ronald F. Dorfman, et al: Lymphoma of Gastrointestinal Tract, *Cancer*. 42: 693-707, 1987.
- 9) Kelvin Contreary, Francis C. Nance, Walter F. Becker, et al: Primary Lymphoma of the Gastrointestinal Tract, *Ann, Surg.* 191: 593-598, 1980.
- 10) Herbsman H, Hassan A, Gardner B, et al: Tumor of the small intestine. *Curr, Prob, Surg.* 17: 127, 1980.

和文抄録

十二指腸原発の悪性リンパ腫と早期胃癌を合併した一例

京都大学 第一外科

宇山 直樹, 菅 典道, 井上 一知, 今村 正之

京都大学 第一内科

鳥居 恵男, 梶山 徹, 上田 俊二, 酒井 正彦, 田嶋 政朗

消化管原発の悪性リンパ腫のうち十二指腸原発悪性リンパ腫は、比較的稀である。早期胃癌を併発した症例は更に少なく、本邦では文献上二例目である。今回、我々は更に胃リンパ腫も合併した非常に稀な症例を経験したのでここに報告する。

症例は65歳の男性。主訴は上腹部痛。現病歴は、三年前に十二指腸潰瘍 stage A1 と診断されその後内視鏡にて経過観察していたが、今回十二指腸球部に異常を認め、更に生検にて悪性リンパ腫が疑われたので当

科を紹介された。術前検査にて病巣は、十二指腸球部を中心に胃粘膜下に浸潤しており、さらに早期胃癌の合併が疑われ開腹、臍頭十二指腸切除術にて上記が確認された。今回術前の生検で胃悪性リンパ腫は偽陰性であったが、EUS では悪性リンパ腫に典型的な所見を呈した部位が有り、病巣の診断に EUS が有効であった。また予後については治癒切除し得たが、Contreary の分類では CLASS III に相当するため術後に化学療法 (VEMP 療法) を施行した。