

---

臨 床

---

## Treatment of Anal Fissure: A Comparison of Three Different Forms of Therapy

GERALD DENK GIEBEL, RAYMUND HORCH

Department of Surgery Faculty of Medicine of the University of Bonn West Germany  
Received for Publication, May 12, 1988.

### Summary

454 patients with a fissure-in-ano were treated by different forms of therapy. In a follow-up we examined 314 patients, 178 of them having been treated by anal stretch, 60 of them by subcutaneous lateral sphincterotomy and 76 of them by conservative measures. Most of the anal stretched patients were free of symptoms. Only few of them had to be treated again for the same disease by their physician. Anal stretch - similar to sphincterotomy - breaks the pathologically raised sphincter tone. We therefore propose anal stretch gently performed over a period of 3-5 minutes under general anaesthesia as the method of choice for the initial treatment of anal fissure. In cases of relapse we recommend lateral sphincterotomy by an experienced operator.

### Introduction

The anal fissure occurs as a longitudinal oval ulcer in the skinlined part of the posterior midline of the anal canal. However it can be found in the anterior midline in up to 10% in women and up to 1% in men. Lateral fissures are rare. It is predominant in young adults but is sometimes seen in infants and children. Several anal fissures at the same time are considered to be an exception. The fissure is a frequent and rather painful disease. The pain is explained by the extensive sensible innervation of the anoderm. There is no morphological correlation between pain and degree of anal fissure.

Since there are various opinions about the origin as well as the best form of treatment of fissure-in-ano we studied 454 patients in a follow-up after different methods of therapy.

### Etiology and Pathogenesis

The exact pathogenesis of anal fissures is not completely understood yet. It was suggested

---

Key words: Anal fissure, Etiology, Different forms of treatment, Anal stretch, Results.

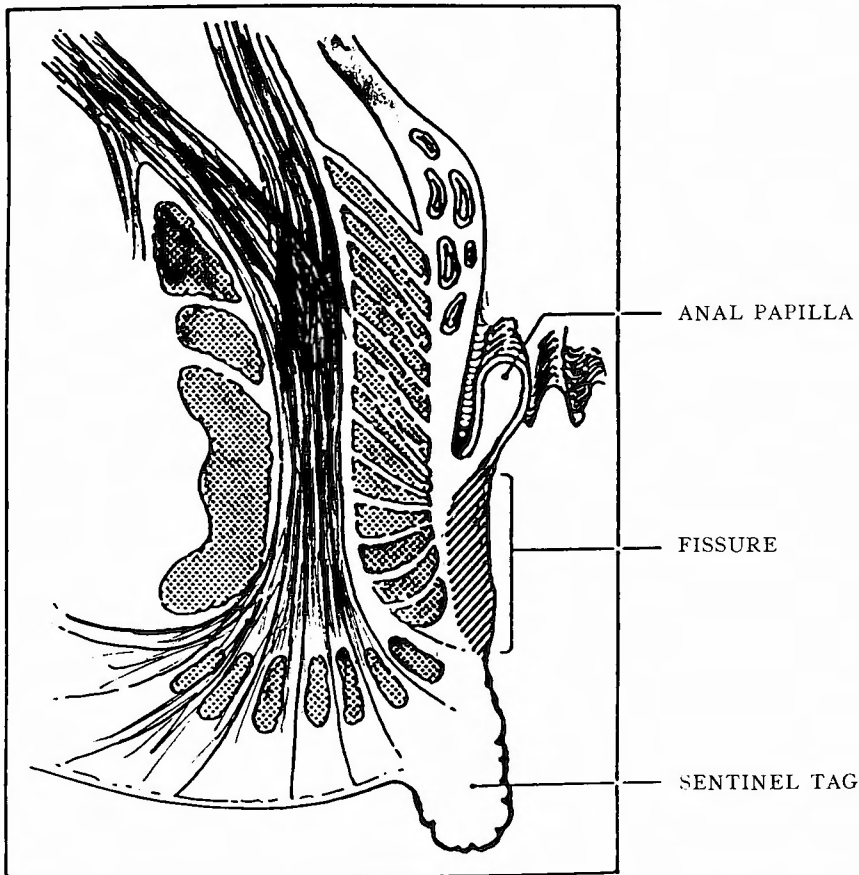
索引語: Anal fissure, Etiology, Different forms of treatment Anal stretch, Results.

Dr. Gerald Denk Giebel (M.D.), Dr. Raymund Horch (M.D.), Department of Surgery, Faculty of Medicine of the University of Bonn, S. Freud-Str. 25. D-5300 Bonn-Venusberg, West Germany.

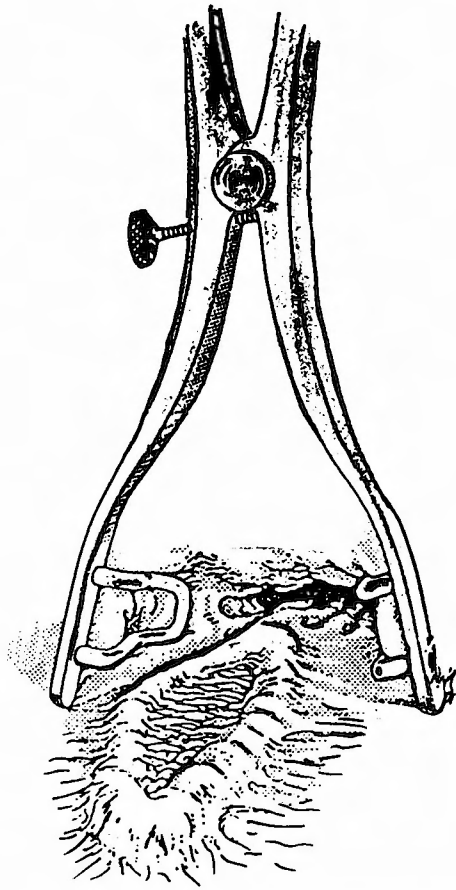
(3) that all concepts are still subject of speculation. It was also stated (1) that fissures occur more often in context with other anal diseases. Other authors (5) have noted that the anal pain often arises after a period of diarrhoea and the onset of normal or hard stool. *Stelzner* (11/12) has recurrently mentioned that there is an increased muscle tonus in combination with hemorrhoids. This raised anal pressure is connected with a reduced blood outflow and serves as an explanation for the frequent occurrence of hemorrhoids and fissures at the same time.

### Pathological Morphology

In the beginning there is a simple superficial tear only, measuring 0.5 cm when the anal canal is stretched. It is situated between the *linea anocutanea* and the *dentate line* (Fig. 1). The edges become undermined and tend to bleed when they are altered mechanically. Within a few days at the outmost end of the fissure a swollen and red dermal fold, the so called "sentinel tag" arises as a result of the diminished lymph drainage. At the inner end of the lesion a so-called "hypertrophic anal papilla" can be the consequence of the chronic irritation.



**Fig. 1** Localtztion of anal fissure between skin and dentate line; anal papilla as well as the sentinel tagare pictured too.



**Fig. 2** Chronic fissure-in-ano parting the anal verge.

Even after spontaneous healing in this stage the sentinel tag as well as the hypertrophic anal papilla are persistent (Fig. 2).

However, usually the disease turns over into a chronic stage. The edges become undermined and the base deepens to expose the circular fibres of the internal sphincter. In 5%-10% of cases an intersphincteric abscess or a subcutaneous fistula-in-ano can be found (5).

### Symptoms and Signs

Almost all patients complain of the excruciating pain which occurs during defaecation and often lasts for several hours. It can radiate into the back, the legs or into the genital region. It ranges from mild to severe and can cause a psychological constipation. Blood is usually seen as a smear on the toilet paper or on the stool and is bright. It is predominant in chronic fissures as a leading sign to diagnosis. Pruritus is common and occurs up to 50% of cases, whereas constipation is noticed in only 25% of cases. In addition to this we found some patients very anxious about the sentinel tag. In extremely severe cases we saw some patients

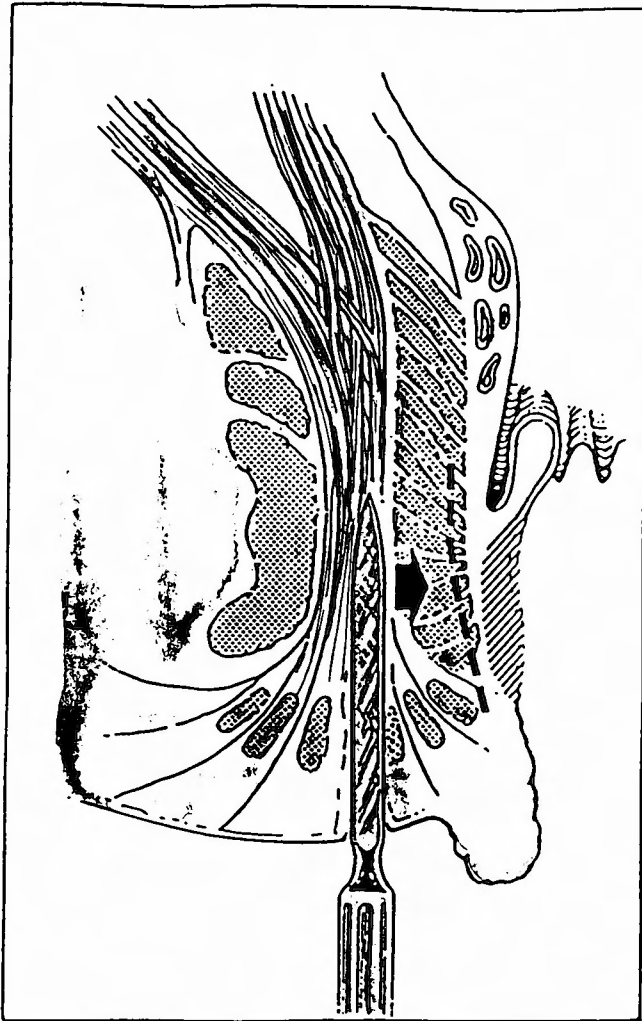


Fig. 3 Technique of lateral subcutaneous sphincterotomy.

complaining about disturbances of miction.

### Diagnosis

A fissure is diagnosed through the complaints of the patient and by inspection, parting the anal verge to show a longitudinal split in the lower anal canal.

In the differential diagnosis a thrombosed perianal varyx or anorectal abscess may be considered as reasons of severe pain and a chronic intersphincteric abscess or intermittently discharging fistula may present with exacerbations and remissions similar to a long-standing fissure. Sexually transmitted diseases such as warts, syphilitic lesions or herpes and anal carcinoma can produce bleedings and other symptoms as well as hemorrhoids, proctitis or a low-lying rectal neoplasm. Anal pruritus, stenosis of the internal sphincter muscle, proctocolitis

and inflammatory bowel disease, especially ulcerative colitis and Crohn's disease have to be excluded carefully. A precise discrimination can be achieved by histological, serological and microbiological investigations.

### Management

The aim of therapeutical measures is to dissolve stenosis and spasm of the internal anal sphincter muscle. Further on the drainage of secretion from the bottom of the lesion is attended.

*Conservative treatment*, only applied to patients with a short history and a simple superficial split without papilla or tag, consists of laxatives to soften the stool and local anaesthetic preparations to relieve symptoms. Anal dilatation with local anaesthesia only is not part of our therapeutical regimen as irreversible damage may be done to the internal sphincter muscle.

*Anal Stretch* is considered to be an operative approach to the disease and is carried out in general anaesthesia. We perform this therapy on outpatients. The dilatation is started by inserting the index fingers gently. After the third and fourth fingers are introduced usually the slight initial resistance disappears. Dilatation should be continued for about 5 minutes with four fingers at a time.

*Posterior Sphincterotomy* used to be practiced for a long time but has become less popular nowadays. The functional results are rather poor compared with lateral sphincterotomy. There have been reports of minor disturbances of continence in 20%-40% of cases. In our experience it is only necessary where a fissure is associated with a posterior fistula or intersphincteric abscess.

*Lateral Sphincterotomy* is the procedure of first choice in our regimen. In general anaesthesia an anal retractor is inserted and a mixture of Adrenalin and a local anaesthetic is injected submucously for hemostasis. A lateral incision is made and the lower border of the internal sphincter can be identified either by direct vision or palpation, as the fibers are almost white compared to the red-brown colour of the external sphincter. The fissure is then divided up to the dentate line. A sentinel tag and papilla is excised in the same session. A laxative is prescribed. The patient can leave the hospital usually on the next day. The operative procedures, however, can be followed by partial loss of continence. As this side effect is mentioned up to 30% in the literature we compared the three different and most common forms of therapy treated in our hospital.

### Examination and Results

Between 1979 and 1986, 454 patients were treated for anal fissures. 116 patients (25.5%) underwent conservative treatment. 249 patients (54.8%) received an anal stretch, 89 patients (19.6%) were treated by lateral sphincterotomy. Mean age was 46.1 years, and 236 (52%) were female.

314 (69.2%) of 454 could be followed up. This group consisted of 178 (56.7%) patients with anal stretch, 60 (19.1%) with lateral sphincterotomy and 76 (24.2%) with conservative

**Table 1** Results of the follow-up examination after treatment of anal fissures with three different forms of therapy.

	AS	LS	CT
without symptoms	120=67.4%	36=60.0%	41=53.9%
relapse	35=19.7%	8=13.3%	17=22.4%
treated again	22=19.7%	11=18.3%	16=21.1%
2nd operation because of relapse	7= 3.9%	1= 1.7%	5= 6.6%
Inflammatory bowel disease	7= 3.9%	6=10.0%	4= 5.3%
Incontinence			
(smear in underclothing)	1= 1.3%	2= 2.6%	
(flatus incontinence)		2= 2.6%	
(faecal incontinence)		1= 1.3%	

Total number of patients: n=454

CT=Conservative treatment, n=116 (25.5%)

AS=Anal Stretch, n=249 (54.8%)

LS=Lateral Sphincterotomy, n=89 (19.6%)

Mean age: 46.1 years

236 female patients

Follow up: n=314 (69.2%)

in the follow up group: AS: n=178 (56.7%)

LS: n= 60 (19.1%)

CT: n= 76 (24.2%)

treatment only. 17 patients had died because of other diseases, 9 patients had moved away and could not be found, the rest of cases did not want follow-up examination.

The examination had to be done at least one and a half year after the first treatment. Were without symptoms 67.4% of patients after anal stretch, 60.6% after lateral sphincterotomy and 53.9% after conservative therapy. 22.4% had a relapse after conservative treatment, 19.7% after anal stretch and 13.3% after sphincterotomy. 12.4% of conservatively treated and 19.7% of anal stretched patients as well as 13.3% of patients with sphincterotomy had a new attack of the anal disease. In the examination period 6.6% of cases from the conservative treatment group, 3.9% from anal stretch group and 1.7% from sphincterotomy group patients finally had to be operated upon for an acute relapse. 7 patients with anal stretch (3.9%), 5 patients with lateral sphincterotomy (10.0%) and only 4 patients (8.3%) with conservative treatment had an inflammatory bowel disease in addition. In our follow-up study we found only 5 patients complaining about partial incontinence. One patient reported recurrent minor disturbance of continence. After anal stretch we did not find anal incontinence up to now (see Table 1).

### Discussion

The etiology of anal fissure is unknown. The raised sympatheticotonus is probably one of the central factors within the pathophysiological chain of the disease. In contrast to the motility of other bowel tracts, where motility is regulated by the stimulus of sympathal nervous

system and the inhibition through parasympathic activity, the activity of sphincter muscles is controlled merely by the influence of sympathetic nerves. This was proved especially for the internal anal sphincter (14), which has no intramurally localized ganglion cells and is therefore regulated by extramural impulses. Others have found that unstable patients are suffering more often from a fissura-in-ano, because stress situations lead to an increased sympathal tonus. The elevated anal rest pressure was recently proved over the whole distance of the anal sphincter zone. The constant state of tonic activity in the lower anal canal during the distension of the rectum is the result of the reduced opening capability (6).

The aim of the different forms of therapy is to break through the increased tonic activity of sympathal nervous system and to remove the spasm of the sphincter muscle. This can be achieved by anal stretch under general anaesthesia rather than by conservative treatment. It was proved in randomized studies (8) that postoperatively measured rest pressure values were significantly lower after anal stretch than after lateral sphincterotomy. This effect even lasted for 4 months. The most successful procedure should be sphincterotomy, because the vicious circle is interrupted by this measure (6). Although in our series patients were not quite as often relieved from their symptoms, we found fewer relapsing cases in the follow up. However sphincterotomy bears the risk of irreversible damage to the sphincter organ, especially under the aspect that continence is built up through a rather complex system (12). Closure of the anal canal is due to a complex regulation of different mechanisms (13). The lack of only one of these different acting parts may lead to incontinence as it can not be compensated by other mechanisms. Goligher (2) found an occasional smear on the underclothing in 28% of cases, the leakage of flatus in 24% and a faecal incontinence in 11% of cases after sphincterotomy. In our series we found a smaller number of incontinence symptoms only. However we consider incontinence as such a burden for the patients that we prefer anal atretch as the method of first choice in our regimen. Fortunately we did not find a case of incontinence after this form of treatment up to now. It is less stress to the patient and offers almost as good results as sphincterotomy. In cases of relapse we then would perform lateral sphincterotomy.

### Literature

1. Götze, K. J., Mohr, T.: Zur Pathogenese der Analfissur. *Dtsch. Gesundh.-Wes.* 64, 275, 1976.
2. Goligher, J. C.: An evaluation of internal sphincterotomy and simple sphincter-stretching in treatment of fissure-in-ano. *Surg. Clin. N. Am.* 45, 1299, 1965.
3. Goligher, J. C.: *Surgery of the anus, rectum and colon.* 4. Aufl. 1984, Bailliere Tindall, London.
4. Gough, M. J., Lewis, A.: The conservative treatment of fissure-in-ano. *Br. J. Surg.* 70, 175, 1983.
5. Hansen, H., Stelzner, F.: *Proktologie.* 1. Aufl. 1981, Springer, Berlin.
6. Jostardt, L., Nitsche, D., Löhnert, M., Albers, U., Hammelmann, H.: Funktionelle Pathomechanismen der Analfissur. *Langenbecks Arch. Chir.* 368, 97, 1986.
7. Marti, M. C.: Die Analfissuren. *Swiss. Med.* 7, 30, 1985.
8. Olsen, J., Mortensen, P. E., Krogh Petersen, I., Christiansen, J.: Anal sphincter function after treatment of fissure-in-ano by lateral subcutaneous sphincterotomy versus anal dilatation. *Int. J. Colorect. Dis.* 2, 255, 1987.
9. Parks, A. G.: The management of fissure-in-ano. *Hosp. med.* 1, 737, 1967.

10. Stelzner, F.: Über die Anatomie des analen Sphinkterorgans, wie sie der Chirurg sieht. *Z. Anat. Entwickl. Gesch.* **121**, 525, 1960.
11. Stelzner, F.: Die Hämorrhoiden und andere Erkrankungen des Corpus cavernosus recti und des Analkanals. *DMW* **88**: 689, 1963.
12. Stelzner, F.: Kontinenz, Superkontinenz und Inkontinenz im Anorektalbereich. *DMW* **90**, 2275, 1965.
13. Stelzner, F.: Einige Fortschritte auf dem Gebiet der ano-rektalen Chirurgie. *Chirurg* **41**, 155, 1970.
14. Stelzner, F.: Sphinkter ani internus der Mittelpunkt des Kontinenzorgans. *Zbl. Chir.* **100**, 65, 1975.