

---

臨 床

---

## Study on Cases of Traumatic Subarachnoid Hemorrhage

SHIN-ICHI OTSUKA, SHOJI NAKATSU, SHIN-ICHI SATO, TAKAHIKO MOTOZAKI,  
SADAHIKO BAN, TOYOSHIRO YAMAMOTO, TARO FUKUMITSU\*,  
SATOSHI NAKAO\*\*

Department of Neurosurgery, Kobe City General Hospital

\*Department of Neurosurgery, Yoshida Hospital

\*\*Department of Neurosurgery, Kishiwada City Hospital

### Abstract

Fifty eight cases presented with traumatic subarachnoid hemorrhage on CT were studied. They were classified into two groups, Group A: twenty one patients with subarachnoid hemorrhage alone, Group B: thirty seven patients with subarachnoid hemorrhage and other intracranial lesions. With regard to the level of consciousness on admission, there were more numerous patients with impaired consciousness in Group B. There was no significant difference in the frequency of accompanying skull fracture between Group A and Group B. Brain contusion and associated intracerebral hematoma most frequently accompanied subarachnoid hemorrhage in Group B. With regard to the outcome of these cases, there were many dead cases and the prognosis was poor in Group B. In Group A, there were many cases classified as good recovery and the prognosis was relatively good. In the cases with mild subarachnoid hemorrhage limited to the cortical sulci, interhemispheric fissure and sylvian fissure in Group A, the prognosis was good even if the level of consciousness was poor on admission.

### Introduction

The recent advent of CT has made it easy to diagnose intracranial lesions in cases of head injury and also permits easy visualization of the site and degree of traumatic subarachnoid hemorrhage. Previously, traumatic subarachnoid hemorrhage was considered to be poor in prognosis as a sign indicative of primary brain stem injury. However, few clinical studies on it have been reported. Actually, the clinical symptoms in cases of traumatic subarachnoid hemorrhage varied from mild to severe and the prognosis of all cases is not always poor. In the present study, we investigated the level of consciousness on admission, CT findings and prognosis in cases of traumatic subarachnoid hemorrhage diagnosed with CT.

---

Key words: Traumatic subarachnoid hemorrhage Head injury Computerized tomography.

索引語: 外傷性くも膜下出血, 頭部外傷, コンピューター断層撮影.

Present address: Department of Neurosurgery Kobe City General Hospital 4-6 Nakamachi, Minatojima, Chuo-ku, Kobe Japan 650.

### Subjects and Methods

Of 684 patients with head injury who were admitted to our hospital during the period of January 1981 to August 1985, CT demonstrated intracranial lesions due to trauma in 472 patients. Of them, 58 patients presented with traumatic subarachnoid hemorrhage. They were classified into 21 patients (4.4% of the 472 patients, referred to as Group A) with subarachnoid hemorrhage alone and 37 (7.8% of the 472 patients, referred to as Group B) with subarachnoid hemorrhage and other intracranial lesions, such as subdural hematoma and brain contusion. We investigated the age, sex, level of consciousness on admission, and the presence or absence of skull fracture and the prognosis in Group A and Group B, and the site of subarachnoid hemorrhage and prognosis in Group A. For the assessment of the level of consciousness on admission, the Glasgow Coma Scale (GCS) was used and for the assessment of prognosis on discharge, the Glasgow Outcome Scale (GOS) was used.

### Results

#### 1. Age and sex

The age and sex of patients in Group A and Group B are shown in Fig. 1. Of 21 patients in Group A, 13 were males and 8 were females: males outnumbered females about 3 to 2. They ranged in age from 4 to 84 years, with a mean of 32 years. Of 37 patients in Group B, 34 were males and 3 were females: males overwhelmingly outnumbered females about 11 to 1. They ranged in age from 2 to 78 years, with a mean of 42 years. There was no significant difference in age distribution between Group A and Group B.

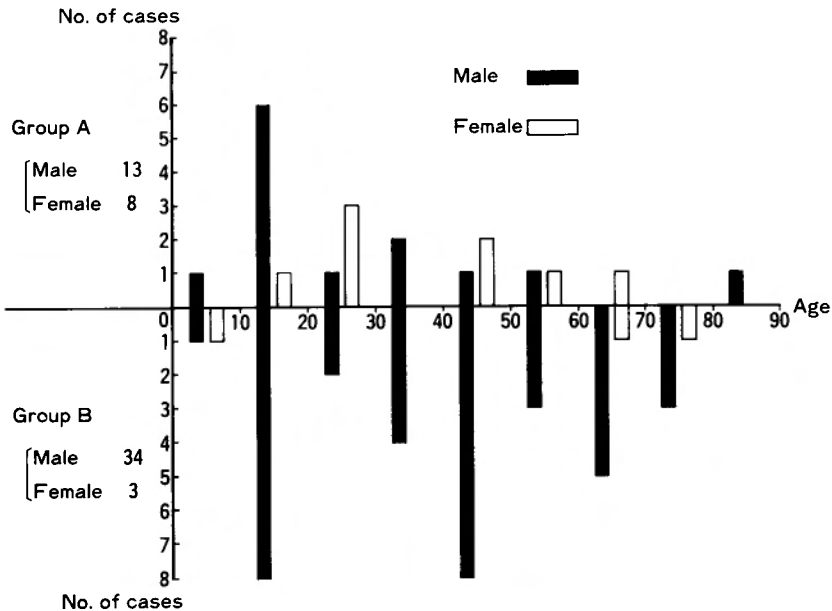


Fig. 1 Age and sex distribution in Group A and Group B

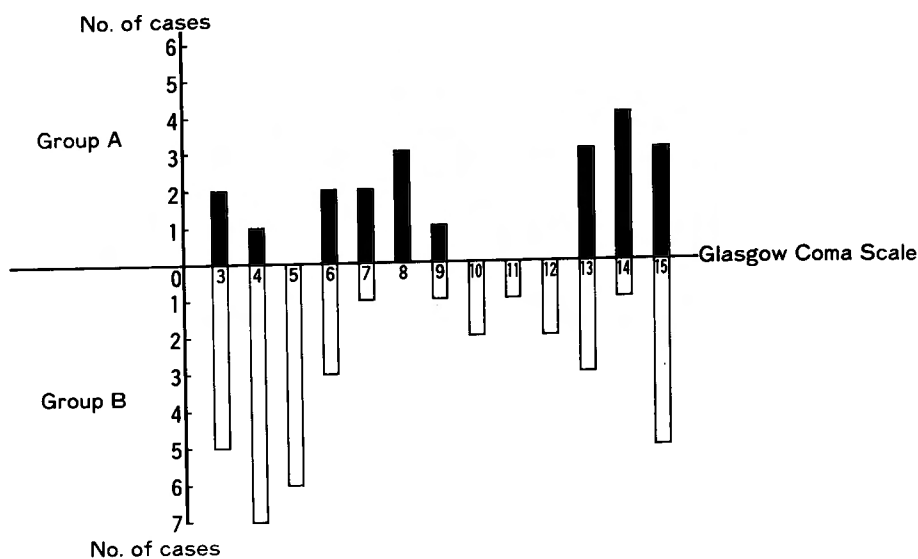


Fig. 2 Glasgow coma scale on admission in Group A and Group B

## 2. Level of consciousness on admission

Fig. 2 shows the level of consciousness on admission based on the GCS. The GCS was 8 or less in 10 patients (47.6%) of Group A and 22 (59.5%) of Group B. There were significantly numerous patients whose GCS was 8 or less in Group B ( $P < 0.05$ ).

## 3. Accompanying skull fracture

With regard to skull fracture, as shown in Table 1, in Group A, a linear fracture of the calvaria was found in 11 cases (52.4%), a basal skull fracture in 1 (4.8%) and no fracture in 10 (47.6%). In Group B, a linear fracture of the calvaria was found in 26 cases (70.3%), a basal skull fracture in 3 (8.1%) and no fracture in 9 (24.3%). There was no significant difference in the frequency of skull fracture between Group A and Group B.

## 4. Concurrent intracranial lesions

Other intracranial lesions accompanying subarachnoid hemorrhage in Group B are listed in Table 2. The most frequently accompanying lesion was brain contusion and associated intracerebral hematoma, being found in 16 cases (43.3%). The next most frequently accompanying lesion was subdural hematoma (9 cases, 24.3%), followed by subdural hematoma plus brain contusion (5 cases, 13.5%), epidural hematoma (3 cases, 8.1%), intraventricular hemorrhage (2 cases, 5.4%) and intraventricular hemorrhage plus brain contusion (2 cases, 5.4%).

Table 1 Frequency of skull fracture in Group A and Group B

	Group A	Group B
Linear fracture of calvaria	11 (52.4%)	26 (70.3%)
Skull base fracture	1 (4.8%)	3 (8.1%)
Fracture (-)	10 (47.6%)	9 (24.3%)

**Table 2** Type and frequency of intracranial lesions accompanying subarachnoid hemorrhage in Group B

		No. of cases
1	Contusion	16 (43.3%)
2	Subdural hematoma	9 (24.3%)
3	Subdural hematoma+contusion	5 (13.5%)
4	Epidural hematoma	3 (8.1%)
5	Intraventricular hemorrhage	2 (5.4%)
6	Intraventricular hemorrhage+contusion	2 (5.4%)

### 5. Outcome

Table 3 shows the outcome of the cases according to the GOS on discharge. In Group A, 3 cases (14.3%) were classified as "death", 0 as "vegetative state", 0 as "severe disability", 4 (19.0%) as "moderate disability" and 14 (66.7%) as "good recovery", the prognosis being relatively good. In Group B, 16 cases (43.3%) were classified as "death", 2 (5.4%) as "vegetative state", 5 (13.5%) as "severe disability", 7 (18.9%) as "moderate disability" and 7 (18.9%) as "good recovery". Comparing Group A and Group B, there were significantly more cases classified as "death" in Group B ( $P < 0.05$ ) and there were significantly more cases classified as "good recovery" in Group A ( $P < 0.01$ ).

### 6. Site of subarachnoid hemorrhage, level of consciousness on admission and prognosis

Table 4 shows the site of subarachnoid hemorrhage, level of consciousness on admission and prognosis in Group A. All of the three patients that died showed a very extensive subarachnoid hemorrhage from the basal cistern to the cortical sulci and had also acute brain swelling. Clinical neurological signs also indicated severe primary brain stem injury. In these cases, consciousness was severely disturbed on admission, the GCS being 3 or 4. Out of 4 cases rated as "moderate disability", 2 showed subarachnoid hemorrhage only in the cortical sulci and another 2 showed subarachnoid hemorrhage also in the basal cistern. In these cases, abducens palsy, oculomotor palsy, equilibrium disturbance remained. In cases with good recovery, the GCS on admission varied from 6 to 15. Subarachnoid hemorrhage was mild and confined to cortical sulci, sylvian fissure, interhemispheric fissure in 10 (71.4%) of the 14 cases. In the remaining 4 cases, subarachnoid hemorrhage was also detected in the basal cistern.

**Table 3** Glasgow outcome scale on discharge in Group A and Group B

	Group A	Group B
Death	3 (14.3%)	16 (43.3%)
Vegetative state	0	2 (5.4%)
Severe disability	0	5 (13.5%)
Moderate disability	4 (19.0%)	7 (18.9%)
Good recovery	14 (66.7%)	7 (18.9%)

**Table 4** Site of subarachnoid hemorrhage, level of consciousness on admission and outcome in Group A

	Interhemispheric, Sylvian fissure, Cortical sulci	Suprasellar cistern	Ambient, Quadrigeminal cistern	Prepontine, Interpeduncular cistern	GCS	GOS
1	+	+	+	+	4	D
2	+	+	+	+	3	D
3	+		+	+	3	D
4	+				8	MD
5		+	+		14	MD
6	+		+		13	MD
7	+				15	MD
8	+	+	+		13	G
9	+	+	+		15	G
10	+	+			9	G
11		+	+		6	G
12	+				6	G
13	+				7	G
14	+				7	G
15	+				8	G
16	+				8	G
17	+				13	G
18	+				14	G
19	+				14	G
20	+				14	G
21	+				15	G

D: Death MD: Moderate disability G: Good recovery

### Discussion

CT has enabled us to easily make a diagnosis of traumatic subarachnoid hemorrhage. However, few clinical studies on traumatic subarachnoid hemorrhage have been reported. Previously, traumatic subarachnoid hemorrhage was considered to be a sign of primary brain stem injury with poor prognosis. However, it varies in severity from so severe as to lead to death immediately after injury to so mild as to present no neurological abnormalities. Mori et al. (3) reported that in cases in which CT performed soon after injury showed subarachnoid hemorrhage in the basal cistern, brain stem injury existed and the prognosis was poor. Saito et al. (4) classified cases of diffuse brain injury into five types according to CT findings and they described that the Glasgow Outcome Scale at 6 months after injury in 7 cases presenting subarachnoid hemorrhage only was "death" in 1 case, "moderate disability" in 1, and "good recovery" in 5. They reported that possibly because there were many cases of relatively mild subarachnoid hemorrhage confined to the surrounding area of the brain stem, the prognosis was not always poor. Hayashi et al. (1) classified cases of subarachnoid hemorrhage into three types according to CT findings. Among them, 4 of 5 patients who showed diffuse subarachnoid hemorrhage extending over the cisterns surrounding the brain stem, sylvian fissures, inter-

hemispheric fissure and cortical sulci had poor prognosis, resulting in death. Out of 7 patients with subarachnoid hemorrhage in the cisterns around the brain stem, such as ambient cistern and quadrigeminal cistern, three died, one was in the vegetative state and one was severely disabled. On the other hand, with regard to cases of subarachnoid hemorrhage detected only in supratentorial subarachnoid spaces such as sylvian fissure, interhemispheric fissure and cortical sulci, out of 10 cases, 7 were rated as "good recovery", 2 as "moderate disability" and 1 as "severe disability". They reported that even in patients who had been in the poor state of consciousness on admission, the prognosis was good. When our present cases of traumatic subarachnoid hemorrhage were classified according to CT findings into cases with subarachnoid hemorrhage alone (Group A) and cases with subarachnoid hemorrhage and other intracranial lesions, such as subdural hematoma and brain contusion (Group B), Group B had more severely impaired consciousness on admission and worse prognosis with a greater number of deaths than Group A. It was considered that in Group B patients, various types of intracranial lesions influenced clinical symptoms, course and prognosis. On the other hand, in Group A patients, three who died developed extensive subarachnoid hemorrhage and brain swelling and according to the clinical symptoms, primary brain stem injury was suspected. Out of 14 patients with good recovery, 10 had relatively mild subarachnoid hemorrhage limited to the cortical sulci, interhemispheric fissure and sylvian fissure. In these cases, the GCS on admission varied from 6 to 15 but in all cases the prognosis was good. It was thus considered that in such cases, even if the level of consciousness was poor on admission, the prognosis was good.

The possible mechanism of traumatic subarachnoid hemorrhage is that shear strain caused by a powerful external force caused hemorrhage from the vessels on the surface of brain stem (2). Tatsuno et al. (7) investigated 34 autopsied cases of basal subarachnoid hematoma due to trauma and reported that in 14 cases tears were found in the arteries at the base of the brain. They cited three mechanisms by which blows on the face and neck caused tears in these arteries: [1] short-term oscillation of the brain is produced by a rotational acceleration of the head; [2] the vertebro-basilar system is stretched by hyperextension of the head; [3] as a result of a blow to the carotid artery in the neck, intraarterial pressure is highly elevated transiently. Traumatic arterial tears occur not only at the base of the brain but also at the convexity and particularly, superficial parietal and temporal branches of the middle cerebral artery are vulnerable to injury (7). It has been also reported that even in minor head injury fatal subarachnoid hemorrhage may occur, particularly in alcohol-intoxicated persons. Acute alcoholic intoxication increases the risk of such hemorrhage, primarily due to the dilatation of the cerebral vessels and to a lesser extent, due to less appropriate avoiding reactions and the heavier falling of intoxicated persons (5). Takizawa et al. (6) reported that in many of patients presenting with subarachnoid hemorrhage in the unilateral ambient cistern or quadrigeminal cistern, the fronto-temporal region, i.e. the side opposite to hemorrhage was struck and assumed that an impact on the head might damage the brain tissue or small vessels on the surface of the mesencephalic tegmentum at the tentorial incisura on the diagonal line, resulting in subarachnoid hemorrhage in the same area.

There have been few clinical reports on traumatic subarachnoid hemorrhage. In our

present study, so far as cases presenting with subarachnoid hemorrhage alone on CT, the prognosis was relatively good. Therefore, it should not be decided immediately that in cases of traumatic subarachnoid hemorrhage, primary brain stem injury exists, indicating a poor prognosis. The prognosis of these cases should be determined based on neurological findings, the location and severity of subarachnoid hemorrhage on CT, and objective findings on brain stem function such as auditory brain stem response.

#### References

- 1) Hayashi T, Yoshida Y, Amou M, et al: Pathological state of traumatic subarachnoid hemorrhage. Proceeding of the 13th General Meeting of the Japanese Association for Acute Medicine 233, 1985.
- 2) Kobayashi S: Classification of computerized tomography and prognosis of traumatic primary brain stem injury. *Neurol Med Chir* **22**: 838-848, 1982.
- 3) Mori, N, Sugiura M, Yamamoto M, et al: CT findings of basal cistern in head trauma. *Neurotraumatology* **3**: 154, 1981.
- 4) Saito A, Kuwana N, Mochimatsu Y, et al: Relationship between CT findings and prognosis in diffuse brain injury. *Neurol Med Chir* **24**: 946-953, 1984.
- 5) Simonsen J: Fatal subarachnoid haemorrhage in relation to minor head injuries. *J Forensic Med* **14**: 146-155, 1967.
- 6) Takizawa T, Matsumoto A, Sato S, et al: Traumatic subarachnoid hemorrhage. *Neurol Med Chir* **24**: 390-395, 1984.
- 7) Tatsuno Y, Lindenber R: Basal subarachnoid hematomas as sole intracranial traumatic lesions. *Arch Pathol* **97**: 211-215, 1974.

## 和文抄録

## 外傷性くも膜下出血症例の検討

神戸市立中央市民病院脳神経外科

大塚 信一, 中津 正二, 佐藤 慎一, 本崎 孝彦  
伴 貞彦, 山本 豊城

吉田病院脳神経外科

福 光 太 郎

岸和田市民病院脳神経外科

中 尾 哲

CTにて外傷性くも膜下出血の認められた58例について検討した。58例のうちくも膜下出血のみの症例（A群）は21例、他の頭蓋内病変を合併した症例（B群）は37例であった。年齢はA群では4～84歳、平均32歳、B群では2～72歳、平均42歳で、性別はA群では男13例、女8例、B群では男34例、女3例で圧倒的に男が多かった。B群における合併頭蓋内病変で最も多かったのは、脳挫傷およびこれに伴う脳内血腫であった。搬入時の意識レベルを Glasgow coma scale (GCS) でみてみると、8以下の症例はA群で10例(47.6%)、B群で22例(59.5%)であり、B群で意識レベルの悪い症例が多かった。これらの症例の退院時の

Glasgow outcome scale は、A群では death 3例(14.3%)、moderate disability 4例(19.0%)、good recovery 14例(66.7%)で予後は比較的良好であった。B群では death 16例(43.3%)、vegetative state 2例(5.4%)、severe disability 5例(13.5%)、moderate disability 7例(18.9%)、good recovery 7例(18.9%)で死亡例が多く予後は不良であった。今回検討した症例から判断すると、CT上くも膜下出血のみで他の頭蓋内病変が認められない例では、くも膜下出血が広範でなく、著明な brain swelling が伴わなければその予後は良好であると考えられた。