
症 例

Tricuspid Endocarditis Complicating Transvenous Permanent Pacemaker Implantation

TOMOHIKO MURAGUCHI, KATSUJI SAKAI, NORIHIKO USUI, YASUHIKO TSUKAMOTO,
EJI KIMURA, and KEIJIROU NISHIZAWA, *KAZUhide TAKEUCHI and *HISAO OKU

The Second Department of Surgery and *First Department of Internal Medicine,
Osaka City University School of Medicine, Osaka, Japan

Received for Publication, Aug. 5, 1988.

Summary

A 21-year-old man, who had received a transvenous pacemaker because of sick-sinus syndrome 4 years before, was admitted to our hospital for sustained fever and general fatigue. *Staphylococcus epidermidis* was isolated from his blood culture, and vegetation on the tricuspid valve was disclosed by two-dimensional echocardiography. After intensive chemotherapy, he was successfully treated by the complete removal of the pacemaker unit and the infected valve under cardio-pulmonary bypass. There were no major postoperative complications and the patient has been doing well at this writing with no evidence of recurrent endocarditis.

Introduction

Pacemakers are now well recognized as a safe and effective treatment of heart block and arrhythmia, and are being extensively used in clinical practice. Complications are becoming more infrequent with improvements in surgical technique and pacemaker technology, and are usually amenable to treatment when they do occur. Among these complications, however, endocarditis remains difficult to manage, and is thus a major problem despite its relative rarity.

Herein, we report on a case with tricuspid endocarditis complicating the presence of transvenous permanent pacemaker, who was successfully treated by the complete removal of the pacemaker unit and the infected valve under cardio-pulmonary bypass.

Case Report

A 21-year-old man, who had received a transvenous permanent pacemaker (AV flex, model 400, DDD, Cook Pacemaker Inc.) for sick-sinus syndrome at another hospital in 1984, was admitted to our hospital on February 22, 1988, because of sustained fever and general fatigue. He had a history of receiving antibiotics from his family physician for the same symptoms, and

Key words: Transvenous permanent pacemaker, Tricuspid endocarditis, Cardio-pulmonary bypass.

索引語: 経静脈的恒久的ペースメーカー, 心内膜炎, 人工心肺.

Present address: 1-5-7, Asahi-machi, Abeno-ku, Osaka City, Japan.

had experienced swelling at the generator pocket 6 months prior to admission.

On admission, his blood pressure was 120/70 mmHg, and heart rate was 72/min and regular. Physical examination revealed no source of infection. No heart murmur was audible, and the generator pocket appeared to be unremarkable. Laboratory results revealed marked leukocytosis of $21000/\text{mm}^3$; the erythrocyte sedimentation rate and c-reactive protein level were 10 mm/hr and 8.2 mg/dl, respectively. Liver and renal function were normal. *Staphylococcus epidermidis* was isolated from blood cultures. The chest X-ray revealed no cardiomegaly or congestion (Fig. 1). Two-dimensional echocardiography disclosed vegetation on the thickened tricuspid valve; Doppler image detected grade 1 tricuspid regurgitation (Fig. 2). On this basis, we diagnosed tricuspid endocarditis complicating the presence of pacemaker. We then began intensive chemotherapy with cefmetazole, and subsequently with a combination of fosfomycin and minocycline to which the microorganism was sensitive. Blood cultures eventually proved

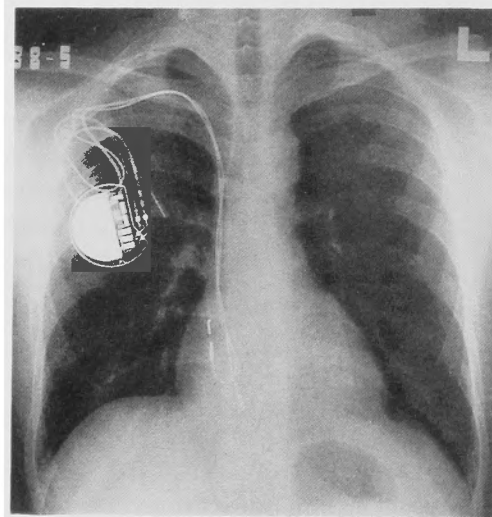


Fig. 1. Chest X-ray film, revealing no cardiomegaly or congestion. The atrial and ventricular electrodes are identified.

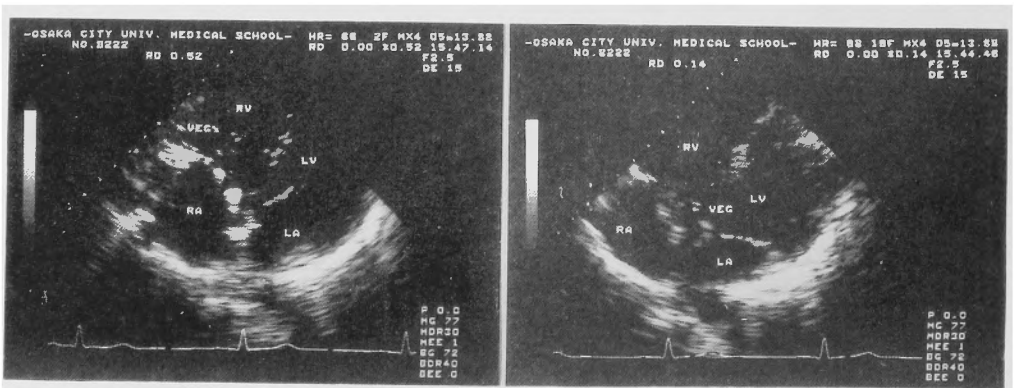


Fig. 2. Two-dimensional echocardiograms, demonstrating vegetation on the thickened tricuspid valve.

sterile, and the leukocyte count and c-reactive protein improved during therapy, but low-grade fever persisted. Because of the sustained fever and intracardiac vegetation, complete removal of the pacemaker unit and the infected tissue was considered necessary.

Holter electrocardiography, with the pacemaker reset into VVI mode and using a pacing rate of 30/min, showed regular sinus rhythm with a minimal heart rate of 59/min and no pacing rhythms, suggesting no need for pacemaker re-implantation.

On May 17, 1988, a median sternotomy was made and cardio-pulmonary bypass was established. The atrial electrode was embedded into the right atrial appendage. The ventricular electrode passed through the commissure between the posterior and septal leaflets of the tricuspid valve and was attached to the infero-posterior wall of the ventricular septum. Vegetation extended along the electrodes from the entrance of superior vena cava into the right atrium to the posterior and a small part of the septal leaflet. We then cut these electrodes just below the entrance of the superior vena cava, and removed them without difficulty using careful traction after cutting the fibrous tissue tightly surrounding the tips. All visible vegetation, and the posterior and a small part of septal leaflet were excised away; the defect of the tricuspid valve was repaired by Kay's annuloplasty (Fig. 3). The residual electrodes were removed carefully by subclavian venotomy with the generator.

After surgery, the patient received intravenous cefmetazole for 2 weeks as well as oral

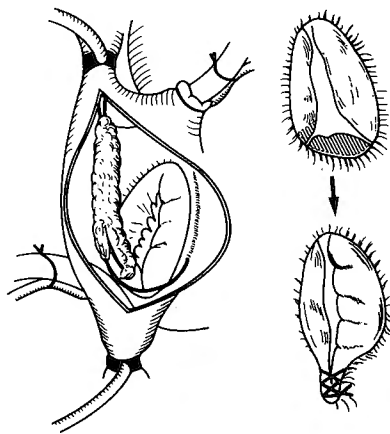
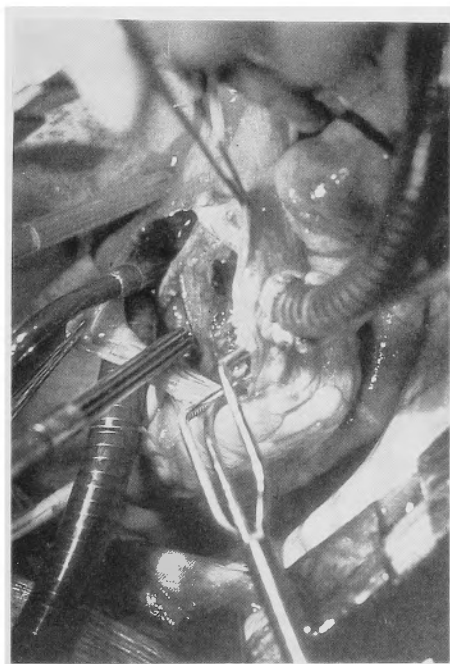


Fig. 3. Photo and schema of the operation. Vegetation extended along the electrodes from the entrance of superior vena cava into the right atrium to the posterior and a small part of the septal leaflet of tricuspid valve. After removal of the electrodes, vegetation and infected valve, the defect of the tricuspid valve was repaired by Kay's annuloplasty to reduce the diameter of the ring to 30 mm.

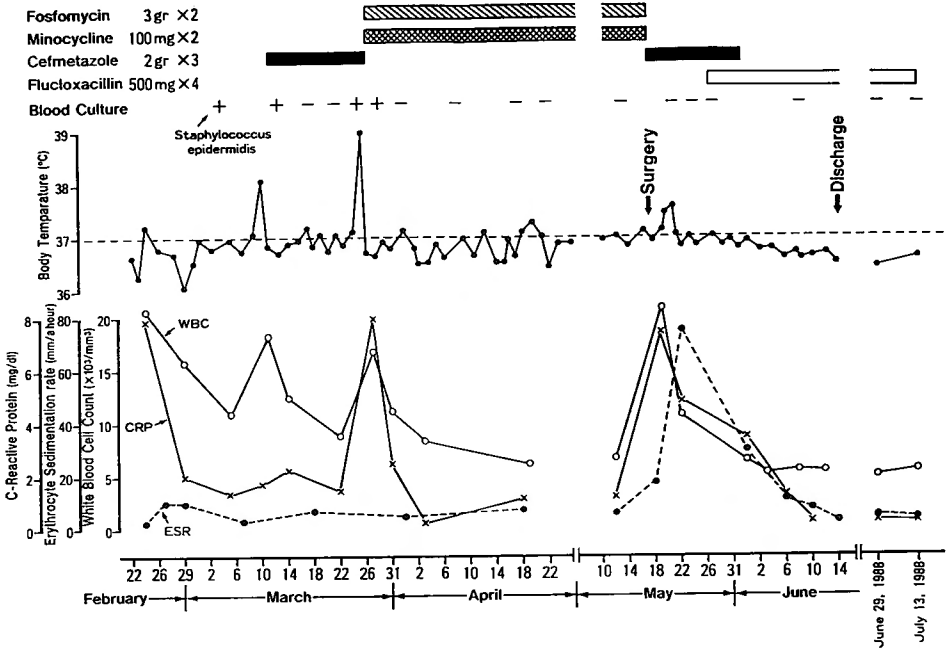


Fig. 4. The clinical course of this patient before and after operation.

Flucloxacillin for 8 weeks. There were no complications and blood cultures remained sterile. Echocardiography after surgery revealed no tricuspid stenosis or regurgitation; vegetation completely disappeared. On the 30th day after surgery, he was discharged in good health, and has been doing well at this writing with no evidence of recurrent endocarditis. The clinical course of this patient is depicted in Fig. 4.

Discussion

Endocarditis as a complication of transvenous pacemaker implantation is rare, the reported incidence being 0.2–6.6%^{9,11,14}. Few cases have been reported by physicians so far^{4,13,16}. However, this is one of the most difficult problems to manage and can be life-threatening once initiated. The tricuspid valve is the most commonly affected site, because of the usual use of right ventricle for pacing¹⁹. Vegetation and thrombi on the infected valve may escape, possibly causing a pulmonary embolism or abscess^{18,19}. Pacemaker dysfunction and ventricular perforation related to endocarditis have also been described^{3,13,17}. The overall mortality of the lesion remains 30–50% even now¹⁷.

With respect to pathogenesis, there are two different clinical types of the lesion³. Infections involving the pacemaker unit usually start at the generator pocket, probably from contamination during surgery or by direct spread from infection of the eroded or necrotized skin (foreign-body type). The overall incidence of local infection was reported to be 5.1 percent in 1376 implantations by Grögler et al., in which 3.2 percent were generator infections and 1.9 percent

were infections of the electrode⁷. And the incidence increases with each reimplantation, according to the literatures^{1,11}. The generator infections tend to occur soon after implantation (within 2 months), while electrode infections tend to occur later¹¹. Staphylococci are the most frequent pathogen in this type of endocarditis, where *Staphylococcus aureus* is commonly seen in early infections and *Staphylococcus epidermidis* in late ones^{4,8}. *Klebsiella*, and rarely *Echerichia coli*, *Candida albicans*, *Flabobacterium* and *Enterobacteriaceae* have been isolated from the patients as well^{1,4}. Our case is probably of this type, because of the history of swelling at the generator pocket and of the lack of any remarkable remote source of infection.

The other variety, although more rarely encountered, is the so-called "metastatic implantation" type, in which the microorganism from the remote source of infection extends into the bloodstream and accidentally implants on the section of the endocardium abraded by the electrode. The pathogen, when isolated, can come from a diverse range of microorganisms and this make this type considerably more lethal⁹.

With regard to the management, Zeller et al. in 1975 emphasized a trial of intensive chemotherapy²⁰, while Chavez et al. in 1977 and Bryan et al. in 1978 suggested the need for the early and complete removal of the pacemaker unit^{3,4}. There are, however, no known standardized regimens for management, because of the rarity of the lesion.

Infection at the generator pocket may be controlled with adequate antibiotic therapy and drainage before the development of bacteremia. However, such a "conservative" therapy is successful only in cases of infection with *Staphylococcus epidermidis*, according to Jara et al¹⁰. Other workers have also reported unsuccessful "conservative" therapies for this infection^{1,6}. It is generally recognized that the virulence of the microorganism is enhanced and the eradication of the infection is delayed in the presence of a foreign body. Moreover, the infection has a great potential for becoming life-threatening¹¹. An early removal of the foreign body and its replacement in another location is, therefore, thought to be mandatory when "conservative" therapy is not wholly effective; the electrode should be cut at its entrance into the vein if cannot be removed with traction⁴. Especially in patients developing bacteremia, prolonged "conservative" therapy actually yields a poor result and considerable mortality in spite of a few recorded success^{3,13}. Several cases of recurrent endocarditis after this therapy have been also described¹⁶. In such cases, only a complete removal of the pacemaker unit offers a chance for survival^{1,11}.

The electrode may be easily withdrawn by simple or steady traction on the distal tip. But in some cases, when the tip of the electrode is entrapped too tightly by the fibrous tissue around it, removal by forcible traction may disrupt the endocardium, causing the formation of an atrio-venous fistula, avulsion of the tricuspid valve, ventricular tachycardia, and syncope^{1,2}. A more aggressive approach such as cardiomy under cardio-pulmonary bypass must be employed, as recommended by Chavez et al. in 1977⁴. Cases with intra-cardiac vegetation and/or thrombus, as in our case, will also require cardio-pulmonary bypass in order to keep these bodies from escaping, and to remove the intra-cardiac foreign body and the infected tissue accurately and safely^{3,15,19}. Replacing the electrode on the epicardium will provide the best pacing in this contingency.

Our experience of this case impressed us with the importance of the early removal of the foreign body to eradicate this potentially life-threatening condition. To prevent this complication, the greatest care must be taken to reduce the incidence of infection at the generator pocket. This includes more precautions to insure sterility, complete hemostasis, and the prophylactic use of antibiotics¹⁾. Reimplantation of the generator after the complete excision of the fibrous scar tissue is also recommended¹⁾.

Finally, two-dimensional echocardiography should be available for detecting vegetation or thrombi even in right chamber of the heart^{5,19)}.

References

- 1) Beeler BA: Infections of permanent transvenous and epicardial pacemakers in adult. *Heart and Lung* 11: 152-155, 1982.
- 2) Bluhm G, Julander I, Levander-Lindgren ML, et al: Septicaemia and endocarditis-uncommon but serious complication in connection with permanent cardiac pacing. *Scand J Thorac Cardiovasc Surg* 16: 65-70, 1982.
- 3) Bryan CS, Sutton JP, Sanders DE, et al: Endocarditis related to transvenous pacemakers. *J Thorac Cardiovasc Surg* 75: 758-762, 1978.
- 4) Chavez CM and Conn JH: Septicemia secondary to impacted infected pacemaker wire. *J Thorac Cardiovasc Surg* 73: 796-800, 1977.
- 5) Daelemans R, Kersschot I, Branden FVD, et al: Case reports-pacemaker endocarditis: contribution of two-dimensional echocardiography. *Acta Cardiol* 39: 293-299, 1984.
- 6) Furman S: Cardiac pacing and pacemakers. *Am Heart J* 94: 378-386, 1977.
- 7) Grogler FM, Frank G, Greven G, et al: Complications of permanent transvenous cardiac pacing. *J Thorac Cardiovasc Surg* 69: 895-904, 1975.
- 8) Hartstein AI, Jackson J and Gilbert DN: Prophylactic antibiotics and the insertion of permanent transvenous cardiac pacemakers. *J Thorac Cardiovasc Surg* 75: 219-223, 1978.
- 9) Imparato AM and Kim GE: Electrode complications in patients with permanent cardiac pacemakers. *Arch Surg* 105: 705-710, 1972.
- 10) Jara FM, Toledo-Pereyra L, Lewis JW Jr, et al: The infected pacemaker pocket. *J Thorac Cardiovasc Surg* 78: 298-300, 1979.
- 11) Kennelly BW and Piller LW: Management of infected transvenous permanent pacemakers. *Brit Heart J* 36: 1133-1140, 1974.
- 12) Lee ME, Chaux A, Matloff JM, et al: Avulsion of a tricuspid valve leaflet during traction on an infected entrapped endocardial pacemaker electrode. *J Thorac Cardiovasc Surg* 74: 433-435, 1977.
- 13) Lyons C: Sepsis and pacemaker malfunction. *Arch Intern Med* 142: 1931, 1982.
- 14) Morgan G, Gink W, Siddons H, et al: Septicemia in patients with endocardial pacemaker. *Amer J Cardiol* 44: 221-224, 1979.
- 15) Schwartz IS and Pervez N: Bacterial endocarditis associated with a permanent transvenous cardiac pacemaker. *JAMA* 218: 736-737, 1971.
- 16) Tylman CTA and Seaworth MB: Pacemaker-associated sepsis: successful medical management. *South Med J* 78: 1140-1141, 1985.
- 17) Umezawa S, Sugimoto K, Fujiwara H, et al: A case of pacing failure and undersensing due to fluid invasion into the pacemaker-electrode connection and bacterial endocarditis. *Heart* 15: 574-578, 1983. (in Japanese)
- 18) Waisser E, Kuo CS and Kalbins SA: Septic pulmonary emboli arising from a permanent transvenous cardiac pacemakers. *Chest* 61: 503-505, 1973.
- 19) Ward C, Naik DR and Johnstone MC: Tricuspid endocarditis complicating pacemaker implantation demonstrated by echocardiography. *Br J Radiol* 52: 501-509, 1979.
- 20) Zeller NH, Lusk RH, and Palmer DL: Nonsurgical cure of endocarditis associated with a pacemaker. *Arch Intern Med*: 135: 580-581, 1975.

和文抄録

Transvenous Permanent Pacemaker による感染性心内膜炎の一例

大阪市立大学 外科学第二教室

村口 和彦, 酒井 克治, 臼井 典彦, 塚本 泰彦

木村 英二, 西沢慶二郎

同 内科学第一教室

竹内 一秀, 奥 久雄

症例は22才, 男. 4年前に洞不全症候群の診断のもとに Pacemaker 植え込み術を受けた. 今回発熱及び全身倦怠感を主訴に来院. 血液培養で staphylococcus epidermidis が, 超音波断層法で三尖弁に付着した Vegetation が検出され, 感染性心内膜炎と診断した. 強力な化学療法により白血球数増多, CRP 値異常は改善したが微熱が持続したため, 完全体外循環下に Pacemaker unit, Vegetation および三尖弁後尖を除去

した. なお弁欠損部は弁輪形成術 (Kay 法) により修復した.

術後の経過は良好であり, 超音波断層法においても Vegetation は消失し, 三尖狭窄や閉鎖不全は認めなかった. また術後8週間化学療法を続行, 現在まで再発はない. 一治験例を報告し, 若干の文献的考察を加える.