
原 著

PATHOGENESIS AND TREATMENT OF RADICULAR SCIATICA

by

Prof. EISHI KONDO, Assistant Prof. KENGO YAMADA

From the Orthopedic Division, Kyoto University Medical School

and Prof. TETSUO ITO

From the Orthopedic Division, Yamaguchi medical College.

Since 1941, we have carried out systematic investigation upon the causes of intractable low back and sciatic pain and come to attach the main importance to the impinging factors on the nerve roots composing sciatic nerve.

Recently such great advances have been made especially in the development of operative treatment to remove the impinging factors on the nerve roots by means of laminectomy, that it is now time to evaluate these end-results.

The purpose of this paper is :

- 1) to crystallize the results of our experience with cases of sciatica,
- 2) to discuss these clinical and pathological findings in comparison with pathological findings in experimental disc lesions upon animals,
- 3) to examine statistically the end-results obtained by various forms of our operative treatment, and
- 4) to make some contributions to the determinations of indication for operative treatment by analysing the factors, which exert influences upon the results of our treatment.

The records of patients operated upon for radicular sciatic pain include 620 cases. In this series, intervertebral disc protrusions far outnumbered all other causes of sciatic pain; next came thickenings of the ligamentum flavum, then meningitis spinalis adhesiva and disc lesions without protrusion, and, in rare cases, spondylolysis and spondylolisthesis were causative factors (Table 1).

Table I.

	Cases	Per cent
Intervertebral disc protrusion	406	65.5
Thickenings of ligamentum flavum	68	10.9
Meningitis adhesiva	59	9.5
Disc lesion without protrusion	20	3.4
Spondylolysis	13	2.2
Spondylolisthesis	12	1.7
Others.	42	6.8
Total	620	100.0

Moreover, these affections are connected closely with each other in their clinical pictures as well as in the experimental evidences seen in the following chapters. Therefore, we have come to the opinion that they may belong to the same series

of affections centering around the disc lesions. And so here will be discussed mainly the intervertebral disc protrusions with special reference to their post-operative results, indications for operation and forms of treatment.

I. PATHOLOGY OF RADICULAR SCIATICA

For investigation of the causes of radicular sciatica, it is essential in the first place to clarify the statico-dynamic relations of the functional structures of the normal lumbar spine and to examine the pathologic states caused by rupture of their normal relations above mentioned, which exerts influences upon nervous elements in the spinal canal. In this paper the pathological findings in the human disc lesions have been discussed in comparison with the findings in the experimental disc lesions upon animals, which were caused by incision in the ventral part of the intervertebral disc.

§ 1. Statico-dynamic relations of the functional structures of the normal human lumbar spine and pathological changes in the spine caused by those disorders

The range and modus of movements of the normal human articulations were radiographically examined. The lower lumbar articulations, where disc lesions most commonly occur, have greater mobility than upper lumbar articulations.

The modus of its movements is characteristic as demonstrated in Fig. 1.

On flexion, the anterior part of the superior vertebral body falls downward, its posterior part rises upward and at the same time it slips on the whole slightly forward. On extension, the reverse movement occurs. Therefore, the superior vertebra performs simultaneously seesaw and piston movements on

flexion and extension, and the axis of those movements normally passes through a point slightly posterior to the disc center, at which point the nucleus pulposus is situated.

These studies reveal that intervertebral discs play a leading part in these movements, and the vertebral body performs movements correlated with the posterior part of the vertebra, including the spinal canal.

In our clinical cases of intervertebral disc lesions, especially in the disc protrusions, limited mobilities of the lumbar spine were commonly observed, and thickening of the related interlaminar ligaments (lig. flavum) were found in approximately 50 per cent of the cases, who had undergone laminectomy. And in these thickened interlaminar ligaments, pathological changes, such as rupture of the elastic fibres, blood vessel invasion and proliferation, hyaline degeneration and calcification of the connective tissues, were found in various degrees.

Also in our animal experiment, changes in the interlaminar ligaments analogous to those found in human beings were demonstrated after an adequate period of

Fig. 1

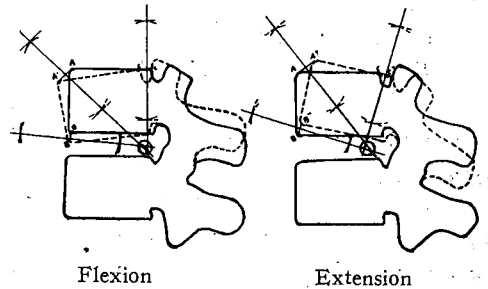
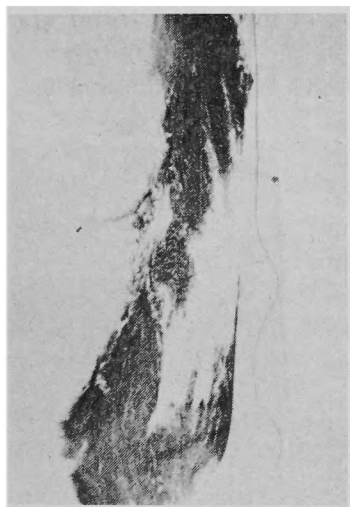
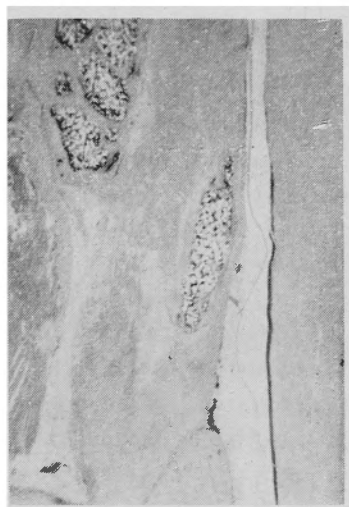

Fig. 2



Weigert's staining



Hematoxylin-eosin staining

Rupture of the elastic fibers and calcification in lig. flavum of a rabbit with experimental disc lesions (10 months after incision in the ventral part of the intervertebral disc).

observation (ca. 10 months)(Fig. 2).

When an incision was made in the ventral part of the intervertebral discs of rabbits, and in animals forced to stay on their hind limbs, the changes developed much earlier and more markedly than in those who were permitted to remain on four limbs.

Further, morphological examination of the specimens of human lumbar laminae, which were removed by means of our osteoplastic bilateral laminectomy with facetectomy for intervertebral disc protrusion, showed asymmetry of the posterior part of the vertebra in 80 per cent of the cases. This asymmetry tended to be greater in degree in the chronically developed cases, and was frequently accompanied by deformative changes in the articular facets.

These facts above mentioned suggest that disc lesions could cause incongruent movements of the spine, followed by degenerative changes in the interlaminal ligaments and the articular facets.

§ 2. Pathological changes in the spinal canal caused by disc lesions

It is not difficult to presume, that functional disorders of the spine due to disc lesions might affect some of the nervous elements included in the spinal canal.

a) Anatomical characteristics of the lumbar spinal canal.

Most of the anatomy of the spinal canal will not be described here. The following two points especially noteworthy that Nn. sinoverbrales (Lushka), which contain mostly afferent nerve fibers, are widely distributed in the spinal canal to the ligaments, articular capsules and dura, and that the blood and lymph vessels, which run along the nerve root through the intervertebral foramina, play a leading part in the circulation of fluid in the intra- and extra-dural spaces.

b) Experimental and clinical study of disc lesions.

In rabbits, operative incision in the ventral part of the intervertebral disc caused not only disc protrusion through the incised part of the annulus fibrosus, but also, in spite of no injury to the dorsal part of the annulus fibrosus, more or less inflammatory changes in the extradural tissues, such as wide spread edema, blood vessel engorgement, fibrin exudation and cellular infiltration (Fig. 3). These inflammatory changes developed more markedly in the rabbits forced to stay on their hind limbs than those kept on four limbs, and in case of retrotrusion of the disc they developed more markedly. The same experimental procedures performed in dogs showed, in addition, congestion of veins in the spinal canal or disturbance of out flow of the cerebrospinal fluid through the intercellular spaces in the dural sheath near the involved nerve root.

Review of our operative findings in the human disc lesions revealed that they were frequently associated with congestion in the extradural space, edema of the nerve root or the dura, and strong adhesions around the nerve root. Also similar findings could be demonstrated histologically in the adipose tissue in the spinal canal, where chronic inflammatory changes existed, such as edema, round cell infiltration, marked thickenings of the wall of the blood vessels and scar formation.

In the disc lesions with or without protrusion, extradural myelography demonstrated clear filling defects considered to be due to these extradural pathological changes. These experimental and clinical facts reveal that disc lesions, whether they are associated with protrusion or not, can cause extradural inflammatory changes and congestion, followed by adhesions between the nerve roots and the dura or the disc.

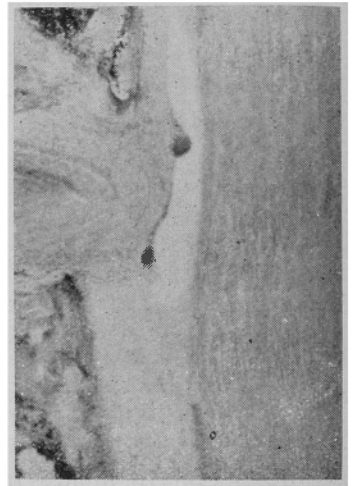It is well known that there is a structural weak point in the posterior part of the disc. This can also be proved by our experimental injuries to the spine performed on fresh cadavers, which proved that the posterior part of the annulus fibrosus was easily ruptured by a twisting force.

Moreover statistical investigations upon our cases with intervertebral disc protrusions revealed, that most of the cases had a definite history of acute injury following a twisting strain while lifting a heavy object, and a high percentage occurred at an age, when physiological disc degeneration had already advanced to some extent. Moreover, our histological examination of the specimens removed operatively from the protruded discs always showed some degenerative changes.

These facts above mentioned seemed to suggest close association of mechanical factors as a cause of intervertebral disc protrusion.

Also cinematographic analysis of the postures of skilled labourers at work revealed

Fig. 3



Inflammatory changes caused by experimental disc lesions.

that, while dealing with heavy weight, they fixed their lumbar spines as straight as possible, avoiding excessive lumbar bending, and this limited motion of lumbar spines was compensated by coordinated flexion of the lower limbs at knee and hip joints. These postures serve the purpose of protecting the intervertebral discs from injuries. Any-way, in the intervertebral protrusions, it is probable that lesions of the nervous elements in the spinal canal are caused the more intensely by mechanical compression on the nerve root due to the related intervertebral disc protrusion, which is followed by the extradural changes mentioned above. And it is not difficult to consider, that the lesions to the nerve roots, cauda equina, and Nn. sinovertebrales might produce various kinds of referred pain or reflexes, according to their anatomical distribution. Therefore, the neurological aspect of disc lesions may be confused by referred reflexes. This can also be proved by our clinical experiences of intervertebral disc lesions, especially of the intervertebral disc protrusions.

For these reasons, myelography may be required to determine the precise localization of the disc lesions. In our clinic, myelographic accuracy was found in 98.1 % for the cases with intervertebral disc protrusions, and also for disc lesions without protrusion extradural myelography gave good results, where routine myelography failed. So we cannot agree with the opinion, that routine neurologic diagnosis without myelography is sufficient for the determination of the location of the lesions.

As we have mentioned above, affections of nerve roots may be caused by intervertebral disc lesions, especially by the intervertebral disc protrusions. Our histolo-

Fig. 4




Fig. 5

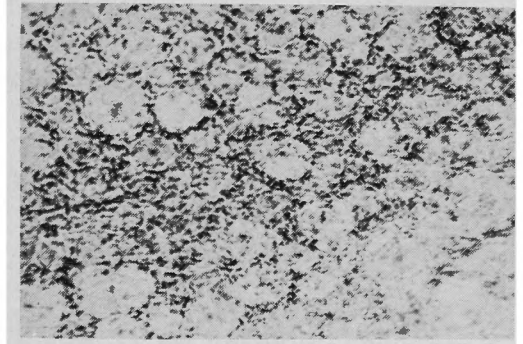
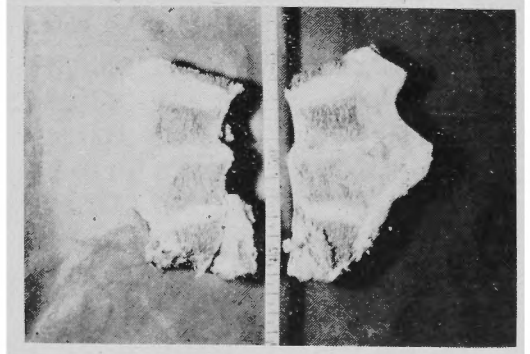


Fig. 6



gical examination of the nerve roots demonstrated radiculitis and ganglionitis as illustrated in Fig. 4 and Fig. 5. The former is a specimen obtained at autopsy from a case with the intervertebral disc lesion shown in Fig. 6, the latter is that from a rabbit with experimental intervertebral disc lesions.

It is thought that this radiculitis and ganglionitis may produce the typical clinical features of disc lesions, which

are also associated with the symptoms and signs produced by lesions of Nn. sinovertebrales.

II. THERAPY

§ 1. Summary of end-results

All records of patients operated upon for radicular sciatica were reviewed. This group included 620 patients, to whom letters as in Table II were sent, asking them to report the results of treatment. 410 patients (66.7%) have answered and 103 of them have been examined by ourselves.

The results were considered on the basis of two points: capacity for work and freedom from pain. The criteria for the evaluation of the results are as follows:

- 1) Cured: Freedom from low back and sciatic pain and no restriction of activities since original operation.
- 2) Improved: Moderate reduction in severity of pain, though incomplete in capacity for work after the operation.
- 3) Unimproved: Presence or augmentation of pre-operative complaints.
- 4) Died: Death for any reason.

Table II.

Sample Questionnaire

Dear —

We are checking up on the results obtained in the operative treatment of low back and sciatic pain, and should appreciate having your answers to the following questions:

- 1) Do you have any pain? If there is any pain after operation, is it improved?, unimproved?, increased?
- 2) How soon after operation did your pain disappear?
- 3) How soon after operation did you return to work?
- 4) What is your present occupation? If it is the same as before, is your capacity for work full?, reduced?
- 5) Have you been forced to change your work or not able to work because of pain?

Table. III.

	Results obtained				
	cured	improved	unimproved	died	sum
Intervertebral disc protrusion	218(78.0%)	41(14.6%)	16(5.6%)	5(1.8%)	280
Disc lesion without protrusion	14(70.6%)	5(25.0%)	1(5.0%)	0	20
Thickening of lig. flav.	13(36.2%)	15(41.7%)	3(8.3%)	5(13.8%)	36
Meningitis adhesiva	15(42.9%)	11(31.5%)	8(22.8%)	1(2.8%)	35
Spondylolysis	2(40.0%)	2(40.0%)	1(20.0%)	0	5
Spondylolisthesis	1(20.0%)	1(20.0%)	0	3(60.0%)	5
Others.	15(51.7%)	6(20.7%)	4(13.8%)	4(13.8%)	29
Total	278(67.9%)	81(19.7%)	33(8.0%)	18(4.4%)	410(100.0%)

Describe in detail as much as possible what your activities are.

The results of laminectomy performed for radicular sciatica are shown in Table III.

Most of the deaths in this series were attributed to wound infection in War time, when there was no adequate chemotherapy. Since 1947 there have been no death. The incidence of favorable results was 87.6% (sum of 67.9% cured and 19.7% improved).

The results were most excellent in disc protrusion and disc lesion without protrusion, and not so satisfactory in meningitis spinalis adhesiva and thickenings of ligamenta flava. These latter two diseases as mentioned in the preceding chapter, can be caused by disc lesions. Therefore, it is difficult to presume that they are independent of each other and their unfavorable results can be supposedly attributed to concealed disc lesions. For example, in a case which had been operated upon for thickening of the ligamentum flavum, a large protrusion developed several months after the operation. This fact will also suggest the truth of the reason mentioned above. Therefore, the authors will discuss mainly the results of intervertebral disc lesions, especially of the protruded disc in the following.

§ 2. End-results of treatment in disc protrusion

The authors examined the results of 280 out of 406 cases (69.0%) with disc protrusion. Results in general are shown in Table III. These results obtained are not obviously inferior to those by other authorities in the world.

In operating, there are two objectives, the first is to relieve sciatic pain, the second to prevent post-operative back pain as much as possible. To attain these two objectives, various operative techniques were tried successively. The results are shown in Table IV and compared statistically with each other.

Table IV.

	cured	improved	unimproved	died	sum
Bilateral laminectomy	51(78.5%)	9(13.8%)	2(3.1%)	3(4.6%)	65
Hemilaminectomy	38(74.5%)	8(15.7%)	4(7.8%)	1(2.0%)	51
Partial laminectomy	18(60.0%)	10(33.3%)	2(6.7%)	0	30
Osteoplastic bilateral laminectomy	72(83.3%)	6(7.0%)	8(9.3%)	0	86
Osteoplastic hemilaminectomy	23(88.5%)	3(11.5%)	0	0	26
Laminectomy combined with fusion	16(76.2%)	5(23.8%)	0	0	21

Partial laminectomy is inferior to bilateral laminectomy and osteoplastic faceto-laminectomy (KONDO). For this reason, it is certain that operative techniques which allow wide exposure of nerve roots and adjacent disc, are superior to techniques which allow narrow exposure. The results of operation combined with bone fusion do not necessarily show special superiority, but it is evident that osteoplastic hemilaminectomy is superior to simple hemilaminectomy.

These facts must be discussed in relation to the problem of low back symptoms.

Complaints of the low back symptoms are varied as shown in Table V. and occur in a high percentage of cases whichever technique is used (Table VI).

But on this subject, it seems that partial laminectomy and combined excision-

Table V.

Lumbar symptoms after operation

1. Inability to keep half-bending posture longer than half an hour.
2. Inability to keep the same posture over one hour.
3. Dullness and fatigue in the lumbar region after a few kilometer's walk.
4. Fatigue in the lumbar region soon after work.
5. Inability to lift up a heavy load.
6. Sensitiveness in the lumbar region to vibration when riding in a vehicle.
7. Difficulty in lying prone.
8. Sensitiveness to cold.
9. Difficulty in running fast or jumping high.
10. Difficulty in bowing.

Table VI.

Operative technique	Complications of post operative low back symptoms	
	No. of cases	Per cent
Bilateral laminectomy	36 of 62	58.0%
Hemilaminectomy	30 of 50	60.0%
Partial laminectomy	13 of 30	43.3%
Osteoplastic bilateral laminectomy	43 of 86	50.0%
Osteoplastic hemilaminectomy	18 of 26	69.3%
Laminectomy combined fusion	9 of 21	42.9%
Total	149 of 279	53.5%

fusion are definitely superior to the other techniques. However, the present operative techniques, whichever are used, are much less satisfactory for complete relief of post-operative back symptoms, so there may be rather a greater variety of etiological possibilities to consider, than the extent of invasion against the bony structure of the spine. It is probable that not only damages to the architecture of the spine, such as increase in narrowing of the disc after removal of the protrusion, but also damage to the soft tissue are important etiological factors. Therefore, it is extremely difficult to prevent completely the post operative low back pain. Our clinical examination revealed that relief of root symptoms had a more intimate relationship with the results obtained than that of back symptoms. From this point of view, the authors believe that the prime aim of operative treatment of this disease should be the complete relief of root symptoms.

§ 3. Operative indications for disc protrusion

In our studies, the sex, age, occupation of the patient, the clinical course of disease and pathological changes, such as site of lesions, thickenings of ligamentum flavum and adhesion around the nerve root, did not affect the end-results of operation. In the severe cases with large protrusion, which was found as a definite

defect in myelography, causing severe radiating pain, local tenderness to pressure and tension signs, operation gave more excellent results than in the mild cases.

As the clinical manifestations of disturbances are essentially subjective, the assessment of the results of treatment presents difficulties. Even the capacity for work can not be independent of the emotional accompaniment of pain. The results of operation must be considered against a back ground of the intensity of pre-operative symptoms and signs. If the mild case has been accepted as an indication for surgery, it is clear that even mild post operative complaints obscure the improvement in the subjective symptoms, denoting partial or complete failure in operation, and disturb the capacity for work.

In the patients who have already a neurotic back ground or who are bent on the secondary gain from disability insurance, operation should be avoided. Operation should be restricted to the patients with large protrusion and severe or prolonged neurological symptoms and signs.

And we are of the opinion that the real aim of operation for disc lesion, as Greenwood asserted, is restoration of the affected nerve root to its original state.

From the congested epidural venous plexus which is very often found in the disc lesions as mentioned in the preceding chapter, profuse bleeding in operation occasionally results in fall of blood pressure, so operation should be avoided in cases with cardiovascular or organic visceral complications.

§ 4. Treatment of disc protrusion

In the early stage of disease or in acute attacks of sciatic pain, local rest and antiphlogistic measures for a certain length of time are valuable, because of the severe inflammatory changes in the extradural tissue.

However, when the conservative measures fail to give satisfactory relief, surgery should be undertaken on the principles of operative indication as mentioned above.

Our experimental disc lesion in rabbits proved that only the superficial part of the incised annulus fibrosus healed, and the union of the deep layers completely failed for a long period. These findings suggest that complete healing of disc protrusion by means of conservative treatment hardly occurs with the exception of the mild case.

Operation consist primarily in removal of the protruded disc and division of adhesions around the nerve root. Thus, the individual nerve fiber affected by a disc lesion may recover to a certain extent the ability to respond the stimuli.

In rabbits, degeneration of the peripheral nerve fibers caused by insertion of a piece of Laminaria under the nerve root recovered after its removal. And it was also clinically proved by recovery of normal sensation and tendon reflex after removal of the protruded disc. As the best operative technique, we use osteoplastic hemilaminectomy (Kondo), which allows wide exposure of a nerve root and adjacent disc. The additional fusion operation should be performed in cases with chronic back symptoms after excision.

For a certain period after operation, the low back structure should be protected from strain and irritation by a plaster cast or brace.

SUMMARY AND CONCLUSION

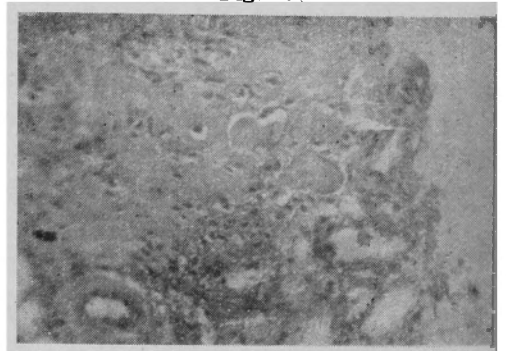- 1) Disc lesions cause abnormal movements of the spine, followed by degenerative changes in the ligamentum flavum and posterior articulations.
- 2) Disc lesions with or without protrusion result in extradural inflammatory changes and congestion, followed by strong adhesions around the nerve root.
- 3) In addition, nerve root compression by the protruded disc and thickened ligamentum flavum may act in combination in producing severe lesions of the intraspinal nervous elements.
- 4) The results of operative treatment in radicular sciatica are most excellent in disc lesions with or without protrusion.
- 5) Operation should be restricted to severe cases and avoided in mild cases with neurotic backgrounds.
- 6) Operation for disc protrusion consist in removal of the protruded disc and division of adhesions around the nerve root. As the best operative technique to attain these two objects, we use osteoplastic himilaminectomy.

The authors have discussed pathogenesis and treatment of radicular sciatica caused by disc lesions. There were many problems to be investigated in the treatment of disc protrusion. And more difficulties were presented in the treatment of complicated pathological conditions caused by other disc lesions. Moreover, the authors discovered four cases of severe radicular sciatica caused by extradural allergic inflammation, which showed such changes in the extradural adipose tissue, as thrombosis formation, fibrinoid swelling of connective tissue fibers, thickening of the wall of the blood vessels and edema as shown in Fig. 7. These changes, which offer problems to solve in the future, must have an intimate relationship with myofascial pain in the low back.

Our investigation in the low back will be confidently carried out to solve many problems which arise one after another.

We should like to record our deep indebtedness to all those who have helped us in this work, particularly to Professor Kihara Department of Anatomy, Professor Banq, Department of Architecture, Assis ant Professor Amano Department of Pathology, and orthopedic colleagues in the Kyoto University.

Fig. 7



Thrombosis formation, fibrinoid swelling of connective tissue fibers, thickenings of the wall of the blood vessels and edema in the extradural adipose tissue.

References

- 1) Barr, Low-Back and sciatic pain, results of treatment. *J. Bone & Joint Surg.*, **33-A**, 3, 1951.
- 2) Brailsford, Deformities of the lumbosacral region of the spine. *Brit. J. Surg.*, **16**, 64, 1929.
- 3) Camp, The roentgenologic diagnosis of intraspinal protrusion of intervertebral discs by means of radiopaque oil. *J.A.M.A.*, **113**, 2, 1939.
- 4) Chamberlain & Young, The diagnosis of intervertebral disk protrusion by intraspinal injection of air. *J.A.M.A.*, **113**, 23, 1939.
- 5) Dandy, Loose cartilage from intervertebral disc simulating tumor of the spinal cord. *Arch. Surg.*, **19**, 1929.
- 6) Dandy, Concealed ruptured intervertebral disks. *J.A.M.A.*, **117**, 1941.
- 7) Eckert & Decker, Pathological studies of intervertebral discs. *J. Bone & Joint Surg.*, **29**, 2, 1947.
- 8) Fujita, Clinical and experimental studies on osteoplastic laminectomy. *Arch. Japan. Chir.*, **22**, 6, 1953.
- 9) Goldwait, The lumbosacral articulation, an exploration of many cases of "Lumbago", "Sciatica" and paraplegia. *Boston Med. and Surg. J.*, CLXIV, 365, 1911.
- 10) Greenwood, A study of the cases of failure in the herniated intervertebral disc operation. *J. of Neurosurgery*, **9**, 1, 1952.
- 11) Hattori, Experimental studies on the destruction of the spine II. *Arch. Japan. Chir.*, **22**, 4, 1953.
- 12) Hayashi, Experimental studies of intervertebral disc lesions. *J. Japan. Orthop. Surg. Soc.*, **27**, 3, 4, 1953.
- 13) Hayashi, Ueber das abführende Lymphgefässsystem der Zerebrospinalflüssigkeit. *Kyoto igaku zasshi*, **46**, 6, 1943.
- 14) Inman & Saunders, Referred pain from skeletal structures. *J. Nerv. and Ment. Dis.*, **99**, 1944.
- 15) Igari, On the mechanism of occurrence of lumbago on its neuro-histological research. *J. Japan. Orthop. Surg. Soc.*, **27**, 3, 4, 1953.
- 16) Joplin, The intervertebral disc, Embryology, Anatomy, Physiology and Pathology. *Surg. Gynec. & Obst.*, **61**, 1935.
- 17) Jung & Brunschwig, Recherches histologique sur l'innervation des corps vertebraux. *La press médicale*, **27**, Feb, 1932.
- 18) Kondo, Sciatic pain. *Rinsho geka*, **1**, 2, 1947.
- 19) Kondo & Yamada, Investigations upon low back and sciatic pain. *J. Japan. Orth. Surg. Soc.*, **16**, 2, 1941.
- 20) Lenhard, End-result study of the intervertebral disc. *J. Bone & Joint Surg.*, **29**, 2, 1947.
- 21) Lindblom, Backache and its relation to ruptures of the intervertebral disks. *Radiology.*, **57**, 5, 1951.
- 22) Love, Protrusion of the intervertebral disc (fibrocartilage) into the spinal canal. *Proc. Staff Meet. Mayo Clin.*, **11**, 529; 535, 1936.
- 23) Love, Protruded intervertebral disks with a note regarding hypertrophy of ligamenta flava. *J.A.M.A.*, **113**, 23, 1939.
- 24) Love, The disk factor in low back pain with or without sciatica. *J. Bone & Joint Surg.*, **29**, 2, 1947.
- 25) Love & Camp, Root pain resulting from intraspinal protrusion of intervertebral disks, diagnosis and surgical treatment. *J. Bone & Joint Surg.*, **19**, 3, 1937.
- 26) Love & Walsh, Protruded intervertebral disks, report one hundred cases in which operation was performed. *J.A.M.A.*, **111**, 5, 1938.
- 27) Mixter and Barr, Rupture of intervertebral disc with involvement of spinal canal. *New England J. Med.*, CCXI, 210, 1934.
- 28) Nachlass, End-result study of the treatments of herniated nucleus pulposus by excision with or without fusion. *J. Bone & Joint Surg.*, **34-A**, 4, 1952.
- 29) O'Connell, Protrusion of the lumbar intervertebral disc, a clinical review based on 500 cases treated by excision of the protrusion. *J. Bone & Joint Surg.*, **33-B**, 1, 1951.
- 30) Ott & Adson, The diagnosis and treatment of the spinal cord, involving the conus and cauda equina. *New Orleans Med. and Surg. J.*, LXXIV, 169, 1923.
- 31) Roofe, Innervation of annulus fibrosus and posterior longitudinal ligament. Forth and fifth lumbar level. *Arch. Neurol. and Psychiat.*, **44**, 1940.
- 32) Sakaida, Das zerebrospinalflüssigkeit-ableitende Lymphgefässsystem der Säugetiere und des Menschen. *J. Anat.*, **24**, 4, 1949.
- 33) Smith & Walmsley, Experimental incision of the intervertebral disc. *J. Bone & Joint Surg.*, **33-B**, 4, 1951.
- 34) Spurling & Bradford, Neurological aspect of herniated nucleus pulposus at the forth and fifth lumbar spaces. *J.A.M.A.*, **113**, 23, 1939.
- 35) Tsukada, Histologische Studien über die Zwischenwirbelscheibe des Menschen. *Mitt. Med. Akad. Kioto*, **24**, 4, 1938.
- 36) Uebermuth, Die Bedeutung der Altersveränderungen der menschlichen Bandscheiben für die Pathologie der Wirbelsäule. *Arch. klin. Chir.*, **56**, 1930.
- 37) Wenzel, Sacralisation des V Lendenwirbels und ihre klinische Bedeutung. *Arch. klin. Chir.*, **188**, 1937.
- 38) Yamada, Ueber die hinteren Randwülste des Lendenwirbelkörpers. *Arch. Jap. Chir.*, **18**, 4, 1941.
- 39) Yamada & Ito, Pathogenesis and therapy of so-called radicular sciatic pain-centering around the intervertebral disc lesions with special reference to the intervertebral disc herniations. *Arch. Japan. Chir.*, **23**, 1, 1954.
- 40) Young & Michael, Air myelography. the substitution of air for lipiodol in roentgen visualization of tumors and other structures in the spinal canal. *Am. J. Roentgenol.*, **39**, 187, 1938.