

An Experimental Study on the Influence of Trypsin on Peripheral Circulation

by

YOSHIO KINAMI

From the 2nd Department of Surgery, Kanazawa University Medical School
(Director ; Prof. Dr. ICHIO HONJO)

Received for Publication Jan. 18, 1965

CONTENT

I. Introduction	ii. Circulating Blood Volume and Circulating Plasma Volume
II. Materials	iii. Microcirculation in the Auricle
1. Animals	iv. Microcirculation in the Intestinal Wall
2. Drugs	v. Microcirculation in the Liver
i. Trypsin	3. Microcirculation in Mouse with Trypsin In-
ii. Kallikrein	jection into the Portal System
III. Methods	i. Microcirculation in the Intestinal Wall
1. Microscopic Observation on Microcirculation	ii. Microcirculation in the Liver
2. Measurement of Arterial and Portal Pressures	4. Influence of Chlorpromazine on the Effect of
3. Circulating Blood Volume and Circulating Plasma Volume	Intravenous Injection of Trypsin
4. Examination of Vascular Permeability	i. Microcirculation in the Intestinal Wall
5. Histological Studies	ii. Microcirculation in the Liver
i. Hematoxylin-eosin Staining	5. Effect of Serum Added with Trypsin on
ii. Staining of Fat	Microcirculation
IV. Results	i. Microcirculation in the Intestinal Wall
1. Microcirculation in Mouse of Control with	ii. Microcirculation in the Liver
Intravenous Injection of Saline Solution	6. Localized Circulatory Disturbance Caused by
i. Microcirculation in the Auricle	Trypsin
ii. Microcirculation in the Intestinal Wall	7. Alteration of Vascular Permeability Caused
iii. Microcirculation in the Liver	by Trypsin
2. Microcirculation in Mouse with Intravenous	8. Histological Findings
Injection of Trypsin	V. Discussion
i. Peripheral Arterial Pressure and Portal	VI. Summary
Pressure	VII. References

I. INTRODUCTION

At acute pancreatitis, it is obviously known that various enzymes²⁾¹⁴⁾, such as trypsin, diastase, lipase and so on, are liberated from the pancreas seriously affecting the prognosis of the disease. Among these enzymes, trypsin has a particular significance in the disease process because of its activity to affect microcirculation. GISSENDÖRFER¹⁴⁾, in 1940, studied the influence of various enzymes of the pancreas on the circulatory system, and he reported that trypsin has an intense toxicity on the vascular system, whereas diastase and lipase have no particular significance in the development of circulatory collapse. MIGAY and PETROFF³⁵⁾ attributed the cause of circulatory collapse in pancreatic necrosis to the effect of trypsin on the vasomotoric nerves.

In 1910, NATUS⁴⁰⁾ studied circulation of the pancreas microscopically with the lapse

of time in rabbits with pancreatitis induced with the ligation of the pancreatic duct. ROSENBACH⁽⁴⁸⁾ also studied the effect of trypsin on the capillary of the tongue of frog and observed vasodilatation and circulatory disturbance with hemorrhage. On the other hand, it has been well known since early days that intravascular administration of trypsin results in a shock. ROCHA E SILVA⁽⁴⁵⁾⁽⁴⁶⁾ maintained that this state of shock resembles the type of anaphylaxis or pepton shock, and TAGNON⁽⁴⁹⁾⁽⁵⁰⁾ considered that the shock is associated with blood clotting. FOLLER⁽¹¹⁾, moreover, pointed out kallikrein as an etiologic factor of shock. In recent years, the existence of plasmakininogen has been disclosed by ROCHA E SILVA⁽⁴⁷⁾, WERLE⁽⁵⁵⁾, ELLIOT⁽⁹⁾⁽¹⁰⁾, FOX⁽¹²⁾, HILTON⁽¹⁸⁾ and others, which is activated by trypsin in the pancreas and serum to affect the peripheral vessels, and it has come to be conceived that these factors are in close association with circulatory collapse⁽⁵⁶⁾⁽⁵⁸⁾ at acute pancreatitis. Thus, various studies were carried out on intravascular administration of trypsin such as the observation of characteristic necrosis, (carried out by KELLNER, ROBERTSON⁽²⁵⁾ and others), in the cardiac and skeletal muscles following intravascular administration of trypsin. However, systemic studies on the attitude of the peripheral vessels, particularly on microcirculation at the administration of trypsin are scarcely found and little is clarified on visceral circulation. According to NITTA⁽⁴¹⁾, trypsin content in pancreatic venous blood showed a high level at acute pancreatitis experimentally produced in dogs, and important significance should be attributed to the influence of trypsin draining into the portal system on hepatic circulation.

The present experiment was carried out in the aim of clarifying the influence of trypsin on microcirculation, employing transillumination technique for the observation of peripheral circulation.

II. MATERIALS

1. Animals

Rabbits weighing approximately 2 kg and mice of DD-strain weighing approximately 20 g were used.

2. Drugs

i. Trypsin Crystalline trypsin (Novo Industry A/S in Denmark) of 50 mg (1.25 Anson units) was dissolved in saline at use, in order to avoid the decrease in activity.

ii. Kallikrein Kallikrein (Bayer) of 10 biological units was dissolved in saline.

III. METHODS

1. Microscopic Observation on Microcirculation

i. Light source, Filter and Illumination Regular bulb of 30 W with 6 volt was used as the light source with a blue color compensating filter and an adiabatic filter. The illumination was performed with an illumination system of Köhler.

ii. Microscope and Photographic Apparatus Nikon Microscope S Ke (Nippon Optical Company) was used, with water immersion objective of 5X, 10X and 20X. Diameter of the vessels was measured with ocular micrometer or by the use of the photographs. Photographic apparatus specially designed for Nikon Microscope was used. Photographs were taken with Cannon Camera and films of Fuji-color ASA 100, Fuji-color Negative

ASA 64, Sakura-color ASA 50, Neopan SS ASA 100, Neopan F ASA 32 and Minicopy ASA 32.

iii. Apparatus for Microscopic Observation on Living Mouse

The apparatus was consisted of a methacrylic basin, a plate on a side for animal fixation and a basement plate supporting the former two. Thermostatic Ringer's solution was perfused from small orifices on the both sides of the basin (Fig. 1).

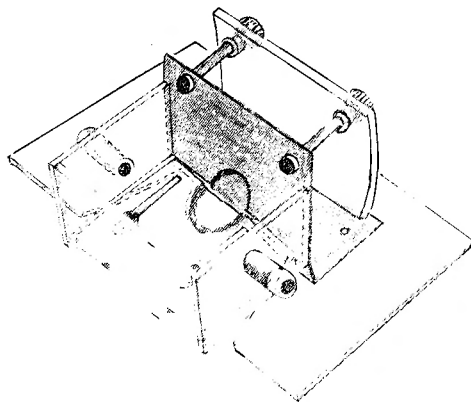


Fig. 1 Apparatus for Microscopic Observation in Living Mouse

iv. Anesthesia and Fixation of Animals

Isozol of 0.75 mg/10 g body weight was injected intramuscularly or intraperitoneally in adult mice weighing around 20 g. Depth of anesthesia was examined from respiration and disappearance of corneal and pain reflex. The auricle was shaved and the animal was set in the ap-

paratus so that the auricle might be placed in the basin through a semicircular hole of the side plate. Microscopic observation was made in a dry system in room temperature. For the observation of microcirculation in the liver, intestinal wall, the upper abdomen was carefully shaved and opened with upper median incision. The small intestine or the liver was placed in the basin through the semicircular hole and fixed to the side plate with adhesives to prevent leakage of the fluid for perfusion. Ringer's solution within the basin was kept to 37°C by the use of thermostat.

2. Measurement of Arterial and Portal Pressures

A glass canula was inserted into the femoral artery of rabbits, which was connected to a mercurial manometer for the measurement of arterial pressure. Portal pressure was measured through a vinyltube inserted from the mesenteric vein to the portal vein.

3. Circulating Blood Volume and Circulating Plasma Volume

Circulating blood volume and circulating plasma volume were measured with Evans blue method.

4. Examination of Vascular Permeability

Alteration of vascular permeability following the administration of trypsin was studied microscopically using India ink, Evans blue, Pontamine sky blue and Trypan blue.

5. Histological Studies

- i. Hematoxylin-eosin Staining
- ii. Staining of Fat (Sudan III Staining)

IV. RESULTS

1. Microcirculation in Mouse of Control with Intravenous Injection of Saline Solution
 - i. Microcirculation in the Auricle

Appearance of blood flow was studied in the arterioles, capillaries and venules. In these animals, saline of 0.02, 0.04, 0.06 and 0.1 cc was injected in the tail vein for the

Table 1. Findings of Peripheral Circulation in Control Mice

No. of Mouse	Saline	Contraction of Vessel	Dilatation of Vessel	Retardation of Flow
Blood Circulation in the Auricle				
5	0.02cc	—	—	—
5	0.04cc	—	—	—
5	0.06cc	—	—	—
5	0.10cc	÷	—	÷
Blood Circulation in the Intestinal Wall				
5	0.02cc	—	—	—
5	0.04cc	—	—	—
5	0.06cc	—	—	—
5	0.10cc	÷	—	÷
Hepatic Blood Circulation				
5	0.02cc	—	—	—
5	0.04cc	—	—	—
5	0.06cc	—	—	—
5	0.10cc	—	÷	÷

÷ below 10 %.

control (Tab. 1). In animals of saline injection of 0.02, 0.04 and 0.06 cc, any alteration could not be observed in diameter of the vessels and in the appearance of blood flow, whereas in animals of saline injection of 0.1 cc, slight and temporary contraction of the vessels and retardation of blood flow could be observed.

ii. Microcirculation in the Intestinal Wall

The observation was carried out in the wall of the ileum of upper part and in the mesentery.

In the intestinal wall, small tributaries originating from adjoining main stems of artery and vein communicated with each other. In the normal state, blood stream could not be recognized as the movement of blood corpuscles in the vessel larger than the smallest arteries and veins because of large velocity of the stream. However, in the arterioles the stream could be sometimes obviously recognized as the movement of leucocytes.

Appearance of circulation in the smallest vessels could be adequately studied in the mesentery, and the arteriole, metarteriole, thoroughfare channel, true capillary and venule as demonstrating the microcirculation unit could be all identified. Periodic contraction could be observed in the arterioles and metarterioles, and periodic fluctuation of velocity of blood stream caused by the periodic contraction of the precapillary sphincter of the true capillaries could be also obviously observed.

For control study, saline of 0.02, 0.04, 0.06 and 0.1 cc was respectively injected in the tail vein (Tab. 1). In each animal slight and temporary contraction of the vessels and retardation of blood flow were observed in cases of 0.1 cc as in the observation of microcirculation in the auricle, whereas significant change could not be recognized in the occasions of saline injection of 0.02, 0.04 and 0.06cc.

iii. Microcirculation in the Liver

Microcirculation in the liver was studied in the left lobe of mouse which was laparotomized with the upper median incision. Marginal part of the liver showed respiratory movement with abundant vessels intermingling with each other, diffusely coloured with reddish tone (Fig. 2, Photo. 1).

The vascular system can be classified into blood supplying system and blood draining one, the former constituting the

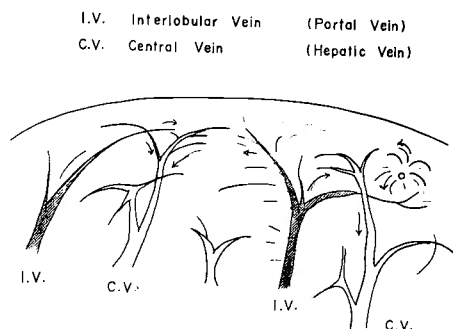


Fig. 2 Vascular Architecture in the Marginal Area of Mouse Liver

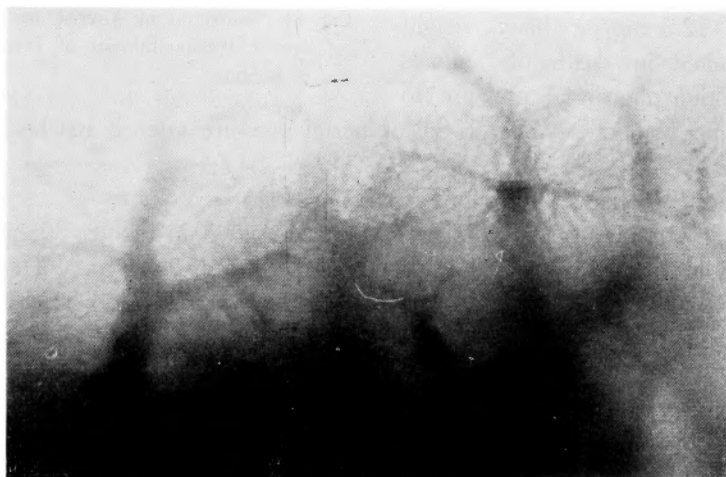


Photo. 1. Vascular Architecture of the Left Lobe of the Mouse Liver (50×)

portal system i. e. interlobular vein and the latter the central vein belonging to hepatic vein system. Blood from the interlobular vein entered the central vein through the sinusoids as if it were sucked in. Between the adjoining central veins, the vessels could be observed running in the vertical direction in a shape of dot gushing up blood corpuscles, which is the branches of interlobular veins bifurcated in deeper part. In the marginal area of the liver, alternative arrangement of the portal and hepatic veins could be observed.

The sinusoids had the width of 7 to 10 μ , and sinusoidal flow had not certain tendency, showing change in route of flow or flow in the reverse direction in some parts. Velocity of sinusoidal flow was rapid in some parts and slow in other parts. Flow regulating mechanism of the sinusoid, i. e. so-called inlet and outlet could not be observed, and in the marginal area of the liver the vessels, which could be called the branches of the hepatic artery, could not be recognized.

In control study with saline injection of 0.02, 0.04, 0.06 and 0.1 cc in the tail vein, change of vascular diameter and velocity of flow could not be observed in the injection

of 0.02, 0.04 and 0.06 cc, whereas in cases of 0.1 cc injection slight and temporary vaso-dilatation and retardation of blood flow could be observed (Tab. 1).

2. Microcirculation in Mouse with Intravenous Injection of Trypsin

i. Peripheral Arterial Pressure and Portal Pressure

Crystalline trypsin of 12.5 mg/kg body weight, being dissolved in saline, was infused dropwise in the auricular vein of rabbits spending 20 minutes. Simultaneously with the commencement of the infusion, arterial pressure began to fall and portal pressure to elevate (Fig. 3).

Large dosis administration of trypsin of more than 12.5 mg/kg body weight invariably resulted in death of animals without restoration of arterial pressure to normal level and with one way-path fall of portal pressure after it reached the maximum level.

ii. Circulating Blood Volume and Circulating Plasma Volume

Circulating blood and plasma volumes were determined in rabbits 30 minutes after the commencement of infusion of trypsin of 12.5 mg/kg body weight. The determination revealed a decrease of 22 per cent in circulating blood volume and a decrease of 28 per cent in circulating plasma volume compared with the values before the administration of trypsin (Tab. 2).

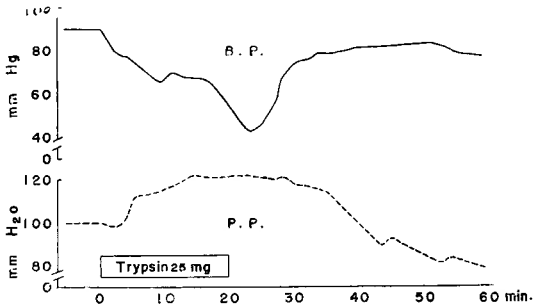


Fig. 3 Fluctuation of Arterial and Portal Pressures Following Infusion of Trypsin of 25mg in Rabbit

Table 2. Changes in Circulating Blood Volume and Circulating Plasma Volume after Administration of Trypsin in Rabbits

Rabbit No.	Trypsin mg/kg	Circulating Blood Volume cc/kg		Circulating Plasma Volume cc/kg	
		Before Inj.	After Inj.	Before Inj.	After Inj.
12	12.5	100	60	57	36
13	12.5	100	84	59	46
14	12.5	92	78	47	39
16	12.5	110	93	60	40
18	12.5	96	71	51	37
Mean		99.6	77.2	54.8	39.6

iii. Microcirculation in the Auricle

Trypsin of 0.05, 0.10 and 0.15 mg/10 g body weight dissolved in saline was injected in the tail vein of mice, the amount of injected solution being 0.02, 0.04 and 0.06 cc, respectively.

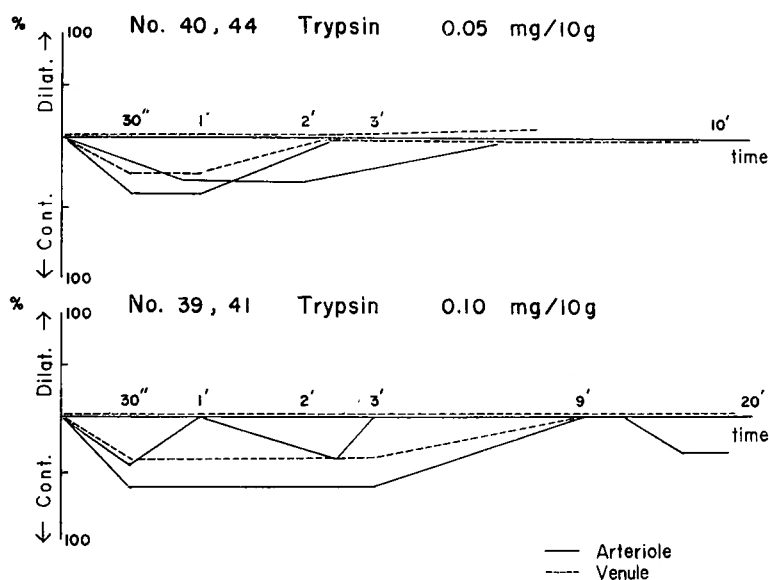
The degree of alteration in circulatory appearance was various from a slight circulatory disturbance to abrupt and lethal shock, depending upon the dose of trypsin injected.

Immediately after the injection of trypsin in the tail vein, vasoconstriction occurred with simultaneous retardation of blood flow (Tab. 3, Fig. 4). There was difference in

Table 3. Finding of Auricular Circulation in Mice after Injection of Trypsin in the Tail Vein

Mouse No.	Trypsin mg/10g	Contraction		Retardation of Flow	Stasis	Outcome
		Arteriole	Venule			
40	0.05	+	+	+	—	Survival
43	0.05	+	—	+	—	Survival
44	0.05	+	—	+	—	Survival
45	0.05	+	+	+	—	Survival
39	0.10	†	—	+	—	Survival
41	0.10	†	+	+	+	Death
42	0.15	†	+	+	+	Death
46	0.15	†	+	+	+	Death

Contraction + 20~50%
† above 50%

**Fig. 4** Change in the Auricular Vessels of Mice after Injection of Trypsin in the Tail Vein

the degree of vasocontraction of the artery, depending on the individual branches and on the part of a single branch. After the injection of trypsin of 0.05 and 0.10 mg/10 g body weight, contraction of the veins was sometimes observed and sometimes not. In the occasion of trypsin injection of 0.05 mg/10 g body weight, there were some animals that did not show particular change in the velocity of blood flow although accompanied by a slight contraction of the arterioles. When trypsin of 0.15 mg/10 g body weight was injected, intense contraction of both arteries and veins could be observed with stasis of blood flow in all cases. After the stasis, there occurred pendular movement of blood corpuscles and reverse flow in the arterioles and venules.

iv. Microcirculation in the Intestinal Wall

Microcirculation in the intestinal wall was studied in the mice which received injec-

Table 4. Findings of Circulation in the intestinal Wall of Mice after Injection of Trypsin in the Tail Vein

Mouse No.	Trypsin mg/10g	Contraction		Retar- dation of Flow	Stasis	Hemagglu- tination	Hemorrh- age	Outcome
		Arteriole	Venule					
6	0.05	+	-	+	-	-	-	Survival
7	0.05	+	-	+	-	-	-	Survival
12.	0.05	+	-	+	-	-	-	Survival
13	0.05	+	+	+	+	-	-	Survival
18	0.05	+	-	+	-	-	-	Survival
21	0.10	++	+	+	+	+	-	Death
24	0.10	++	+	+	-	-	-	Survival
25	0.10	++	+	+	+	-	+	Survival
30	0.10	+++	+	+	+	-	-	Survival
36	0.10	+++	+	+	+	÷	-	Death
15	0.15	+++	++	+	+	+	-	Death

Contraction ++ 50~70%
+++ above 70%

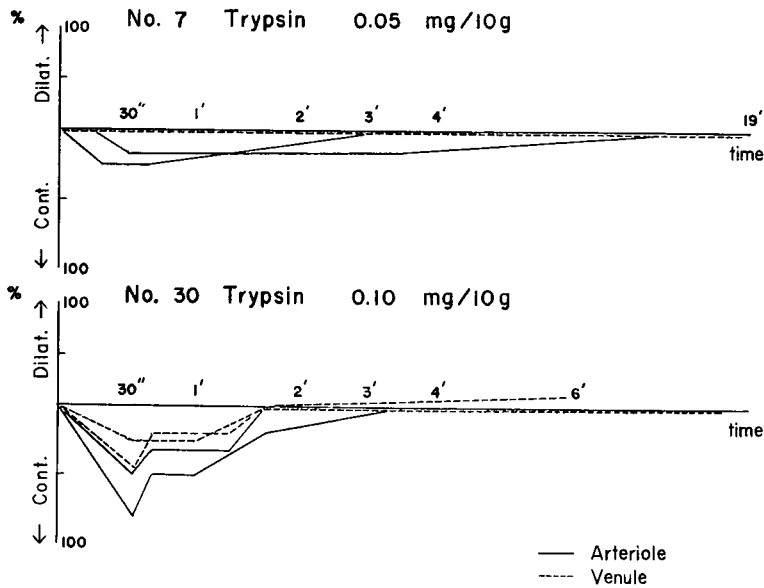


Fig. 5 Vascular Change in the Intestinal Wall of Mice after Injection of Trypsin in the Tail Vein

tion of trypsin of 0.05, 0.10 and 0.15 mg/10 g body weight in the tail vein, the amount of injected solution being 0.02, 0.04 and 0.06 cc, respectively (Tab. 4, Fig. 5, Photo. 2, 3).

Contraction of various degree could be observed in the artery from the size of the smallest arteries to that of precapillary arterioles, the degree of contraction depending on the dose of trypsin injected ranging from 10 to 70 or 80 per cent. As in the vessels of the auricle, the contraction sometimes occurred uniformly in a single vessel and sometimes

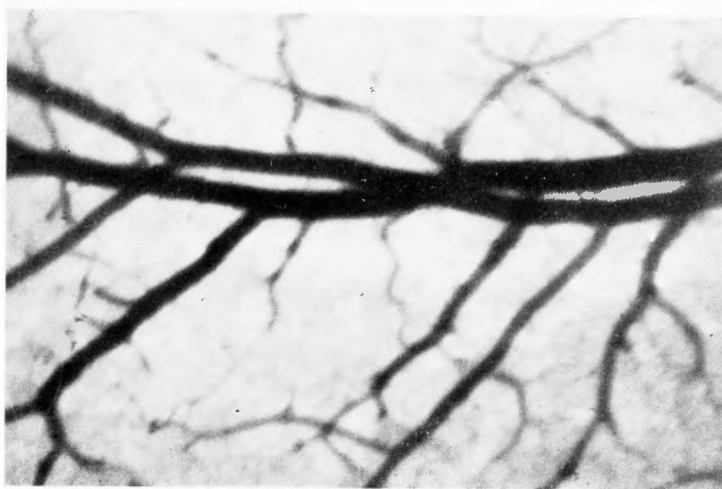


Photo. 2. Vessels in the Intestinal Wall of Normal Mouse (50 \times)

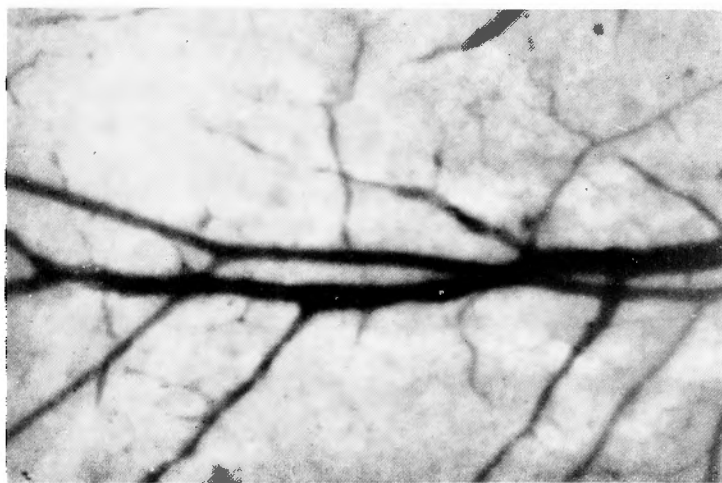


Photo. 3. Contraction of Vessels Caused by Injection of Trypsin of 0.1 mg/10 g Body Weight in the Tail Vein (50 \times)

occurred in a different degree in various parts of a single one. Slight contraction of the veins could be observed in the venules only in cases of trypsin injection of large dose.

All animals survived trypsin injection of 0.05 mg/10 g body weight, and arterial contraction could be observed with accompanying retardation of blood flow. Although vasoconstriction and stasis of blood flow in the veins were observed in a single case, hemagglutination and hemorrhage could not be found in any case.

In animals receiving trypsin injection of 0.10 mg/10 g body weight, degree of arterial contraction ranged from 30 to 80 per cent, and venous contraction and retardation of blood flow occurred. Stasis of the flow also occurred with an exception in one case, and hemagglutination and diapedic hemorrhage, although in one case, were also observed (Photo. 4).

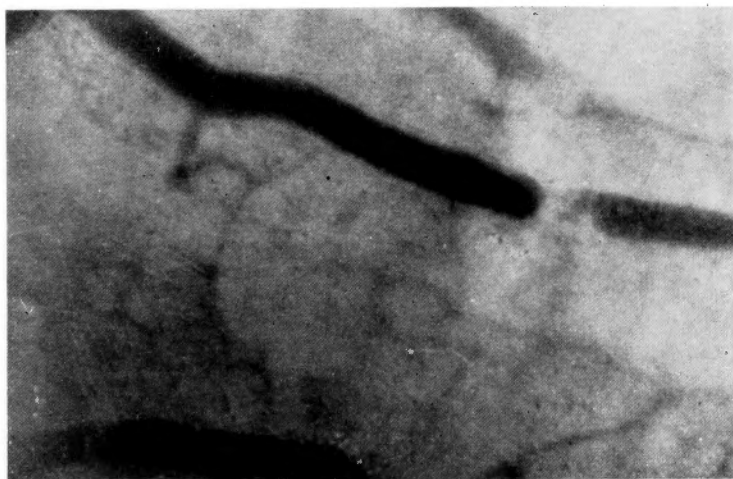


Photo. 4 Hemagglutination within the Arterioles Caused by Injection of Trypsin of 0.1 mg/10 g Body Weight (100 \times)

At trypsin injection of 0.15 mg/10 g body weight in the tail vein, an intense contraction occurred with stasis of blood flow and microscopic view turned brighter. At this occasion, reverse flow was observed in the smallest arteries and venules, and hemagglutination occurred in the arterioles. In the cases of intense and lethal shock, marginal stream of leucocytes occurred in the venules without the sticking of leucocytes immediately before the death. Invariable death occurred ultimately in animals with trypsin injection of this dose.

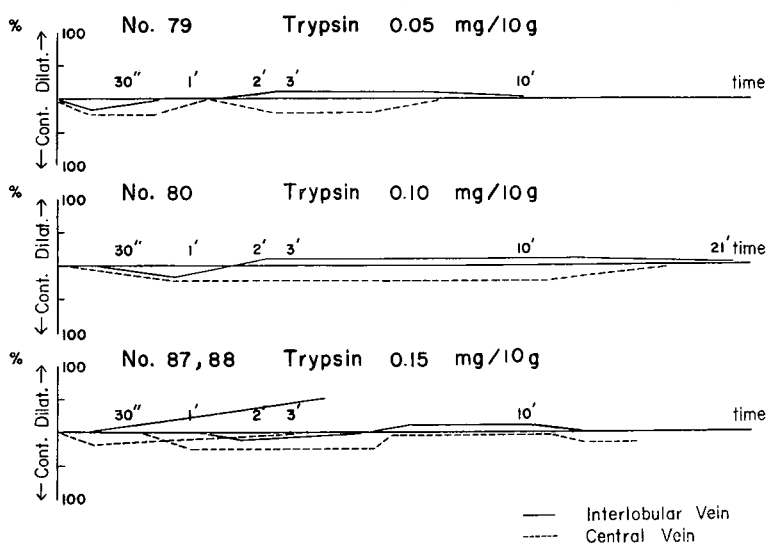
Furthermore, minute circulatory changes were studied in the vessels of the mesentery. Contraction was particularly marked in the precapillary arterioles, caliber of which so much narrowing as to eliminate bloody content. Although obvious contraction could not be recognized in the true capillaries, retarded flow of plasma was merely observed, which was due to the captivation of corpuscular components by the contraction of the precapillary sphincter. Blood corpuscles could be identified in the arterioles owing to the retardation flow at arterial contraction. At the contraction of more intense degree, sludgy appearance of blood was observed and pendular movement of corpuscular masses occurred in some parts.

v. Microcirculation in the Liver

Immediately after the injection of trypsin in the tail vein, retardation of blood flow was observed in the interlobular veins with following retardation of the flow in the sinusoids and further in the central veins. Complete stasis of blood flow could not be observed in the sinusoid after trypsin injection of 0.05 mg/10 g body weight, but it was sometimes observed in the animals receiving trypsin injection of 0.10 or 0.15 mg/10 g body weight. In the marginal area of the hepatic lobe, blood stream was maintained in some parts and in other parts it could not be observed, in some cases slight respiratory movement of blood corpuscles being recognized. In animals, which survived trypsin injection despite the occurrence of stasis of blood flow it was observed that blood stream restored from the interlobular veins through the sinusoids to the central veins.

Table 5. Finding of Hepatic Circulation in Mice after Injection of Trypsin in the Tail Vein

Mouse No.	Trypsin mg/10g	Response of Vessels	Retardation of Flow	Stasis	Hemagglutination	Outcome
74	0.05	Contraction → Dilatation	+	—	—	Survival
75	0.05	Contraction → Dilatation	+	÷	÷	Survival
76	0.05	Contraction → Dilatation	+	—	—	Survival
77	0.05	Contraction → Dilatation	+	—	—	Survival
79	0.05	Contraction → Dilatation	+	—	—	Survival
80	0.10	Contraction → Dilatation	+	—	—	Survival
81	0.10	Contraction → Dilatation	+	+	+	Death
82	0.10	Contraction → Dilatation	+	+	—	Survival
84	0.10	Contraction → Dilatation	+	—	+	Survival
87	0.15	Slight Contraction → Intense Dilatation	+	+	—	Death
88	0.15	Slight Contraction → Intense Dilatation	+	+	—	Death

**Fig. 6** Vascular Change in the Liver of Mice after Injection of Trypsin in the Tail Vein

In parallel with the retardation of hepatic blood flow, decrease in diameter of the interlobular veins and the central vein was observed. At the moment of stasis of the flow, dilatation of the sinusoids could not be observed, and ischemia was observed instead. As the hepatic blood flow restored, there appeared dilatation of the interlobular veins which further spread to the sinusoids and thus blood flow restored even more actively. However, intrahepatic pooling of large amount of blood could not be observed despite decrease in the velocity of blood flow that occurred later (Tab. 5, Fig. 6).

By trypsin injection of 0.15 mg/10 g body weight, sudden stasis of the flow was observed with following marked dilatation of the sinusoids.

3. Microcirculation in Mouse with Trypsin Injection into the Portal System

i. Microcirculation in the Intestinal Wall

A loop of the intestine and the spleen were drawn out from the incision in the left side of the abdomen.

Trypsin of 0.05 and 0.10 mg/10 g body weight dissolved in saline was injected in the mesenteric vein or spleen, the amount of injected solution being 0.02 and 0.04 cc, respectively. Immediately after the injection, the arteries and veins in the intestinal wall began to contract with resulting retardation of blood flow, the degree of contraction being slight and less than 20 per cent (Tab. 6, Fig. 7). Although there were some animals which died with the finding of slight dilatation of the venules, hemagglutination and hemorrhage could not be observed.

Table 6. Finding of Circulation in the Intestinal Wall and Liver of Mice after Injection of Trypsin in the Portal

° Injection in the Spleen
* Injection in the Mesenteric Vein

Mouse No.	Trypsin mg/10g	Response of Vessels		Retardation of Flow	Outcome
		Contraction	Dilatation		
Blood Circulation in the Intestinal Wall					
° 99	0.05	÷	Venule ÷	÷	Survival
*101	0.10	÷	Venule +	+	Survival
°102	0.10	÷	Venule +	+	Death
Hepatic Blood Circulation					
°107	0.05	Slight Contraction → Slight Dilatation		+	Survival
*108	0.10	Intense Contraction → Slight Dilatation		Stasis	Survival
°109	0.10	Contraction → Slight Dilatation		+	Survival
*110	0.10	Intense Contraction → Slight Dilatation		Stasis	Death
°115	0.10	Contraction → Slight Dilatation		Stasis	Death

Changes in Vascular Diameter ÷ below 20%
+ 20%

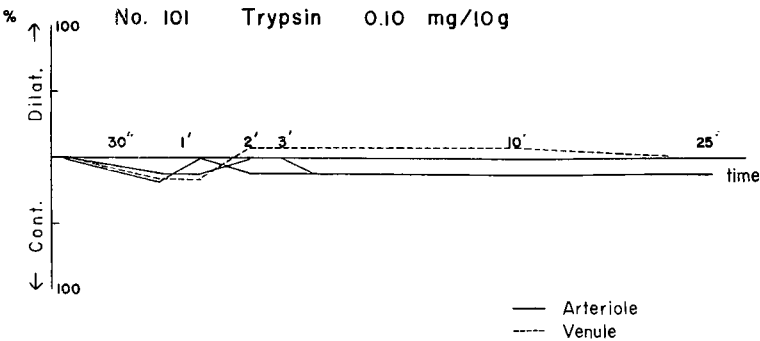


Fig. 7 Vascular Change in the Intestinal Wall of Mice after Injection of Trypsin in the Portal Vein

ii. Microcirculation in the Liver

As in the study of microcirculation in the intestinal wall, trypsin of 0.05 and 0.10

mg/10 g body weight was injected in the mesenteric vein or spleen and microcirculation was studied in the liver (Tab. 6).

Immediately after the injection, retardation of blood flow occurred in the interlobular veins through the sinusoids to the central veins and contraction of the hepatic vessels could be observed (Fig. 8). The degree of the contraction was more intense than in occasion of the injection in the tail vein, ischemia of the liver also being more pronounced. In some area interruption of blood flow could be observed in the interlobular veins and in some area pendular movement of blood corpuscles could be also observed. Although blood flow tended to restore thereafter, blood circulation was worse as a whole, contraction being retained for long in the hepatic vessels. Stasis was observed for long in the sinusoids, but particularly marked dilatation was not observed.

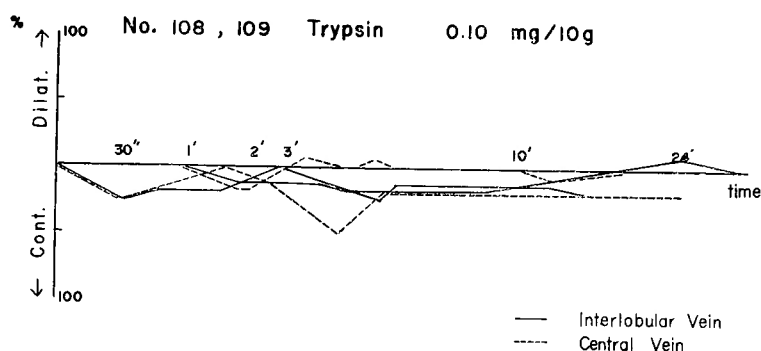


Fig. 8 Vascular Change in the Liver of Mice after Injection of Trypsin in the Portal Vein

4. Influence of Chlorpromazine on the Effect of Intravenous Injection of Trypsin

i. Microcirculation in the Intestinal Wall

Chlorpromazine of 0.3 mg/10 g body weight was intramuscularly injected with additional injection of Isozol of 0.3 mg/10 g body weight, and microcirculation was studied in the intestinal wall. In these cases, peristalsis of the intestine was more weak than in animals with administration of Isozol alone, and the vessels of the intestine showed slight dilatation and congestion and vasomotion was markedly depressed.

Immediately after the injection of trypsin in the tail vein, obvious retardation of blood flow was observed simultaneously with slight contraction of the artery, being followed by dilatation of the arterioles and capillaries, and blood flow, once tended toward restoration, retarded again with resulting stasis of the flow. Retardation of the flow was particularly prominent on the venous side (Tab. 7, Fig. 9).

Although, as in cases with Isozol administration alone, the degree of initial slight contraction of the vessels and retardation of blood flow was proportional to the dosis of trypsin injected in all cases, vasodilatation followed thereafter with later occurrence of retardation in more than half of the cases.

ii. Microcirculation in the Liver

Similarly with the observation in the intestinal wall, circulatory appearance was studied in the liver in animals with the administration of chlorpromazine and Isozol. Periph-

Table 7. Finding of Circulation in the Intestinal Wall and Liver of Mice with Chlorpromazine Treatment after Injection of Trypsin in the Tail Vein

Mouse No.	Chlorpromazine mg/10g	Trypsin mg/10g	Contraction	Dilatation	Retardation of Flow	Outcome
Blood Circulation in the Intestinal Wall						
181	0.3	0.05	÷	—	+	Death
184	0.3	0.05	—	—	+	Survival
185	0.3	0.05	—	+	+	Survival
187	0.3	0.05	÷	+	+	Survival
182	0.3	0.10	÷	—	+	Survival
186	0.3	0.10	÷	+	+	Death
188	0.3	0.10	÷	+	+	Death
Hepatic Blood Circulation						
189	0.3	0.05	—	—	+	Survival
190	0.3	0.05	—	—	+	Survival
191	0.3	0.10	÷	—	+	Survival
192	0.3	0.10	÷	—	+	Survival
195	0.3	0.10	÷	—	+	Death

Changes in Vascular Diameter ÷ below 10%
+ 10%

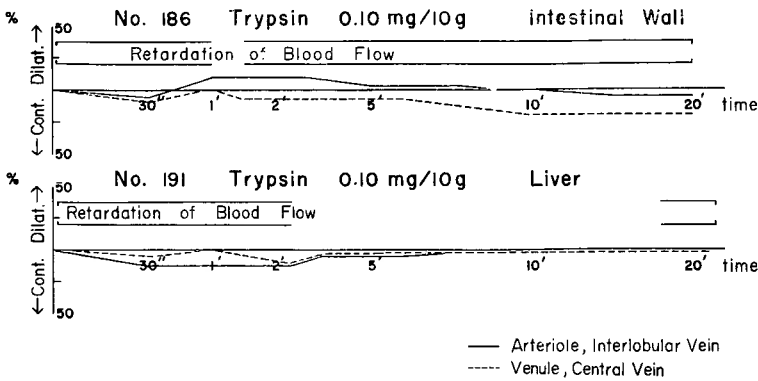


Fig. 9 Vascular Change in the Intestinal Wall and Liver of Mice with Chlorpromazine Treatment after Injection of Trypsin in the Tail Vein

ery of the interlobular veins and central veins showed slight dilatation and the sinusoids were observed to be wide. Although retardation of blood flow could be seen in a slight degree, there was no marked difference and no obvious decrease in the amount of draining blood compared with the cases of Isozol administration alone.

Immediately after the injection of trypsin in the tail vein, slight decrease in diameter of the interlobular veins and marked retardation of blood flow were observed being accompanied by decrease in hepatic blood flow (Tab. 7, Fig. 9). In cases of large dosis injection of trypsin, similar findings complete stasis of blood stream, pendular movement of blood corpuscles and hemagglutination could be seen as in cases of Isozol administration alone. However, neither intense contraction nor dilatation of the sinusoids could be

observed and in general, alteration in the circulatory appearance of the liver was milder than in Isozol administration alone.

5. Effect of Serum Added with Trypsin on Microcirculation

i. Microcirculation in the Intestinal Wall

In this experiment rabbit serum was used, kallikrein being used for control study.

After the injection of kallikrein of 0.4 biological units/10 g body weight in the tail vein of mice, vasodilatation and increase in the velocity of blood flow were observed, which was then followed by retardation of the flow (Tab. 8, Fig. 10). On the contrary to obvious dilatation of the arterioles, diameter of the venules rather decreased. In general, an increase in the blood flow was observed including the capillary bed, and all animals survived.

After the injection of trypsin of 0.005 mg/10 g body weight in the tail vein of 5 mice, change in circulatory appearance could not be observed in any case.

Table 8. Finding of Circulation in the Intestinal Wall and Liver of Mice after Injection of Trypsin, Kallikrein, Rabbit Serum and Rabbit Serum Containing Trypsin (Activation for 10 Minutes)

Procedure	Injection	Mouse No.	Vascular Response		Blood Flow		Outcome
			Contraction	Dilatation	Acceleration	Retardation	
Blood Circulation of the Intestinal Wall							
Trypsin	0.005 mg/10g	200	—	—	—	—	Survival
	0.4 biol. u./10g	164	—	++	+	÷	Survival
Kallikrein	0.4 biol. u./10g	166	—	++	+	÷	Survival
	0.04cc	170	—	—	—	—	Survival
Rabbit Serum	0.04cc	171	—	—	—	—	Survival
	0.04cc	172	—	—	—	—	Survival
Rabbit Serum +	0.04cc	170	—	+	—	+	Survival
	0.04cc	171	—	+	—	+	Death
Trypsin	0.04cc	172	—	+	—	—	Survival
Hepatic Blood Circulation							
Trypsin	0.005 mg/10g	205	—	—	—	—	Survival
	0.4 biol. u./10g	163	—	++	+	÷	Survival
Kallikrein	0.4 biol. u./10g	180	—	++	+	÷	Survival
	0.04cc	175	—	—	—	—	Survival
Rabbit Serum	0.04cc	176	—	—	—	—	Survival
	0.04cc	177	—	—	—	—	Survival
Rabbit Serum +	0.04cc	175	—	+	—	+	Death
	0.04cc	176	—	+	—	+	Survival
Trypsin	0.04cc	177	—	+	—	+	Survival

Changes in Vascular Diameter + 10~20%
++ above 20%

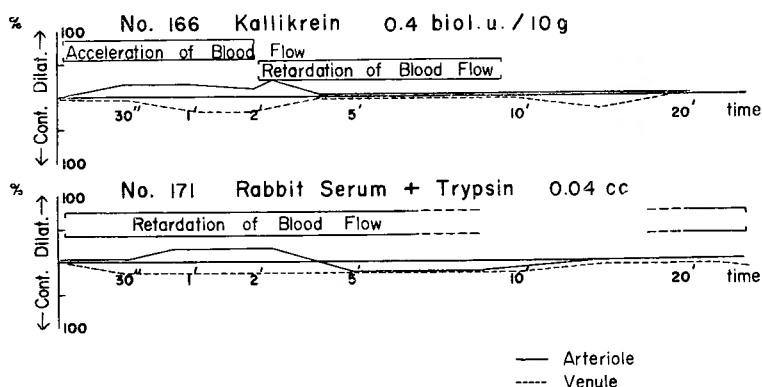


Fig. 10 Vascular Change in the Intestinal Wall of Mice after Injection of Kallikrein and Rabbit Serum Added with Trypsin (Activation for 10 Minutes) in the Tail Vein

Microcirculation was studied for 20 minutes in the intestinal wall of mice which received injection of rabbit serum of 0.04 cc in the tail vein. In all animals, there was no change in the vessels and blood flow. Then, trypsin of 0.25 mg was added to 1 cc of rabbit serum and left in room temperature for 10 minutes, 0.04 cc of which was injected in the tail vein of mice and the response of the vessels was studied in the intestinal wall (Tab. 8). Immediately after the injection, there occurred retardation of blood flow and vasodilatation in the venules (Fig. 10). During the stadium of this vasodilatation blood flow was retarded to show the sludgy appearance, but stasis of blood flow and hemagglutination could not be observed. In parallel with restoration of vascular diameter, velocity of blood flow also returned to normal, which was, however, followed by retardation of blood flow as time went on, and some of the animals died with the finding of vasocontraction. To survey all cases, vasodilatation of 10 to 20 per cent and retardation of blood flow were prevailing findings, and acceleration of blood stream could not be observed with necessarily resulting decrease in blood flow.

ii. Microcirculation in the Liver

By the injection of kallikrein of 0.4 biological units/10 g body weight in the tail vein of mice, slight increase in the velocity of blood flow, dilatation of the interlobular veins, central veins and sinusoids and increase in hepatic blood flow were observed (Tab. 8, Fig. 11).

Injection of trypsin of 0.005 mg/10 g body weight in the tail vein of mice did not cause any change in circulatory appearance in the liver.

Rabbit serum of 0.04 cc also did not cause any change in the finding of the hepatic vessels and velocity of blood flow when it was injected in the tail vein of mice.

Twenty minutes later, 0.04 cc of rabbit serum containing trypsin in the proportion of 0.005 mg/10 g body weight was injected from the tail vein of mice, which resulted in slight dilatation of the peripheral part of the hepatic vessels and sinusoids being accompanied by retardation of blood flow (Tab. 8, Fig. 11). Consequently, hepatic blood flow decreased, but the velocity of blood flow shortly returned to normal and the diameter of the vessels improved. However, in lethal cases, blood flow again retarded and hepatic

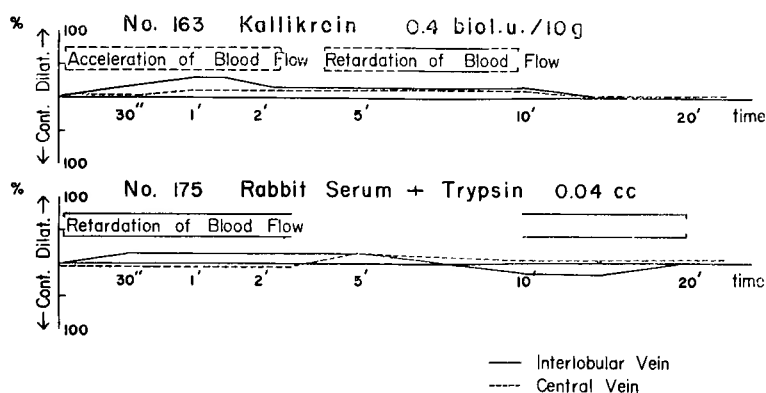


Fig. 11 Vascular Change in the Liver of Mice after Injection of Kallikrein and Rabbit Serum Added with Trypsin (Activation for 10 Minutes) in the Tail Vein

blood flow also decreased. In general, slight dilatation of the hepatic vessels, retardation and decrease in blood flow were observed.

6. Localized Circulatory Disturbance Caused by Trypsin

Observation was performed for an hour on the vessels of the intestinal wall in the apparatus for microcirculation study in living animals, the basin of which being perfused for 5 minutes with trypsin solution of 0.25 per cent of 37°C (Tab. 9). Slight contraction and retardation of blood flow occurred in the arterioles and precapillary arterioles within 1 to 2 minutes after the commencement of the perfusion.

A few minutes later, both diameter of the vessels and blood flow returned to normal and blood flow was not disturbed in the capillaries of the serosa of the intestinal wall. The arterioles tended rather to dilatation thereafter, while the venules showed contraction of 20 to 30 per cent. However, the capillaries showed no particular change. Then, retardation of arterial blood flow occurred and partial contraction was observed in the arteries. Stasis also occurred in the venules with retardation of blood flow. At this stadium, marginal stream of leucocytes appeared, and there developed sticking of these cells as time

Table 9. Finding of Circulation in the Intestinal Wall of Mice after Perfusion with 0.25 % Trypsin Solution for 5 Minutes in Vessel of Apparatus for Observation

Mouse No.	Trypsin	Contraction	Dilatation	Retardation	Stasis	On Set of Hemorrhage	Leucocyte Sticking	Edema of Intestine	Outcome
51	0.25%	+	+	+	+	16th min.	+	+	Death
52	0.25%	+	+	+	+	23rd min.	+	+	Survival
53	0.25%	÷	+	+	+	17th min.	+	+	Death
56	0.25%	÷	+	+	+	17th min.	+	+	Death
57	0.25%	+	+	+	+	12th min.	+	+	Death
58	0.25%	+	+	+	+	16th min.	+	+	Survival
59	0.25%	+	+	+	+	25th min.	+	+	Death
60	0.25%	÷	+	+	+	20th min.	+	+	Death

Changes in Vascular Diameter ÷ below 10%

+ { 20~30% (Contraction)
10~20% (Dilatation)

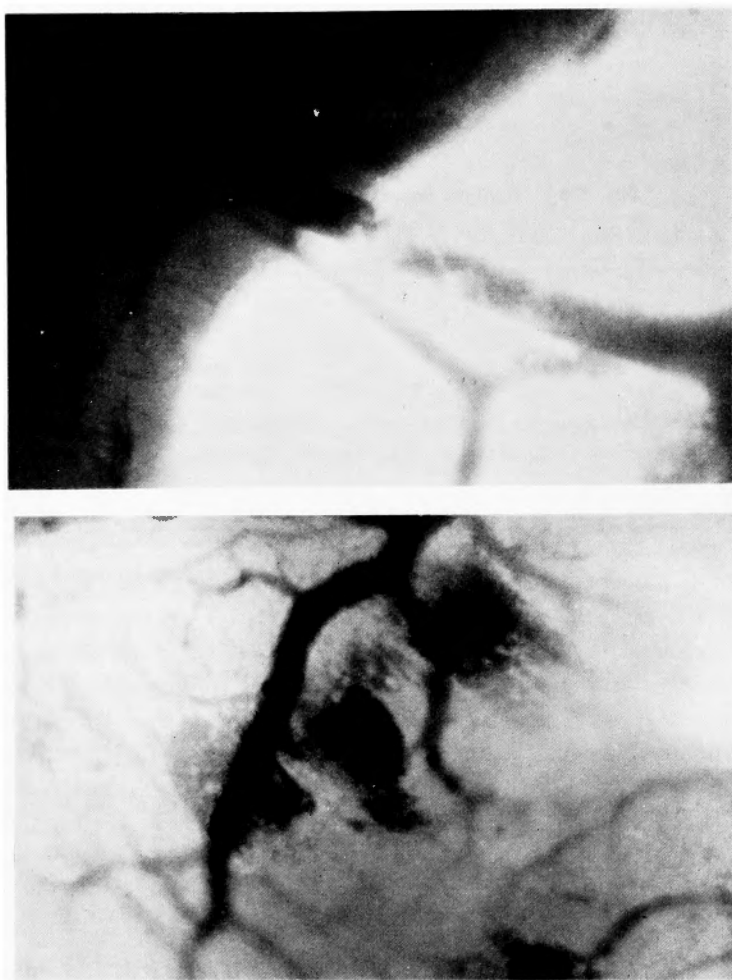


Photo. 5. and 6. Mural Thrombosis and Haemorrhagia per Rhexin after Perfusion with 0.25 % Trypsin Solution in Basin of Apparatus for the Observation (50×)

elapsed, gradually forming mural thrombosis. This thrombosis enlarged finally to obstruct the entire lumen of the vessel. Erythrocytes were observed to stream through the thin cleft between the thrombosis and the vessel wall. Such findings could be observed also in the main branch of the vein and the mural thrombosis sometimes exfoliated from the vessel wall and flew away. Furthermore, mural thrombosis developed in the smallest arteries and arterioles and flew away to the periphery, sometimes becoming to fine pieces in the arterioles and further obstructing the smaller branches to interrupt blood stream (Photo. 5).

At such stadium, haemorrhagia per rhexin was observed in the capillary bed here and there. This hemorrhage showed an appearance of gushing out from the vessel and the hemorrhage increased as time passed on. However, once occurred hemorrhage did not further developed suddenly at that very site. Haemorrhagia per rhexin did not occurred in

the arterioles and venules and occurrence of diapedic hemorrhage of the venules could not be clarified (Photo. 6).

Retardation of arterial flow developed and slowly flowing blood corpuscles could be identified even in the main branches of the artery. At this stadium, blood flow ceased here and there in the arterioles, and the capillaries sometimes contained and sometimes did not contained blood corpuscles. Blood flow ceased in the capillaries and the flow was irregular. In the venules, blood flow could be hardly observed with constrictions here and there, blood component being left between the adjoining constricted sites. At late stadium, reverse flow occurred in the arterioles, and simultaneously with stasis of blood flow contraction occurred leading animals to death.

At the stadium of haemorrhagia per rhexin, observation was also carried out on the intestinal loop within the abdominal cavity, kept away from the immediate effect of trypsin. Arterial blood flow was similarly retarded as in the intestinal wall in the vessel of the apparatus, showing sludgy finding in the peripheral part with slight contraction of the arteries. Although stasis of blood flow was observed, constriction could not be observed as was in the intestinal wall in the observation apparatus. Hemorrhage and mural thrombosis also could not be found.

To summarize these findings, six animals out of eight died during the study and remaining 2 survived for more than 2 hours. The degree of vasoconstriction was 20 to 30 per cent, with the exception of late stadium immediately before the death. However, the vessels showed a tendency of dilatation after the vasoconstriction which occurred immediately after the perfusion with trypsin solution in the vessel of the apparatus, and blood flow was maintained well. In all cases, findings such as stasis of blood flow in the venules, retardation of blood flow, hemorrhage, sticking of leucocytes and remarkable edema were observed (Tab. 9, Fig. 12).

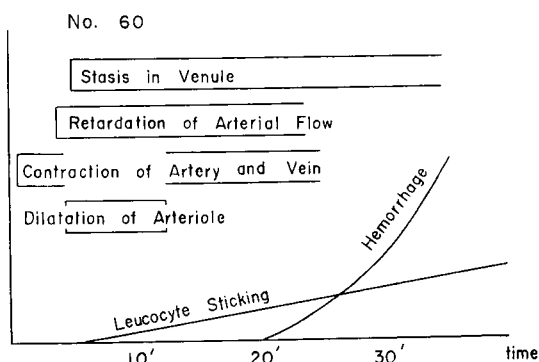


Fig. 12 Principal Findings of Peripheral Circulatory Disturbance in the Intestinal Wall of Mice with Local Perfusion of Trypsin Solution

7. Alteration of Vascular Permeability Caused by Trypsin

Simultaneously with or after trypsin injection in the tail vein, India ink, Evans blue, Pontamine sky blue or Trypan blue was injected in the tail vein and alteration of vascular permeability in the intestinal wall was studied.

Five to ten minutes after the injection of trypsin of 0.10 mg/10 g body weight in the tail vein, 0.1 cc of India ink was injected in the tail vein. Particles of India ink passed through the arterioles and capillaries and they were found on the wall of the venules, particularly in their bifurcations, which was not observed in control study of saline injection (Photo. 7, 8).

Simultaneously with the injection of trypsin of 0.05 and 0.10 mg/10 g body weight, 0.1 cc of 0.25 per cent Evans blue solution was injected in the tail vein. Within 7 min-

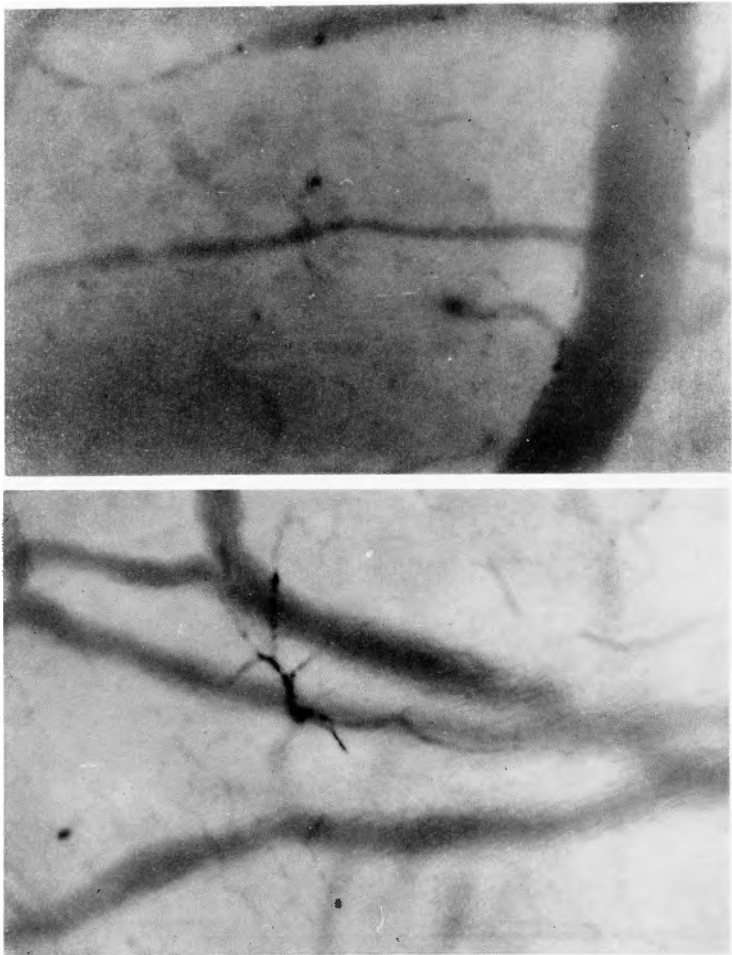


Photo. 7. and 8. Particle of India Ink on the Wall of the Venules Observed after Injection of Trypsin and India Ink in the Tail Vein (100×)

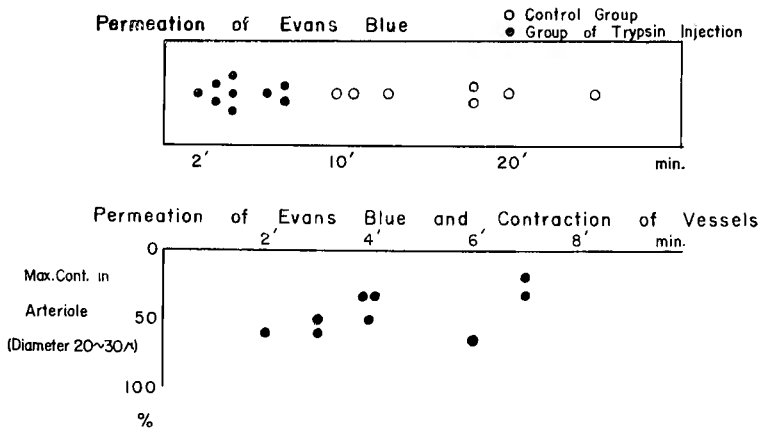


Fig. 13 Alteration of Vascular Permeability in the Intestinal Wall of Mice after Injection of Trypsin

Table 10. Change in Vascular Permeability in the Intestinal Wall of Mice after Injection of 0.25% Evans Blue and Trypsin

Mouse No.	0.25% Evans blue cc	Trypsin mg/10g	Permeation of Evans Blue min.	Max. Cont. Rate in 20~30 μ Arteriole %	Outcome
Control Group					
124	0.1	—	10	—	Survival
125	0.1	—	18	—	Survival
126	0.1	—	11	—	Survival
127	0.1	—	13	—	Survival
128	0.1	—	18	—	Survival
129	0.1	—	20	—	Survival
130	0.1	—	25	—	Survival
Group of Trypsin Injection					
134	0.1	0.05	7	30	Survival
135	0.1	0.05	4	30	Survival
131	0.1	0.10	3	60	Death
132	0.1	0.10	4	50	Death
133	0.1	0.10	2	60	Death
136	0.1	0.10	3	50	Survival
137	0.1	0.10	6	70	Survival
138	0.1	0.10	7	20	Survival
139	0.1	0.10	4	30	Survival

utes of relatively early period, liberation of pigment was observed around the venules in all cases, which, however, required at earliest more than 10 minutes in control animals with Evans blue injection alone (Tab. 10, Fig. 13).

From the findings of the examination with other dyes also, increase in permeability of the vessels could be ascertained.

8. Histological Findings

Trypsin of 25 mg in total amount was infused dropwise in rabbits weighing 2 kg in the auricular vein. Twenty-four hours later, histological studies were carried out on the cardiac and skeletal muscles and the liver. Focal necrosis was found in the skeletal muscle, that is, transverse striation of the muscle fibres disappeared and acidophilic and amorphous circumscribed small focus was recognized together with the infiltration of monocytes, eosinophilic granulocytes and a small number of neutrophilic granulocytes. In other tissues obvious change could not be found (Photo. 9).

Histological study on the intestine, microcirculation of which had been observed for an hour after perfusion with 0.25 per cent trypsin solution of 37°C in the basin of the apparatus, revealed marked edema and hemorrhage, and the part of intestinal tissue that was not covered with cover glass showed finding of necrosis (Photo. 10, 11).

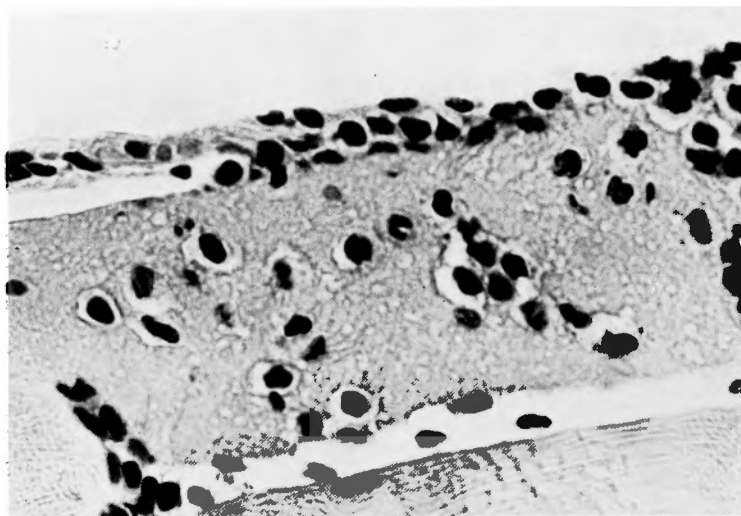


Photo. 9. Focal Necrosis in the Skeletal Muscle 24 Hours after Administration of Trypsin of 25 mg in Rabbit (H-E 400 \times)

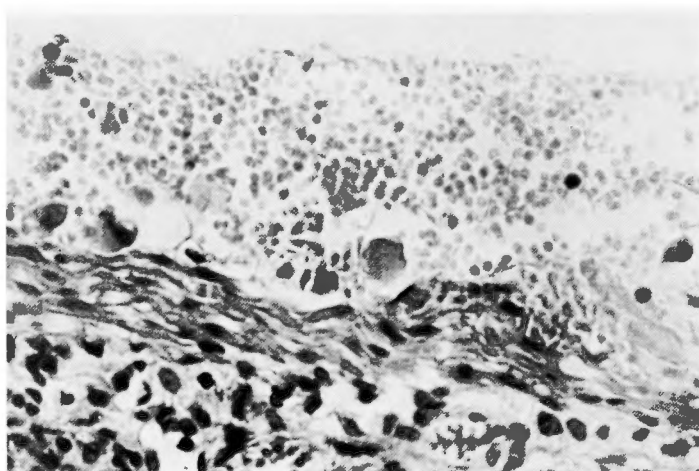


Photo. 10. Hemorrhage and Edema of the Intestinal Wall of Mouse after Perfusion with 0.25 % Trypsin Solution in Basin of Apparatus for Observation (H-E 400 \times)

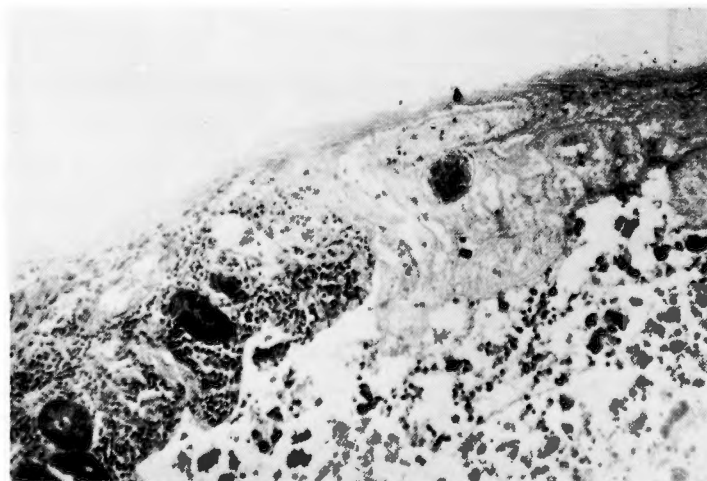

Photo. 11. Necrosis of the Intestinal Wall of Mouse after Perfusion with 0.25 % Trypsin Solution in Basin of Apparatus for Observation (H-E 100 \times)

Trypsin of 0.10 mg/10 g body weight was injected in the mesenteric vein in mice weighing 20 g, and 24 hours later fat staining was performed in the liver section.

Histological finding revealed slight increase in fat of the liver compared with control. However, obvious necrosis could not be observed.

V. DISCUSSION

Experimental studies on the influence of pancreatic enzymes, particularly of trypsin on the peripheral vessels has been carried out since early days. In 1910, NATUS⁴⁰⁾ observed circulatory disturbance such as vasodilation and hemorrhage in the pancreas following the ligation of the pancreatic duct, and ROSENBAACH⁴⁸⁾ observed dilatation of capillaries and hemorrhage following the injection of trypsin in the tongue of frog. KIRCHHEIM²⁶⁾, in 1911, observed local edema, hemorrhage and necrosis after subcutaneous injection of proteolytic pancreatic preparations and active pancreatic juice and demonstrated the toxicity of pancreatic juice. MIGAY and PETROFF³⁵⁾ studied the toxicity of pancreatic juice and its effect on arterial pressure and the vessels, and postulated that the descension of arterial pressure should be attributable to vasodilatation caused by the vasomotoric nerves. Toxicity of trypsin, particularly its effect on the circulatory system, has come to attract attention of researchers thereafter. GEISSENDÖRFER¹⁴⁾, in 1940, asserted that among trypsin, diastase and lipase, the first one has the activity on the peripheral vessels.

In the present experiment, descension of arterial pressure and elevation of portal pressure were observed following the administration of trypsin in rabbits in the auricular vein. Considerable decrease in circulating blood and plasma volumes could be also recognized. DOS REIS⁷⁾ also observed a decrease of 30 per cent in circulating blood volume in dogs of experimental pancreatitis. ROCHA E SILVA⁴⁵⁾⁴⁶⁾ studied the effect of crystalline trypsin on the circulatory system in cats, rabbits and dogs, observed marked fall of arterial pressure after the injection of trypsin. He reported that the observed symptoms closely resembled the shock of anaphylactic type and he postulated that this shock was caused by histamine liberating effect of trypsin from the tissues. In 1945, TAGNON⁴⁹⁾⁵⁰⁾ stated that prolongation of clotting time was observed after the injection of trypsin presumably being caused by decrease in fibrinogen and prothrombin, and that this fact has close connection with the trypsin shock. Moreover, TAYLOR and WRIGHT⁵²⁾ observed formation of blood clots within the heart of rabbits following the rapid intravenous injection of trypsin. They further observed local phlebothrombosis and cyanosis of the auricle by the infusion of trypsin of more large amount.

By many researchers⁹⁾¹⁰⁾¹²⁾¹⁸⁾⁴⁷⁾⁵⁵⁾, various substances such as kallikrein, bradykinin and kallidin have been investigated and it has been clarified that these substances have effect of vasodilatation³²⁾ on the peripheral vessels with resulting descension of blood pressure. From these facts, in recent years, it became to be considered that the cause of shock in acute pancreatitis consists in the activation of precursors of these substances in serum. In 1955, FORELL¹¹⁾ experimentally demonstrated that kallikreinogen in serum is activated by trypsin in serum to become kallikrein which is the cause of vasodilatation of peripheral vessels and descension of blood pressure. WERLE⁵⁶⁾ and others sought the mechanism of shock development in these substances and YOSHIOKA⁵⁸⁾ has also made the

same assertion. HOLLENBERG¹⁹⁾, THAL⁵³⁾ and others reported that large amount of vasoactive substances is liberated into serum at acute pancreatitis.

There have been numerous studies on microscopic observation^{4) 5) 6) 27) 28) 38)} on peripheral circulation in living organisms. The author of the present paper has succeeded in clarifying circulatory appearance in the intestinal wall and mesentery of mice and reassured the microcirculation unit and vasomotion as observed by CHAMBERS, ZWEIFACH and others. In the liver, marginal area of the left lobe was subjected to the observation in the present experiment. Although regulating mechanism of blood flow or periodic pause stadium in lobular unit as asserted by KNEISELY^{28) 29)}, WAKIM, MANN⁵⁴⁾ and others could not be identified, similar findings could be obtained as reported by NAGAI³⁵⁾, TAZAKA⁵¹⁾, FUJITA¹³⁾, NATANI³⁹⁾, ONO⁴²⁾ and others.

When trypsin as injected in the tail vein of mice, there occurred contraction in the vessels of the auricle and intestinal wall, which varied in degree in proportion to the amount of trypsin injected, showing sometimes so intense one as to brighten the entire microscopic view. As was observed by McMASTER and KRUSE³³⁾, ABELL and SCHENCK¹⁾, FUJITA¹³⁾, HARA¹⁷⁾ and others in anaphylactic shock, vasocontraction was so intense, and stasis of the blood flow and reverse flow were observed in the present experiment, but the contraction of the vessels was transient and did not occur repeatedly. Obvious diapedic hemorrhage and fibrinoid substance did not appear within the vessels. However, agglutination of erythrocytes was observed within the arterioles. It is noteworthy that in the present experiment similar finding could be obtained as strongly asserted by HARA that the vessels of the intestinal wall, and a part of the visceral vessels showed the same attitude at anaphylactic shock as the superficial vessels of the body.

After the injection of trypsin from the tail vein, retardation and stasis of blood flow, pendular movement of blood corpuscles and reverse flow were observed in the marginal area of the liver. At the same time, vasocontraction of the hepatic vessels was observed with macroscopic ischemia of the liver at an early stadium. Then, dilatation of the hepatic vessels could be observed in parallel with the recurrence of hepatic flow or improvement of the velocity of blood flow, which led to congestion of the liver. In many respects, these findings resemble those of dilatation and congestion of hepatic vessels at anaphylactic shock as observed by FUJITA. However, hepatic ischemia observed in the early stadium differs from the finding of anaphylactic shock and this rather resembles the finding of hepatic circulation at adrenaline injection carried out by McMICHAEL³⁴⁾, FUJITA and others. Although MAEGRAITH³¹⁾ and others reported about active constriction of the branches of the hepatic veins at anaphylactic shock in dogs, this could not be ascertained in the present experiment.

Following the injection of trypsin from the mesenteric vein or spleen, stasis and retardation of hepatic blood flow and contraction of the hepatic vessels were observed, the degree of which was more intense than after the injection in the tail vein, with marked ischemia in the liver and long persisting decrease in hepatic blood flow. FUJITA observed prolongation of continuance of vasocontraction in the liver following the injection of adrenaline in the spleen compared with the injection in the tail vein. ROCHA E SILVA also reported that following the injection of trypsin in the portal vein, duration of descension

of arterial pressure was prolonged compared with the injection in the femoral vein. NAKAGAWA³⁷⁾, in our clinic, observed more intense symptoms of lethal shock in dogs with acute pancreatitis, whose pancreas was fixed with sutures to the retroperitoneum around the abdominal aorta, when compared with the animals without fixation of the pancreas. From his observation, he reported that in this serious disease process the vasomotoric nerves may have important significance. On the other hand, it has been known since early days that irritation of the splanchnic nerve results in a decrease in the volume of the liver caused by peripheral ischemia and stasis of blood flow. Considering from the results of the experiment of the splanchnic nerve irritation carried out by GRIFFITH and EMERY¹⁶⁾ and from the observation of vasocontraction in the intestinal wall and liver following the administration of adrenaline made by McMICHAEL, FUJITA and others, existence of vasomotoric nerve reflex, including the splanchnic nerve reflex, induced by trypsin cannot be neglected in the findings of microcirculation in the intestinal wall and liver.

When trypsin was injected in the tail vein in the mice which received pretreatment of intramuscular injection of chlorpromazine as an autonomic nerve blocking agent with additional anesthesia with Isozol, retardation of blood flow could be observed in the intestinal wall simultaneously with slight contraction of the vessels, which was followed by dilatation of the arterioles and capillaries. Velocity of blood flow, once tended to restoration, retarded again and stasis of the blood flow was observed, vasodilatation and retardation of the flow being more intense than in animals with Isozol administration alone. In the liver, slight contraction of the vessels, retardation of blood flow and decrease in hepatic blood flow could be observed. Marked dilatation of the sinusoids was not observed following the injection of large amount of trypsin, and the reduction of the hepatic blood flow was not recognized.

FORELL stated that kallikreinogen in serum is activated by trypsin and caused vasodilatation and descension of blood pressure. It is, already known also that kallikrein, bradykinin and kallidin in serum are activated by trypsin or activated by each other with resulting dilatation of the vessels.

Intravenous injection of kallikrein in the tail vein in mice resulted in dilatation of the vessels in the intestinal wall and increase in velocity of blood flow which was followed by retardation of blood flow. In general, an increase in blood flow was observed including the capillary bed. In contrast to dilatation in the arterioles, the venules showed the tendency of contraction. As pointed out by IJIMA²³⁾, this change is assumed to be a compensatory one. In the late stadium of kallikrein effect, contraction was observed in the arterioles.

By the injection of rabbit serum alone, particular change could not be observed in the vessels and blood flow, whereas by the injection of rabbit serum containing trypsin of such a small dosis as having no influence on the microcirculation retardation of blood flow and vasodilatation of the arterioles were observed, without being accompanied with stasis of blood flow and hemagglutination.

Following the injection of kallikrein, vasodilatation and increase in hepatic blood flow could be observed. Any changes could not be found in the hepatic vessels and velocity of blood flow after the injection of rabbit serum alone, but the injection of rabbit serum

containing trypsin, as above mentioned, resulted in slight dilatation of the hepatic vessels, and retardation and decrease in hepatic blood flow. It is assumed that vasodilating substances in serum is activated by adding trypsin to the serum and peripheral circulatory disturbance occurred. This interpretation comes in accordance with the assertion of FORELL.

Studies on local effect of trypsin have been made by NATUS, ROSENBAACH, KIRCHHEIM and others, since early days. In the present experiment, microcirculation of the intestinal wall was studied in the vessel of the apparatus for the observation of microcirculation with perfusion of trypsin solution of 37°C. Slight contraction of the vessels could be observed which then turned to dilatation with resulting retardation of blood flow. Furthermore, stasis of the blood flow and development of mural thrombosis within the venules were observed and there occurred haemorrhagia per rhexin in the capillary bed.

These finding was somewhat different from those of local allergy asserted by IJIMA²²⁾, KAGEYAMA²⁴⁾ and others. In local allergy, they observed marked changes in leucocytes and diapedic hemorrhage in the initial stage, whereas in the changes induced by trypsin vasodilatation and haemorrhagia per rhexin was prevailing and it was interesting that these findings had rather resemblance to the changes induced by Habu toxin.

Studies on the alteration of vascular permeability were carried out with India ink, Evans blue and other dyes, injecting these dyes in the tail vein after the trypsin injection. An increase in permeability was observed in the venules. AMANO²³⁾ stated that the venules play an important role in the increase in permeability of the diseased vessels²⁷⁾, and HARA reported similar increase in permeability of the venules in anaphylactic shock. In the increase in vascular permeability caused by trypsin injection, important factors can be considered to be the changes in the vascular endothelial cells caused by trypsin, histamine liberated from the tissues and bradykinin in serum.

KELLNER and ROBERTSON²⁵⁾ observed focal necrosis in the cardiac and skeletal muscles of rabbits which received trypsin injection. Changes being found particularly in the active striated muscles, they presumed that the occurrence of focal necrosis in the muscles might be caused by the changes in metabolic process. In the present experiment also, focal necrosis was observed in the skeletal muscles of rabbits following intravenous infusion of trypsin solution. In recent years, DOS REIS²⁹⁾ reported that histological change could be observed in the cardiac muscle, liver, kidney and brain of dogs of acute pancreatitis and those with trypsin injection.

GOTTESMAN, CASTEN and BELLER¹⁵⁾ clinically observed electrocardiographic changes at acute pancreatitis, and LIEBERMAN³⁰⁾, POLLOCK⁴³⁾ and others reported occurrence of disturbance in the stimulation conducting system and abnormality of P, QRS, ST and T after administration of trypsin in rabbits and dogs. In the present experiment²⁰⁾, similar abnormality was observed in the findings of electrocardiogram.

VI. SUMMARY

As a part of studies on pathophysiology of acute pancreatitis, disturbance of peripheral circulation and histological changes of the organs caused by trypsin were investigated in rabbits and mice. By the injection of trypsin in rabbits, findings obtained were 1). descension of arterial pressure and elevation of portal pressure ; 2). decrease in circulating

blood volume and circulating plasma volume ; 3). occurrence of focal necrosis in the skeletal muscles.

Furthermore, circulation was studied microscopically on the auricle, intestinal wall and liver in living mice receiving trypsin injection, and obtained results are summarized as follows :

1. By the injection of trypsin in the tail vein, contraction of the vessels, retardation and stasis of blood flow and hemagglutination could be observed in the auricle and intestinal wall. In the liver, there developed ischemia which was followed by dilatation of the hepatic vessels.

2. Following the injection of trypsin in the portal system, vasocontraction was more intense in the liver compared with that after the injection in the tail vein, and long persisting hepatic ischemia was observed.

3. When trypsin was injected in the tail vein with chlorpromazine administration, slight contraction was observed in the arteries of the intestinal wall, which was followed by slight dilatation of the arterioles and retardation of blood flow. In the liver, the findings were similar to the animals without administration of chlorpromazine, vasodilatation, however, being deprived of, disturbance in hepatic circulation being generally in a slight degree.

4. Injection of rabbit serum containing trypsin of such a small dosis as having no influence on microcirculation resulted in vasodilatation and retardation of blood flow in the intestinal wall and liver, which could not be observed in animals with rabbit serum injection alone. Blood flow also decreased in the liver.

5. By the local administration of trypsin on the intestinal wall, vasodilatation, hemorrhage, mural thrombosis and edema could be observed.

6. Vascular permeability was increased by the injection of trypsin in the tail vein.

In the results of the present experiment, it is noticable that trypsin affects seriously not only peripheral circulation of the entire body, but also hepatic circulation, particularly when administered in the portal system. Furthermore, it is a noteworthy finding that serum which contains trypsin of such a small dosis as having no influence on microcirculation had activity to impair peripheral circulation seriously including that of the liver.

Accomplishing the present paper, the author expresses his greatest gratitude to Prof. Dr. Ichio Honyo for his encouraging guidances and valuable advices. The author is also grateful to Dr. MIYAZAKI and the member of our clinic for their kind helps.

VII. REFERENCES

- 1) Abell, R. G. and Schenck, H. P. : Microscopic observations on the behavior of living blood vessels of the rabbit during the reaction of anaphylaxis. *J. Immunol.*, **34** : 195, 1938.
- ※2) Amano, C. Diapedic Hemorrhage. (Hemorrhage from the venule.) *Symposium on Hematology*, **4** : 195, 1951.
- ※3) Amano, C. et al : Microcirculation. *Saishin-Igaku*, **18** : 1441, 1963.
- 4) Chambers, R. and Zweifach, B. W. : Topography and function of the mesenteric capillary circulation. *Am. J. Anat.*, **75** : 173, 1944.
- 5) Chambers, R. and Zweifach, B. W. : Blood-borne vasotropic substances in experimental shock. *Am. J. Physiol.*, **150** : 239, 1947.
- 6) Chambers, R., Zweifach, B. W. and Lee, R. E. : Vaso-excitor and -depressor substances as "toxic" factors in

- experimentally induced shock. *Proc. Soc. Exp. Biol. & Med.*, **56** : 127, 1941.
- 7) Dos Reis, L. : Importance of blood volume changes in acute pancreatitis. *Am. Surg.*, **29** : 605, 1963.
 - 8) Dos Reis, L. : Visceral lesions in acute pancreatitis. *Arch. Surg.*, **87** : 604, 1963.
 - 9) Elliot, D. F., Horton, E. W. & Lewis, G. P. : Isolation of bradykinin. *Biochem. J.*, **78** : 60, 1961.
 - 10) Elliot, D. F., Horton, E. W. & Lewis, G. P. : Actions of pure bradykinin. *J. Physiol.*, **153** : 473, 1960.
 - 11) Forell, M. M. : Zur Frage des Entstehungsmechanismus des Kreislaufkollapses bei der akuten Pankreasnekrose. *Gastroenterologia*, **84** : 225, 1955.
 - 12) Fox, R. H., Goldsmith, R., Kidd, D. J. & Lewis, G. P. : Bradykinin as a vasodilator in man. *J. Physiol.*, **157** : 589, 1961.
 - ※13) Fujita, T. : Study on microscopical observation of hepatic circulation in situ about mice-liver. *J. J. S. S.*, **61** : 589, 1960.
 - 14) Geissendörfer, H. H. : Untersuchungen über die Wirkung von parenteral zugeführten Bauchspeichel. Zugleich ein Beitrag zur Bedeutung der Fermententgleisung bei akuter Bauchspeicheldrüsennekrose. *Arch. Klin. Chir.*, **198** : 321, 1940.
 - 15) Gottesman, J., Casten, D. and Beller, A. J. : Changes in the electrocardiogram induced by acute pancreatitis. *J. A. M. A.*, **123** : 892, 1943.
 - 16) Griffith, F. R. and Emery, F. E. : The vasomotor control of the liver circulation. *Am. J. Physiol.*, **95** : 20, 1930.
 - ※17) Hara, K. : Circulatory changes at intestinal wall of living mice at anaphylactic shock. *J. Osaka Med. Coll.*, **16** : 74, 1955.
 - 18) Hilton, S. M. and Lewis, G. P. : Mechanism of the functional hyperemia in the submandibular salivary gland. *J. Physiol.*, **129** : 253, 1955.
 - 19) Hollenberg, M. J., Watanabe, N., Prvett, R. and Thal, A. P. : Liberation of vasoactive materials in acute pancreatitis. *Fed. Proc.*, **21** : 266, 1962.
 - ※20) Honjo, I. et al : Symposium on pancreatitis. 16th Gen. Ass. Jap. Med. Cong., 1963.
 - 21) Howard, J. M., Smith, A. K. and Peters, J. J. : Acute pancreatitis : Pathways of enzymes into the blood stream. *Surg.*, **26** : 161, 1949.
 - 22) Iijima, S. : Durchblutungsstörungen an Kaninchenohr bei allgemeiner und lokaler Anaphylaxie mit intravitralen Photogrammen. *Beitr. Path. Anat.*, **118** : 67, 1957.
 - ※23) Iijima, S. : Pathophysiology of microcirculation. *Suishin-Igaku*, **18** : 1470, 1963.
 - ※24) Kageyama, K. : Dynamic pathologic observations of microcirculatory disturbances. *Suishin-Igaku*, **18** : 1448, 1963.
 - 25) Kellner, A. and Robertson, T. : Selective necrosis of cardiac and skeletal muscle induced experimentally by means of proteolytic enzyme solutions given intravenously. *J. Exp. Med.*, **99** : 387, 1954.
 - 26) Kirchheim, L. : Über die Giftwirkung des Trypsins und seine Fähigkeit, lebendes Gewebe zu verdauen. *Arch. Exp. Path. Pharmacol.*, **66** : 352, 1911.
 - 27) Knisely, M. H. : A method of illuminating living structures for microscopic study. *Anat. Rec.*, **64** : 499, 1936.
 - 28) Knisely, M. H. : Microscopic observations of the circulatory conditions in living frog liver lobules. *Anat. Rec.*, **73** (Supplement 2) : 69, 1939.
 - 29) Knisely, M. H., Harding, F. and Debacker, H. : Hepatic sphincters. *Science*, **125** : 1023, 1957.
 - 30) Lieberman, J. S., Taylor, A. and Wright, I. S. : The effect of intravenous trypsin administration on the electrocardiogram of the rabbit. *Circulation*, **10** : 338, 1954.
 - 31) Macgrath, B. G., Adelaide, M. B., Horner, W. H. and Wenyon, C. E. M. : Active constriction of hepatic venous tree in anaphylactic shock. Relation to centerlobular lesions. *Lancet* July-Dec., **257** : 56, 1949.
 - ※32) Matsubara, I. : Bradykinin. -A Hormone Regulating Local Circulation. *Igaku no Ayumi*, **41** : 353, 1962.
 - 33) McMaster, P. D. and Kruse, H. : Peripheral vascular reactions in anaphylaxis of the mouse. *J. Exp. Med.*, **89** : 583, 1914.
 - 34) McMichael J. : The portal circulation. *J. Physiol.*, **75** : 241, 1932.
 - 35) Migay, T. I. und Petroff, J. R. : Untersuchungen über die Wirkung des Pankreassaftes auf den Organismus bei parenteraler Einführung. *Zeitschrift F. D. Gesamte Exp. Med.*, **36** : 457, 1923.
 - ※36) Nagai, S. : Microscopical observation in vivo about mouse's liver. *Jap. J. Constitutional Med.*, **19** : 95, 1951.
 - ※37) Nakagawa, T. : Personal communication.
 - ※38) Nakata, K. : Intravital observations of the splenic circulation. Symposium on Hematology, **7** : 36, 1954.

- ※(39) Natani, K. et al : Some contributions to the intravital microscopic observations of the mouse's liver. About the relation between the blood flow in the hepatic lobulus and Kupffer's cell and the speed of the capillary blood flow in it. *Jap. J. Constitutional Med.*, **22** : 161, 1957.
- 40) Natus, M. : Versuch einer Theorie der chronischen Entzündung auf Grund von Beobachtungen am Pankreas des lebenden Kaninchens und von histologischen Untersuchungen nach Unterbindung des Ausführungsganges. *Virch. Arch. Path. Anat. Physiol. Klin. Med.*, **202** : 417, 1910.
- 41) Nitta, T. : Attitude of trypsin in experimental acute pancreatitis. *Arch. Jap. Chir.*, **33** : 703, 1964.
- ※(42) Ono, K. : Microscopical observation on the liver of the living mice treated with various medicines. 1. On the normal case and the case of injected dye. *J. J. S. I. M.*, **45** : 1234, 1957.
- 43) Pollock, A. V. and Bertrand, C. A. : Electrocardiographic changes in acute pancreatitis. *Surg.*, **40** : 951, 1956.
- 44) Popper, H. L. and Necheles, H. : Pathways of enzymes into the blood in acute damage of the pancreas. *Proc. Soc. Exp. Biol. & Med.*, **43** : 220, 1940.
- 45) Rocha e Silva, M. : Beiträge zur Pharmakologie des Trypsins. II. Wirkung des Trypsins auf den Blutkreislauf bei Katze, Kaninchen und Hund. *Arch. Exp. Path. Pharmacol.*, **194** : 351, 1940.
- 46) Rocha e Silva, M. : The histamine theory of anaphylactic shock with special reference to anaphylaxis in the rabbit. *Arch. Path.*, **33** : 387, 1942.
- 47) Rocha e Silva, M., Beraldo, W. T. and Rosenfeld, G. : Bradykinin a hypotensive and smooth muscle stimulating factor released from plasma globulin by snake venoms and by trypsin. *Am. J. Physiol.*, **156** : 261, 1949.
- 48) Rosenbach, J. : Experimenteller Beitrag zur Wirkung des Trypsins auf die Gefäße. *Arch. Klin. Chir.*, **93** : 279, 1910.
- 49) Tagnon, H. J. : The nature of the mechanism of the shock produced by the injection of trypsin and thrombin. *J. Clin. Invest.*, **24** : 1, 1945.
- 50) Tagnon, H. J., Weinglass, A. R. and Goodpastor, W. E. : The nature and mechanism of shock produced by the intravenous injection of chymotrypsin. *Am. J. Physiol.*, **143** : 644, 1945.
- ※(51) Tasaka, S. et al : Intravital microscopic observation of the intrahepatic circulation of blood. *Medicine*, **13** : 632, 1956.
- 52) Taylor, A. and Wright, I. S. : Intravenous trypsin. *Circulation*, **10** : 331, 1954.
- 53) Thal, A. P., Kobold, E. E. and Hollenberg, M. J. : The release of vasoactive substances in acute pancreatitis. *Am. J. Surg.*, **105** : 708, 1963.
- 54) Wakim, K. G. and Mann, F. C. : The intrahepatic circulation of blood. *Anat. Rec.*, **82** : 233, 1942.
- 55) Werle, E. and Roden, P. : Über das vorkommen von Kallikrein in den Speicheldrüsen und im Mundspeichel. *Biochem. Z.*, **286** : 213, 1936.
- 56) Werle, E., Tauber, K., Hartenbach, W. und Forell, M. M. : Zur Frage der Therapie der Pankreatitis. *Münch. Med. Woch.*, **100** : 1265, 1958.
- ※(57) Yasuhira, K. and Yamamoto, K. : Abnormal permeability of vessels. Symposium on Hematology, **3** : 160, 1950.
- ※(58) Yoshioka, H. : *Pancreas. Surg. Ther.*, **3** : 654, 1960. (※ in Japanese)

和 文 抄 録

Trypsinの末梢循環に及ぼす影響について

金沢大学医学部第2外科教室（主任：本庄一夫教授）

木 南 義 男

急性膵炎時、Trypsinを含め膵酵素が膵臓より逸脱し急性膵炎の予後に重大なる影響を及ぼす事は明らかであるが、此等の酵素中特に Trypsin の循環系に及ぼす障害は古くから研究されて来た。然るに Trypsin 投与による生体の末梢血管の態度特に microcirculation に関する系統的研究は余り知られておらず内臓循環、特に肝臓循環に関しては明らかでない。そこで透過光方式の生体顕微鏡を使用し、Trypsin の microcirculation に与える影響を検討した。

マウスに Trypsin を投与し耳翼、腸壁、肝臓の循環障害を観察し次の結果を得た。

(1) Trypsin の尾静脈注射により耳翼、腸壁血管は収縮し血流速度の緩徐化、停止、血球凝集等を生じ、肝臓では肝貧血に続き肝血管拡張を見た。

(2) Trypsin を門脈系に投与すると尾静脈投与時より著しい肝血管収縮を認め持続的肝貧血を見た。

(3) Chlorpromazine投与群に於ける Trypsin 尾静脈注射では、腸壁血管は最初の軽度な動脈性血管収縮について細動脈拡張と血流の緩徐化を生じ、肝臓では

Chlorpromazine 無投与の場合とほぼ同様の所見を呈したが著しい血管拡張は見られず肝臓循環の障害は全般的に軽度であつた。

(4) microcirculation に影響を及ぼさぬ少量の Trypsin を含む家兎血清のマウス尾静脈注射では、家兎血清単独注射で変化を生じなかつたマウスの腸壁及び肝臓血管の拡張と血流の緩徐化を生じ、肝血流量の減少を見た。

(5) 腸壁血管に対する Trypsin の局所投与により血管拡張、出血、mural thrombosis等を観察した。

(6) Trypsin の尾静脈注射により血管壁の透過性の亢進を生じた。

以上の実験成績より、Trypsin は全身の末梢循環障害を生じ、特に Trypsin が門脈系に投与された際には著しい肝臓循環障害を生じた点が注目された。又 microcirculation に影響を及ぼさぬ少量の Trypsin を含む血清は肝臓循環を含め末梢循環に明らかな循環障害を起こした。