

FURTHER STUDY ON THE USE OF EHRlich METHOD IN STUDIES OF THE NERVOUS SYSTEM WITH SPECIAL REFERENCE TO DEGENERATING NEURONES*

TETSUO FUKUDA, M. D., D. Sc. (Med.) **

Laboratory of Malcolm Bliss Psychiatric Hospital, Department of Neuropsychiatry,
Washington University School of Medicine, St. Louis, Missouri.

(Received for publication: Apr. 14, 1958)

A series of experimental observations here to follow were undertaken in order to determine whether the EHRlich method, somewhat modified recently and yielded a reasonable contention with respects to intact neurones of the central nervous system (CNS), can as well be applicable to degenerating neurones. Since it was felt necessary to have more evidence systematically worked out in order to arrive at decisive conclusion (FUKUDA, 1957), efforts have been exercised in making the present report reasonably complete. As result, it will be seen that an over-all view point has also been attained on the problem which had so far been unsuccessfully challenged (CAJAL, 1928; ANDO, 1957).

MATERIAL AND PROCEDURE

Adult albino rats with descriptions given previously served as the principal materials during this study. The total of rats used counted 120. A few of dogs, guinea pigs, kittens and rabbits, all aging between 1~4 months, were also available; they furnished supplementary materials upon confirming results obtained on rats. Operative procedure: Inasmuch as the vascular damages as consequence of operation appeared to be a potentially significant factor that gave rise to the inconclusive data as previously shown, attempt was made to avoid gross bleeding noticeable during and following operative manipulations. The procedure described by SPERRY (1956, 1957) was applied for this purpose. Practically, animals under light anesthesia were approached at lateral canthus. Using a sharp scissors of small size, connective tissues thereabout were carefully dissected so as to produce a small hole through which optic nerve can be brought into the sight. With the aid of gentle pull of eyeball outward using forceps, optic nerve was solely cut at the neck where it runs into eyeball. The eyeballs so treated were usually left *in situ* thereafter. After a few of preliminary practices, the whole procedure was complete in a matter of few minutes whereby only oozing kind of cutaneous bleeding was appreciable. To some of rats, removal of unilateral eyes as done previously were per-

* This study was aided in part by funds from "Institute of Medical Education and Research", St. Louis, Missouri.

** Present address: Department of Physiology and Pharmacology, Graduate School of Medicine, University of Pennsylvania, Philadelphia, Pennsylvania.

formed and some were prepared for the control of the histological outcome of such a manipulation as "pulling of eyeball outward".

Both aseptic and antiseptic precautions, as well as postoperative cares were taken according to the manner described elsewhere (FUKUDA, STERN and ULETT, 1957).

Subsequent steps for histological preparations were essentially the same as before and will not be therefore repeated here. Instead, an account of cautions which appeared to be of importance as learned during early stage of this study will be here described.

1. Dyes: In addition to "methylene blue chloride" (Merck), "Azur A" ("Methylene Azur"; "Azur 1"; Harleco) and "Pure methylene blue" (Burroughs Wellcome and Co.) were also employed. 2.5% solutions of each stain in physiological saline solution were usually kept overnight at 40°~50°C. They were filtered before use. The pH was usually found around 9.0 with variation of 0.5 at the time of injection.

2. Injection: Needles of smaller calibre (size 20~22) were preferred. This eliminated sudden infusion of the dye at excessive pressure into CNS via the arterial circulation which seemed to be responsible for the appearance of perivascular neurones with questionable disintegration encountered often with larger needles.

Of critical importance further was the time when injection was to be discontinued. Up to 3 seconds was allowed to keep injecting as timed following the last breath. By this manner, unpleasant by-staining of non-specific tissues could be avoided almost exclusively.

3. Removal and preparation of tissues before fixation: This step is also of considerable importance. A variety of artifacts, resulting in equivocal outcome and disturbing hence the final evaluation, could be produced at this stage alone, largely if not exclusively on account of the obvious fact that the tissue is as yet unfixed and highly vulnerable to practically unlimited number of extraneous factors. Areas containing the lesion should therefore be protected with utmost cares, particularly when material was to cut into smaller blocks prior to dye-fixation in ammonium molybdate.

4. Fixation for the dye: This was better performed in refrigerator at 4°C for 2~6 hours according to the thickness of each block. A prolonged treatment in the ammonium molybdate often appears to extract some of the dye for unknown reasons, while shorter fixation results in unpleasant pallor of deep structure on account of insufficient penetration of the reagent known to diffuse very slowly.

5. Dehydration and clearing: The alcohols have been exclusively discarded for the reason that they dissolve the dyes away. Slides were instead dried at room temperature in the air, carefully avoiding extreme exsiccation. Direct immersion into xylol is then followed for the clearing.

Sections were cut both frontally and sagittally in the light of suggestion made by some worker (see, GLEES, 1941) though no significant difference was appreciable on result. Upon frozen sections, alternate sections were taken as serial as possible

in order to counter-stain with the classical Sudan IV method for the fat (HERXHEIMER, 1903). Cautions here to take are to pass through the media containing alcohol as rapidly as possible and to cool off the mounting media, glycerin-jelly, down to 40~50°C upon use.

For comparative purposes which will be discussed later, both silver impregnation of NAUTA (1957) and Nissl stain were employed.

RESULTS

The Methylene Blue Preparation :

By virtue perhaps of some technical development above mentioned, reasonably uniform results were obtained.

In as early as 24 hours subsequent to the operation, characteristic disintegrations of degenerating fibers were detectable in the expected areas whereby fibers of finer calibre were predominantly involved. As the days lapsed, gradual development of disintegrating features was added by the involvement of large fibers. As was the case of limited number of slides previously presented, these features were in a full presentation with materials of 3-7 days postoperative. Characteristics of the disintegration can best be described in detail by the photographs attached at the end and will not intend here to reiterate; they are available elsewhere in reasonable abundance (FEINDEL et al., 1948; HILLARP, 1946; FUKUDA, 1953, 1957; ANDO, 1956; WEDDEL et al., 1942).

Striking features were however caught on the nerve cells of the affected area, i. e., of lateral geniculate. Their cell bodies including dendritic processes displayed morphological changes distinct from controls namely those of other areas of same sections and of those obtained from control materials. They showed irregular outlines of structures, some swollen and others shrunk, gross distortion of dendritic processes, evenly intense dark-blue coloring of cell bodies where nuclei were lacking, dislocated or no longer recognizable, while some showed unusually uneven staining of cytoplasm revealing particulates of various size associated with wholesome irregularity of structural images.

Such features became augmented at the presence of disintegrating terminal axons so as to portray what may be simply expressed as "disintegration of neurone", an expression that will be used hereafter in contrast with those of respective elements, namely, cell body and fiber of neurone.

Examinations of slides for controls of one sense or another as previously designated, have so far failed to indicate that such disintegration of neurone is products of artifact. It should be in this connection pointed out that intact neurones occasionally stain intensively dark as well as faintly blue or green, even associated with the presence of tortuous axons, but, none of them to date have been observed to demonstrate simultaneously the irregularity and unevenness described above.

The disintegration of neurone was observed constantly in materials starting 3 days up to 50 days of postoperative intervals, regardless of type of the stains used.

Neurones so disintegrated showed progressive tendency toward shrinkage and

fragmentations to disappearance with the dendritic processes as the most vulnerable.

Identical results were secured on the aforementioned mammalia other than rat. With slight variations of time intervals, they yielded the morphological identity essentially similar to the preceding descriptions. Although these results were brought forth by all of the 3 stains hereby tested, Azur A showed advantages both in number of neurones stained and methylene blue Merck and pure methylene blue followed the order. Likewise, tendency of metachromasia was noticed to be of the same order. Again the metachromasia showed hardly distinct regularity in bringing about degenerating neurones alone, though it was, if occurred, more predominant on the pathologic elements.

Counterstaining for the fat: The counterstain was applied exclusively on rats, for they provide alternate sections of adequate size in handling. When conditions were adequate, this procedure did not appear to interfere the original blue coloring, though accompanied occasionally by tendencies to fade. Around 3 weeks of postoperative days, unmistakable appearance of the fat droplets was encountered. Result, however, was far from the expectation; they had no regularity of topographical localization with respects to degenerating axon despite reasonable number of trials, spreading widely around neurones with or without close relationship with the axons. The distribution of the fat particles, however, appeared to be about in lieu of the myelin figure of the region. Since control slides, namely the fat stain alone, also revealed more or less identical feature it might have been due in part to the strain specificity including behavior of CNS as a whole under certain experimental condition such as the one here employed. It was felt nonetheless that the procedure should be tested on different species under similar condition as will be taken up later.

The Silver Preparation:

With materials of prolonged fixation for 5~8 months, result in major accord with the original author's was obtained without difficulty, indicating hence that the technique has now launched into a realm of reasonable safety. Not mentioned here will be of the characteristics of degenerating axons disposed to the silver impregnation, by taking liberty of referring to the detailed descriptions given by the original worker who deserves the merit of it (GLEES and NAUTA, 1955; NAUTA, 1957). Such characteristics were invariably observable in the expected areas. It is worth drawing attention that, although appearances were fairly identical, stained axons were far greater in number in case of the silver compared with those methylene-blue-stained, and that there seemed some discrepancy present between the two types of preparations with regards to minute images of degenerating axons of finer calibre, the silver showing more predominantly the tendency of fragmentation, while methylene blue preserving more vivid images of the degradation. As to the cellular aspects, the silver technique did not permit to provide even a near-by result of the methylene blue's.

Nissl Preparation:

Pathognomonic features including chromatolysis which nerve cells display under

identical experimental conditions are rather well known. Most, if not all, of such changes were constantly observed in the present preparation, being appreciable in 24 hours. Some of these cells closely resembled the methylene blue preparations regarding their overall images. Since such cellular changes observed were largely confined to rats brain, further analysis of such resemblance seemed to be warranted for a decisive conclusion. It was for this reason that observations were further made on peripheral autonomic ganglia of cat where the material was favored by the presence of a wealth of large sized neurones. In addition, counterstain for the fat was also tested at the same time for the reason mentioned above.

FURTHER EXPERIMENTAL OBSERVATION

Material and Procedure: Some 20 of adult cats weighing 2.5~4.0 kg were anesthetized by intraperitoneal injection of Sodium Pentothal (Nembutal) 30 mg per kg. Cervical sympathetic trunks were unilaterally cut at 1.5~2.0 cm below superior cervical ganglia, removing away about 1 cm of the length to prevent the reinnervation. These animals developed invariably typical denervation syndrome unilaterally including that of nictitating membrane (see, CANNON and ROSENBLUETH, 1949). Here again, gross hemorrhage was avoided and in fact it was done easily on account of topographical arrangement of the elements concerned in this region.

At various stage of postoperative intervals, about 2~5 cc of the dye-solution was given to death through the common carotid artery of the side denervated. The superior cervical ganglia with some length of pre- and postganglionic trunks were carefully removed. By virtue of their size, they were able to be fixed *in toto* subsequently. Longitudinal sections were cut in 5μ to 60μ as serial again as possible for both cytological purposes and counterstaining for the fat. Equivalent materials were prepared for Nissl stain.

Result: Superior cervical ganglia contains the largest size of ganglial cells (see De CASTRO, 1951). They began to disclose morphological disintegrations in 24 hours. With methylene blue preparation, neurones became swollen or shrunk with a strong tendency of nuclear shrinkage as well as displacement and of faint outlining of cytoplasmic boundary associated with irregular outlook of individual neurones, some stained intensively and others faintly. The features advanced progressively throughout ganglia till most of neurones were identified only by the presence of enormously shrunk nuclei with variety of dislocation, at the presence or absence of fragmented cytoplasm. With combination of disintegrating terminal axons, whole picture resembled closely the images of disintegration of neurons seen in CNS.

As expected, development of these characteristics was somewhat rapider than in case of the secondary degeneration.

Nissl preparation showed again indications of some pertinent parallelism between the pathology of Nissl substances as contrasted with the cellular features of the methylene blue's.

The fat stain in this case was more resultful: Starting 2 weeks after denervation, both pre- and postganglionic trunks displayed fibres of varied size to bear

positive fat-particles or droplets. They were constantly seen in red color along or on top of the fibers, coexistent thus, if conditions were favorable, with characteristics of degenerating axons visible in blue color. Intraganglionic fibers similarly showed the product of demyelinating processes with slight delay in appearing than in case of postganglionic fibers. The fat stain kept positive thereafter up to about 5th week of the postoperative course.

DISCUSSION

A series of data thus far presented seems to be reasonably conclusive to indicate that the intraarterial methylene blue can be as well applicable to degenerating neurones of CNS as it is to intact neurones and that the CAJAL's statement previously quoted can be no longer acceptable therefore without qualifications.

On technical aspects: As indicated by a diversity of modifications developed according to the individuals' views as much as experiences (see ANDO, 1956; DOGIEL, 1924; HILLARP, 1946; SCHABADAÖCH, 1930; HELLER, et al., 1947), essential part of the procedure that matters in securing consistent result with high reproducibility is largely dependent at the moment on the vital to supravital processes of tissue which must be properly caught by the dye of adequate amount. It follows that the success or failure is as yet beyond the control of an objective satisfaction. While such unfortunate aspect of the procedure has given ways to an attitude, surprisingly wide-spread, regarding the technique to be capricious, the fact otherwise indicates in reality that the empiricism due to the aspect can, if properly worked out, be of no less value in attaining works of high objective level (see WOOLLARD, et al., 1940; POLYAK, 1941; CAJAL, 1896; HILLARP, 1946). Under the circumstances, it may be claimed with humility that the methylene blue technique thus far developed can be useful as an analytic stain for degenerating neurones of CNS, hence of the entire nervous system, in the sense equal to that for intact neurones as described in the recent paper.

On the counterstain: The application and result of the counterstaining appears, while as yet leaving more to be desired with respects to the retrograde degeneration, to extend scope of the technique and point to a suggestion that it should be useful for studies, for instance, on experimental demyelination in exposing simultaneous behavior of both axon and myelin sheath at various stage of demyelinating process, the aspect remaining relatively unexplored hitherto. It may as well be of some value in this connection to add here that the methylene blue procedure can now be considered as a partial inactivator of the acetylcholinesterase as determined by both WARBURG analysis and histochemical technique (FUKUDA and KOELLE, 1958a; 1958b), which as result has made possible a detailed analysis of histologic-histochemical aspects of cholinergic neurones, the histochemical procedure for the enzyme being used as a counterstain.

On the discrepancy between the silver and the methylene blue: It seems to be beyond controversy that the silver is capable of bringing forth degenerating axons in greater number possibly more consistently at least in the brain, whereas methy-

lene blue is capable of disclosing delicate details of such degenerating axons. As witnessed by the reports so far available in reasonable number (ANDO, 1956; FEINDEL et al., 1948; HILLARP, 1946; FUKUDA, 1953; WEDDELL and GLEES, 1941), the methylene blue has been known to be capable of revealing vital morphology of neurones to a higher degree than any other classical stains hitherto available. Such would account for the constant detection during this study of various stage of degenerating axons by methylene blue preparations for prolonged period following the denervation even up to 15 days, whereas they were shown to be of much shorter life with the silver impregnation, both being spoken of intraganglionic fibers (see DE CASTRO, 1951). Decisive answer to the point however remains to be seen.

On the features of cellular degeneration: Description of the cellular features above shown is unusually scanty of literature, except the one given by FEINDEL and his colleagues where somewhat disintegrated cells were described (1948): At any rate, the vivid images constantly caught on intact nerve cells should expect some kind of disintegrative features as reflection of vital processes under experimental condition like denervation. A convincing witness is no doubt the NISSL preparations, for it is NISSL substances, the basophilic component of cytoplasm rich of nucleic acid, being constituted of so called 'endoplasmic reticulum' (PALADE, 1956) where protein synthesis is being taken place (BRACHET, 1957; PALAY and PALADE, 1955; PORTER, 1953) and the fall of the synthesis subsequent to denervation is reflected microscopically on the variety of pathology including chromatolysis noticeable on the NISSL bodies (see, HYDEN, 1943; 1947; BODIAN, 1947). On the other hand, the appearance of resting neurones stained with methylene blue corresponds, on account probably of its being one of the basic dyes, to the relative amount of nucleic acid present in nucleus and cytoplasm respectively, nucleus being by far richer hence stained more intensively as shown regularly (see, BRACHET, 1945; DOUNCE, 1955; HOGBOOM and SCHNEIDER, 1955): In addition, while the faintly-blue staining evenly spread throughout remainder of cytoplasm may be due partly to the vacuole formations *in vivo* named 'crinome' as result of reciprocal actions between the dye and the basophilic substance (CHLOPIN, 1927; DUSTIN, 1947), such cellular interactions may be at least to some extent participated by mitochondria, another principal component of cytoplasm, for it is the mitochondria that is principally linked with respiratory enzyme system (see, CHANCE et al., 1955, BRACHET, 1957) to which the dye has been assigned to have potent affinity (see, GLICK, 1949; EHRlich, 1885; 1886; SCHABADASCH, 1935). Such views are in fact supported by that the dye has been used in demonstrating both mitochondria, GOLGI apparatus (WORLEY and WORLEY, 1943) and nucleoprotein (WISLOCKI and DEMPSEY, 1948). Moreover, that such respiratory system as reflected onto the enzyme system also undergoes similar changes following denervation (see, BODIAN, 1947) seems to enforce the indication of some rôle being played by the mitochondria together with the basophilic component in yielding eventually to the resultant characteristics of nerve cells as revealed in the methylene blue preparations.

What such interpretation is amounting to, though necessarily tentative, is a

close relationship apparently present between metabolic events and methylene blue staining of nerve cells, the point having already been suggested independently (FEINDEL et al., 1948; FUKUDA, 1957). When preoccupied with the foregoing interpretation, there are a few at least of observations in hand, more or less circumstantial in nature, which it begins to shed light upon:

1. Relative stainability of gliocytes according to age: In case of new-born animal or aged less than 1 month, practically none of gliocytes has been to date shown stained (FUKUDA, 1957, plate, 1, fig. 1.). In adult animals, the number of gliocytes stained is usually negligible but may be brought forward to some extent by adjusting the temperature of the dye-solution (FUKUDA, 1957).

2. When electric current of low voltage high frequency is given through electrodes into various regions of brain, neurones along and in the immediate vicinity of the electrodes became usually strongly-metachromatic and or intensively stained whereby accompanying some morphologic disintegrations of the neurones involved. This has made possible of localizing histologically the site of electrodes for both acute and chronic experiments (FUKUDA, 1957a).

3. Morphological disintegrations upon exposure to seizure with or without stress: When animals were given electrically induced seizure either coupled or uncoupled with stresses experimentally designed, neurones in various areas of brain displayed a variety of minor though distinct from controls morphological disintegrations according to the degrees of the induced conditions (FUKUDA, STERN and ULETT, unpublished observation), whereby accompanying simultaneously a distinct abnormality of electroencephalograms consisting of high voltage slow waves (FUKUDA et al., 1957). Such an observation, considered then to be of questionable value, seems to bear some quantitative significance from the foregoing view point, since certain molecular events have been shown to take place in neurones under identical conditions (DAWSON and RICHTER, 1950; RICHTER, 1952; SHAPOT, 1957), while the preceding 1. and 2. are pointing to an indication that some metabolic factors are involved in the stainability according to the type of nervous tissues where difference can be found on metabolic levels (see, ELLIOTT and HELLER, 1957) thus complimenting one to another on the view here in dispute. It may follow that neurones are not uniformly alike one from another with respects at least to macromolecular or metabolic levels even under physiological conditions. This would then shed some light also upon understanding of the presence of degenerating characteristics simultaneously noticeable elsewhere in unexpected areas, the point both the silver and the methylene blue having in common (ANDO, 1956; FEINDEL et al., 1948; GLEES and NAUTA, 1955); they may be a physiological product. That such might be the case until proved otherwise, has recently been pointed out by GLEES (1956).

A length of consideration has thus far taken the liberty of venturing on analysis and a resultant view point possibly attainable at the present stage with the aids of some data available as to the methylene blue staining of neurones. What it has brought to clarity as result seems to be that it is no longer of an imaginary

level to consider the methylene blue technique as a potent indicator at least of an overall processes of biochemical events particularly of nerve cells. It has also brought forth the obscurity which the technique appears to be confronting in order to be incorporated into such a rather newer domain, namely, cyto- and histochemistry of neurone, paradoxically enough indeed coexistent with its remarkable specificity and potentiality. An apparent excuse in rendering such a venture may be due to the rapid and continually growing progress of the very field, much celebrated of late and giving rise to an outlook of the problem hereby borne out to be highly susceptible to further analysis (see, CASPERSSON, 1957; LINDERSTROM-LANG and HOLTER, 1943; LOWRY, 1957). It may be otherwise or in addition that considerable amount of works so far accumulated from electrophysiological techniques have given insights as yet far from the understanding of quantitative aspects of neuronal activity, the aspect appearing by now to bear significance in comprehending what is going on inside the 'black box', where thousands of, millions of neurones are closely packed one to another and some are supposed to be predominantly active under certain circumstances accordingly (see, LASHLEY, 1954). The more recent report obtained from chronically implanted electrodes in the brain (STRUMWASSER, 1958) is supporting strongly in favor of the view point and encourages further works along the line to be done in the future. It is not at all unlikely that the intravital methylene blue technique may someday find itself among others to be of value in linking the classical morphology with cyto- and histochemistry of neurones, a subject matter being of a current interest (POPE, 1955; LUMSDEN, 1957).

It will be remembered that the original idea of EHRlich was indeed led by the capacity of methylene blue specific to the vital phenomena of living tissues (1885; 1886). Such an idea, interluded by the proposal of SCHABADASCH, methylene blue as a hydrogen-acceptor (1935), has tolerated in reality the examinations upon classical morphology (CAJAL, 1896; 1954; DOGIEL, 1926; POLYAK, 1941; WOOLLARD et al., 1940) and appears to pose forward an interesting challenge from an unique angle onto the realm of today's problem. That techniques of vital stain have lost nothing of their interest of today and may bring useful data in many problems of cell physiology (DUSTIN, 1947), seems to be fully supported by all of the foregoing.

SUMMARY

Further study on the use of EHRlich method was undertaken where degenerating neurones were primarily concerned. Results obtained are as follows:

1. With technical modifications, degenerating neurones of CNS can be demonstrated in a fair constancy.

2. As compared with the silver method, discrepancy was noticed to be both in the number of demonstrated axons and in the minute images thereof, methylene blue being subordinate in the former but appearing to be superior in the latter.

3. Counterstaining for the fat was applied with result more plausible in case of the Wallerian type than of the retrograde degeneration. In the former, the fat stain became positive in about 2 weeks subsequent to denervation, lasting for about

3 weeks thereafter and was observed to be located along or on top of degenerating axons stained priorly. A suggestion was made further of possible use of the technique in studies such as experimental demyelination.

4. Cellular features of degeneration were also revealed, which showed some parallelism to the behavior of Nissl substances. An account of description on the features has been given.

5. On the basis of the above results, aided in part by the addition of circumstantial evidences available, an overall analysis and resultant speculation was tried to focus on the subject matter under the heading. A suggestion was further reached to indicate that the technique could be useful as an analytic stain in linking the classical morphology with cyto- and histochemical domain of the nervous system.

ACKNOWLEDGEMENTS

Part of Nissl preparation and the initial stage of work regarding the fat stain were carried out during my 3 weeks visit in February, 1957, at the Laboratory of Neuropathology, State Psychiatric Institute of New York, where the arrangement was made possible by the Principal Scientist, Dr. L. ROIZIN and the senior technician, Miss KOGAN. Dr. L. ROIZIN gave me invaluable advices on the technical aspects of the fat stain.

Some of Nissl preparation were made available by Mrs. M. KELLER, chief technician of Department of Pathology at the University.

I hereby gratefully acknowledge their silent collaborations which made possible of completing this study.

It is also my privilege to express gratitude to Professor W. E. EHRICH, Department of Pathology at the University of Pennsylvania for his having read this manuscript with interest and cares, as much as to Professor G. B. KOEHLER of the present Department for his generous interests on preparing the manuscript.

REFERENCES

- 1) Ando, K.: Evaluation of the Methylene Blue Vital Staining of the Brain with Intravenous Drip Technique. Arch. Jap. Chir., 25, 735, 1956.
- 2) Bodian, D.: Nucleic Acid in Nerve Cell Regeneration. In: "Nucleic Acid". Symp. Soc. Exp. Biol., I. Cambridge University Press pp. 163-178, 1947.
- 3) Brachet, J.: Remarques sur la synthèse partielle ou totale de l'acide thymonucleique au cours du développement embryonnaire. Compt. rend. soc. Biol., (Paris), 139, 193, 1945.
- 4) Brachet, J.: "Biochemical Cytology". Academic Press, 1957.
- 5) Cajal, Ramon y, S.: El azul de metileno en los centros nerviosos. Rev. trim. micrograf., 1, 26, 1896.
- 6) Cajal, Ramon y, S.: "Degeneration and Regeneration of the Nervous System". Oxford University Press. London. 2 vols. 1928.
- 7) Cajal, Ramon y, S.: "Neurone Theory or Reticular Theory?" Translated by M. Ubieda-Purkiss and C. A. Fox. Consejo Superior De Investigaciones Cientificas, Madrid. 1954.
- 8) Cannon, W. B. and A. Rosenblueth: "The Supersensitivity of Denervated Structures. A Law of Denervation." MacMillan. New York, 1949.
- 9) Caspersson, T.: "Cytochemical Methods with Quantitative Aims". Exp. Cell Res., supp., 4, 1957.
- 10) Chance, B. and G. R. Williams: Respiratory Enzymes in Oxidative Phosphorylation. I. II. III. J. Biol Chem., 217, 383, 1955.
- 11) Chlopin, N. G.: Experimentelle Untersuchungen ueber die sekretorischen Prozesse im Zytoplasma. Arch. exp. Zellforsch., 4, 462, 1927.

- 12) Dawson, R. M. C. and D. Richter: The Phosphorus Metabolism of the Brain. *Proc. Roy. Soc. B.*, **137**, 252, 1950. 13) De Castro, F.: Aspects anatomiques de la transmission synaptique ganglionaire chez les mammifères. *Arch. internat. Physiol.*, **59**, 479, 1951. 14) Dogiel, A. S.: *Methylenblau zur Nervenfaerbung*. In: "Enzyklopaedie der mikroskopischen Technik." R. Krause, 3rd Edition. Berlin. Urban and Schwarzenberg, 1390, 1926. 15) Dounce, A. L.: The Isolation and Composition of Cell Nuclei and Nucleoli. In: "The Nucleic Acids." E. Chargaff, edit. Academic Press, pp. 93-154, 1955. 16) Dustin, P.: Ribonucleic Acid and the Vital Staining of Cytoplasmic Vacuoles in Animal cells. In: "Nucleic Acid". *Symp. Soc. Exp. Biol.*, I. Cambridge University Press, pp. 114-4126, 1947. 17) Ehrlich, P.: Zur biologischen Verwertung des Methylenblau. *Zbl. med. Wissenschaft.*, **23**, 113, 1885. 18) Ehrlich, P.: Ueber die Methylenblau Reaktion der lebenden Nervensubstanz. *Biol. Zbl.*, **6**, 214, 1886. 19) Elliott, K. A. C. and I. H. Heller: Metabolism of Neurons and Glia. In: "Metabolism of The Nervous System." D. Richter, edit. Pergamon Press, New York:London, pp. 286-290, 1957. 20) Feindel, W. H., A. C. Allison and G. Weddell: Intravenous Methylene Blue for Experimental Studies on the Central Nervous System. *J. Neurol. Neurosurg. Psychiat.*, **11**, 227, 1948. 21) Fukuda, T.: Demonstration of the Cutaneous Nerves with Methylene Blue Staining in Leprosy. *Arch. Jap. Chir.*, **22**, 525, 1953. 22) Fukuda, T.: A Re-evaluation of the Intra-Arterial Methylene Blue (Method of Ehrlich) in Studies of the Central Nervous System. *Arch. Jap. Chir.*, **26**, 505, 1957. 23) Fukuda, T.: Histological Localization of Implanted Electrodes by Means of the Modified Ehrlich Method. (unpublished). 1957a. 24) Fukuda, T. and G. B. Koelle: Correlative Cytological Organization of Acetylcholinesterase. *Proc. Biophys. Soc.*, Cambridge, Massachusetts, February, 1958a. 25) Fukuda, T. and G. B. Koelle: The Intravital Methylene Blue Technique on Neurons as a Partial Inhibitor of Acetylcholinesterase (in Preparation). 1958b. 26) Fukuda, T., J. A. Stern and G. A. Ulett: Electroencephalographic Studies on the Effects of Electroconvulsive Shock, Experimental Stress and Atropine on Albino Rats. *Proc. Electoshock Res. Assoc., Am. Psychiat. Ass.*, Chicago, Illinois, May, 1957. (Full account in the press of *Conf. neurol.*). 27) Glees, P.: The Termination of Optic Fibres in the Lateral Geniculate Body of Cat. *Anat. Rec.*, **75**, 434, 1941. 28) Glees, P.: A Critical Survey of the Work Done with Bouton Degeneration. In: "Progress in Neurobiology." J. Ariens Kappers, edit. Elsevier Pub. Co., Amsterdam: New York, pp. 101-103, 1956. 29) Glees, P. and W. J. H. Nauta: A Critical Review of Studies on Axonal and Terminal Degeneration. *Mschr. Psychiat. Neurol.*, **129**: 74, 1955. 30) Glick, D.: "Techniques of Histo- and Cytochemistry". Interscience Publishers, New York, 1949. 31) Heller, R. E., R. W. Thomas and H. A. Davenport: Staining Nerve Fibers with Methylene Blue. An Evaluation of Variables Used in an Immersion Technique. *Stain Techn.*, **22**: 111, 1947. 32) Herxheimer, G.: Zur Fettfaerbung. *Centralbl. allg. Path. u. Path. Anat.*, **14**, 841, 1903. 33) Hillarp, N.-A.: Structure of the Synapse and the Peripheral Innervation Apparatus of the Autonomic Nervous System. *Acta anat., supp.*, **4**, 1946. 34) Hogeboom, G. H. and W. C. Schneider: The Cytoplasm. In: "The Nucleic Acids." E. Chargaff, edit. Academic Press, pp. 199-246, 1955. 35) Hydén, H.: Protein Metabolism in the Nerve Cell During Growth and Function. *Acta physiol. scand.*, **6**, supp., 17, 1943. 36) Hydén, H.: Protein and Nucleotide Metabolism in the Nerve cell under Different Functional Conditions. In: "Nucleic acid". *Symp. Soc. Exp. Biol.*, I. Cambridge University Press, pp. 152-162, 1947. 37) Lashley, K. S.: Dynamic Processes in Perception. Group Discussion. In: "Brain Mechanisms and Consciousness." J. F. Delafresnaye, edit. Charles C Thomas, Springfield, Illinois, pp. 437-443, 1954. 38) Linderström-Lang, K. and H. Holter: Theory and Technique of the Cartesian Diver. *Compt. rend. trav. lab. Carlsberg, Serv. chim.*, **24**, 333-478, 1943. 39) Lowry, O. H.: Quantitative Analysis of Single Nerve Cell Bodies. In: "Ultrastructure and Cellular Chemistry of Neural Tissue." H. Waelsch, edit. Hoeber-Harper: New York, pp. 69-82, 1957. 40) Lumsden C. E.: The Problem of Correlation of Quantitative Methods and Tissue Morphology in the Central Nervous System. (The Distribution of Cholinesterase). In: "Metabolism of the Nervous System. D. Richter, edit. Pergamon Press, pp. 91-100, 1957. 41) Nauta, W. J. H.: Silver Impregnation of Degenerating Axons. In: "New Research Techniques of Neuroanatomy." W. F. Windle, edit. Charles C Thomas, pp. 17-26, 1957. 42) Palay, S. L. and G. E. Palade: The Fine Structure of Neurons. *J. Biophys. Biochem. Cytol.*, **1**, 69, 1955. 43) Palade, G. E.:

The Endoplasmic Reticulum. *J. Biophys. Biochem. Cytol.*, **2**, 85, No. 4, supp., 1956. 44) Polyak, S. L.: "The Retina". University of Chicago Press, 1941. 45) Pope, A.: The Relationships of Neurochemistry to the Microscopic Anatomy of the Nervous System. In: "Biochemistry of the Developing Nervous System." H. Waelsch, edit Academic Press, New York, pp. 341-349, 1955. 46) Porter, K. R.: Observations on a Submicroscopic Basophilic Component of Cytoplasm. *J. exp. Med.*, **97**, 727, 1953. 47) Richter, D.: Brain Metabolism and Cerebral Function. *Biochem. Soc. Symp.*, **8**, 62, 1952. 48) Schabadasch, A.: "Theoretische und experimentelle Studien zur Methylenblaufärbung des Nervengewebes." Gorkij. Staatsverlag. 1935. 49) Shapot, V. S.: Brain Metabolism in Relation to the Functional State of the Central Nervous System. In: "Metabolism of the Nervous System." D. Richter, edit. Pergamon Press, pp. 257-262, 1957. 50) Sperry, R. W.: Functional Regeneration in

the Optic System. In: "Regeneration in the Central Nervous System." W. F. Windle, edit. Charles C Thomas, pp. 66-76, 1955.

51) Sperry, R. W.: (Personal communication) 1957. 52) Strumwasser, F.: Long-term Recording from Single Neurons in Brain of Unrestained mammals. *Science*, **127**, 469, 1958. 53) Weddell, G. and P. Glees: The Early Stages in the Degeneration of Cutaneous Nerve Fibers. *J. Anat.*, **76**, 65, 1941. 54) Wislocki, G. B. and E. W. Dempsey: The Chemical Cytology of the Choroid Plexus and Blood Brain Barrier of the Rhesus Monkey (*Macaca Mulatta*). *J. comp. Neurol.*, **88**, 319, 1948. 55) Woollard, H. H., G. Weddell and J. A. Harpman: Observations on the Neurohistological Basis of Cutaneous Pain. *J. Anat.*, **74**, 413, 1940. 56) Worley, L. G. and E. K. Worley: Studies of the Supravivally Stained Golgi Apparatus. I. Its Cycle in the Tectibranch Mollusc, *Navanax inermis* (cooper) *J. Morph.*, **73**, 365, 1943.

Explanations for the figures:

- Plate 1: **Fig. 1.** 9 days postoperative. Optic tract of rat side opposite to the denervation. Most of axons are degenerating regardless of their size. 60M. 800×.
- Fig. 2.** 3 days postoperative. Lateral geniculate of rat. Axons and terminals are disintegrating while cell bodies are intensively stained. 60M. 800×.
- Fig. 3.** 32 days postop. Optic tract of rat. The characteristics seen in Fig. 1 are still appreciable. 60M. 800×.
- Fig. 4.** Nauta's silver. 9 days postop. Optic tract of rat. Numerous degenerating axons are seen. 30M. 800×.
- Fig. 5.** The silver impregnation. 3 days postoperative. Lateral geniculate of rat. Some of axons appear to be relatively intact. 25M. 800×.
- Fig. 6.** Control for the methylene blue. Thalamus of intact rat. Axons appear to be somewhat tortuous due to artifacts, though feature of true degradation is lacking. Note the cells with smooth outlines (not in focus). 60M. 800×.
- Plate 2: **Fig. 7.** 3 days postop. Lateral geniculate of rat. presenting the 'disintegration of neurone'. 60M. 640×.
- Fig. 8.** 7 days postop. Lateral geniculate of rat. Both irregularity and unevenness are disclosed predominantly. 60M. 640×.
- Fig. 9.** 6 days postoperative. Lateral geniculate of kitten. Cellular images are identical with fig. 7. 60M. 800×.
- Fig. 10.** Cresylviolet stain. 3 days postoperative. Lateral geniculate of rat. Pathologic processes are evident. 800×.
- Fig. 11.** Methylene blue control. Typical appearances of intact neurones seen in rabbit thalamus.
- Fig. 12.** 2 days after unilateral eye-enucleation. The methylene blue is seen to be accumulated in and around the blood vessels, disturbing identification of degenerating elements, though some are appreciable on this slide. The typical picture, frequently encountered during the previous study, is now controllable by avoiding vascular damages. 60M. 800×.
- Plate 3: **Fig. 13.** Cresylviolet stain. A typical resting pattern of Nissl substance, seen in superior cervical ganglia of cat. 800×.
- Fig. 14.** Nissl substances undergoing chromatolysis. 3 days after denervation. Material is

PLATE 1

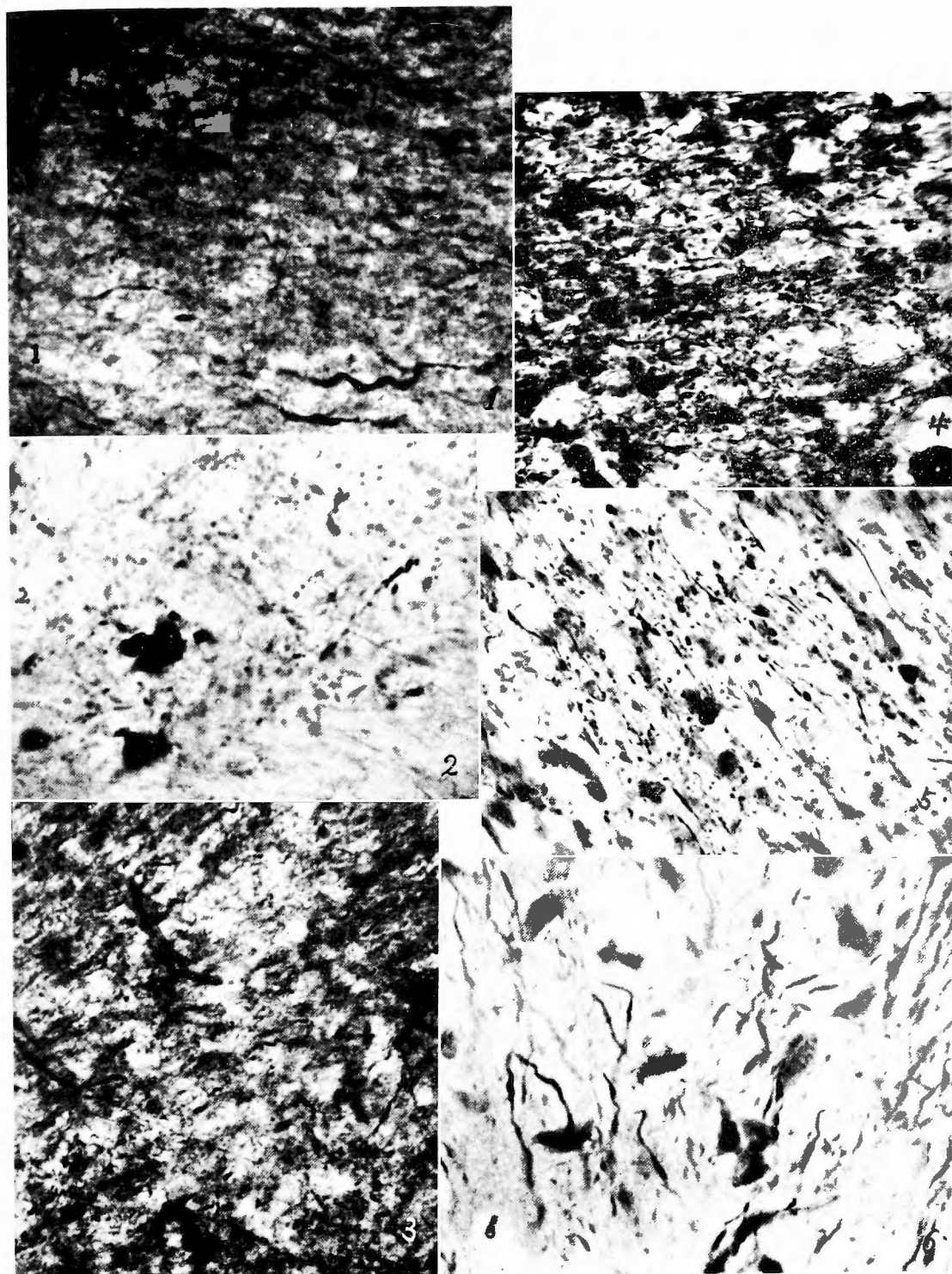


PLATE 2

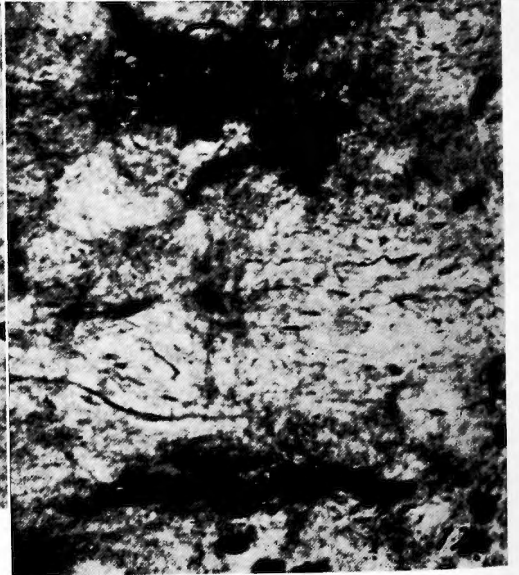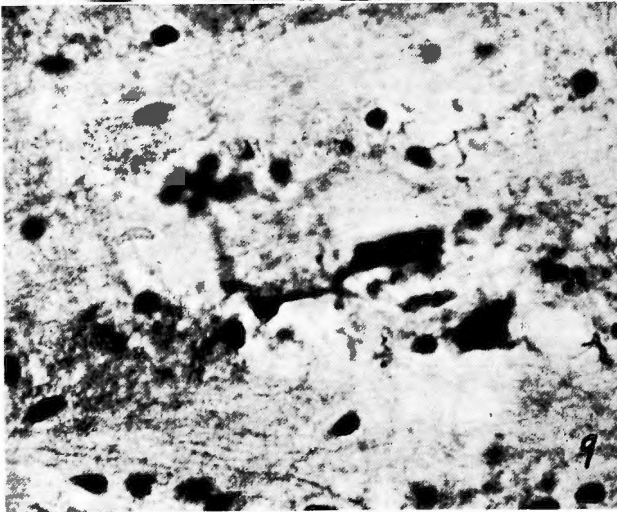
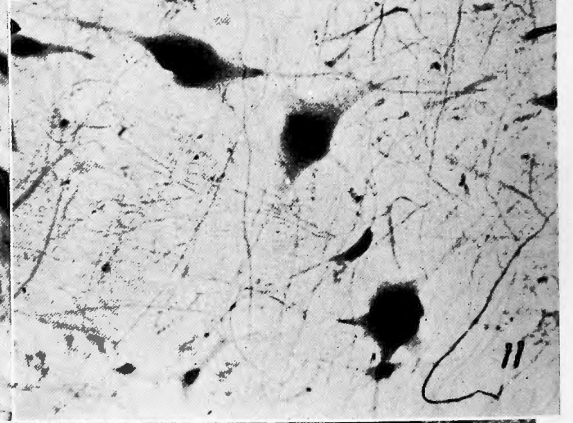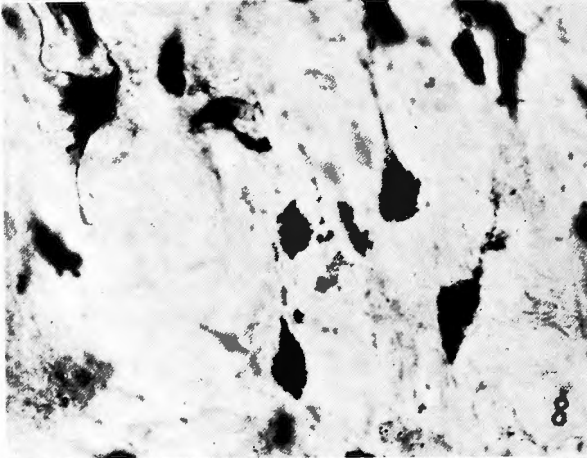
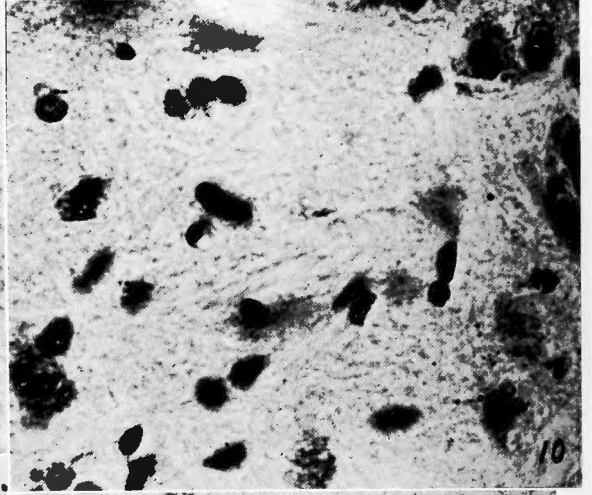
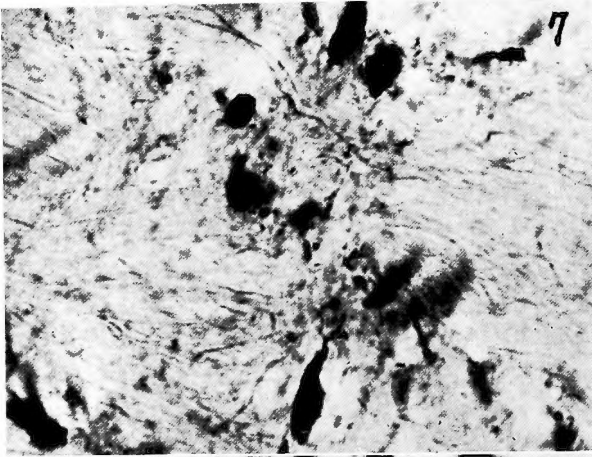


PLATE 3

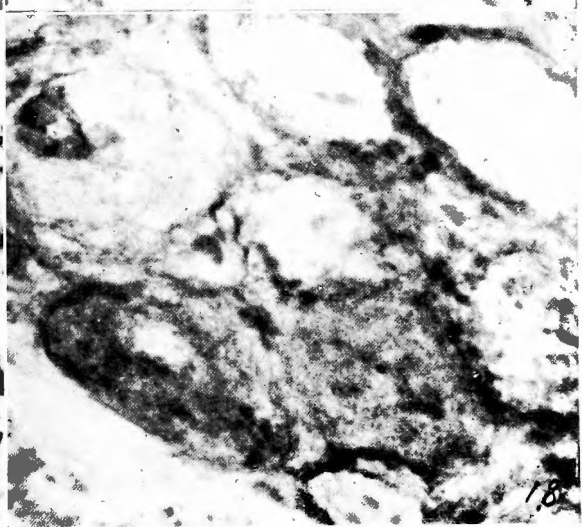
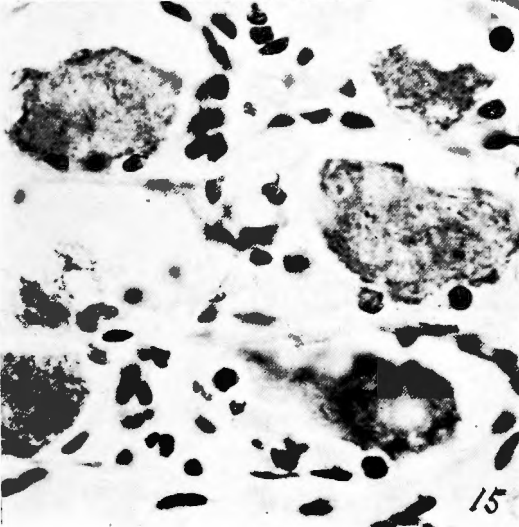
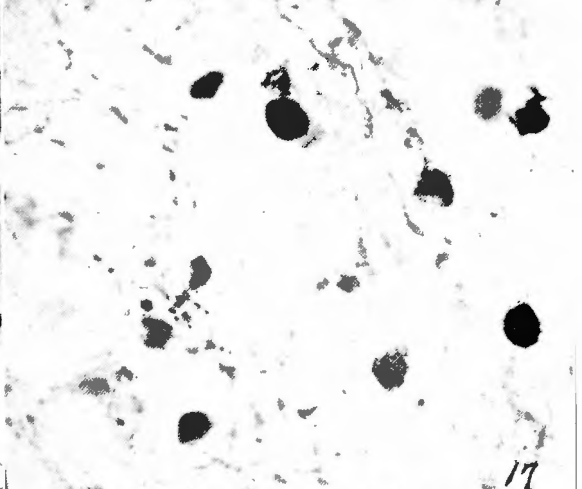
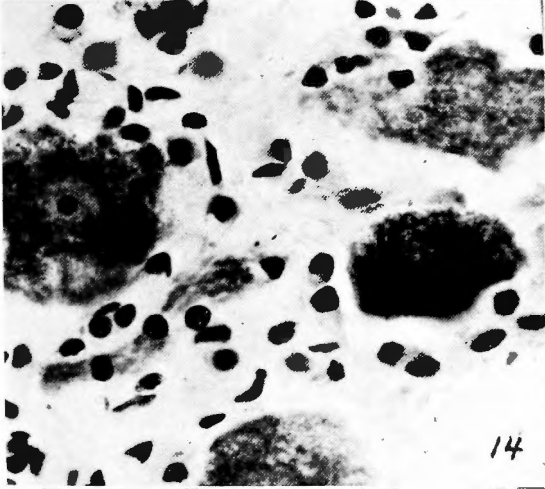
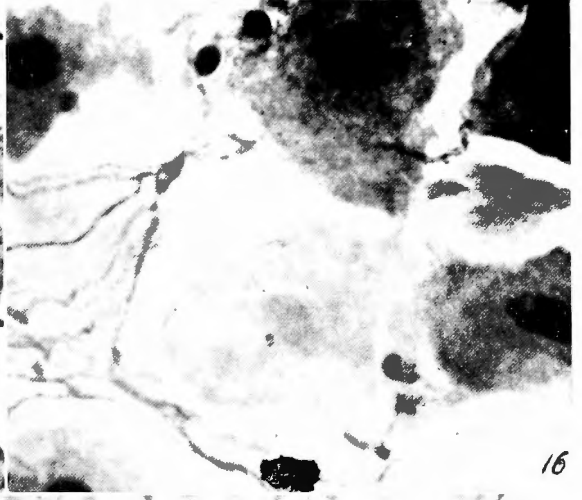
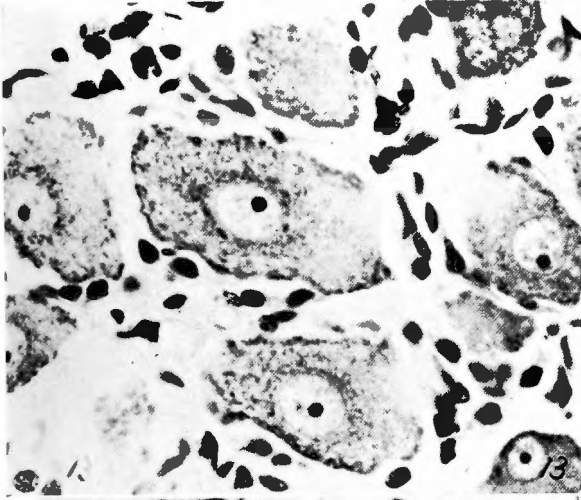


PLATE 4


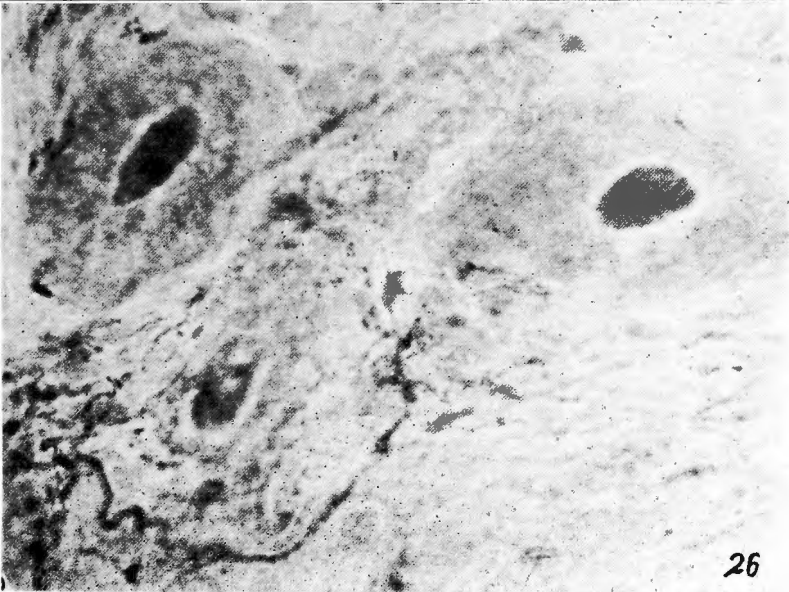


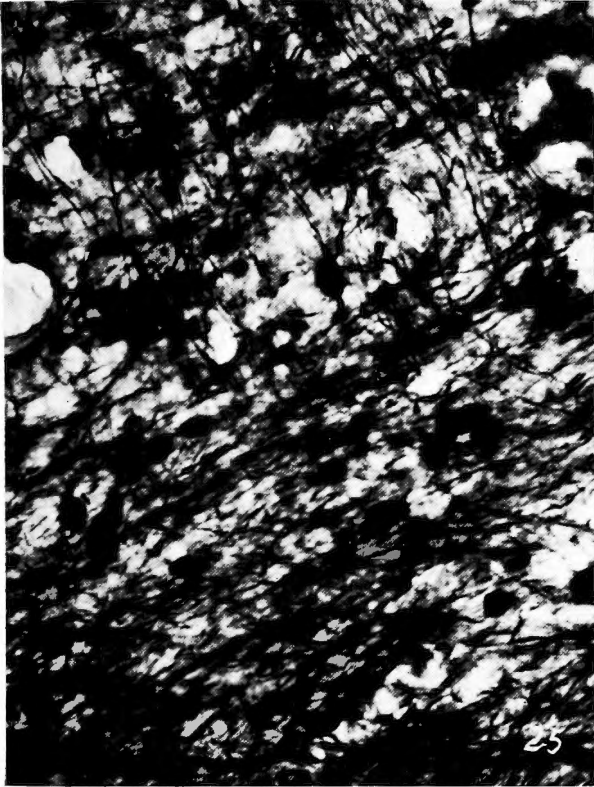


PLATE 5



identical otherwise to the Fig. 13. 800×.

Fig.15. 7 days postoperative. Pathological processes are far advanced by this stage. Some of cells are showing marked shrinkage. 800×.

Fig.16. Methylene blue. A typical feature of resting ganglion cells and axons. Stellate cells are also stained. 30M. 800×.

Fig.17. 5 days postoperative. Methylene blue appears to be not very well attached to neurones. Marked decolorization, nuclear shrinkage are being associated with the irregular outline of cytoplasm. Note the degenerating axons appreciable. 30M. 800×.

Fig.18. 20 days postoperative. At this stage, the whole feature presents irregularity and displaced nuclei dimly appreciable. By-stain of boundary membranes are obvious. 30M. 800×.

Plate 4: **Fig.19.** Preganglionic sympathetic trunk. 1 day after denervation. Fibers of medium size began to show early stages of degeneration. 30M. 800×. Methylene blue stain.

Fig.20. 15 days after denervation. All of fibers show unmistakable degradation. Methylene blue stain. 25M. 800×.

Fig.21. Alternate sections of the Fig.20. Counterstained for the fat. Red droplets and particles are seen to be along and on top of the axons faintly visible in blue color. 25M. 800×.

Fig.22. Material equivalent to the Fig. 21. The fat stain alone. Particles of the fat seen on intraganglionic fibers. Cells are designated by c.

Fig.23. 25 days postoperative. Degenerating axons are accompanied by fat particles without definite relationships topographically, though roughly corresponding to the myelin figures. 30M. 640×.

Fig.24. Lateral geniculate of rat. 26 days postoperative. The positive fat are being closely associated with neurones, though more details can not be ascertained. 30M. 800×.

Plate 5: **Fig.25.** The silver stain control. Motor cortex of the same material as in Fig. 5. Intact axons at the junction between descending axons and the white matter. Surface of cortex is upward left. 25M. 800×.

Fig.26 Methylene blue control. Ganglionic neurones of cat, cut by fresh frozen section technique (Fukuda, Koelle, 1958a. b.) without formalin fixation. Note delicate terminals and some of dendritic processes without gross distortion even by such procedure. 10M. 800×.

Fig.27. 6 days postoperative. Main optic tract of kitten. Degeneration is taken place in fibers of various size. 60M. 460×.

Fig.28. 4 days postoperative. Main optic tract of guinea pig. Some of finer fibers are predominantly stained. The disintegrating features are identical to the others above shown. 60M. 800×.

和文抄録

神経系研究における Ehrlich 法の価値

——特に変性ノイロンに関して——

マルコーム・プリス精神病院研究室
セントルイス・ワシントン大学医学部精神々経科

福 田 哲 雄

Ehrlich 法に適当な変改を加えることによつて、中枢神経系の変性ノイロンをかなり確実に染色し得る。これを鍍銀法に比較すると、染色される軸索の数においても、その微細像においても相違が見られ、メチレン・ブルー法は前者に関しては劣つてゐるが、後者についてはより優れている。脂肪染色を追加すると、逆行変性の場合よりも Waller 変性の場合により成績が得られる。後者の場合、神経切断後約2週間

以内に脂肪染色が陽性となり、約3週間持続する。脂肪は変性した軸索の先端又は軸索に沿つて認められる。神経細胞の変性像も本法で観察し得るが、これは略々 Nissl 体の態度と平行する。

以上の結果から、本法は神経系の研究において、古典的な形態学的研究と細胞乃至組織化学的研究とを関連づける方法として用い得るものと考えられる。