

ON A CASE ACCOMPLISHED WITH A REGENERATED BLADDER

by

NAOHIKO HARADA, IKUJI KOYAMA, MICHIKO ISHIDA,
YASUO IIDA, HIROSHI KADOWAKI, MORIHIKO TANIMURA,
FUJIYA MARUI, TAKASHI ABEA and SHINTARO TOMIZAWA

From the Department of Surgery, Osaka City University Medical School

(Director : Prof. Dr. YAEMON SHIRAHATA)

Received for publication May 2, 1959

It is a well known fact that the urinary tract possesses a remarkable regenerative ability. There are, however, few reports on its clinical application. TIZZONI (1888), SCHILLER (1923) and PERLMAN (1927) reported on the fact experimentally. BOHNE (1957) and GARRET (1957) utilized this ability first clinically.

The authors have recently experienced a case who had been cystectomized subtotally on the X-ray irradiated bladder and has been observed on the bladder regeneration through a period of two and a half years. The patient, unfortunately, died from an emergent bleeding. The authors will describe the details of this instructive case.

CASE HISTORY

A house-wife, K. S., aged 35, complained of bloody urine. The patient had been diagnosed as a case of the uterus and had undergone a total hysterectomy about 2 years before. Following the operation, the patient had been treated by regular X-ray irradiation. When the dose of the irradiation accumulated about 5,000 γ , she noticed herself marked cyanosis, thirst, severe heart beat, ulceration on the skin of the pelvis and bloody stool and urine. The skin of the abdomen, thigh and gluteal regions had been thickened (Fig. 1). Volume of urine became smaller in quantity and began to contain blood clot. It was evident that the condition was severe roentgen injury. The patient was admitted to the authors' surgical department on July 27, 1957.

The authors proved giant vesicorectal fistula on roentgenological and romanoscopic examination. The bladder could not be expanded with fluid, because the fluid leaked out into the rectum through the fistula in the right supratrigonal portion. Due to the severe rectosigmoidal hemorrhage, the patient was in condition of anemic shock (RC: 2,680,000, hemoglobin: 52%, WC: 6,300). After sufficient

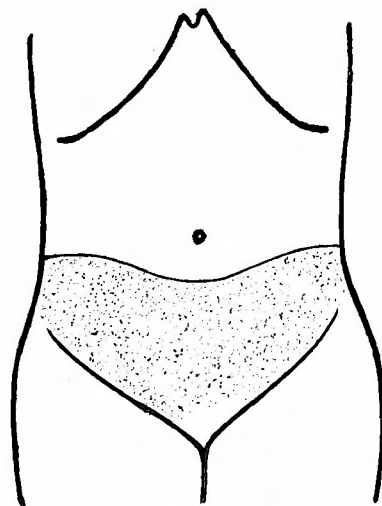


Fig. 1. The skin of the abdomen had been thickened by X-ray irradiation.

supply of various fluids, an operation was performed on August 12, 1957. The peritoneal cavity was opened by a midline incision under an endotracheal anesthesia. The sigmoid colon and omentum had adhered to the anterior parietal peritoneum and had made a barrier which shut off the small pelvic cavity from the free peritoneal cavity. The adhesion had to be dissected with great troubles, either sharply or bluntly. The authors found that the sigmoid colon and bladder had shrunk and stiffened markedly, adhering together at the site of 8 cm oral side from the anus. Both of these organs were easily damaged with manipulations and showed a tendency of uncontrollable parenchymatous bleeding. These findings indicated both rectal amputation and subtotal cystectomy. An artificial anus was made in the left hypochondrium. There was a large defect in the posterior peritoneum, and so the dead-space in the pelvic cavity opening to the perineum was left without peritoneal covering. Only one thing done for protection against infection was simple tamponade with sponges. The remaining bladder, the trigon alone, was mobilized sufficiently and capped with posterior sheath of the rectus muscle, being utilized as its wall on the cranial side. The line of sutures of the remaining bladder was completely covered with the anterior peritoneum (Fig. 2). A polyvinyl mold of 20 cm³ was inserted into the newly reconstructed bladder. The authors expected that a perfect and sufficiently large bladder would be regenerated around the mold. Then the abdominal wound was closed primarily but the perineal wound was left open. On the 10th postoperative day, an infection occurred in the suture line and abdominal wall and vesicomuscular suture lines fell in insufficiency. The mold had to be removed. But

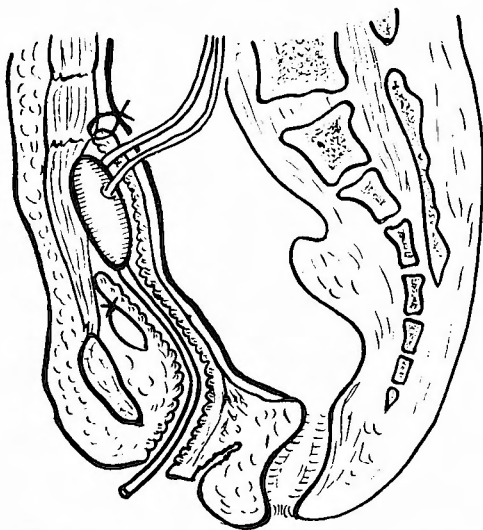


Fig. 2. The remaining bladder, the trigon alone, was mobilized sufficiently and capped with posterior sheath of the rectus muscle. The site of suturing was completely covered with the anterior peritoneum. A mold was inserted into the newly formed bladder.

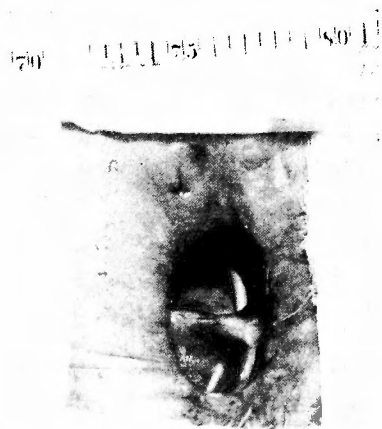

Fig. 3. The abdominal wound became a giant defect like a hole. Through this hole, the regenerated bladder was noticed in the giant dead-space as if it were a tiny ledge, and ureteral peristalsis was seen on it.

fortunately, the barrier between free peritoneal and the pelvic dead-space cavities had been perfectly constructed with the intestine and colon. Consequently, the infection did not advance to a general peritonitis. Urine leaked from the abdominal and perineal wounds, but not from the urethra. In spite of the occurrence of these serious complications, the patient recovered gradually. It must be the most precious gift to the patient the previous hemorrhage had been completely controlled. About 2 months later, the patient could walk around the bed. Urine passed into a urinal bag through 2 ureterourethral catheters. The abdominal wound became a giant defect like a hole. Through this hole, the regenerated bladder was noticed in the giant dead-space as if it were a tiny ledge, and ureteral peristalsis was seen also on the ledge (Fig. 3). The authors could observe that the ledge enlarged every day and the enlarging area was forming the posterior wall of the bladder. After 3 months, the regenerated bladder took a form of a bottle, because it had no dome.

The general status of the patient was very well. Blood and urinary electrolytes were determined (N. P. N.: 69.32 mg/dl, Cl: 366.30 mg/dl). After about 4.5 months, on Dec. 20, 1957, when the right ureteral catheter was exchanged, a massive bleeding from the right ureteral orifice was noticed. The bleeding was so severe that the blood took a swirl form. It was controlled by compression with sponges, but the original point of this bleeding was not ascertained. The blood loss amounted about 1,000 cc. The blood was transfused into the patient's body swiftly. However, as soon as the blood pressure was recovered over 90 mmHg, the hemorrhage recurred. Nephrectomy on the right side and insertion of gauze tamponade into the right ureter were performed on Dec. 23, and the authors could narrowly find out that the blood had issued from a portion injured by the roentgen irradiation on right common iliac artery. After all, the nephrectomy proved to be unsuitable for checking the hemorrhage. The authors could stop the severe hemorrhage with compression tamponade alone after 10 days.

Thereafter, the general condition of the patient has been well, gaining body weight. Then the patient complained of pain in the pubic bone on July 10, 1958. X-ray revealed that the bone had been destroyed and decalcificated. The osteitis pubis had occurred. It was treated only by chemotherapy, being cured 60 days later.

On Oct. 23, 1958, the patient was doing very well and the bladder was regenerated to a remarkable degree. In order to make walking easily, the defect in the abdominal wall made by the previous operation was plugged up with nylon sponge and urine was collected in the dead-space. After that urine was normally discharged through the urethra, not through the indwelt catheters. Unfortunately, when urine was collected in the dead-space, the surrounding skin of the wound was irritated by urine. On November 28, the patient suddenly suffered from a severe hemorrhage from the left common iliac artery. The bleeding was so severe that her blood pressure could not be raised at all despite any antihemorrhagic treatments. The patient died of the blood loss at last on Nov. 30, 1958.

At autopsy, both common iliac arteries showed degenerative changes and necrosis effected by X-ray irradiation. Their walls ruptured easily by slight physical and

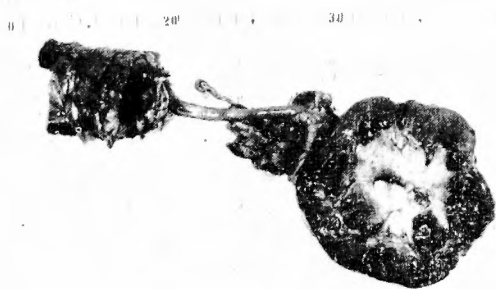

Fig. 4

Figs. 4, 5 6 and 7. The regenerated bladder had a thick wall covered with the uroepithelium and formed in a bottle shape. Its capacity amounted about 60 cc. No renal damage was demonstrated.

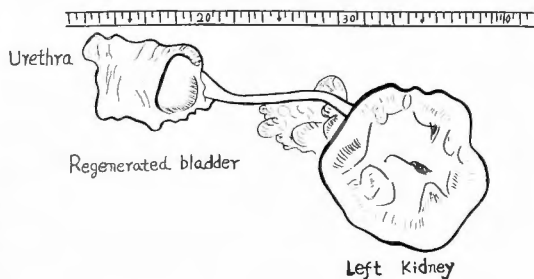


Fig. 5.



Fig. 6.

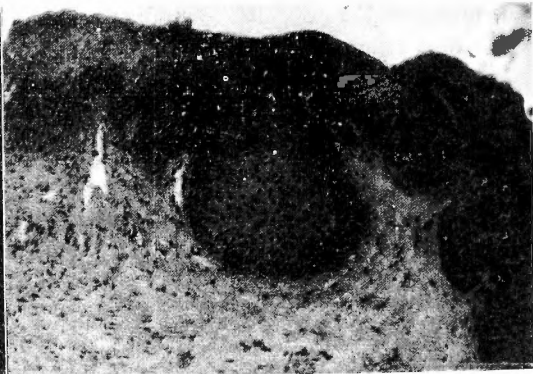

Fig. 7.

chemical irritations. The right iliac artery had been filled with thrombi but the left contained partial thrombus partially. In the left iliac artery, the bleeding had not been yet perfectly controlled. It was evidently the cause of death. However, the bladder had regenerated remarkably. The regenerated bladder had a thick (1.5 cm) wall covered with the uroepithelium and formed itself in a bottle shape (Figs. 4, 5, 6 and 7). Its capacity was about 60 cc. No renal damage was shown. The injuries by previous X-ray irradiation had remained on the entire abdominal wall, but there was an inclination of recovery.

DISCUSSION

The authors experienced a case to whom a subtotal cystectomy was applied and whose bladder was regenerated after the operation and who was placed under careful observation through a period of two and a half years.

The left part of the bladder after subtotal cystectomy was only the trigon, but during 2.5 years a bottle shaped bladder with capacity of 60 cc had been built up! Unfortunately, however, the patient was lost suffering from an accidental bleeding

just before the completion of the bladder regeneration was achieved.

This case clearly showed to the authors a fact that the urinary tract possesses remarkable regenerative ability and it suggested that there might be a promising future development in the field.

On the other hand, the authors have tried and expected a new idea to utilize dead-space as an artificial bladder on this case. However, it has been shown through the experiences of the present case that the uroepithelium hardly develops on granulation tissue. The fact suggested that the uroepithelium actually possesses a regenerative ability but a suitable bed must be selected in order that its regenerative ability may functionate. And the authors have found out recently that the muscle tissue is preferable to fascia as a bed for the uroepithelium.

These two possibilities which have been noticed by the authors through careful observations of this clinical case promoted us to work on further problems, namely an artificial bladder reconstructed by autotransplantation of the uroepithelium in the muscles.

CONCLUSION

1. A clinical case accomplished with the regenerated bladder has been observed during a period of two and a half years after subtotal cystectomy.

2. It may be a hopeful attempt that the regenerative ability of the urinary tract will be taken up for the completion of an artificial bladder.

REFERENCES

- 1) Bohne, A. W. & Urwiller, K. L.: Experience with urinary bladder regeneration. *J. Urol.*, **77**, 725, 1957.
- 2) Garret, R. A. & Vaughn, W. R.: Regeneration of bladder: Case report. *J. Urol.*, **77**, 718, 1957.
- 3) Harada, N., Tsukazaki, Y. & Koyama, I.: An artificial bladder by autotransplantation of the uroepithelium. *J. Urol.*, in press.
- 4) Perlman, S.: Demonstration of bladder regeneration. *Zschr. Urol.*, **21**, 621, 1927.
- 5) Schiller, H.: Regeneration of resected urinary bladder in rabbits. *Surg., Gyn. & Obst.*, **36**, 24, 1923.
- 6) Tizzoni, G. & Foggi, A.: Die Wiederherstellung der Harnblase: Experimentelle Untersuchungen. *Zbl.Chir.*, **15**, 921, 1888.

和 文 抄 録

膀胱垂全剔出後、膀胱の再生を認められた1例

大阪市立大学医学部外科学教室（指導：白羽弥右衛門教授）

原 田 直 彦・小 山 育 二・石 田 道 子
飯 田 保 夫・門 脇 宏・谷 村 守 彦
丸 井 富士哉・饗 庭 隆・富 沢 新太郎

子宮癌のため子宮全剔出術を受け、後療法としてレ線治療中その過剰照射により骨盤内臓器傷害をおこし

た35才の女子に対し、膀胱垂全剔出後残存した三角部から膀胱を再生させる目的で、新しい手術をこころみ

た。すなはち、三角部に出来るだけ可動性を与え、前腹壁腹膜の前において、腹直筋筋膜にこれを固定し、新しく尿貯溜腔を造設した。このさい、腹膜はその後方で閉鎖、遊離腹腔から遮断された。その結果、膀胱粘膜が再生されて、完全な膀胱の完成されることを期待した。術後腹膜が縫合不全に陥り、腹壁創が哆開して、前腹壁から会陰にいたる大きな死腔が形成された。ところが、膀胱の尿路上皮はこの死腔の肉芽組織面を日々増殖進展し、死腔の一部が膀胱様囊体として

働くにいたつた。この再生された膀胱は容量60ccで、その内面は尿路上皮で被われ、尿をよく貯えていたが、術後2年6ヵ月後に、以前うけたレ線過剰照射のために出来たと思われる総腸骨動脈の損傷部位から、突然大出血をおこし、患者は死亡した。本症例の処置として行われた術式が特異であり、その術後経過は私達にとくに多くの示唆を与えてくれたのでここに報告する。