
臨 床

Surgical Treatment of Femur-Shaft Fractures in Children

by

SHIN MORITA and HAJIME ODA

Clinic of Orthopaedic Surgery, Wakayama Red Cross Hospital, Wakayama

Received for Publication Sept. 12, 1967

The conservative treatment has been to be thought the best in the treatment of femur-shaft fractures in children. But it has the disadvantages of uncertainty in the reduction of displaced fragments and its maintenance. Marked overgrowth of the affected femur, as had been expected, was not observed in the cases of end to end apposition fixed by intramedullary nailing, of which metal as the foreign body may hardly produce the stimuli for the elongation of the femur. The elongation was of slight degree in our series. When we have sufficient caution for the prevention of infectious complication, the surgical treatment will be the method based upon the principles of the fracture management in general.

The characteristic features in the course of femur-shaft fractures in children consist in the overgrowth of the affected femur and the liability to fusion of fragments without leaving behind the knee contracture. Then, the conservative treatment has been insisted upon almost exclusively as the method of choice in the treatment. However, it encounters, owing to the anatomical conditions of the thigh, some difficulties. It would be sometimes necessary to treat surgically even femur-shaft fractures in the newborn.⁷⁾ The femur is surrounded by the voluminous soft tissues to hinder the precise immobilization of fragments. Furthermore, the muscles of the thigh are comparatively strong, which causes easily the displacement of fragments at injury, and even after the reduction of fragments the angulation deformity of the femur is apt to occur in the course of immobilization at the site of fractures due to the unbalance of surrounding muscle tonus. Those are the difficulties in the conservative treatment of femur-shaft fracture and in regards to the certainty of the treatment, the conservative treatment has some disadvantages. Many devices and methods elaborated by many authors²⁾⁴⁾⁵⁾ for traction and immobilization prove the difficulty of conservative management. Then, with small series of femur-shaft fractures in children surgically treated at hand, we show in the article that the surgical treatment has enough advantages not to be abandoned.

TECHNIQUE

The osteosynthesis are attained with dia-pin (modified Rush-pin with a cross section of rhomboidal shape), intramedullary nails of V- or clover-shape, plate, screws and wire for comminuted fracture. The plate and screws are usually used for the synthesis of subtrochanteric fracture. In older children, intramedullary nailing was carried out with the same method as that in adults but in younger children the dia-pin is often used for

the intramedullary fixation of which the procedure will be here described.

The standard anterolateral approach reveals easily the broken site of the femur with less damages to the soft tissues. A Kirschner wire is introduced through the medullary cavity of the proximal fragment as a guide pin and driven out through the greater trochanter in retrograde fashion. A small incision is made down on the skin of the buttock tented up by the wire. Then the Kirschner wire is pulled back distally in a little distance and the dia-pin is introduced through the wound in the buttock until it arrived at the region of the greater trochanter (more exactly fossa intertrochanterica). At that point, the Kirschner wire and the dia-pin must be exactly on the same alignment which is kept under two directional control of inspection during the driving of the dia-pin (Fig. 1). Then, the dia-pin is driven into the medullary cavity of the proximal fragment and the Kirschner wire is withdrawn. After the precise adaptation of the fragments, the dia-pin is driven further into the medullary cavity of the distal fragment and the intramedullary nailing is attained. Alexis nad McIvor elaborated the device of the guide rod with a hollow cavity at its tip in order to ascertain and easify the osteosynthesis after the corrective osteotomy for the deformed femur.¹⁾ But it would suffice for us to use a Kirschner wire as the guide pin in the synthesis of the broken femur, of which management is much easier than that of the deformed femur at surgery.

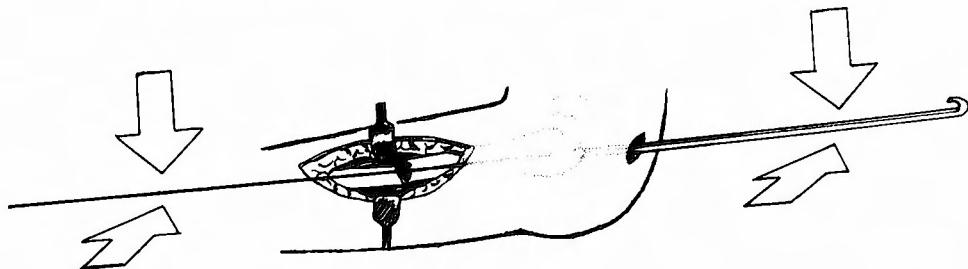


Fig. 1 The dia-pin and guide pin, Kirschner wire, must be on the same alignment controlled by two directional inspection, while the dia-pin is driven through the intertrochanteric fossa into the medullary cavity of the proximal fragment.

MATERIALS AND RESULTS

Surgery was carried out in forty-six patients of femur-shaft fractures in our clinic during these eleven years. Fifteen patients of the forty-six were under the ages of fifteen years. Excluded one patient of pathological fracture after infectious osteomyelitis of the femur, the ages of the remainder fourteen patients, of which twelve were male and two female, were ranged from two years four months to fourteen years. The patients could be divided according to their ages into three groups somewhat arbitrarily for the conveniences of the perspective, that is, five patients aged less than five years, five patients aged from five to eight years and four patients aged from nine to fourteen years (Table 1). In the third group, the surgical procedure was almost the same as that in adults (Fig. 2). In the second group, the intramedullary nailing was performed sometimes with the dia-pin and sometimes with the nails of V- or clover shape (Fig. 3, 4, 5). In the first group, the intramedullary nailing was attained with the dia-pin (Fig. 6).

Table 1

| Patient | Age | Sex | Injury | Side | Site of Fracture | Type | Metal for Fixation | Follow-up | Elongation | Notes |
|---------|------------------|--------|---------------------|-------|--|--------------------------|----------------------------|---------------|-------------------|----------------|
| 1 K.T. | 2 yrs. 4 mos. | male | traffic accident | left | between upper & middle thirds | transverse | dia-pin | 2 yrs. | + 1cm | |
| 2 Y.Y. | 4 yrs. 7 mos. | male | traffic accident | both | distal third (r.) middle third (l.) | transverse transverse | dia-pin dia-pin | 3yrs. 11mos. | bilaterally equal | |
| 3 Y.K. | 4 yrs. | male | fallen from a swing | left | subtrochanteric | transverse | plate & screws | 4 yrs. 6mos. | + 1 cm | |
| 4 A.N. | 2 yrs. 10mos. | male | traffic accident | left | middle third | transverse | dia-pin | 1 yr. 11mos. | +0.5cm | |
| 5 Y.O. | 3 yrs. 11mos. | female | traffic accident | right | between upper & middle thirds | transverse | dia-pin | 7 yrs. 5mos. | + 1 cm | |
| 6 Y.S. | 8 yrs. | male | fallen from a swing | right | subtrochanteric | transverse | plate & screws | 11 yrs. | +0.5cm | |
| 7 T.T. | 7 yrs. | male | traffic accident | right | middle third | transverse | dia-pin | 1 yr. 6 mos. | | |
| 8 H.H. | 5 yrs. | female | traffic accident | right | middle third | transverse | intramed. nail (V) | 1 yr. 5 mos. | + 1 cm | mild infection |
| 9 K.T. | 6 yrs. | male | traffic accident | left | between middle & distal thirds | transverse | intramed. nail (clover) | 1 yr. 6 mos. | +0.5cm | |
| 10 S.K. | 6 yrs. | male | traffic accident | left | middle third | oblique | dia-pin | 3 mos. | 0 cm | |
| 11 I.H. | 9 yrs. | male | fallen from a tree | left | middle third | transverse | intramed. nail (clover) | 1 yr. 7 mos. | + 1 cm | |
| 12 K.M. | 11 yrs. | male | while playing | left | upper third | comminuted | screw & wire | 8 mos. | | |
| 13 Y.T. | 14 yrs. | male | traffic accident | left | between upper & middle third | oblique | intramed. nail (clover) | 3 yrs. | +0.5cm | |
| 14 M.U. | 14 yrs. | male | traffic accident | right | between upper & middle third | comminuted | wire & intr. nail (clover) | 5 yrs. 5 mos. | - 2.5cm | open fracture |

N.B. intramed. nail (V) = intramedullary nail of V-shape.

intramed. nail (clover) = intramedullary nail of clover-shape.

The injuries of the majority of the patients (ten patients) were due to traffic accident. Two were fallen from a swing with the resultant subtrochanteric fracture of the femur. Traction was applied in all cases for a short while from injury to surgery. As a complication, a mild infection followed the surgery in one case (Fig. 4), which lengthened inevitably the period of treatment. However, the complete healing of the infection was obtained after sequestrectomy and administration of appropriate antibiotics. The embolism, one of suspected complications after surgery, was not observed.

At review, the elongation of slight degree (0.5—1 cm) in the affected femur was detected except in the cases of bilateral affection (Fig. 7) and of severe comminution (Fig. 8). In the latter, the femur was shortened in 2.5 cm. In the measurement of the elongation, the spina-malleolar distance of both sides was compared and it was ascertained by means of the inspection of difference of knee height between both sides with the

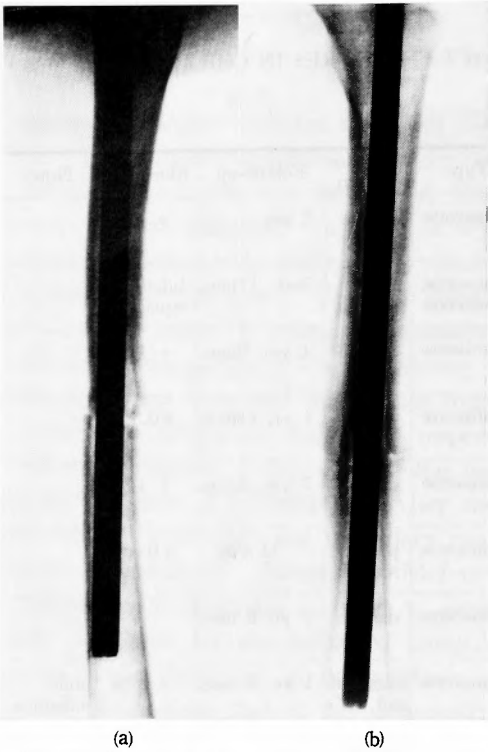


Fig. 2 Case 11. I. H., a boy aged nine years. The intramedullary nailing was carried out with the same method as that in adults.
(a) After surgery.
(b) Three months after surgery.

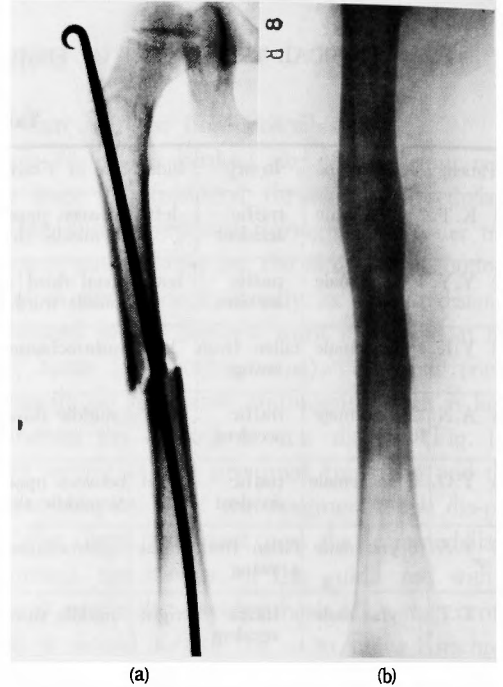


Fig. 3 Case 7. T. T., a boy aged seven years. A slender nail (dia-pin) not full of the medullary cavity suffices for the osteosynthesis. The angulation deformity did not developed owing to the early callus formation.
(a) After surgery.
(b) One year six months after surgery.

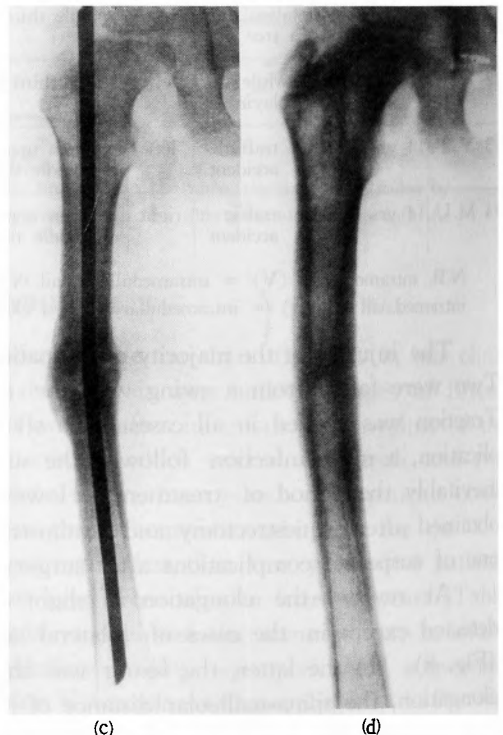
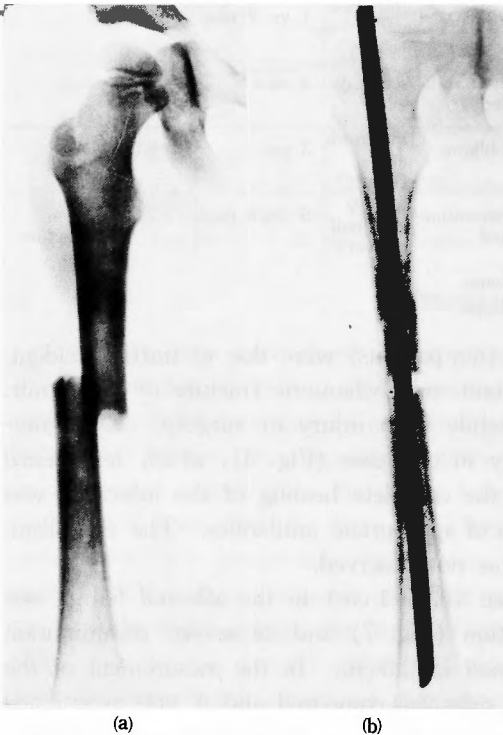

Fig. 4 Case 8. H. H., a girl aged five years. (a) After injury. (b) An intramedullary nail of V-shape was used for the osteosynthesis. A mild infection was found as a complication after surgery. roentgenogram was taken two months after surgery. (c) After the administration of appropriate antibiotics and sequestrectomy, osteomyelitis subsided. The roentgenogram was taken six months after the primary osteosynthesis. (d) The roentgenogram taken one year and five months after surgery revealed the complete healing of osteomyelitis.

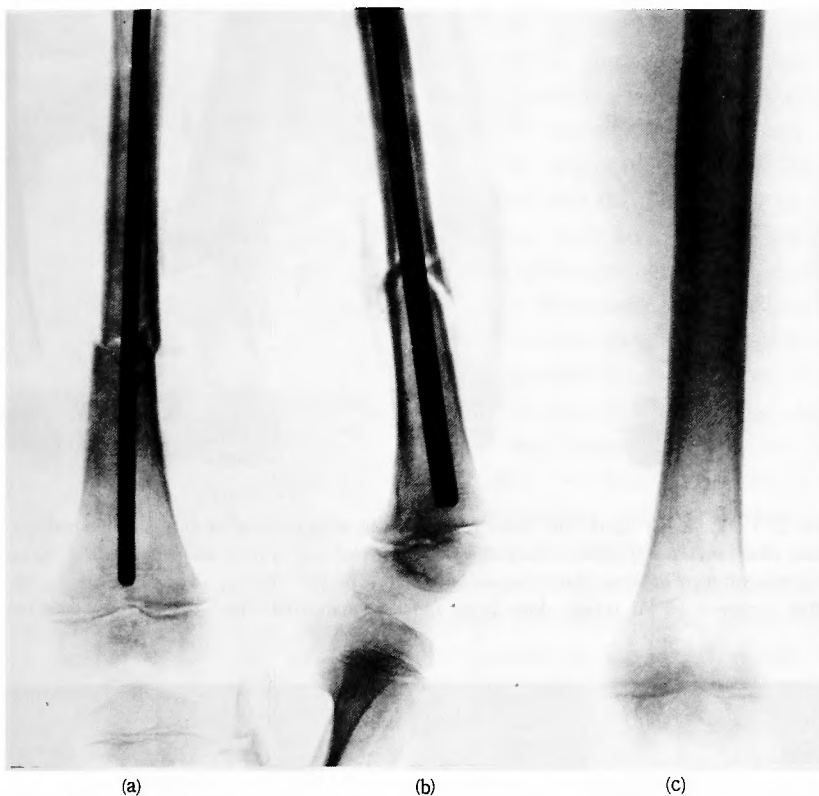

Fig. 5 Case 9. K. T., a boy aged six years. (a), (b) The intramedullary nail of clover-shape was used for the osteosynthesis. (c) The roentgenogram was taken at review one year six months after surgery.

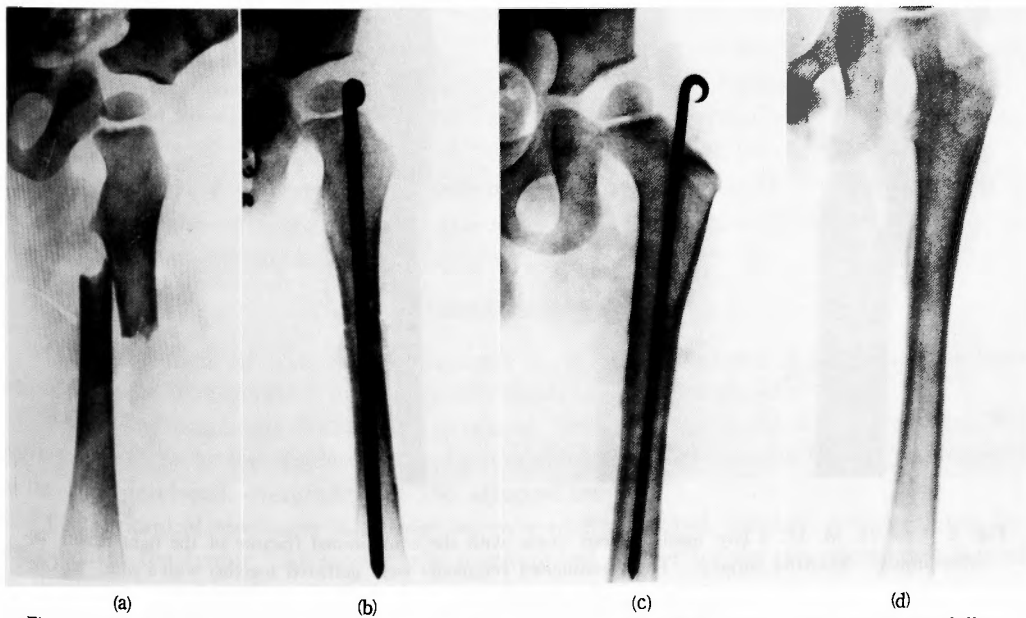


Fig. 6 Case 1. K. T., a boy aged two years and four months. (a) After injury. (b) The intramedullary nailing was attained with the dia-pin. (c) One year after surgery. (d) Two years after surgery.

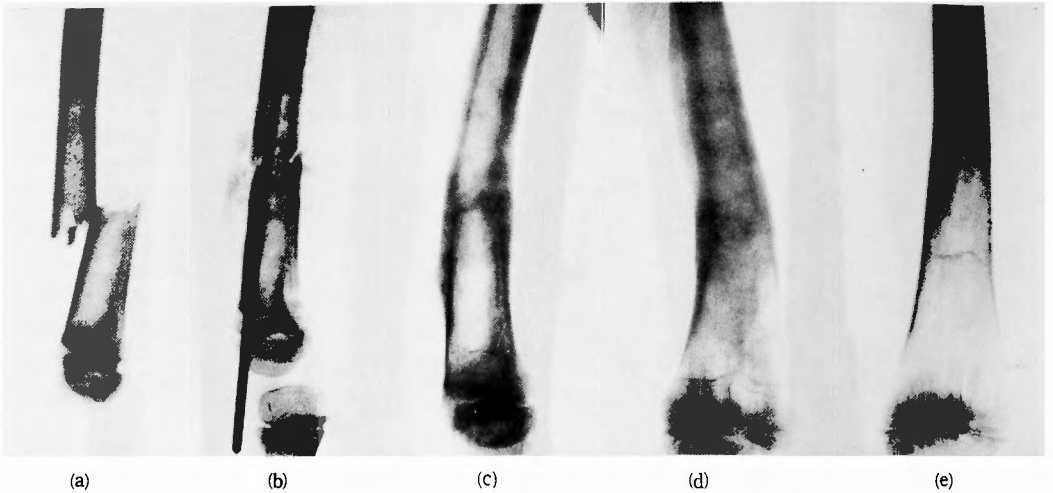


Fig. 7 Case 2. Y. Y., a boy aged four years seven months with fracture of bilateral femur-shafts. (a) The right femur after injury. (b) The osteosynthesis was carried out with a dia-pin. As the dia-pin was too long, the after-treatment of long duration was necessary for the recovery of knee function. (c), (d) Eight months after surgery. (e) At review three years and eleven months after surgery. The knee function was normal.

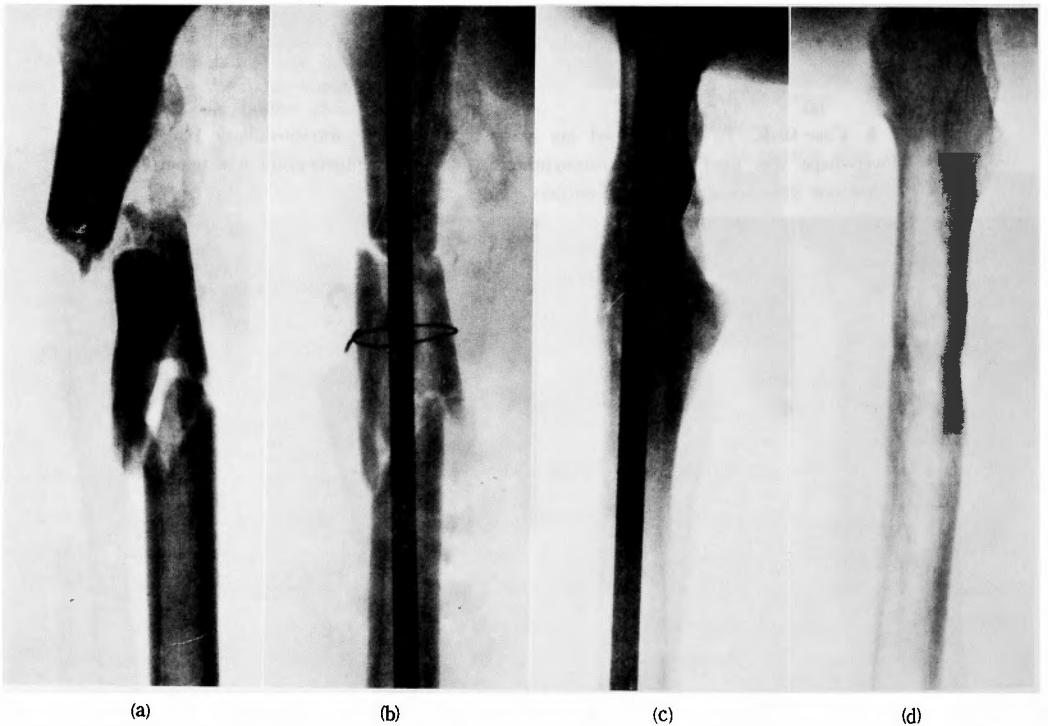


Fig. 8 Case 14. M. U., a boy aged fourteen years with the comminuted fracture of the right femur. (a) After injury. (b) After surgery. The comminuted fragments were gathered together with a wire. (c) One year after surgery. The wire had been previously withdrawn. (d) At review five years and five months after surgery. The shortening of the right femur was of 2.5 cm.

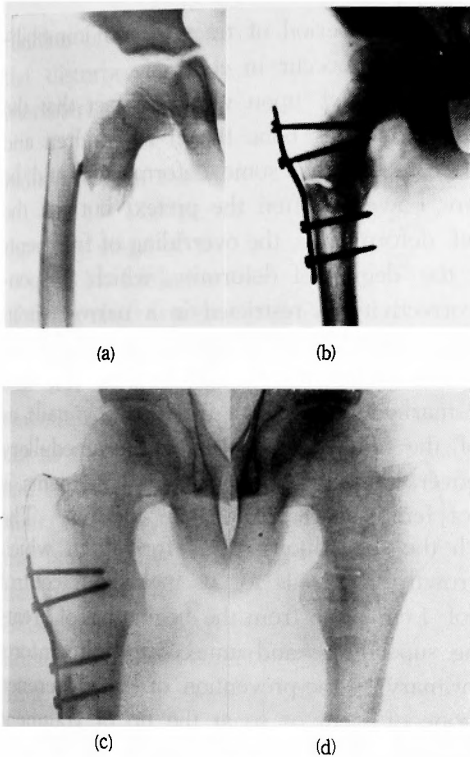


Fig. 9 Case 6. Y. S., a boy aged eight years with subtrochanteric fracture of the right femur. (a) After injury. (b) After surgery. (c), (d) At review eleven years after surgery. Any noteworthy varus or valgus deformity of the femoral neck was not observed in the affected side (c), compared with the uninjured side (d). But the overgrowth in the trochanter region was observed. The patient had refused to make the plate and screws withdrawn.

Any noteworthy varus or valgus deformity of the femoral neck was not observed at review in two cases of subtrochanteric fracture. But the roentgenograms revealed a relative overgrowth in the trochanter region (Fig. 9).

DISCUSSION

In the treatment of femur-shaft fractures in children, non-surgical treatment has been estimated better than surgical treatment, of which the basis is as follows:

(1) The fragments do not fail to fuse in children, even if the exact reduction was not obtained. As to the displacement, slight overriding of fragments is favorable in regards to the later developed overgrowth of the affected femur.

(2) Surgical treatment is a sort of over-treatment and surgery is superfluous for the fusion of the femur. Moreover, the possibility of danger for the complications followed by disastrous sequelae after surgery is great in comparison with non-surgical treatment. Those are osteomyelitis, embolism and pseudarthrosis.

patient in supine position and with the hips and knees in flexed position that the femur was responsible for the elongation. The degree of the elongation seldom differs between the cases reviewed more than one year. It suggests that the stimuli for the overgrowth did endure only for a short while after injury and the constancy of the degree of elongation explains a firm maintenance of reduction after surgery without producing superfluous stimuli for overgrowth as in the cases of fallacious and insufficient fixation. The slight elongation of the femur provides the patients in their daily life with no inconveniences and is also compatible with the vigorous activity. The firm synthesis of fragments accomplished, the immobilization with a plaster of paris cast is often unnecessary and, if needed, it is for the purpose of the repair of the soft tissues at most during two weeks after surgery. In the majority of the cases, the callus formation is apparent on the roentgenograms taken two weeks after surgery and the after-treatment can be commenced by means of a hot bath and active movement without weight-bearing. Owing to the early callus formation, a slender nail not full of the medullary cavity will suffice especially in younger patients (Fig. 3). It offers enough fixation to prevent the angulation deformity of the femur.

(3) Non-surgical treatment needs inevitably longer period of traction and immobilization. However, the knee contracture does not after all occur in children.

In this way, non-surgical treatment has been insisted upon with the fact that the displacement of fragments could not be the hinderance of the bone fusion in children and also with the presupposition of biological self-correctivity that some deformity would be corrected in the course of the growth. Those are, however, often the pretext but not the reason justifying a deformed healing. The chief deformity is the overriding of fragments and angulation at the site of fracture. In fact, the degree of deformity, which is spontaneously overcome owing to the biological self-correctivity, is restricted in a narrow limit. Blount stated that 1 cm of overriding was the ideal position for union and that side to side apposition gives a more rapid and stronger union than end to end contact. He also denied intramedullary fixation because of the marked overgrowth produced by nails as the foreign body.²⁾ However, the overgrowth of the femur in the cases of intramedullary nailing is of constantly slight degree. Moreover, the slight overriding of fragments is never the ideal position for the management of femur-shaft fractures in children. The lack of the firmness of fixation will bring forth the superfluous callus formation, which would produce much more stimuli for the overgrowth. It needs for us meticulous control over the affected thigh to keep the overriding of 1 cm or so from the beginning of treatment to the consolidation of the femur, imposing superfluous and unnecessary discomforts upon the children. It would be better, if the primary be the prevention of the difference of the femur-length, to excise beforehand the bone of 1 cm or so at the tip of fragment at surgery. However, we do not agree to such a petty conformation in the treatment of the disorder in children. For the slight elongation of the femur is compatible without any discomforts not only with the daily life but also with the vigorous activity of the patients.

In the course of femur-shaft fractures in children the characteristic features, which are the liability to fusion of fragments and no disabling knee contracture after traction and immobilization of long duration, do not lead to the conclusion that the conservative treatment is the only ideal and the best one but to the opinion that it is one of the effective methods when performed by the skilful hands. However, the difficulty of management still exists. On the other hand, the principles of fracture management in general may be described as follows:

- (1) The method must be easy to be performed with certainty.
- (2) The period of the primary treatment shortened, the after-treatment is to be initiated as early as possible.
- (3) The danger followed by disastrous sequelae must be minimum.
- (4) The pain and discomforts must be minimum in the course of treatment. It would be important for the improvement of disturbed local circulation and for the early consolidation of the broken bone.

The anatomical reconstruction of fragments leads generally to the recovery of physiological function. But in the fracture management, the problems of local circulation cannot be too much stressed upon, as were pointed out by Schnek stating the role and importance of plaster of paris cast without pad.⁶⁾ In this view-point, the traction applied until the firm consolidation of the broken site is theoretically against the physiology. The firm

fixation of fragments and free movements of the joints of the proximity will much improve the disturbed local circulation. The surgical treatment will satisfy this condition. Its characteristics may be described as follows :

(1) The procedure is carried out easily within a short time. The maintenance of reduction is of certainty and its meticulous control is unnecessary.

(2) The period of immobilization shortened, the after-treatment can be initiated in the early stage of the course. The discomforts of the patients are much decreased.

(3) Little damages to the soft tissues occur at surgery. Thus, the surgical treatment of femur-shaft fractures may be sustained by the principles of the management of fractures in general.

But we must pay much attention to the prevention of complications. Osteomyelitis, embolism, although generally less common in children,³⁾ and pseudarthrosis were pointed out as the possible complications followed by disastrous sequelae. However, osteomyelitis and embolism are not always the possible complications only of surgical treatment of femur-shaft fractures in children. Their danger may be suspected at all surgery. Therefore, the unfortunate possible complications do not afford the reason to abandon the surgical treatment only of femur-shaft fractures in children. The prevention of complications consists in the carefulness and skilfulness. Surgery must be carried out within shorter duration without superfluous damages. Desinfection at surgery and during management after surgery is to be performed with extreme caution. The general status of patients has to be properly controlled. As to pseudarthrosis, it is now of rare occurrence owing to the progress of metal for fixation and also to the intramedullary nailing. The progress of antibiotics, fixation-metal and anaesthetics enabled our active management of femur-shaft fractures in children.

Although, at first glance, surgical intervention would give us an impression of the superfluity of treatment, it decreases the discomforts and inconveniences of children discarding longer lasting traction and immobilization.

SUMMARY

- 1) Small series of femur-shaft fractures in children surgically treated is reviewed.
- 2) In the majority of cases, a slight elongation (0.5—1 cm) of the affected femur was observed at review, although it is practically negligible. Unfortunately, a mild infection was observed in one case but completely healed with the administration of appropriate antibiotics and sequestrectomy.
- 3) Surgical treatment, which is easily performed and enables the firm fixation of fragments, shortens the period of traction and immobilization. It also decreases the pain and discomforts of children.

REFERENCES

- 1) Alexis, P. G. & McIvor, R. R. : A Practical Method of Insertion of the Rush Rod in the Femur. *J. Bone and Joint Surg.* **45-A** : 1057-1058, 1963.
- 2) Blount, W. P. : *Fractures in Children*. Williams & Wilkins, Baltimore, 1955.
- 3) Crenshaw, A. H. (Editor) : *Cambell's Operative Orthopaedics*. vol. one, fourth edition, Mosby, Saint Louis, 1963.

- 4) Dameron, T. B. & Thompson, H. A. : Femoral Shaft Fractures in Children. Treatment by Closed Reduction and Double Spica Cast Immobilization. J. Bone and Joint Surg. **41-A** : 1201-1212, 1959.
- 5) Ferry, A. M. & Edgar, M. S. : Modified Bryant's Traction. J. Bone and Joint Surg. **48-A** : 533-536, 1966.
- 6) Schnek, F. G. : Die Technik des ungepolsterten Gipsverbandes. Wilhelm Maudrich, Wien, 1937.
- 7) Yoshitomi, J. & Oue, H. : Application of Kirschner Wire to Femur-Shaft Fractures in the Newborn. Seikeigeka (Orthopedic Surgery), **10** : 334-336, 1959. (Japanese)

和文抄録

小児の大腿骨々幹部骨折に対する観血的治療法

和歌山日赤整形外科

森田 信・小田 一

小児の大腿骨々幹部骨折に対する観血的治療法を過去11年間の経験14症例に基いて述べた。症例の大多数は交通事故による骨折であり、骨接合術は主として髓内釘によつたが、ブランコより転落し受傷した2例の転子下骨折に対しては内副子及び螺子で固定した。手術前の牽引及び術後のギプス固定は軟部組織の保護の目的で極短期間行なつた。術後1年以上観察した症例の範囲では患側大腿骨に一樣に軽度の延長が認められ

た。

手術療法の主もな利点は整復並びに整復位の保持が確實かつ容易であり、牽引期間或いはギプス固定期間を著るしく短縮でき、患児の疼痛を軽減させる一方、早期に後療法を行ない得るため、障害された局所の循環状態を早期に積極的に改善させ、もつて骨癒合を促進させうる点にある。