

Total Correction of Fallot's Tetralogy (II)

by

YORINORI HIKASA, HITOSHI SHIROTANI, HISAAKI KOIE, KUREO TSUSHIMI,
KOKI ABE, ATSUMI MORI and SHIGEHITO MIKI

From the 2nd Surgical Division, Kyoto University Medical School
(Director : Prof. CHUJI KIMURA)

CHUZO MORI, TETSURO KAMIYA and AKIRA NISHII
From the Department of Pediatrics, Kyoto University Medical School
(Director : Prof. Dr. ROKURO OKUDA)

NORIKAZU TATSUTA and TOKIO TAMURA

From the Tenri Hospital, Nara
(Chief : Dr. SHUNPEI YAMAMOTO)

Received for Publication Sept. 11, 1967

I FOREWORD

For the correction of Fallot's Tetralogy the following principles have been widely accepted. Corrective surgery was indicated to those patients past 5 years of age who have the diametric ratio of pulmonary artery to aorta over 50%. Corrective surgery was performed in a manner that the systolic pressure ratio between right and left ventricles was aimed to be reduced to 60% or at most to 75%, or that the right ventricle to pulmonary artery systolic pressure gradient was aimed to be reduced to 40 mmHg or less. And if needed, the reconstructive procedure of the dilatation of the right ventricular outflow tract using patchgraft was combinedly employed (Fig. 1).

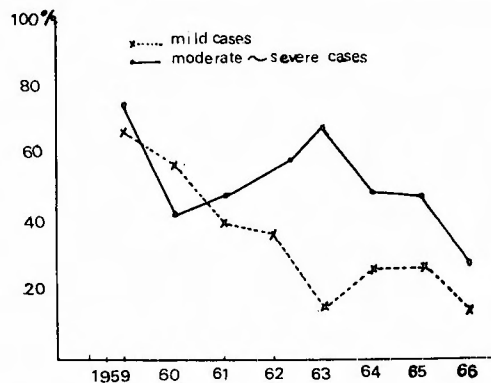


Fig. 1 Mortality in total correction of Fallot's tetralogy in Japan (1959~1966)(after Manabe)

II OUTLINE OF OUR PRESENT TECHNIQUE AND ITS GROUND

The authors too, following the above principles, had been practising the corrective surgery for the repair of Fallot's Tetralogy. The technique was : The authors adopted transverse incision for the right ventriculotomy intending to avoid the restenosis of the right ventricular outflow tract and postoperative hypofunction of the right ventricle (Fig. 2 a). Firstly, the right wing (parietal band) connected with the anterior wall of the right ventricle, which is a extension of the hypertrophic supraventricular ridge is incised. After this manipulation which results in dropping of the ventricular septum posteriorly far enough to ease further surgical procedure, the

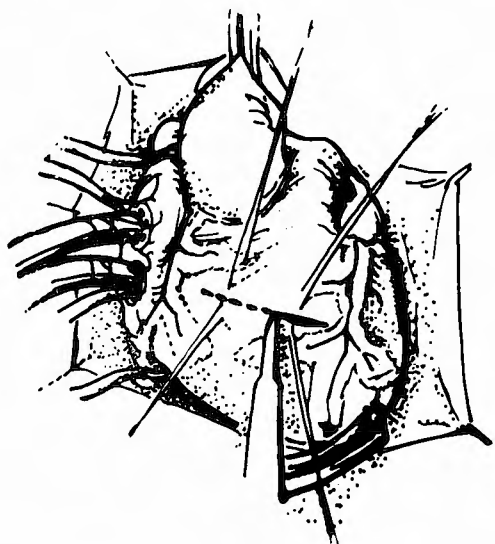


Fig. 2 a Transvers incision for the right ventriculotomy

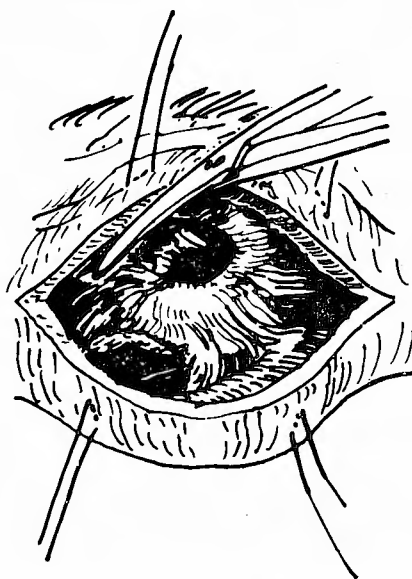
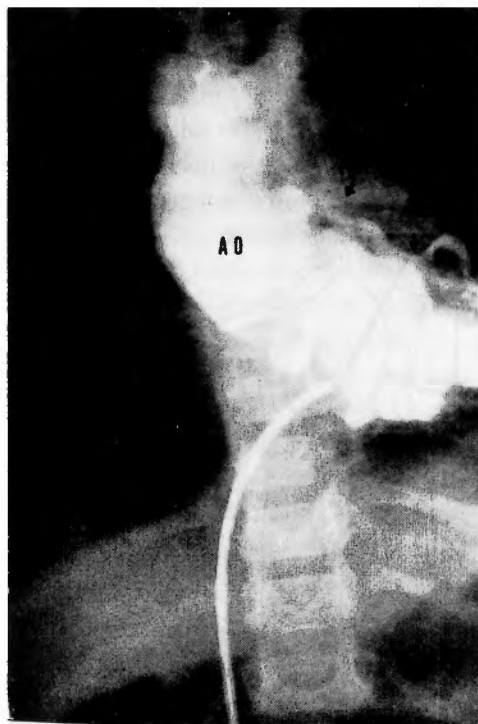
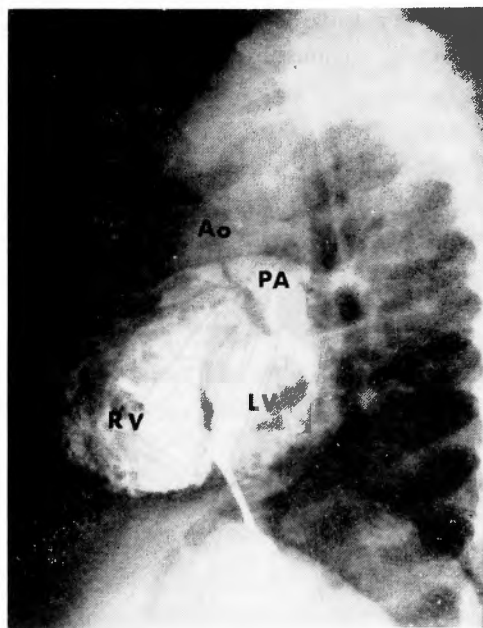


Fig. 2 b The right wing (parietal band) is incised. The reconstruction of the right ventricular outflow tract is attempted only at the site of right wing.



(Frontal)



(Lateral)

Fig. 3 Angiocardiogram

incised muscular wing is resected (Fig. 2 b). Thus the reconstruction of the right ventricular outflow tract is attempted at the site of right wing. By means of preoperative angiocardiogram, hemodynamics of the outflow tract in the normal beating state is accurately recognized before the operation (Fig. 3). And, only when definit obstructing element to the blood flow is noticed at the site of left wing (septal band), muscles of this part is excised as minimally as possible, yet as effectively as possible to remove the obstructing element. Thus the myocardium of the left wing is preserved as much as possible avoiding the injury. In most cases, the utmost manipulation to the left wing is the division or excision of the trabeculations which seem to disturb the closure of VSD. At the anterior and septal wall of the right ventricle, no surgical intervention upon the myocardium is intended, but the myocardium of the upper and lower margins of the transverse right ventriculotomy wound is sliced off, so that the closure of this wound may not cause the restenosis of the outflow tract. The utmost effort is done to the preservation of the right ventricular function and the effective reconstruction of the outflow tract of the right ventricle is performed with the minimal excision of the heart muscle. This technique was made possible owing to the accurate preoperative recognition of hemodynamics of the right ventricular outflow tract with the aid of biplane angiocardiography which has come to show a remarkable progress in its technique (Fig. 3). Then, the fibrously thickened subvalvular endocardium is excised in wedge-shape, usually only at the right side. It is cautioned not to injure the septum with this procedure. If this procedure is not possible, only longitudinal incision is placed. Using the nerve hook, pulmonary valve is turned upside down and is pulled down to the operative field, then the each commissures are divided with a knife (Fig. 2 c). Pulmonary valve dilator, which is a miniature form of Gerbode's transventricular mitral valve dilator, is inserted to the pulmonary valve orifice, and the satisfactory widening of the valvular annulus as

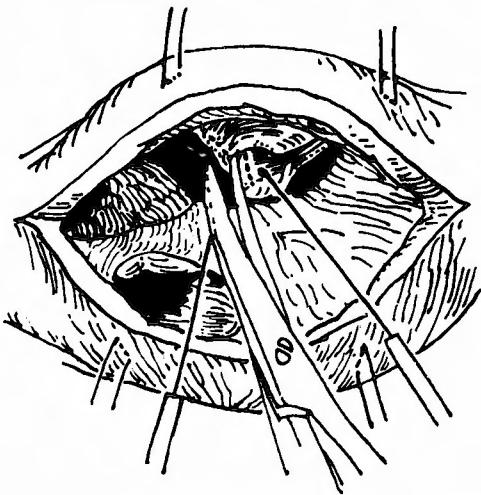


Fig. 2 c Using the nerve hook, pulmonary valve is turned upside down and is pulled down to the operative field. And the each commissures are divided.

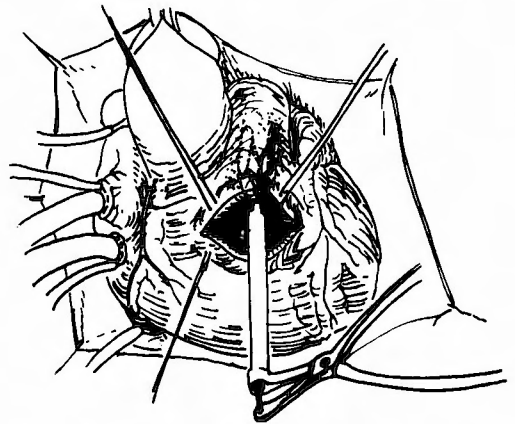


Fig. 2 d Pulmonary valve dilator is inserted to the pulmonary valve orifice and the satisfactory widening of the valvular annulus as well as the correction of the valvular stenosis is attempted.

well as the correction of the valvular stenosis is attempted (Fig. 2 d). Then, in the usual fashion, ventricular septal defect is completely closed with the doubled autogenous pericardial patch (Fig. 2 e). Without using patchgraft for the widening of the outflow tract, transverse right ventriculotomy wound is sutured and closed. With these above techniques, the authors came to have excellent operative result in the patients having the diametric ratio of pulmonary artery to aorta 50% or more.

It has been understood theoretically that the sufficient cardiac output can be maintained with the pulmonary artery, of which diameter is 30% of that of the aorta. So, the authors attempted the corrective surgery for Fallot's Tetralogy in a 15 month old baby, weighing 8.8 kg., having the pulmonary artery of which diameter was 33% of that of the aorta, and who repeated to have anoxic attacks before surgery. In this case, under the profound hypothermia of 19.4°C of rectal temperature, complete circulation arrest was done for 53 minutes. And using the technique described above, correction of Fallot's Tetralogy was successfully performed, without widening the outflow tract of the right ventricle with the patchgraft. Thus it was clinically proven that the satisfactory cardiac output can be maintained by the pulmonary artery, of which diameter is 30% of that of the aorta or so. These points were presented at the symposium at the XIXth general convention of Japanese Association for Thoracic Surgery. And the authors submitted that as far as the above technique is employed, it is not needed to use a patchgraft for the enlargement of the right ventricular outflow tract, which inevitably invite the poor right ventricular performance and the pulmonary insufficiency. Thus our technique for the total correction of Fallot's Tetralogy had come to be established in a way.

The reason why the authors came to adopt this operative technique is as follows. In spite of the theoretical assessment that the satisfactory cardiac output can be maintained with the diametric ratio of pulmonary artery to aorta around 30% or so, it has been usually accepted that the total correction of Fallot's Tetralogy was indicated only for those who showed this ratio above 50%. Moreover, even in these cases, the patchgraft was occasionally employed for the reconstructive enlargement of the right ventricular outflow tract. These facts suggest the existence of some fundamental defect in the technique of the corrective surgery which has been widely employed. Concretely speaking, this defect seems to originate from the operative procedure in which the attention is paid exclusively to the widening of the narrowed right ventricular outflow tract and the preservation of the muscular contractility of the right ventricular outflow tract is ignored. If this fact be ignored, the original function of the right ventricular outflow tract, which is to eject the blood to the pulmonary artery through the valvular orifice, is lost. That is, if extreme expression is allowed, a quite paradoxical situation of muscular contraction appears between

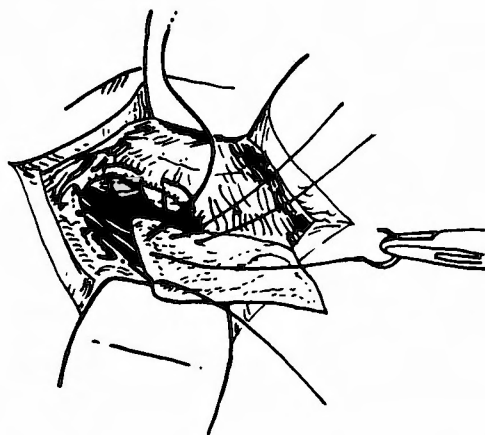


Fig. 2 e Ventricular septal defect is completely closed with the doubled autogenous pericardial patch.

two parts above and below the ventriculotomy site. The anterior wall of the outflow tract above the transverse ventriculotomy wound loses its original function, and it only bulges anteriorly extremely, how much the myocardium below the wound may contract powerfully. Consequently it may become difficult to have satisfactory flow of the blood to the peripheral part of the pulmonary artery beyond the valvular orifice, even during the systolic period. As one good example explaining this situation, it may be mentioned the fact that by the intervention upon the anal sphincter, anal incontinence is to appear inevitably when this sphincter is cut at two or more places, though it is allowed to be cut at one site.

Thus, by means of the above technique, the authors performed the corrective surgery unselectively on 21 patients of Fallot's Tetralogy who had the pulmonary arterial to aortic diametric ratio of 25% or more, after the XIXth general convention of Japanese Association for Thoracic Surgery. In all of these cases, operative correction was performed successfully, and patients were discharged in good condition. After discharge to date every patient is doing well. Age distribution of these cases ranged from 10 months to 15 years of age. Among them there was a case who underwent emergency reopening of the chest due to postoperative intrathoracic bleeding, a case who presented abnormal course of the coronary artery traversing anteriorly over the outflow tract of the right ventricle, a case who combined the branchstenosis of the left pulmonary artery, and a case who obliged to perform reoperation for the closure of the reopened ventricular septal defect which was caused by the parting of the pericardial patch sutured over this area (Table 1).

Moreover, after using the respirator for several hours postoperatively, it was not necessary to perform any particular postoperative treatment, but to keep in oxygen tent. And in all the cases which had pulmonary arterial to aortic diametric ratio of 50% or more, the ratio of right to left ventricular systolic pressure decreased immediately after surgery to the level mentioned at the beginning of this paper. In those cases in which this diametric ratio were below 50%, some of them maintained still high systolic right ventricular pressure immediately after surgery. In such cases, this high pressure rather protected well from the obstruction of the stenotic right ventricular outflow tract due to the bulging of the pericardial patch sutured over the ventricular septal defect. This bulging to the right ventricular side occurs inevitably when there exists systolic pressure gradient between the left and right ventricles. Thus this high pressure seemed to become rather a necessary condition to take uneventful postoperative course. However in such cases too, when the removal of the valvular stenosis and the widening of the annulus by means of the dilator is performed satisfactorily as described above, then right ventricular pressure seems to fall gradually spontaneously, though slowly.

Besides, the authors have to date only six cases of baby (under 10 kg of body weight) who underwent total correction of Tetralogy of Fallot during their babyhood due to frequent anoxic spell. At present in such cases, the authors perform the surgery exclusively by the technique combining our original profound hypothermic procedure which was devised and developed by the authors and partial extracorporeal circulation at the rewarming stage. All of these six cases were corrected successfully and were discharged in good condition. In the baby, even in the cases which have the pulmonary arterial to aortic diametric ratio less than 50%, the right ventricular pressure seems to fall more readily and more rapidly than in the adult cases (Fig. 4). On the other hand, for the

Table 1 Result of total correction of Fallot's tetralogy in our clinic (November 1966 ~ July 1967)

No.	Case	age	Blood		O ₂ Saturation	PA/AO Ratio	Postoperative RV/LV Ratio	Result	reference
			RBC	Hb					
1	H. M.	4 years	473 × 10 ⁴	14.5 g/dl	84.8%	0.8	0.8	survived	H-L machine
2	K. A.	11 years	468 × 10 ⁴	14.0 g/dl	94.2%	0.75	0.4	survived	H-L machine
3	T. Y.	3 years	705 × 10 ⁴	17.4 g/dl	81.8%	0.65	0.5	survived	H-L machine
4	O. T.	10 months	564 × 10 ⁴	16.8 g/dl	—	0.47	0.36	survived	deep hypothermia
5	I. M.	7 years	474 × 10 ⁴	16.4 g/dl	86.8%	0.48	0.5	survived	H-L machine
6	N. K.	13 years	667 × 10 ⁴	17.3 g/dl	76.8%	0.44	0.6	survived	H-L machine
7	Y. H.	8 years	573 × 10 ⁴	18.0 g/dl	74.8%	0.47	1.1	survived	H-L machine
8	O. M.	5 years	617 × 10 ⁴	19.9 g/dl	82.5%	0.25	1.1	survived	H-L machine
9	T. Y.	6 years	695 × 10 ⁴	17.3 g/dl	92.6%	0.77	0.5	survived	H-L machine
10	Y. K.	8 years	532 × 10 ⁴	16.1 g/dl	80.0%	0.47	0.85	survived	H-L machine
11	O. T.	10 years	683 × 10 ⁴	20.8 g/dl	73.9%	0.4	1.0	survived	H-L machine
12	H. M.	2 years	558 × 10 ⁴	17.6 g/dl	68.6%	0.34	0.53	survived	deep hypothermia
13	Y. M.	4 years	492 × 10 ⁴	16.4 g/dl	70.0%	0.47	0.71	survived	H-L machine
14	B. T.	7 years	475 × 10 ⁴	11.7 g/dl	92.9%	1.0	0.5	survived	H-L machine
15	Y. H.	2 years	701 × 10 ⁴	17.6 g/dl	76.0%	0.31	0.54	survived	deep hypothermia
16	S.	15 years	512 × 10 ⁴	16.9 g/dl	86.6%	0.53	0.5	survived	H-L machine
17	A. H.	5 years	728 × 10 ⁴	21.1 g/dl	79.0%	0.36	0.6	survived	H-L machine
18	T. K.	6 years	513 × 10 ⁴	18.6 g/dl	85.2%	0.46	0.38	survived	H-L machine
19	H. U.	12 years	488 × 10 ⁴	17.0 g/dl	87.3%	0.55	0.53	survived	H-L machine
20	W. Y.	13 years	534 × 10 ⁴	15.5 g/dl	81.7%	0.62	0.42	survived	H-L machine
21	H. M.	5 years	480 × 10 ⁴	11.7 g/dl	93.3%	0.75	0.74	survived	H-L machine

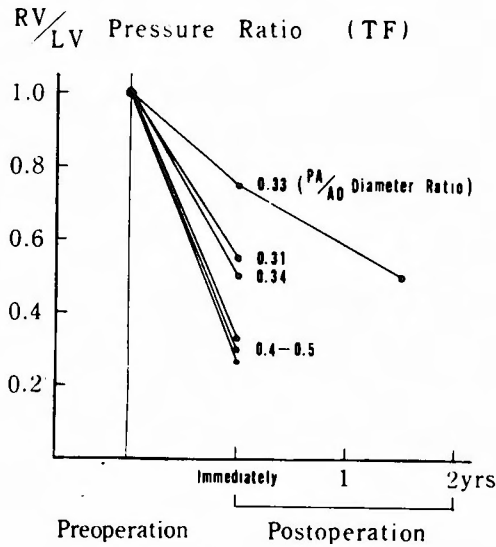


Fig. 4 RV/LV pressure ratio after operation (Six cases of baby who underwent total correction of Fallot's tetralogy).

correction of Fallot's Tetralogy in the older children, complete extracorporeal circulation by means of heart lung machine is employed. Anoxic arrest is employed as needed, and assist-perfusion is intended to be performed afterwards for the equivalent time as that of the anoxic arrest.

III SUMMARY

The outline of the technique of total correction for Fallot's Tetralogy which the authors are performing, and its ground have been described.

REFERENCES

- 1) Hikasa, Y. et al. : Open heart surgery in infants with an aid of hypothermic anesthesia. Archiv für jap. Chirurgie, **36** : 495, 1967.
- 2) Hikasa, Y. et al. : Total correction of tetralogy of Fallot. Archiv für jap. Chirurgie, **35** : 719, 1966.
- 3) Hikasa, Y. : Total correction of tetralogy of Fallot. Jap. J. Thoracic Surg., **15** : 498, 1967.

(和文抄録)

フアロー氏四徴症根治術 (第2報)

京都大学医学部外科学教室第2講座 (指導: 木村忠司教授)

日笠頼則, 城谷均, 鯉江久昭, 都志見久令男

阿部弘毅, 森渥視, 三木成仁

京都大学医学部小児科学教室 (指導: 奥田六郎教授)

森忠三, 神谷哲郎, 西井晃

天理病院心臓血管外科 (山本俊平院長)

竜田憲和, 田村時緒

従来、フアロー氏四徴症に対する根治手術の適応は5才以上で、而も肺動脈/大動脈直径比が50%以上を示すものにあり、術後、右室/左室収縮期圧比が60%以下、少なくとも75%の線に維持するか、あるいは右室-肺動脈収縮期圧勾配が40mmHg以下となる様に根治手術を施行、必要によつてはパッチ縫着による右室流出路の拡大形成術をも併せ行なうというのが、大方の今日までの根治手術方針であつた様に思われる。われわれも大体以上のような方針に則つてフアロー氏四徴症に対する根治手術を従来施行して来た。

しかしながら、従来から肺動脈/大動脈直径比が30%程度存在すれば理論的には十分な心拍出量が確保され得るものとされて来た点に鑑み、著者等は、根治手術に際し、右室横切開を用い、右室流出路のパッチ縫着による拡大形成術の如きは行なうことなく、極力右

室機能の温存に努めると共に、最少限の心筋切除で最も効果的に右翼側に対してのみ右室流出路の形成を図るよう努め、メス及び肺動脈弁用 Dilator の使用により弁狭窄の除去と弁輪の充分な開大を図り、心室中隔欠損孔閉鎖には二重自家心膜片を使用、この様な手術手技によつて適応をはるかに拡大することに成功した。

昭和41年11月より昭和42年7月に至る期間に、21例のフアロー氏四徴症患者で、而も肺動脈/大動脈直径比が25%以上を示したものに対して、無選択的にその根治手術を企て、パッチ縫着による流出路の拡大形成術の如きを併せ行なうことなく、その全例を根治、退院せしめ得た。それら症例の年齢分布は生後10ヵ月より15才にまで亘つて居り、体重10kg以下の乳児症例6例を含んでいる。