Neurohistogical Studies on Paraganglia and Paraganglioma

by

YOSHIO YOKOTA

From the 2nd Surgical Division, Kyoto University Medical School
(Director : Prof. Dr. CHUJI KIMURA)
and
Surgical Department of the Kyoto Hospital of Japan Monopoly Corporation
(Director : Dr. TAKESHI SETSUDA)

Received for Publication Aug. 23, 1968

INTRODUCTION

Chromaffin cell tissues, which are closely related histogenetically to the sympathetic nervous system[2)27)22)9)] have been named "paraganglia" by A. KOHN[20)21)]. Many reports have appeared describing the adrenal medulla, even its innervation[4)29)].

In regard to the other paraganglia, however, relatively few reports have been published [37)38)16)17)7)8)]. The "Paraganglion aorticum abdominale"[29)], has been studied by NAKATA[24)], YAMAJI[36)] and TOMINAGA[33)] of our division, and they have reported the results of their histochemical studies on the dynamic aspects of catecholamine metabolism. The continuity of chromaffin tissue between this paraganglion and the adrenal medulla has been proved[24)], but the mechanism of innervation of the former organ is not yet at all clear.

The author, therefore, has examined the innervation of this paraganglion and compared it to that of the adrenal medulla. He also reports here the neurohistologic findings in three cases of functioning phaeochromocytoma in the abdomen, each of which originated from a different paraganglion.

MATERIALS AND METHODS

Since the histologic appearance of peripheral nerve fibers varies with the age and conditon of the animal[4)], these experimental studies were all performed on healthy adult dogs between 1.5 and 4 years of age which had been examined to rule out present illness and past neurological diseases by a veterinarian.

Intravenous anesthesia (sodium pentobarbital 20-25 mg per kg) was used for operation and for killing.

The retroperitoneal tissues, including abdominal aorta, inferior vena cava and both adrenal glands were removed together from just below the diaphragm to the bifurcation of the common iliac arteries.

After removal, the specimens were fixed in 20% neutral formalin solution for at least two months.

Adrenal gland : After fixation, each adrenal gland was cut along the longer axis sagittally into 3 mm thick pieces. These were then with a freezing microtome into 20 30 μ thick slices, which were impregnated with SUZUKI's modification[30)] of BIELSCHOWSKY's

silver impregnation method.

Paraganglion aorticum abdominale : After fixation, from 1 cm below the lower pole of the left adrenal gland, retroperitoneal tissue including aorta and vena cava was cut transversely into 2 or 3 preparations 3-4 mm thick. These were enbedded in celloidin by the usual method. Celloidin blocks were cut with a microtome into 20-30 μ thick slices, which were treated with BIELSCHOWSKY-SUZUKI's silver impregnation method. Continuous slicing of the whole length of the paraganglion was not performed.

The following experiments were performed ;

1) Unilateral* section of the greater and lesser splanchnic nerves.

2) Unilateral section of the lumbar sympathetic trunk (L_1-L_6).

3) Combined section of the splanchnic nerves and lumbar sympathetic trunk on one side.

4) Bilateral section of the splanchnic nerves.

5) Bilateral section of the lumbar sympathetic trunks.

6) Combined bilateral section of the splanchnic nerves and lumbar sympathetic trunks.

7) Combined section of the anterior and posterior vagal trunk at the level of the abdominal esophagus.

8) Unilateral spinal ganglionectomy (Th_7-L_2).*

NEUROHISTOLOGICAL OBSERVATIONS

1. Adrenal gland and paraganglion of healthy adult dogs.

(A) Adrenal gland.

a) Pericapsular and capsular regions.

As many investigators have pointed out[3)18)11)5)], extremely abundant nerve bundles and nerve cell groups are seen around the adrenal gland, where the splanchnic nerves pass forming the splanchnic ganglia along their courses[22)].

Even macroscopically, some of the splanchnic nerve fibers can be seen reaching and spreading into the adrenal capsule, while others can be pursued to the celiac ganglia.

In the nerve bundles found in the pericapsular and capsular regions, small and medium-sized nerve fibers are the main components, while large ones are very few (Fig. 1). Among these fibers, nerve cells, usually small, often can be seen singly or in groups (Fig. 2). Processes and satellite cells can almost never be seen among the nerve fibers.

Groups of nerve cells forming ganglia (Fig. 3) also can be found in the pericapsular region. These nerve cells are relatively small and almost never have processes. The black granules which are often seen in the nerve cells of the sympathetic ganglia were never found. Nerve fibers in the interstitial tissue of this ganglion are extremely few as compared with those in sympathetic or celiac ganglia (Fig. 4).

In the capsule of the adrenal gland, non-ramifying or simply ramifying nerve endings, not accompanied by SCHWANN's nuclei are numerous ; these are probably sensory

* Unilateral sections were performed on the left side.
Specimens were removed two days, one week and two weeks after operation.
Pheochromocytomas
Specimens obtained from three cases of pheochromocytoma were fixed immediately after extirpation and treated by the silver impregnation method as described above.

nerve endings[28)19)26)] (Fig. 5). These nerve endings occasionally cover the adrenocortical cells of the glomerular zone.

b) Adrenal cortex.

Large nerve bundles which pass through the adrenal cortex and spread into the adrenal medulla are very striking. Nerve fibes proper to the adrenal cortex, however, are all very fine and accompanied by SCHWANN's nuclei in the intercellular space. They are all considered to be autonomic. Fibers considered to be those of sensory nerves could not be found in general, except in the glomerular zone.

c) Adrenal medulla.

Large nerve bundles, having short courses in the capsule and passing through the outer two zones of the adrenal cortex, generally become loose as they approach the corticomedullary border and form nerve plexuses which occasionally contain solitary nerve cells.

Nerve bundles, after reaching the medulla, are apt to change direction a little and, forming nerve plexuses gradually spread into the medulla (Fig. 6). These nerve bundles consist mainly of medium-sized nerve fibers, with relatively few large or small ones.

In nerve bundles which accompany blood vessels, small nerve fibers are found fairly abundantly.

The number of nerve cells scattered in the adrenal medulla is lower in dogs (Fig. 7) than in human beings. They look exactly like ordinary satellite cells, but it could not be determined whether or not they send nerve fibers into the surrounding nerve bundles or tissues.

(B) Paraganglia.

Right and left paraganglia, which are long belt-like encapsulated tissues of chromaffin cells originating from and continuous with the respective adrenal medullas, unite with each other immediately and descend in the retroperitoneal fat tissue just beneath the peritoneal membrane between the abdominal aorta and inferior vena cava until about the level of their bifurcation (Fig. 11)[7)8)24)].

a) Pericapsular region.

In the area neighboring the paraganglia, nerve bundles as well as groups of nerve cells are abundant (Fig. 8).

The nerve bundles are of three types, in general. The first type consists of only small nerve fibers, the second of both small and medium-sized fibers, and the third of one or two large fibers in addtion to small and medium-sized fibers.

A group of nerve cells forming a ganglion was not always found around the paraganglion (Fig. 10). There seems to be a reverse relationship the area occupied by the paraganglion and that by the ganglion with afferent and efferent nerve bundles. Nerve cells and nerve fibers within this ganglion are very similar to those in the celiac ganglion, but the nerve cells have fewer processes, and more nerve cells have no processes than in the celiac ganglion.

b) Capsular region.

The capsule generally consists of relatively thick collagen tissue. Depending on the level of the retroperitoneal tissue, two distinct capsules or a single capsule can be seen.

Blood vessels to the paraganglia regardless of the level in the retroperitoneal tissue, are usually accompanied by perivascular nerve fibers, and there is usually a central vein

as one of the structural characteristics of a paraganglion as in the adrenal medulla[32].

Numerous nerve bundles or fibers independent of blood vessels enter the parenchyma at various parts of the capsule. In these bundles, medium-sized nerve fibers are most abundant.

Just inside the capsule, a rare solitary nerve cell can be found as in the adrenal medulla (Fig. 12).

No nerve endings considered to be sensory in nature could be recognized in the capsule itself.

c) Parenchyma.

Parenchymal cells that have general morphological characteristics of those of ectodermal orgin tend to form cell nests which look just like those in the adrenal medulla, but they contain noradrenalin[24)36)] instead of adrenalin[13)14)15)].

Fine nerve fibers with SCHWANN's nuclei can be found in the connective tissue between these cell nests, but not everywhere in the parenchyma.

Most of the medium-sized nerve fibers, however, neither run along the connective tissue nor have SCHWANN's nuclei along their course (Fig. 9). One of them had a very strange course, independent of the cell nests, and gave off branches which occasionally seemed to twine round the parenchymal cells to resemble the arborized nerve endings of sensory cells (Fig. 13).

Special end organs containing specific nuclei, such as those described frequently in non-chromaffin paraganglia[29], were never seen in these paraganglia.

2. Adrenal gland and paraganglion of dogs following nerve sections.

1) Unilateral section of greater and lesser splanchnic nerves.

(A) Left adrenal gland on side of operation.

a) Pericapsular and capsular regions.

In the pericapsular region, as early as two days after section, granular changes in a large nerve fiber could already be seen in one nerve bundle.

In the nerve bundles in these regions, some of the large or medium-sized nerve fibers showed WALLERIAN degeneration as time progressed, but many of these fibers remained intact.

The number of small nerve fibers, considered to be either afferent or postganglionic, was greatly decreased in the capsular region, but the process of change in these fibers could not be traced.

The changes in the nerve cells in these regions could not be demonstrated clearly by the silver impregnation method only.

b) Adrenal cortex.

Both the medium sized and small nerve fibers constituting the nerve bundle passing through the cortex showed no actual change two days after the opertion, but marked degeneration was evident one week after the operation.

Some small nerve fibers, however, were left intact in other bundles even two weeks after the operation.

c) Adrenal medulla.

As early as two days after the operation, nerve fibers in the adrenal medulla seemed to be decreased generally in number.

Starting one week after the operation, evidence of degeneration was apparent in the medium-sized nerve fibers in the nerve bundles, especially in those independent of perivascular nerves (Fig. 14).

The number of fine nerve fibers running between the cell nests was also remarkably diminished, although no definite degeneration was noted.

(B) Right adrenal gland (on opposite side).

a) Pericapsular and capsular regions.

b) Adrenal cortex.

c) Adrenal medulla.

Unlike the left adrenal gland on the side of operation, the neurohistological findings in the right adrenal medulla were completely normal.

Thus, the adrenal gland appears not to have bilateral innervation by the splanchnic nerves.

(C) Paraganglion.

a) Pericapsular region.

b) Capsular region.

c) Parenchyma.

No detectable change was observed in either the nerve fibers or the nerve cells of these regions (Fig. 15).

2) Unilateral section of lumbar sympathetic trunk (L_1-L_6).

(A) left adrenal gland (on side of operation).

a) Pericapsular and capsular regions.

Starting one week after operation, in a certain area of the adrenal gland, some WALLERIAN degeneration with granular discontinuity of nerve fibers was noted in the large nerve fibers, but it was very rare (Fig. 16). Both medium-sized and small nerve fibers were, however, left intact in the bundle in which the large fiber showed degeneration.

In other areas, no degeneration could be found in any of the nerve bundles.

Small nerve fibers distributed over the capsule and considered to be sensory in nature seemed to become somewhat more scarce.

b) Adrenal cortex

In a nerve bundle passing through the cortex corresponding to the pericapsular area where degeneration was found, the same sort of nerve degeneration could be seen. In other areas of the cortex, no degeneration of nerve fibers was detected.

c) Adrenal medulla

At first glance, no remarkable decrease of nerve fibers or nerve bundles was observed. When the nerve bundles and fibers of the perivascular area were examined in detail, however, small fibers with abnormally pale impregnation, which might be caused by a decreased affinity for silver, could be seen in the nerve bundles or among the cell nests, but these were very rare.

(B) Right adrenal gland (opposite to the side of operation).

a) Pericapsular and capsular regions.

b) Adrenal cortex.

c) Adrenal medulla.

In all these regions, no degeneration of any nerve fibers was proved from two days

to two weeks after operation.

(C) Paraganglion.

a) Pericapsular region.

No degeneration was seen in the nerve bundles, and no abnormality could be detected in the nerve cells in this region.

b) Capsular region and

c) Parenchyma.

No significant decrease or degeneration of the nerve fibers was seen in these regions by two weeks after operation (Fig. 17).

3) Combined section of splanchnic nerves and lumbar sympathetic trunk on one side.

(A) Left adrenal gland (side of operation).

a) Pericapsular and capsular regions.

Signs of degeneration in the nerve cells and also in the nerve bundles, such as eccentric displacement of the nucleus, opacity of intracellular neurofibrils and WALLERIAN degeneration of nerve fibers, became definite starting one week after operation in these regions. These changes, even though they were more severe than those seen in experiments 1) and 2), were still not present in all cells and bundles.

The number of small nerve fibers in the capsule diminished greatly as time progressed, but, there was no definite evidence of degeneration.

b) Adrenal cortex.

As in the pericapsular and capsular regions, degeneration starting was apparent in most of the nerve fibers one week after the operation.

Some small nerve fibers, however, remained intact even two weeks after the operation.

c) Adrenal medulla.

As early as two days after the operation, a generalized decrease in the nmber of nerve fibers was apparent (Fig. 18).

By one week after operation, no medium-sized or large nerve fibers remained intact, and only a few small fibers could be seen. Signs of degeneration were evident in both the nerve bundles and the fine nerve fibers btween the cell nests.

The nerve fibers in the perivascular nerve bundles were also affected by this experiment.

(B) Right adrenal gland (opposite to the side of operation).

a) Pericapsular and capsular regions,

b) Adrenal cortex and

c) Adrenal medulla.

All the nerve elements remained intact in these regions at all intervals after operation.

(C) Paraganglion.

a) Pericapsular region.

Although the disappearance of the nerve fibers in the nerve bundles was not so complete as on the left side around the abdominal aorta, this experiment seemed to have a definite influence on the nerve bundles in the pericapsular region.

All of the medium-sized nerve fibers in one nerve bundle were abnormally pale, but, no definite swelling, discontinuity or destruction of nerve fibers was noted.

The nerve cells appeared completely normal.

b) Capsular region.

No abnormality was found in the nerve fibers.

c) Parenchyma.

A generalized decrease in the number of nerve fibers could be seen. A few argyrophile fragments, which might be the debris of nerve fibers, were found (Fig. 19).

4) Bilateral section of the splanchnic nerves.

(A) Left adrenal gland and

(B) Right adrenal gland.

Since no essential difference could be noted between the right and left adrenal glands, the results of this experiment will be reported for both together.

a) Pericapsular and capsular regions.

Degeneration of large nerve fibers were seen in the bundle one week after the operation.

At the same time, the distribution of small nerve fibers in the capsule was noted to be sparse.

Two weeks after the operation, most nerve fibers except for a few small ones showed marked degeneration, but the nerve cells showed no signs of degeneration.

b) Adrenal cortex.

Two weeks after the operation, only a few small nerve fibers remained visible in one nerve bundle, while most medium-sized and small nerve fibers remained intact in another bundle.

c) Adrenal medulla.

The number of visible nerve bundles and fibers, especially of those not accompanying blood vessels, was reduced, and signs of degeneration were noted in the nerve bundle one week after the operation (Fig. 20).

Two weeks after the operation, only a few small nerve fibers could be seen in the neighborhood of the blood vessels.

The number of small nerve fibers remaining visible in bundles or among cells, was a little higher in the right than in the left adrenal.

(C) Paraganglion.

a) Pericapsular region.

One large nerve fiber in a bundle showed signs of granular degeneration one week postoperatively, although the process of embedding in celloidin or of impregnation might cause such an artefact, especially in myelinated nerve fibers.

Other findings were normal.

b) Capsular region.

Medium-sized and small nerve fibers were all well visualized and appeared normal.

c) Parenchyma.

Many nerve fibers appeared normal two days or one week after the operation, but only a few could be found perivascularly two weeks after the operation (Fig. 21), although no distinct signs of degeneration were noted in the nerve bundles around the paraganglion. No nerve fiber debris was recognized in the parenchyma, either.

5) Bilateral section of the lumbar sympathetic trunks.

(A) Left adrenal gland and

(B) Right adrenal gland.

a) Pericapsular and capsular regions.

In one area, fragmentation of a large nerve fiber in on bundle was noted one week postoperatively.

The number of small nerve fibers, which ramified from a nerve bundle and were distributed in the capsule, seemed to be reduced in that area.

b) Adrenal cortex.

Starting one week after the operation, fragmentation of a large nerve fiber was noted in one nerve bundle which contained nerve fibers following a straight course.

In the nerve bundle containing many tortuous small nerve fibers, no signs of degeneration were seen.

c) Adrenal medulla.

In general, nerve bundles and fibers seemed to be slightly reduced in number.

In the perivascular region where many fine nerve fibers are normally seen, only a few were present. No signs of degenerating were apparent, however (Fig. 22).

(C) Paraganglion.

a) Pericapsular region and

b) Capsular region.

There was no evidence of degeneration here, although complete degeneration of nerve fibers was seen bilaterally around the abdominal aorta.

c) Parenchyma.

Most nerve fibers disappeared, and only a few small ones remained. An irregular medium-sized nerve fiber, which might be in the process of degeneration, was found around a vessel (Fig. 23).

6) Combined bilateral section of the splanchnic nerves and lumbar sympathetic trunks.

(A) Left adrenal gland and

(B) Right adrenal gland.

a) Pericapsular and capsular regions.

A few small nerve fibers persisted, but all large and medium-sized nerve fibers in the bundles on the left showed WALLERIAN degeneration starting one week after the operation. On the right side, one large nerve fiber remained intact as an exception even two weeks after the operation.

Nerve cells, both singly and in groups, were well preserved.

b) Adrenal cortex.

Degeneration of nerve fibers seemed to advance with time. Only a few small nerve fibers remained visible in the nerve bundles two weeks after the operation.

c) Adrenal medulla.

Most of the nerve bundles and fibers showed damage two weeks after the operation. The nerve bundles appeared as only streams of SCHWANN's nuclei (Fig. 24).

In addition to SCHWANN's nuclei between the cell nests, argyrophile bead-like threads were seen.

(C) Paraganglion.

a) Pericapsular region and

b) Capsular region.

Granular structures along the medium-sized nerve fibers were seen in most of the nerve bundles.

c) Parenchyma.

A considerable reduction in the number of all sorts of nerve fibers was noted in all cases. Several nerve fibers of medium size were found in one case (Fig. 25), but none in the others. Argyrophile granulas which might be considered debris of nerve fibers could not be found, however, in any case.

7) Combined section of anterior and posterior vagal trunks at the level of the abdominal esophagus.

(A) Left adrenal gland,

(B) Right adrenal gland and

(C) Paraganglion.

No evidence was apparent of any influence of the vagal nerve on these organs (Fig. 26).

8) Unilateral spinal ganglionectomies (Th_7-L_2).

This experiment was performed to examine the purely afferent innervation of the adrenal gland and the upper portion of the paraganglion.

Since bilateral or cross innervation by spinal ganglion cells via splanchnic nerves or sympathetic trunk had been ruled out, the operation was performed on the left side only.

(A) Left adrenal gland (side of operation).

a) Pericapsular and capsular regions.

In spite of the marked degeneration of large and medium-sized nerve fibers in the splanchnic nerves (Fig. 27) and sympathetic trunk (Fig. 28), relatively few nerve bundles in the capsule were affected.

In some bundles, most of the large and some of the medium-sized nerve fibers showed granular degeneration one week after the operation.

In the capsule, ramifying nerve fibers without accompanying SCHWANN's nuclei were of irregular width and variably pale in color along their course. This appearance probably reflects progressive degeneration.

Two weeks postoperatively, there was a marked reduction in the number of nerve fibers regarded as sensory in the capsule, although small nerve fibers with SCHWANN's nuclei, so-called autonomic nerve fibers, were not affected.

b) Adrenal cortex.

Degeneration of medium-sized nerve fibers was noted in some nerve bundles.

c) Adrenal medulla.

Generalized reduction in the number of nerve fibers was seen two weeks after operation. Furthermore, the distribution of nerve fibers was noted to be different.

In some nerve bundles, even though definite degeneration was not seen (Fig. 29), some of the medium-sized nerve fibers showed irregular width and a pale color here and there along their course.

(B) Right adrenal gland (opposite to the side of operation).

a) Pericapsular and capsular regions,

b) Adrenal cortex and

c) Adrenal medulla.

No pathological findings were found in any of these regions.

(C) Paraganglion.

a) Pericapsular region.

No definite degeneration was observed in either the nerve bundles or the nerve cells.

b) Capsular region and

c) Parencyma.

No general reduction in number of nerve fibers was noted two weeks after operation (Fig. 30).

One medium-sized nerve fiber, entering the capsule and branching off many twigs in the parenchyma, had the same irregular appearance as the one in the left adrenal capsule: marked variability of width, localized paleness in color, discontinuity and rough edges along its course (Fig. 31). No such abnormalities were noted in the same type of nerve fiber in the contralateral paraganglion.

COORDINATION OF NEUROHISTOLOGICAL FINDINGS

It will not be worth while to coordinate the results of these experiments before some discussion.

The author first examined the normal innervation of the adrenal gland and "Paraganglion aorticum abdominale" as controls for the denervation experiments.

In each of the two organs, three regions were examined neurohistologically separately, and the following findings were noted.

Adrenal gland :

a) Pericapsular and capsular regions.

Nerve bundles.

Nerve cells, singly or in groups in the nerve bundle.

Single unmyelinated small nerve fibers, with accompanying SCHWANN's nuclei, regarded as autonomic in nature.

Tapering small nerve fibers, without SCHWANN's nuclei, regarded as sensory in nature.

b) Adrenal cortex.

Nerve bundles.

c) Adrenal medulla.

Nerve bundles or plexuses.

Single nerve fibers running free from nerve bundles.

Nerve cells.

Paraganglion :

a) Pericapsular region.

Nerve bundles.

Nerve cells.

b) Capsular region.

Nerve bundles.

Single nerve fibers.

c) Parenchyma.

Nerve bundles.

Single nerve fibers.

Nerve cells.

The denervation experimets performed and the gross findings in each organ are summarized in Table 1.

Table 1 Denervation experiments perfomed and gross findings in each organ

	L-Adrenal gland*								Paraganglion						
	Pericapsular & capsular regions				Cortex	Medulla			Pericapsular region		Capsular region		Parenchyma		
	n. b.	n. c.	sensory n. f	autonomic n. f.	n. b.	n. b.	single n. f.	n.c.	n. b.	n. c.	n. b.	single n. f.	n. b.	single n. f	n.c.
1) L-Splanchnicotomy (Greater & lesser)	l (+) m (±) s (±)	?	reduced	reduced	m (+) s (±)	m (+) s (±)	reduced		intact ?	intact	intact	intact	intact ?	intact ?	
2) L-Sympathectomy (L_1-L_6)	l (±) m (−) s (−)	intact	reduced partly	reduced partly	m (±) s (−)	m (−) s (±)	intact		intact ?	intact	intact	intact	intact ?	intact ?	
3) Combined 1) & 2)	l (+) m (±) s (±)	(±)	markedly reduced	markedly reduced	m (+) s (±)	m (+) s (±)	markedly reduced		m (±) s (−)	intact	intact	intact	reduced	reduced m (+) ?	
4) R- & L-Splanchnicotomies	l (+) m (+) s (±)	?	reduced	reduced	m (±) s (±)	m (+) s (±)	reduced		m (±) ? s (−)	intact	intact	intact	reduced	reduced	
5) R- & L-Sympathectomies	l (±) m (−) s (−)	?	reduced partly	reduced partly	l (+) m (−) s (−)	reduced perivascularily	reduced perivascularily		intact ?	intact	?	intact	reduced	reduced	
6) Combined 4) & 5)	l (+) m (+) s (±)	intact	markedly reduced	markedly reduced	m (+) s (±)	m (+) s (+)	m ( ) s ( )		m (+) ? s (−)	intact	s (+) ?	?	markedly reduced	markedly reduced	
7) Vagotomy	intact	intact	intact	intact	intact	intact	intact		intact	intact	intact	intact	intact	intact	
8) L-Spinal Ganglionectomies (Th_7-L_2)	l (+) m (±) s (−)	?	reduced	intact	m (±) s (−)	m (±) s (−)	reduced		intact ?	intact	intact	m (+) ? s (−)	intact	m (+) ? s (−)	

n.b. : nerve bundle, n.c. : nerve cell, n.f. : nerve fiber, l, m and s : large, medium-sized and small nerve fibers, (+) : entirely degenerated, (±) : partly degenerated, (−) : no degeneration

* Cross or bilateral innervation was proved absent in both splanchnic nerves and sympathetic trunks. Therefore, only the findings on the left side are included in this table.

DISCUSSION

EMBRYOLOGICAL DEVELOPMENT OF PARAGANGLIA

The problem in the embryology of the sympathetic nervous system[2)27)22)9)] is that the primordial ganglion cells of the sympathetic trunk first appear in the lower thoracic and upper lumbar regions.

The future sympathetic cells are said to migrate from the lateral horn of the spinal cord along the spinal nerves, even though there are two theories about the origin of these cells and their migrating pathway[22)].

In addition to the predominantly sympathetic outflow in the thoracolumbar region, a parasympathetic outflow is considered to predominate in the cranial and sacral regions. The evidence of the powerful outflow of the primordial autonomic nerve cells in these regions may be enough to explain the abundance of nerve elements in the retroperitoneal tissue.

The chromaffin cells, which are present in large numbers in the retroperitoneal tissue, such as the adrenal medulla and paraganglion, are derived histogenetically from the primordial sympathetic cells, or sympathogonia.

The transformation from sympathogonia is considered to be as shown in the following table[1)].

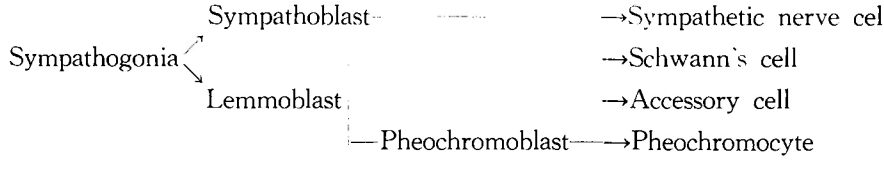

Accordingly, chromaffin cells are homologues of sympathetic nerve cells. This explains the coexistence of chromaffin cells with sympathetic nerve cells in the chromaffin tissues or along the sympathetic trunks.

The adrenal medulla is, in its histogenesis[2)27)22)9)], invested secondarily by the cortex which is derived from mesodermal tissue. In fish, cortex and medulla are quite separate, while in amphibia and reptiles, they are loosely associated. As evolution proceeds, the association between the two parts becomes increasingly intimate until in mammals the cortex encapsulates the medulla completely.

Because of the history that the two originally different glandular tissues coalesce secondarily, we often find chromaffin cell clusters within the capsule or cortex of the adrerenal gland even in dogs (Fig. 32).

Paraganglia, unlike the adrenal medulla, decline gradually after birth in human beings but do not disappear completely[7)8)]. We can find them easily in adults[24)] as dispersed masses of various sizes in the retroperitoneal tissue.

In mammals other than human beings, the paraganglia are said not to decline after birth[24)], but the author, although he did not obtain serial slices of the whole length of the paraganglia, was impressd that the findings in the paraganglia varied remarkably according to the level of that organ. This may suggest that the peraganglion tends to decline after birth even in dogs.

NERVE FIBERS AND NERVE CELLS AROUND THE ADRENAL GLAND AND PARAGANGLION

At an early embryological stage, some of the primordial sympathetic nerve cells, which form the sympathetic ganglia, continue to migrate further anteromedially to give rise to the prevertebral plexuses and the mass of chromaffin cells[22]. They leave behind some of the sympathetic nerve cells in their developmental course as solitary cells or groups of cells.

On the basis of this embryological development, it is feasible that considerable numbers of preganglionic nerve fibers as well as sympathetic nerve cells constitute the nerve elements around the adrenal gland and paraganglion.

According to the size of the axon, regardless of the myelin sheath, the author classified the nerve fibers into three types : large, medium-sized and small. The word "fine" is often used in the sense of "very small but clearly visible as a nerve fiber by light microscope". It does not correspond to the "Terminalreticulum (Stoehr)".

Medium-sized nerve fibers were the main component of the nerve bundles frequently found in the pericapsular regions of the adrenal gland and paraganglion. Small nerve fibers were much less frequently observed than medium-sized ones. More than only one or two large nerve fibers were usually found in the nerve bundle in these regions.

The greater splanchnic nerve can be pursued even macroscopically to the celiac ganglion in one direction and to the capsule of the adrenal gland in another.

This nerve contains many more medium-sized myelinated nerve fibers than small unmyelinated ones and only a very few large myelinated fibers.

On the other hand, it is generally said[22][9] that autonomic preganglionic fibers are all myelinated, whether their sheaths are thick or thin.

As a result of spinal ganglionetomies (Th_7-L_2) on one side, WALLERIAN degeneration of all the large fibers and most of the medium-sized ones was apparent in the homolateral greater splanchnic nerve as well as in the sympathetic nerve trunk on the upper lumbar region (Fig. 27, 28).

Considering these facts, the author was forced to conclude that the number of preganglionic fibers in the greater splanchnic nerve, at least via the anterior spinal nerve root, was much lower than expected. They accounted for less than one fifth of the total number of medim-sized nerve fibers in this nerve.

This lack of preganglionic fibers, however, may vary with the portion of the splanchnic nerve, because there are many sympathetic nerve cells in its course[22].

These nerve cells reputedly produce the postganglionic nerve fibers[22], but the author could not obtain the evidence for it in the nerve cells in the pericapsular region of the adrenal gland. They appeared to lack of processes both in nerve bundles and in ganglia.

It cannot be said that these nerve cells remain at a premature stage of only on the basis of silver impregnation, but they are different from those of the ganglion in the pericapsular region of the paraganglion. The latter cells had obvious processes.

This interesting problem will have to be further clarified in the near future in relation to the postneonatal development of the sympathetic nervous system[6].

Two interesting problems are raised by the evidence that the spinal ganglionectomies produced marked degeneration in most of the myelinated nerve fibers of the splanchnic

nerve, but less degeneration in the nerve bundles around the paraganglion.

One is that the preganglionic fibers in the greater splanchnic nerve, even though they divide into branches some of which constitute the nerve fibers in both the adrenal gland and the celiac ganglion, are very few so that they are in marked imbalance with postganglionic fibers.

The other problem is whether or not the number of preganglionic fibers in the lumbar splanchnic nerves differs from that in the thoracic splanchnic nerves.

After all, the experimental findings that the number of nerve fibers was reduced after neurectomy obliged the author to conclude that the sympethetic nerves play an important role in the innervation of the chromaffin paraganglia, the thoracic splanchnic nerves for the adrenal medulla and both the lumbar sympathetic nerves and thoracic splanchnic nerves for the "paraganglion aorticum abdominale".

SENSORY AND SO-CALLED AUTONOMIC INNERVATION OF ADRENAL GLAND AND PARAGANGLION

In agreement with many previous investigators[28)19)26)], the author identified nerve fibers which tapered off and blended with the surrounding tissue without any accompanying SCHWANN's nuclei as sensory in nature. They noted the peculiar "hard" look of their wavy course in comparison with the "soft" appearance of so-called autonomic unmyelinated fine nerve fibers.

T. AOKI[1)] in our division formerly divided the nerve bundles in the adrenal capsule into three types. Agreeing with his findings, the author also recognized in the capsule simply ramifying nerve endings which often covered the glomerular zone of the adrenal cortex. No corpuscular end organs were found.

In other zones of the adrenal cortex, nerve fibers clearly identified as sensory in nature were not observed.

No sensory nerve endings were found within the capsule of the paraganglion.

As already mentioned[28)29)], the nervous net-work of the paraganglia, whether chromaffin or non-chromaffin, is very peculiar. Nerve fibers are very irregular in caliber and frequently seem not to be accompanied by SCHWANN's nuclei.

In the adrenal medulla and paraganglion, the author could not distinguish the sensory nerve endings clearly from other nerve fibers considered to be preganglionic. However, the results of spinal ganglionectomy convinced the author of the existence of sensory nerve ending with tortuous and glomerular features and complicated ramifying fibers in the chromaffin paraganglion. The author found no encapsulated nerve endings or endings containing special nuclei.

In the secondary (Wallerian) degeneration of nerve fibers, is there any difference between motor and sensory nerve fibers? Furthermore, is there any true evidence of degeneration of autonomic nerve fibers?

As early as two days after splanchnic section, non ramifying or simply ramifying sensory nerve endings became undistinguishable in the adrenal capsule. The same findings have been reported in the region of the knee joint capsule after sciatic neurectomy[23)].

On the other hand, unlike the rapid disappearance of nerve fibers in motor end-plates, encapsulated nerve endings containing special nuclei like muscle spindles or PACINIAN corpuscles have been reputed to resist total degeneration of nerve fibers even eight weeks after neurectomy[23].

Some reports have supported the functional loss of the sympathetic postganglionic fibers by the disappearance of catecholamine fluorescence in the tissue[34][25]. The author believes that he proved morphologically the degeneration of small unmyelinated nerve fibers.

For that purpose, however, chromaffin tissue is rather unsuitable, because silver impregnation is somewhat difficult in chromaffin tissue where it is said to exist in much of the reducing substance. Membranous tissue, especially the meninges of the spinal cord, can be recommended for this purpose[12].

In the adrenal medulla and paraganglion, autonomic postganglionic nerve fibers must have entered the parenchyma along the blood vessels as these organs grew. In fact nerve bundles which consisted mainly of small unmyelinated nerve fibers could easily be found around the vessels. On the basis of the histogenesis of chromaffin paraganglia and also from the finding that vagotomies had no influence on them, these unmyelinated fine nerve fibers must come from prevertebral sympathetic cells. This speculation is supported by the fact that some of the so-called autonomic nerve fibers remained in the adrenal medulla and paraganglion even after combined bilateral section of the splanchnic nerves and lumbar sympathetic trunks.

NOMENCLATURE AND CLASSIFICATION OF PARAGANGLIA

Since the first nomenclator, A. KOHN[20], the term "Paraganglion" has been used variously.

From the standpoint that the paraganglia originally grow in relation to the sympathetic or parasympathetic outflow, the author agrees with WATZKA's classification[35] as follows (partly changed by the author) ;

(A) Sympathetic, chromaffin and catecholamine-producing paraganglia.

1) Paraganglion suprarenale (Adrenal medulla),
2) Free paraganglia (Chromaffin bodies),
3) Intraneural or intraganglionic chromaffin cells or cell groups.

(B) Parasympathetic, non-chromaffin paraganglia which do not produce catecholamine.

1) Paraganglion caroticum,
2) Paraganglion supracardiale,
3) Cell groups distributed in N. vagus and N. glossopharyngeus.

Though WATZKA did not include it in his classification, the author would include here

4) Coccygeal body

in relation to the sacral parasympathetic outflow.

The glomic body of arterio-venous anastomoses is still controversial.

Anyway, the author thinks it better in general to use the term "Paraganglion" qualified by the prefix "chromaffin" or "non-chromaffin", although he used it in this report as one of the chromaffin paraganglia as did earlier investigators[24][36][33] in our division.

PHEOCHROMOCYTOMAS (CHROMAFFIN PARAGANGLIOMAS)

Case 1 : Y. A., male, 24 years of age.

Catecholamine excretion in urine,

Noradrenalin : 3120 μg per day (normal range ; 56.5±11.5)

Adrenalin : 1400 μg per day (normal range ; 10.6±3.7)

V. M. A. : 44.8 mg per day (normal range ; 3-9)

Operatively confirmed that the tumor originated from the left adrenal gland.

Case 2 : M. N., female, 28 years of age.

Catecholamine excretion in urine,

Noradrenalin : 300.0 μg per day (normal range ; 52.0±15.4)

Adrenalin : 70.5 μg per day (normal range ; 7.7±2.3)

V. M. A. : 31.8 mg per day (normal range ; 3-9)

Operatively confirmed that the tumor originated from the right sympathetic nerve trunk in the upper lumbar region.

Case 3 : Y. O., female, 29 years of age.

Catecholamine excretion was not determined but tumor cells showed a positive reaction in both chromaffin reaction[10)36)] and HILLARP and HÖKFELT's technique[13)14)15)24)36)].

At operation, the tumor was formed to rest on abdominal aorta and the adrenal glands and sympathetic nerve trunks were not involved. The tumor was identified as originating from para-aortic bodies.

These three chromaffin paragangliomas (pheochromocytomas) in the abdominal region, each orginating from a different paraganglion, were examined neurohistologically. A careful examination of the subcapsular and central portions revealed no nerve fibers (Fig. 33, 34, 35).

This is a different finding from that of AOKI's case[1)].

The chromaffin tissue in the sympathetic nerve trunk is not innervated by the surrounding nerve fibers too (Fig. 36).

SUMMARY AND CONCLUSIONS

Using a silver impregnation method, the author examined the innervation of the "paraganglion aorticum abdominale" of dogs and compared it with that of the adrenal medulla.

He also examined three human pheochromocytomas neurohistologically.

The following conclusions were reached :

1) In both the "paraganglion aorticum abdominale" and the adrenal medulla, sympathetic nerve cells, sympathetic preganglionic, postganglionic and nerve fibers suspected to be sensory were observed,

2) In the former organ, both thoracic splanchnic nerves and nerve fibers from the lumbar sympathetic trunk seemed to take part in its innervation to some extent, whereas in the latter, the thoracic splanchnic nerves predominated.

3) Sympathetic postganglionic fibers seemed to accompany the blood vessels in both organs.

4) The vagal nerve sent no fibers to either organ.

5) Complicatedly ramifying sensory nerve fibers without special nuclei appeared to exist in the former organ.

6) In the three pheochromocytomas examined, no nerve elements could be clearly identified.

ACKNOWLEDGEMENT

The author offers his sincere gratitude to Prof. Ch. KIMURA for first arousing his interest in this problem and also to Dr. A. OTSU of Kansai Electric Power Company Hospital, Dr. H. SHIROTANI of Senbai Hospital and Prof. Y. ARIHARA and Dr. T. KOTERA of Osaka Medical College for their kind guidance and helpful advice.

REFERENCES

1) Aoki, T. : A neurohistological study of normal and pathological adrenal glands. Arch. Jap. Chir., **28** : 3449-3470, 1959.
2) Arey, L. B. : Developmeatal anatomy, sixth edition. W. B. Saunders Co., 1961.
3) Bardenstein, S. : Ueber nervoese Wechselbeziehungen der Nebennieren und des Paraganglion abdominale mit den anderen Organen der Bauchhoehle der Katze, Anat. Anz., **71** : 37-54, 1930/31.
4) Botár, J. : The autonomic nervous system, akadémiai Kiadó, Budapest, 1966.
5) Brauer, A. : A topographical and cytological study of the sympathetic nervous components of the suprarenal of the chick embryo. J. of Morph., **53** : 277, 1932.
6) Cohen, S., Levi-Montalcini, R. and Humberger, V. : A nerve growth-stimulating factor isolated from sarcoma 180 and 37. Proc. Nach. Acad. Sci., **40** : 1014, 1954.
7) Coupland, R. E. : The prenatal development of the abdominal para-aortic bodies in man J. Anat., **86** : 357-372, 1952.
8) Coupland, R. E. : Post-natal fate of the abdominal para-aortic bodies in man. J. Anat., **88** : 455-464, 1954.
9) Crosby, E. C., Humphrey, T. and Lauer, E. W. : Correlative anatomy of the nervous system. Macmillan Co., 1962.
10) Falck, B. and Hillarp, N. A. : A note on chromaffin reaction. J. Histochem. Cytochem., **7** : 149, 1959.
11) Hollinshead, W. H. : The innervation of the adrenal gland. J. Comp. Neur., **64** : 449-467, 1936.
12) Hayako, T. : On the nerve elements of spinal meninges in rabbits. The Central Japan Journal of Orthopaedic & Traumatic Surgery, **11** : 159, 1968.
13) Hillarp, N. A. and Hokfelt, B. Evidence of adrenaline and noradrenaline in separate adrenal medullary cells. Acta Physio. Scand., **30** : 55, 1953.
14) Hillarp, N. A. and Hökfelt, B. : Cytological demonstration of noradrenaline in the suprarenal medulla under conditions of varied secretory activity. Endocrinology, **55** : 255, 1954.
15) Hillarp, N. A. and Hökfelt, B. : Histochemical demonstration of noradrenaline and adrenaline in the adrenal medulla. J. Histochem. Cytochem., **3** : 1, 1955.
16) Ivanoff, G. : Zur Frage uever die Genese und die genese und Reduction der Paraganglion des Menschen. Z. Ges. Anat. I. Z. Anat Entw. Gesch., **77**, 234, 1925.
17) Iwanow, G. : Variabilitaeten der abdominalen Paraganglien in Kindesalter. S. Ges. Anat. I. Z. Anat. Entw. Gesch., **91** : 405, 1930.
18) Iwanow, G. : Das chromaffine und interrenale System des Menschen. Erg. Anat., **29** : 87-280, 1932.
19) Kimura, Ch. : The problems of abdominal pain. Arch. Jap. Chir., **22** : 59-66, 1953.
20) Kohn, A. : Das chromaffine Gewebe. Z. ges. Anat. 3. Ergebn. Anat. Entw. Gesch., **12** : 253, 1902.
21) Kohn, A. Die Paraganglien. Arch. mikr. Anat., **62** : 263, 1903.
22) Mitchell, G. A. G. : Anatomy of the autonomic nervous system. E. & S. Livingstone LTD., 1953.
23) Nakagawa, H. : Follow up studies on Ch-E activities of the spinal ganglia, sciatic nerve trunk and various nerve endings. The Central Japan Journal of Orthopaedic & Traumatic Surgery, **11** : 157, 1968.
24) Nakata, Y. : Histochemical studies on catecholamine with reference to paraganglia. Arch. Jap. Chir., **32** : 149-168, 1963.

25) Ogushi, N. : The autonomic innervation of the abdominal viscera. A report at 8th general meeting of japanese College of Angiology (J. Jap. Coll. Angiol., **8** : 217, 1967).
26) Otsu, A. : A histological study of sensory nerve endings in the alimentary canal of human beings and dogs. Acta Scholae med. Kioto., **31** : 103-115, 1953.
27) Patten, B. M. : Human embryology. McGraw-Hill Book Co. Inc., 1953.
28) Seto, H. : Studies on sensory innervation, first edition. Igaku Shoin Ltd., 1957.
29) Stoehr jr., Ph. : Handbuch der mikroskopischen Anatomie des Menschen, IV. Nervensystem. Springer-Verlag, 1957.
30) Suzuki, K. : Silver impregnation methoe for various tissues. The experimental therapy., 310-320 (Feb.-Dec.), 1957.
31) Takahashi, R. : Neuropathological studies on an experimental tumor. A report at 29th meeting on orthopaedic and traumatic surgery in central Japan (Takatsuki Cityl Oct. 1967).
32) Tokoro, Y. : The outline of tumors in the peripheral nervous system. No to Shinkei, **7** : 1, 1955.
33) Tominaga, S. Hlstochemical studies on catecholamines (with special reference to the paraganglion). Arch. Jap. Chir., **36** : 430, 1967.
34) Tsunekawa, K. : The autonomic innervation of the blood vessels. A report at 19th congress of research for the autonomic nervous system in Japan (Kyoto, Dec., 1966). Nervous System, **4** : 1, 1967.
35) Watzka, M. : Uever freie, chromierbare Paraganglien beim erwachsenen Menschen. Z. mikrosk. anat. Forsch., **53** : 41-45, 1943.
36) Yamaji, S. : Histochemical studies on catecholamines in paraganglia and paraganglioma. Arch. Jap. Chir., **34** : 1197, 1965.
37) Zuckerkandl, E. : Uever Nebenorgane des Sympathicus in Retro-peritoneum des Menschen. Anat. Anz., **15** : 97, 1901.
38) Zuckerkandl, E. The development of the chromaffin organs and of the suprarenal gland. Keibel and Mall's Manual of Human Embryology, **2** : 157, 1912.

和文抄録

パラガングリオン及びパラガングリオーマの神経組織学的研究

京都大学医学部外科学教室第2講座（指導：木村忠司教授）
日本専売公社京都病院外科（院長：説田　武）

横　田　祥　夫

交感神経系の発生と起源を一にし，A. Kohn (1903) によつて，パラガングリオンと名附けられた褐色細胞組織の中で，副腎髄質は，神経支配に関しても従来から多数の報告がみられるが，副腎外褐色細胞組織のそれは，比較的少ないようである．教室の仲田，山地，富永は，傍腹部大動脈の本組織に関して，主として組織化学的に，その機能を追求し報告したが，著者は犬を用いて，副腎髄質と対比しながら，本組織の神経組織学的な検索を行なつた．また腹部で，異なつた場所の本組織より発生した，ヒト褐色細胞腫の3例についても，同様の検索を行ない，次のような結論を得た．

1）傍腹部大動脈パラガングリオン及び副腎髄質に於て，自律神経細胞，交感神経の節前線維，節後線維ならびに知覚神経線維を認めた．

2）前者の器官では，胸部内臓神経以外に，腰部交感神経幹を経由する神経線維が，有意に支配しているが，後者では，胸部内臓神経の支配が圧倒的に強い．

3）両者の器官ともに，血管に随伴して来る，交感神経節後線維の支配も考慮された．

4）両者の器官ともに，迷走神経の支配を認め得なかつた．

5）前者の器官では，特殊核を有しないで，反覆二叉分岐性線維より成る糸毬状構成の，知覚終末の存在が示唆された．

6）著者の経験した3例の褐色細胞腫に関する限りでは，明瞭に確認された神経要素は発見できなかつた．

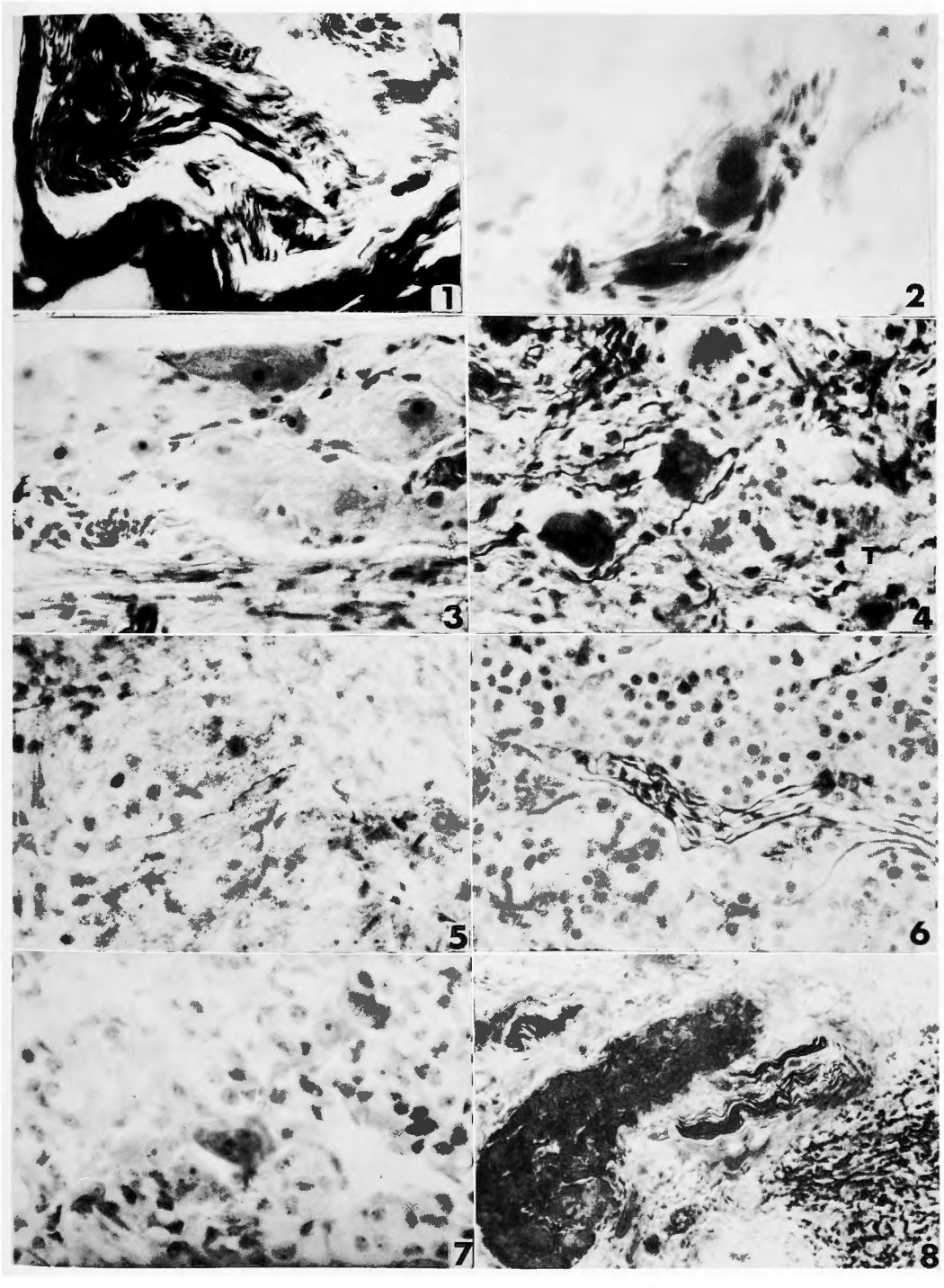
1
2
3
T
4
5
6
7
8

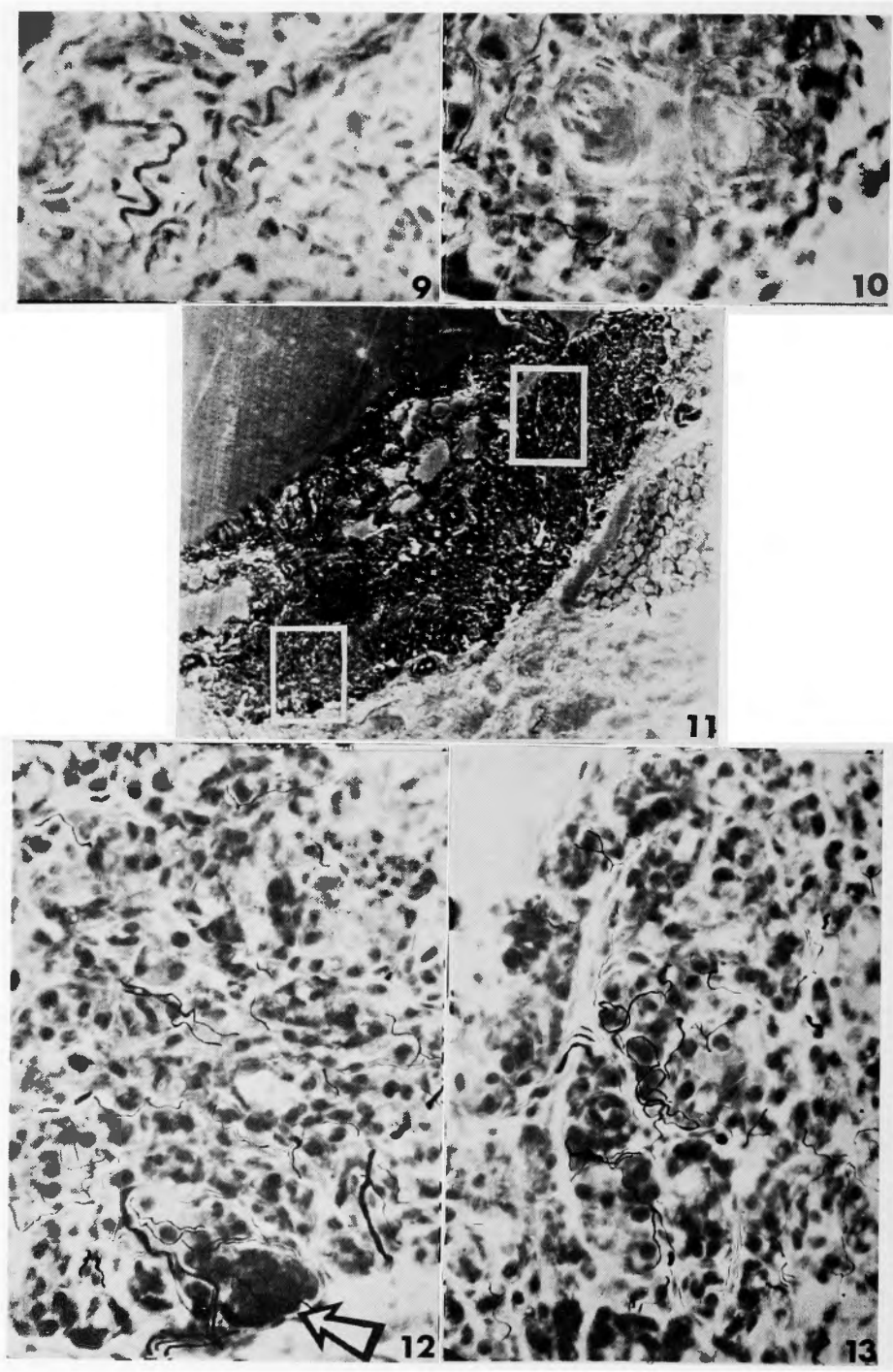
9
10
11
12
13

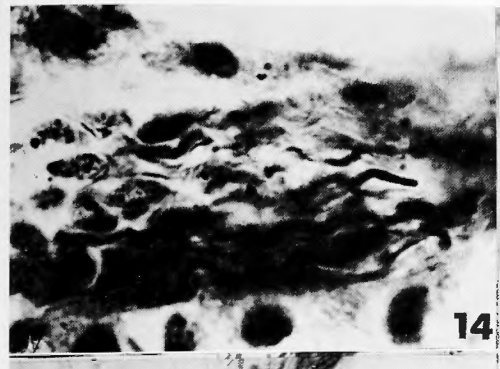
14

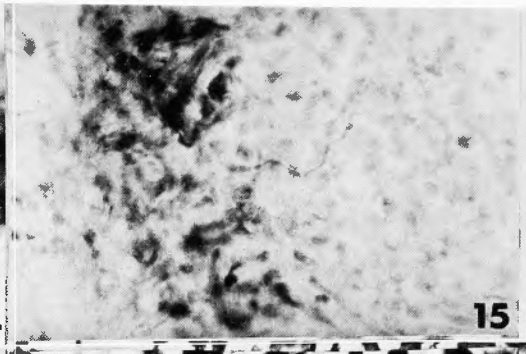
15


16

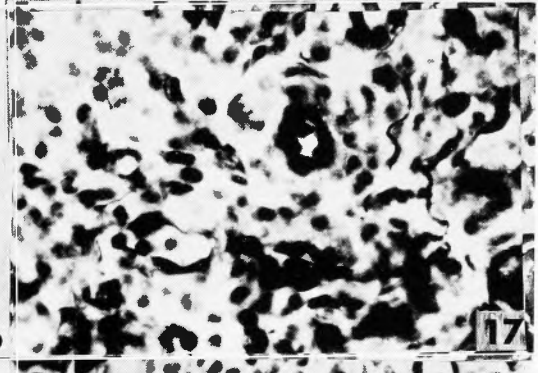
17


18

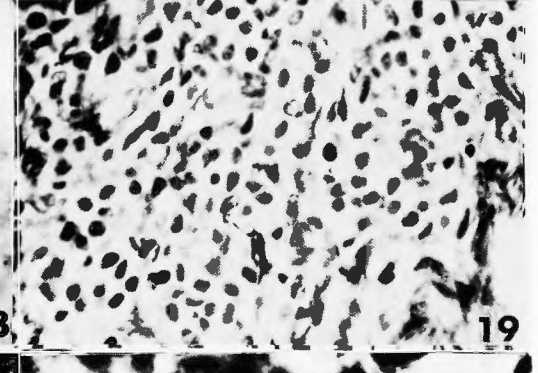
19

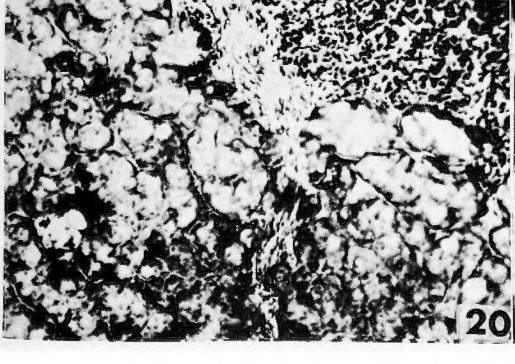
20

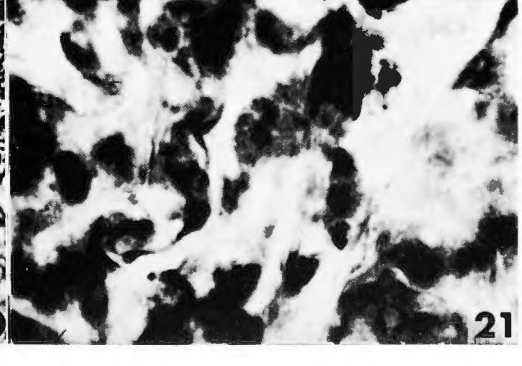
21

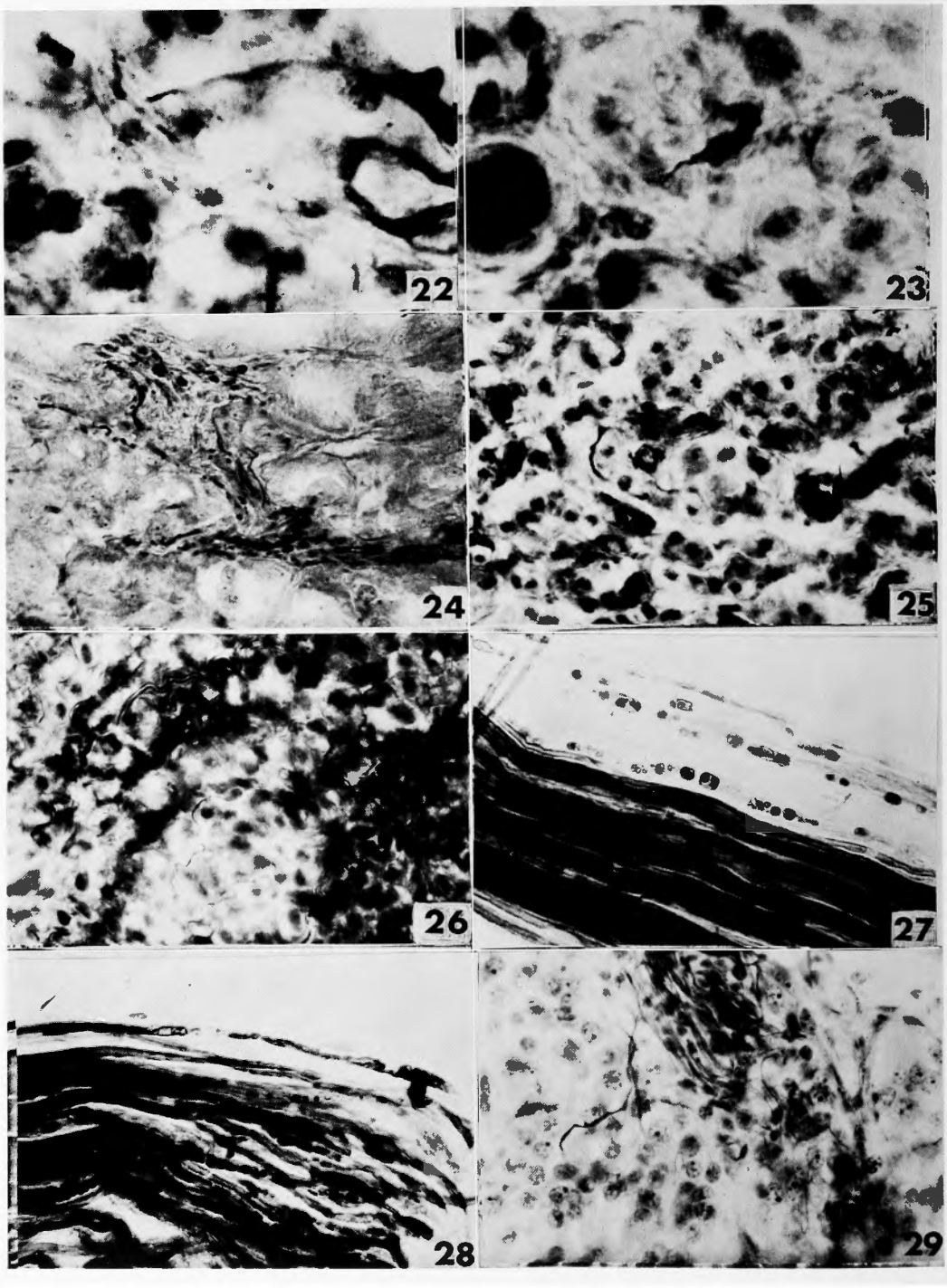
22
23
24
25
26
27
28
29

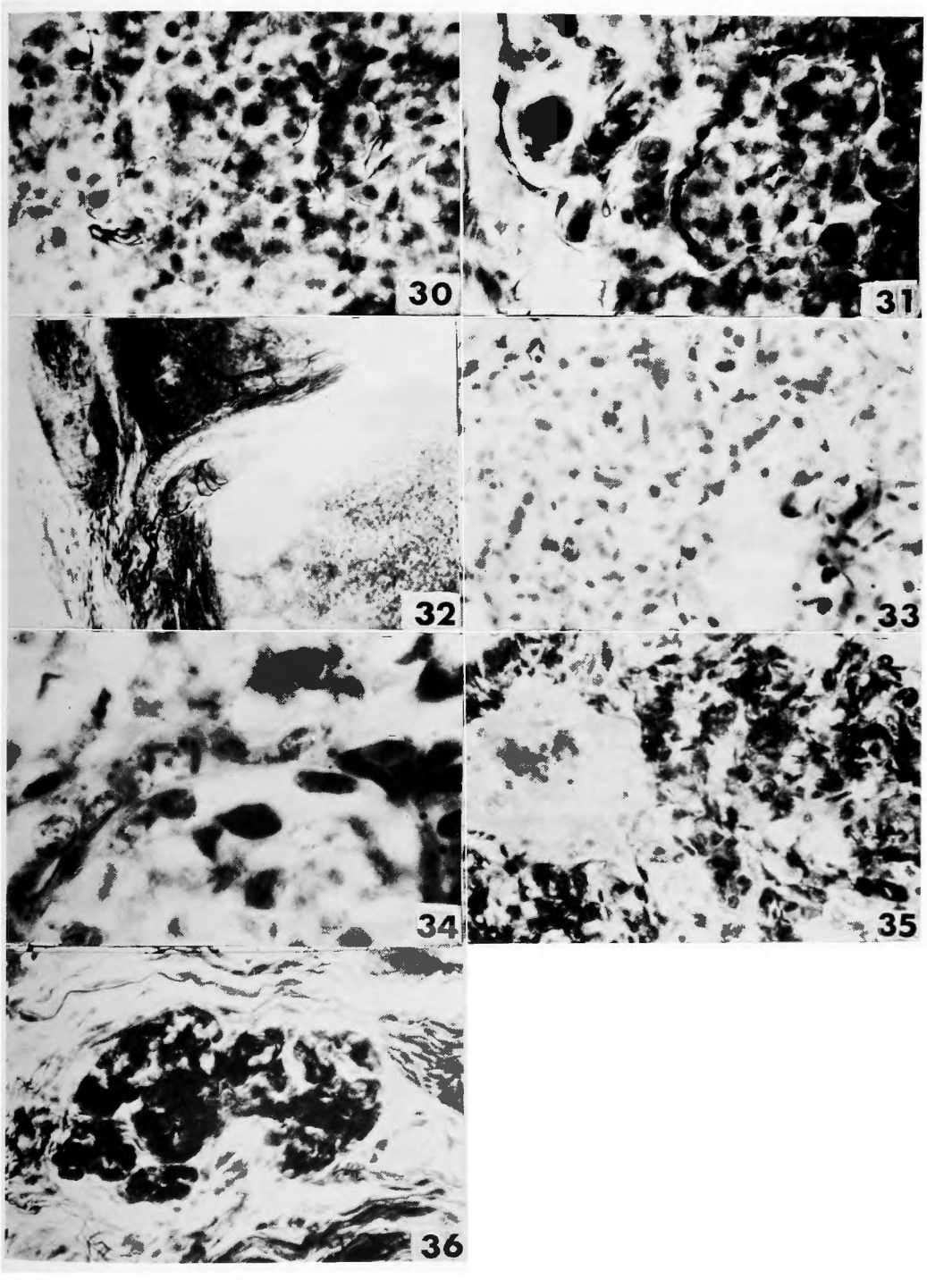
30
31
32
33
34
35
36

EXPLANATION OF FIGURES

Fig. 1 : Nerve bundle containing large nerve fiber in pericapsular region of adrenal gland. ×400
Fig. 2 : Nerve bundle containing nerve cell in pericapsular region of adrenal gland. ×400
Fig. 3 : Ganglion in pericapsular region of adrenal gland. ×400
Fig. 4 : Nerve cells in celiac ganglion. ×400
Fig. 5 : Sensory nerve ending in adrenal capsule. ×400
Fig. 6 : Nerve bundles in adrenal medulla. ×400
Fig. 7 : Nerve cells scattered in adrenal medulla. ×400
Fig. 8 : Nerve bundles in pericapsular region of paraganglion. ×100
Fig. 9 : Nerve fibers in paraganglion. ×400
Fig. 10 : Ganglion in pericapsular region of paraganglion. ×400
Fig. 11 : Paraganglion (transverse section). ×70
Fig. 12 : Nerve cell inside capsule of paraganglion (partly drawed). ×280
Fig. 13 : Sensory (?) nerve fiber in paraganglion (partly drawed). ×280
Fig. 14 : Degeneration of medium-sized nerve fibers in 1-adrenal gland (1 week after 1-splanchnicotomy). ×1000
Fig. 15 : Nerve fiber entering paraganglion (2 weeks after 1-splanchnicotomy). ×400
Fig. 16 : Granular discontinuity of a large nerve fiber in 1-adrenal capsule (1 week after 1-sympathectomy) ×400
Fig. 17 : Nerve fibers in paraganglion (2 weeks after 1-sympathectomy.) ×400
Fig. 18 : degenerated nerve bundle in 1-adrenal medulla (2 days after combined 1-splanchnicotomy and 1-sympathectomy). ×1000
Fig. 19 : Generalized dercease in nerve fibres and argyrophile fragments in paraganglion (2 weeks after combined 1-splanchnicotomy and 1-sympathectomy). ×400
Fig. 20 : Nerve bundle at corticomedullary border of 1-adrenal gland, showing no nerve fibers (2 weekis after bilateral splanchnicotomy). ×100
Fig. 21 : Nerve fiber in perivascular area of paraganglion (2 weeks after bilateral splanchnicotomy). ×1000
Fig. 22 : Small nerve fibers showing probable degeneration in r-adrenal medulla (1 week after bilateral sympathectomy). ×1000
Fig. 23 : Irregular medium-sized nerve fiber in paraganglion (1 week after bilateral sympathectomy). ×1000
Fig. 24 : Markedly degenerated nerve bundle in r-adrenal medulla (1 week after combined bilateral splanchnicotomy and sympathectomy). ×400
Fig. 25 : Bit of irregular nerve fibers in paraganglion in one case (1 week after combined bilateral splanchnicotomy and sympathectomy). ×400
Fig. 26 : No effect in paraganglion (1 week after vagotomy). ×400
Fig. 27 : Marked degeneration in 1-aplanchnic nerve (1 week after 1-spinal ganglionectomy). (OsO_4 staining) ×400
Fig. 28 : Degeneration in 1-sympathetic trunk (1 week after 1-spinalganglionectomy). (OsO_4 staining) ×400
Fig. 29 : Less severe degeneration in 1-adrenal medulla (1 week after 1-spinal-ganglionectomy). ×400
Fig. 30 : No generalized reduction in number of nerve fibers in paraganglion (2 weeks after 1-spinal ganglionectomy). ×400
Fig. 31 : Degenerating sensory (?) nerve ending in paraganglion (2 weeks after 1-spinal ganglionectomy). ×400
Fig. 32 : Nerve fibers surrounding cluster of chromaffin cells in adrenal capsule. ×100
Fig. 33 : Pheochromocytoma, Case 1. ×400
Fig. 34 : Pheochromocytoma, Case 2. ×400
Fig. 35 : Pheochromocytoma, Case 3. ×400
Fig. 36 : Cluster of chromaffin cells in pericapsular region of sympathetic ganglion (L_4). ×400