Arch. Jap. Chir. 38(1), 3~11, Jan. 1969

原　　著

Lenticulo-Striate Arteries in Hypertensive Intracerebral Hemorrhage as Demonstrated by Angiography

by

HARUYUKI KANAYA, SETSUO ONO, YUTAKA HORIE
and KATSUMARO OANA

Department of Neurosurgery, Iwate Medical University, School of Medicine

Received for Publication Nov. 12, 1968

Among the arteries perfusing the internal and external capasules as well as the basal ganglia, two perforaturs branching from the anterior cerebral artery and middle cerebral artery are distinguished; the former being called the recurrent artery of Heubner or A. striatica rostralis, the latter the lenticulostriate artery, strio-thalamic artery or A. striatica caudalis. No uniform terminology is presently available.

The lenticulo-striate artery has frequently an abnormal course in association with lesions in the deep part of the brain, so that the cerebral angiographic diagnosis becomes important. Only the description by HEUBNER[4], WESTBERG[8], ANDERSEN[1)2)], and other is available. Since the report of Charcot and BOUCHARD (1868)[3] stating that this artery was invariable found ruptured miliary aneurysma on its smaller arterial branches, particularly the lenticulostriate arteries in hypertensive and arteriosclerotic apopletic brains, the artery causing apoplexy has drawn widespread attention (A. apoplectica). In actual autopsy, the site of hemorrhage was frequently found in the perfusing area of this artery. Although the importance of this artery in diagnosis is recognized, its detailed angiographic studies were not reported.

Since 1956 we[5)6)7)] have continued studies on the surgical therapy of severe hypertensive intracerebral hemorrhage. The rate of salvage is 72% in the capsular type according to my classification and much lower in other types. A high correlation was found between posthemorrhagic vital sign and neurologic signs and the location and volume of the hematoma. It is therefore very important to know the location and volume of the hematoma before choosing surgical intervention.

The present communication deals with the diagnositic significance of cerebral angiography of the lenticulo-striate artery in cases of hypertensive intracerebral hemorrhage with hematoma of known location and volume, confirmed by autopsy and operative findings, the pontine and cerebellar hemorrhage is out of consideration.

MATERIALS AND METHODS

Sixty-six cases of hypertensive intracerebral hemorrhage were selected. The location of the hematoma was classified into 3 following types from the standpoint of surgical management. The capsular type which was named for hematoma in the internal capsule and its lateral side comprising internal and external capsule, caudate nucleus, putamen and globus pallidus was seen in 41 cases. The thalamic type, hematoma in the thalamus and hypothalamus was seen in 1 case. The capsulothalamic type in which the hematoma extended to the surface of the thalamus and hypothalamus was seen in 25 cases. As controls, 49 cases of arteri osclerosis according to the WHO classification and 100 normal young subjects without intracranial lesions and arteriosclerosis were selected.

Carefid angiography was carried, using about 10 cc of 60% urografin. Angiography was carried out in hypertensive intracerebral hemorrhage one day after stroke in 45 %, 2 days after stroke in 18 %, 3 days after stroke in 13 %, and beyond this stage in 24%.

For the estimation of filling frequency, clear visualization of the lenticulo-striate artery with diagnostic usefulness was called "*fair filling*", visualization of the main artery without diagnostic use on account of the unclear course of the vessel was called "*poor filling*", and failure of visualization of the main cerebral artery was called *non-filling*.

In the measurement of the lenticulo-striate artery in the anterior-posterior view, S was defined as the distance between the sagittal line and the point of branching of this artery from the middle cerebral artery, while the distance to the most lateral point in the course of this artery was called "S',, (Fig. 1).

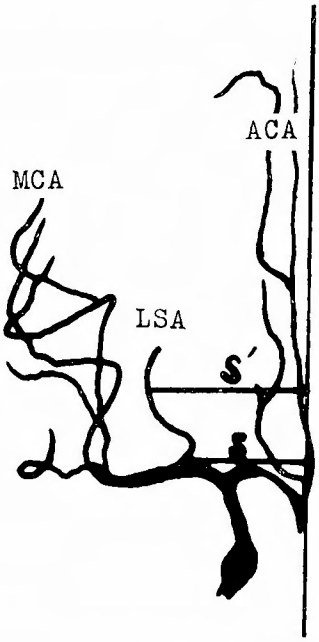

Fig. 1. saggital line
S : The distance between the saggital line and the point of branching of lenticulo-striate artery
S' : The distance to the most lateral point in the course of this artery
ACA : Anterior cerebral artery
MCA : Middle cerebral artery
LSA : Lenticulo-striate artary

FILLING FREQUENCY

In normal controls, the filling frequency of thelenticulo-striate artery was seen in 91 of 100 subjects, in 43 or 49 arteriosclerotic subjects or 88%, and in 51 of 66 cases of hypertensive intracerebral hemorrhage or 77%. Fair filling was obtained in 66 of the normal subjects or 66%, 29 arteriosclerotic subjects or 59% and 41 cases of hypertensive intracerebral hemorrhage or 62%.

Cerebrospinal fluid pressure

In cases of hypertensive intracerebral hemorrhage with cerebrospinal fluid pressure less than 100 mmH_2O, *fair and poor filling* of the lenticulo-striate artery was seen in 5

of 6 cases or 83%, while the corresponding figures were 14 of 18 cases or 78% in those with a pressure of 101-200 mmH_2O, and 10 of 12 cases or 83% in those with a pressure of 201-300 mmH_2O, and 13 of 21 cases or 62% in those with a pressure more than 301 mmH_2O, suggesting a marked decrease more than 301 mmH_2O.

Hematoma location

The frequency of fair and poor filling in the capsulothalamic type was 16 of 25 cases or 64%, while the corresponding figure was 35 of 40 cases or 88% in the capsular type, and 1 of 1 case of the thalamic type. The frequency of fair filling alone was seen in 13 cases or 52% of the the capsulothalamic type, 26 cases or 65% of the capsular type, suggesting a higher frequency of visualization in the capsular type than in the capsulothalamic type.

Hematoma volume

The *fair filling* was obtained in 32 of 44 cases or 73% in cases with a hematoma volume of less than 100 cc while a similar finding was obtained in 7 of 19 cases or 37% when the hematoma was more than 101 cc, suggesting a decrease in the rate of *fair filling* as the volume of hematoma increased.

Secondary ventricular hemorrhage

In hypertensive intracerebral hemorrhage accompanied by intraventricular hemorrhage, *fair aud poor filling* was obtained in 39 of 50 cases or 78%, while the corresponding figure in cases without intraventricular hemorrhage was 11 of 16 cases or 69%. Fair fillig was seen in 8 cases or 50% of cases without intraventricular hemorrhage, suggesting a higher frequency of visualization in cases with intraventricular hemorrhage.

COURSE OF THE LENTICULO-STRIATE ARTERY (Table 1)

Distance S: The distance from the sagittal line to the point of branching of the lenticulo-striate artery from the middle cerebral artery was 21-25 mm in 40 of 66 normal controls with fair filling or 60.6%, and in 16 of 29 cases of arteriosclerosis or 55.2%.

Table 1 Measurement of the lenticulostriate artery by cerebral angiogram in the anterior-posterior view

Distance \ Cases		Normal control	Arteriosclerosis	Hypertensive intracerebral hemorrhage	
				Capsular type	Capsulothalamic type
	(mm)	%	%	%	%
*S	~20	12 (18.2)	0	8 (29.6)	2 (15.4)
	21~25	40 (60.6)	16 (55.2)	13 (48.2)	10 (76.9)
	26~30	11 (16.7)	10 (34.5)	4 (14.8)	0
	31~	3 (4.5)	3 (10.3)	2 (7.4)	1 (7.7)
**S′	~25	1 (1.5)	0	16 (66.7)	2 (15.4)
	26~30	25 (37.9)	4 (13.8)	5 (20.8)	2 (15.4)
	31~35	35 (53.0)	16 (55.2)	2 (7.4)	5 (38.5)
	36~	5 (7.6)	9 (31.0)	4 (14.8)	4 (30.8)

* Shows the distance between the sagittal line and the site of branching of the lenticulostriate artery from the middle cerebral artery.

** Shows the distance to the most lateral point in the course of the lenticulostriate artery.

Both showed high frequencies.

S′: The distance from the sagittal line to the outermost point in the course of the lenticulo-striate artery was 31-35 mm in 35 of 66 normal controls with *fair filling* or 53%, while the corresponding figure was 16 of 29 cases of arteriosclerosis or 55.2%.

Distance ratio S′/S: The lenticulo-striate artery branched from the middle cerebral artery to become medial and lateral branches, running parallel each other. In hypertensive intracerebral hemorrhage, not all these branches were visualized in hypertensive intracerebral hemorrhage because of the rupture of these branches of the lenticulo-striate artery or the hematoma compression. One or two of these were occasionally visualized. The evaluation of the degree of displacement due to hematoma was difficult to make on the basis of the actual distance measured S′. The practical clinical value was also limited. The distance ratio (DR) S′/S (Table 2) was therefore introduced.

Table 2 Relation between hematoma site and distance ratio (D. R.) of the lenticulostriate artery by cerebral angiogram

D. R. (S/S′)	Hypertensive intracerebral hemorrhage	
	Capsular type	Capsulothalamic type
less than 1.10	15 (93.7%)	1 (6.3%)
above 1.11	12 (50%)	12 (50%)

Normal controls

The average value of DR in 66 cases of *fair filling* was 1.35, and the lowest value was 1.10. Values ranging from 1.21 to 1.40 were seen in 41 cases or 62.1%.

Arteriosclerosis

The average value of DR in 29 cases of *fair filling* was 1.33, and the lowest value was 1.12. Values ranging from 1.21 to 1.40 was seen in 11 cases or 37.6%, values ranging from 1.41-1.60 in 9 cases or 31%, and values ranging from 1.00-1.20 in 8 cases or 27.6%. These values failed to show a certain tendency as compared with normal values, probably due to the frequent variations in the course in arteriosclerosis.

In both normal cases and cases of arteriosclerosis, DR was larger than 1.10, so that values less than this were considered to be pathologic.

Hypertensive intracerebral hemorrhage

In 40 cases of *fair filling* the average DR value was 1.14, representing values lower than those in normal arteriosclerotic and cases, probably because many cases of the capsular type in this group as will be stated in the subsequent section.

Hematoma location

Average DR was 1.39 in capsulothalamic type, 1.01 in the capsular type and 1.42 in the thalamic type. Above DR 1.10, 12 cases were found in each of the capsulothalamic type and capsular type, so that the differentiation between these two groups is rather difficult. Among cases with DR of less than 1.10, 15 of 16 cases or 93.7% were of the capsular type, while only 1 was of the capsulothalamic type (Fig. 2). When the lenticulo-striate artery lost the S shaped curve and stood up straight against the cranial base or showed medial displacement, most of them belonged to the capsular type. After the evacuation of the hematoma, this artery returned to its normal position and pattern (Fig. 3, 4).

Hematoma volume: Among 37 autopsy cases, DR was 1.52 in 7 cases of the capsulothalamic type with the volume of hematoma less than 100 cc, while the corresponding

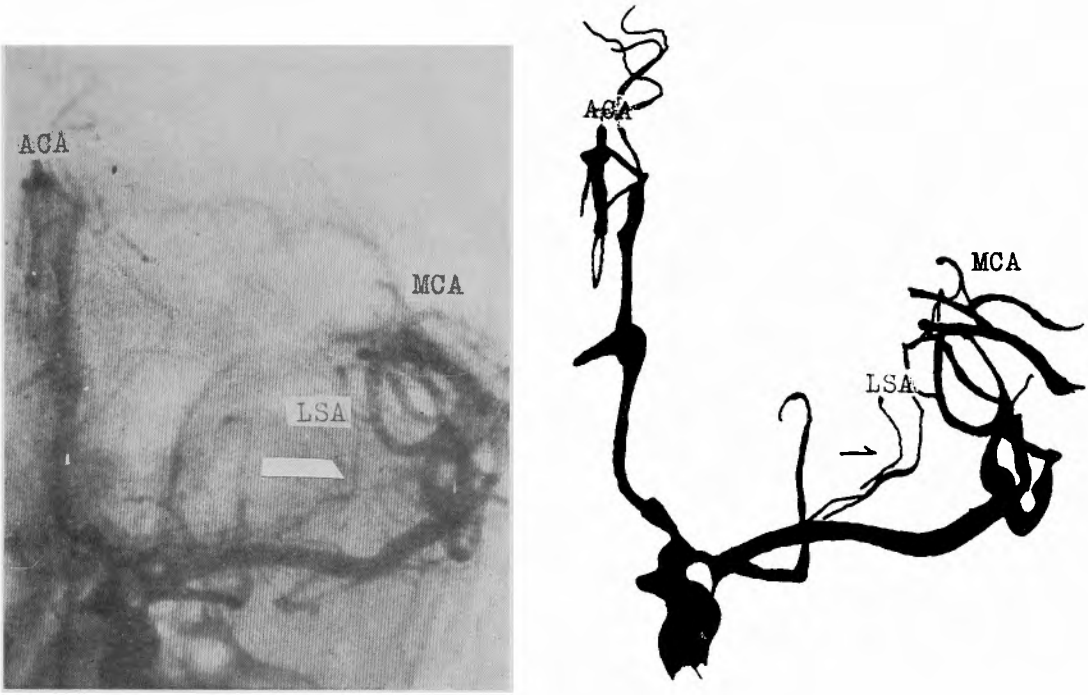

Fig. 2. 61 years old male with deep coma and right hemiplegia. Angiogram, two days after stroke, reveals no shift of main cerebral arteries and lateral shift of lenticulo-striate artery. Small hematoma (20 g) extending thalamus and internal capsule was shown in autopsy. (thalamocapsular type).

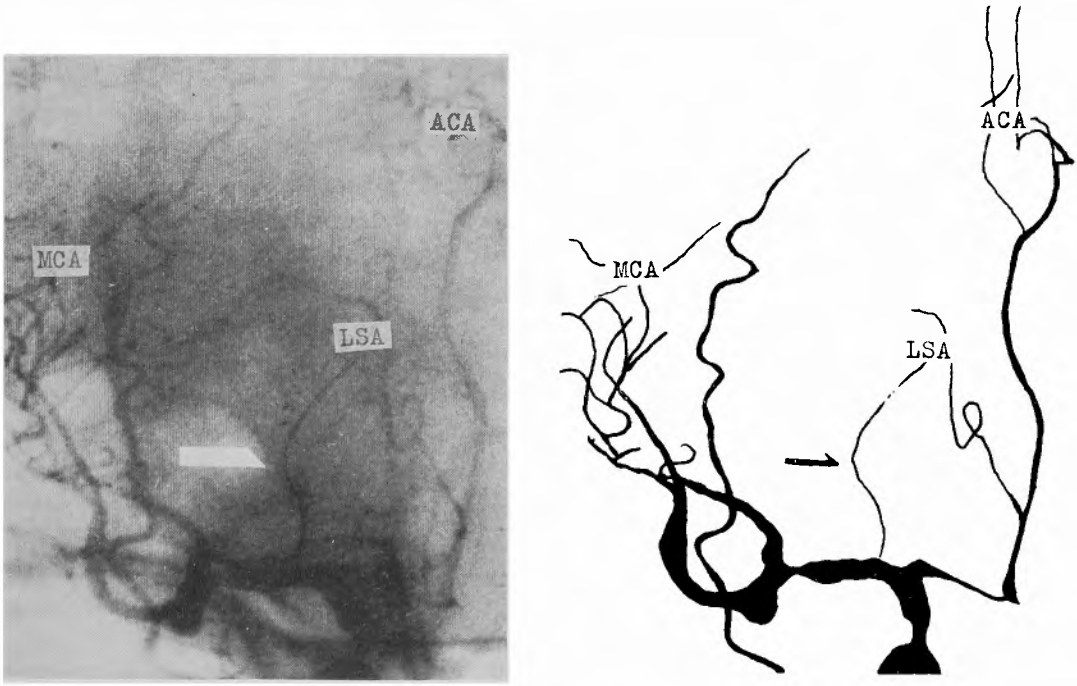

Fig. 3. 53 years old male with semicoma and left hemiplegia. In angiogram at second day after stroke, there is no pathological findings of main cerecral arteries except square shift of anterior cerebral artery. Lenticulo-striate artery stands up straight against the cranial base. Operation : Total evacuation of hematoma (40 g) extending internal capsule and its lateral site (capsular type).

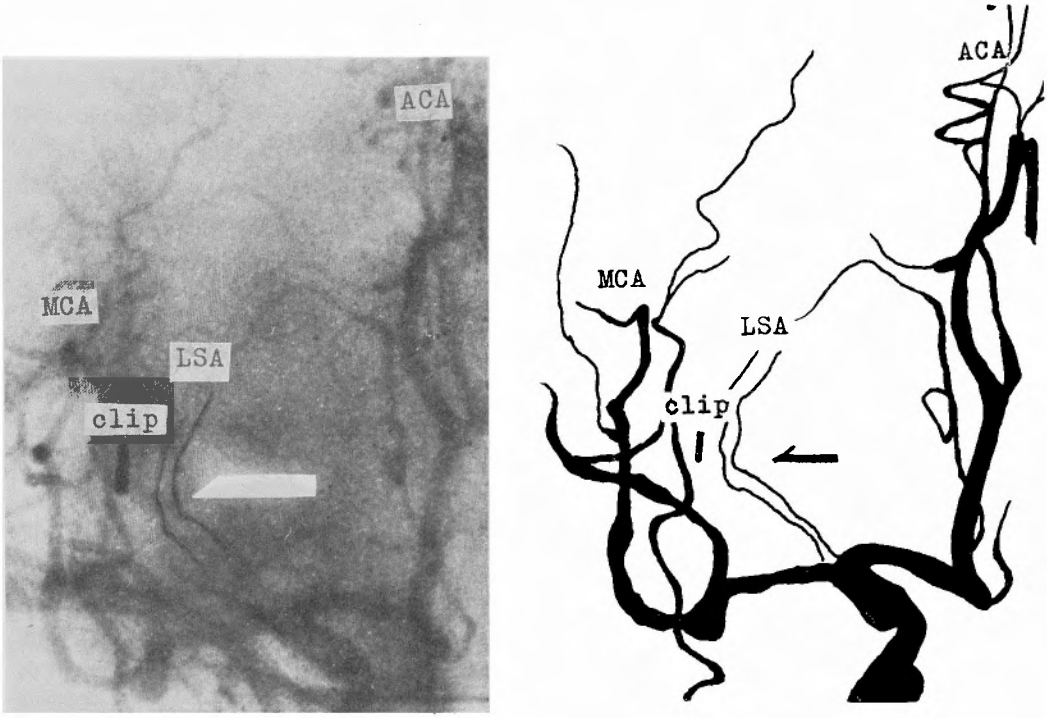

Fig. 4. In angiogram at fifty days after operation, lenticulo-striate artery returns to its normal pattern.

value was 1.01 in 20 cases of the capsular type, and 1.42 in one case of the thalamic type, showing a correlation with the volume of the hematoma. Above 101 cc DR was 1.20 in 6 cases of the capsulothalamic type and 1.07 in 3 cases of the capsular type.

Diameter of hematoma: In autopsy, the largest transverse diameter of the hematoma of less than 40 mm was associated with DR of 0.71 in the capsular type and 1.73 in the capsulothalamic type. Above 41 mm, no correlation was found between this and transverse diameter of hematoma.

Secondary ventricular hemorrhage

In the capsulothalamic and thalamic types, ventricular hemorrhage was seen in all cases, so that the difference in DR between cases with and without ventricular hemorrhage was unknown. In the capsular type, however, DR in cases with ventricular hemorrhage averaged 0.97 in 17 of 24 cases, while the corresponding value in cases without ventricular hemorrhage was 1.12. This was probably due to the rupture of some of the intracerebral blood into the ventricle causing a medial shift of the lenticulo-striate artery.

Prognosis: In the capsulothalamic type, the prognosis became poorer as the DR increased. In the capsular type the disturbance of consciousness became more intense as the DR decreased.

DISCUSSION

According to ANDERSEN[1], the lenticulo-striate artery arises from the first part of the middle cerebral artery and divides into two branches. The medial striate arteries pass

upwards through the anterior or perforate substance, globus pallidus of the lentiform nucleus and the internal capsule to end in the body of the caudate nucleus ; the lateral striate arteries pass upwards through the putamen or between it and the external capsule and often divide into anterior lenticulo-striate, and a posterior lenticulo-optic collection.

The recurrent artery of HEUBNER[4)8)] branches from the anterior cerebral artery to reach the anterior inferior portion of the caudate nucleus, anterior inferior part of the internal capsule and part of nucleus lenticularis.

WESTBERG[8)] states that "it is obvious from these anatomical conditions that the main stem of this vessel must be often difficult and sometimes even impossible to identify in clinical angiography, and therefore its branches may be easily mistaken for branches from the middle cerebral artery". The most frequent site of hypertensive intracerebral hemorrhage is in the regions perfused by these arteries. Since many of our cases had a large hematoma, simultaneous evaluation of these two arteries for the localization diagnosis of angiogram would not lead to a great mistake. Consequently, HEUBNER's artery may be included in our angiographic studies.

The frequency of visualization of the lenticulo-striate artery was rather in favor of *poor and non-filling* in cases with the cerebrospinal fluid pressure above 300 mmH_2O, with volume of the hematoma above 100 cc, with the extension of the hematoma reaching the thalamus and hypothalamus, and without ventricular hemorrhage. Under these conditions in intracranial or intracerebral hypertension, the rate filling is decreased due to the pressure by the hematoma. However, the diagnostic value was large in view of the *fair filling* occupying about 60% of cases of hypertensive intracerebral hemorrhage. As an indication for the surgical treatment of hypertensive intracerebral hemorrhage, the excellent results obtained in the capsular type should be considered. However, no method is available to establish the type preoperatively. The results indicating that 93.7% of cases with DR of less than 1.1 belong to the capsular type should therefore be regarded as important. Cases with the volume of the hematoma less than 100 cc and those with the hematoma diameter less than 4 cm in the coronal section frequently show the DR characteristic to the capsular or capsulothalamic type with definite tendencies. This is probably because of the large size of the hematoma, the floating of the lenticulo-striate artery within the hematoma like a grass, or the complex compression on this artery due to a large hematoma.

In the angiogram obtained in 36 autopsy cases no displacement of the main cerebral arteries was seen in 8 cases including the one with the largest hematoma weighing 150 g, in all of which the complication of intraventricular hemorrhage was noted. Among the silent angiograms without displacement of the main cerebral arteries, the location of the hematoma was established through the lenticulo-striate artery in 6 cases.

In these cases, the ventricular hematoma volume was seen in 65% and intracerebral hematoma volume in 35%. ANDERSEN[2)] also reported that 10-15% of cases with the definite presence of an intracerebral hematoma showed no shift of the main cerebral arteries. The rate of visualization of the lenticulo-striate artery was higher and DR smaller in cases with intraventricular hemorrhage than those without, showing a shift to the medial side. This was probably due to the lower intracerebral pressure due to ventricular perforation and removal of the circulartory disturbance of this artery.

SUMMARY

The location of the lenticulo-striate artery in angiography was studied in 49 cases of acute hypertensive intracerebral hemorrhage. In the antero-posterior view of the angiogram in hypertensive intracerbral hemorrhage, DR showed a marked correlation with the location and volume of hematoma and the presence of intraventricular hemorrhage. When DR was smaller than 1. 10, the capsular type occupied the major part, giving a diagnostic significance.

REFERENCE

1) Andersen, P. E. : The lenticulo-striate arteries and their diagnostic value. A preliminary report. Acta radiol., **50** : 84-91, 1958.
2) Andersen, P. E. : Angiographic localization of small intracerebral hematomas. Acta radiol., Diagnosis, N. S., **1** : **173**-181, 1963.
3) Charcot, J. M. and Bouchard, B. C. : Cited by Murphy, J. P. : Cerebral vascular disease. Year Book Fub., Chicago, 1954.
4) Heubner, A. : Zur Topographie der Ernährungsgebiete der einzelnen Hirnarterien. Zbl. med. Wiss., **52** : 817, 1872.
5) Kanaya, H., Ono, S. and Horie, Y. : Diagnostic value of Ienticulo-striate arteries in hypertensive intracerebral hemorrhage. J. Jap. Coll. Angiol., **8** : 68, 1967.
6) Kanaya, H., Ohsawa, K., Ishikawa, Y., Onodera, E., Ono, S., Sano, Y., Oana, K., Saiki, I. and Horie, Y. : Surgical indication of hypertensive intracerebral hemorrhage. Iji-shinpo, **2260** : 12-26, 1967.
7) Misuno, T., Kanaya, H., Shirakata, S., Ohsawa, K. and Ishikawa, Y. : Surgical treatment of hypertensive intracerebral hemorrhage. J. Nuerosurg., **24** : 70-76, 1966.
8) Westberg, G. : The recurrent atrtery of Heubner and the arteries of the central ganglia. Acta rediol., Diagnosis, N. S. **1** : 949-954, 1963.

和文抄録

高血圧性脳出血に於ける線状体動脈群の脳血管所見について

岩手医科大学金谷外科

金谷春之・小野勢津男・堀江　寛・小穴勝磨

脳血管写上，高血圧性脳出血の血腫局在診断のため，線状体動脈の所見について，正常例，脳動脈硬化症例を対照として検討した．線状体動脈の距離比（頭蓋正中線より本動脈分岐部までの距離分の本動脈最大偏位部までの距離）は血腫の局在，量，拡がりと密接な関係があつた．特に距離比が1.1以下，即ち本動脈特有の S-shaped curve が失われ，直立するか，内側偏位を示す場合，その大部分が血腫が視床，視床下部より外側にあるものであり，手術適応上の意味は大きい．