
症 例

Extravasation from an Intracranial Aneurysm
During Angiography. Case report.

by

JYOJI HANDA, IKUHIRO AOYAMA, and HAJIME HANDA

Department of Neurosurgery, Kyoto University Medical School

Received for Publication 30 April, 1974

The rupture of an intracranial aneurysm during cerebral angiography seems to be rare. Reviewing the available literature, we found 19 previously reported cases, to which we are adding further one case.

Case Report

This 59-year-old house-wife had an initial attack of proven subarachnoid hemorrhage 11 days prior to admission. Carotid angiography performed at an another hospital revealed a right internal carotid aneurysm at the origin of the posterior communicating artery, which measured 3×3 mm in size. A severe luminal narrowing of the trunk of the right middle cerebral artery was seen (Fig. 1).

On admission, she was restless and confused. She complained of severe occipital headache and moderate nuchal stiffness was present, but the physical and neurological examinations were otherwise non-contributory. Her blood pressure was 124/60mmHg. Left carotid angiography was performed, and interpreted to be normal. Her condition had gradually improved until the seventh hospital day when she suddenly became unresponsive. Two hours later, while she was still semicomatose, a right carotid angiography was repeated under a local anesthesia. The common carotid artery was punctured and a 10 ml bolus of the contrast medium was manually

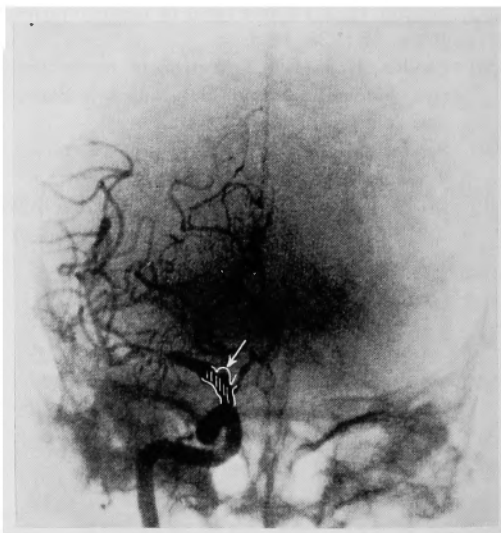


Fig 1. First right carotid angiogram demonstrating an internal carotid aneurysm (Arrow).

injected. Immediately following the injection, the patient became again unresponsive and transiently apneic.

A right frontotemporal craniotomy was performed 2 hours later. Dura was moderately tense and the carotid cistern was filled with the fresh blood clot. The neck of the aneurysm was occluded with a Heifetz's clip. After a stormy postoperative course, she remained apallic for 6 months before her death.

Angiographic Findings

Only three exposures in the anteroposterior projection were obtained. In the arterial phase, diffuse extravasation of the contrast medium into the basal subarachnoid cisterns was noted. The aneurysm was not demonstrated (Fig. 2) and the branches of the anterior and middle cerebral arteries were filled. During the subsequent phases, the contrast medium further spread but the ventricles were not opacified.

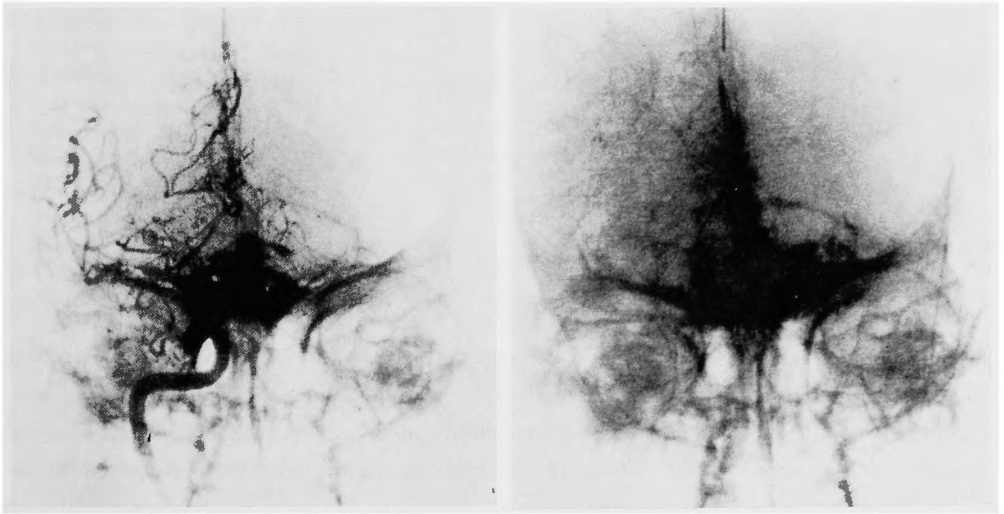


Fig 2. Second right carotid angiogram demonstrating the extravasation of the contrast medium into the subarachnoid cisterns.

Discussion

Since the reports of Jamieson⁸⁾ and Jenkinson et al.⁹⁾, 19 cases have been reported of the rupture of an intracranial aneurysm during angiography, and the ventricular opacification was noted in 6 of them^{5),6),10),14),16)}. Reviewing the records of 20 patients including the case reported here, there were 16 women and 4 men ranging in age from 23 to 84 years; 11 cases were under 50 years of age^{1),2),3),4),7),12),13),15),17),18),19)}. Interval between the previous subarachnoid hemorrhage and the time of angiography was less than 24 hours in 9, 1 to 14 days in 7, and 15 to 34 days in 3. In the remaining one, the extravasation of the contrast medium from the previously unruptured aneurysm was incidentally found during angiography in the patient with acute head injury. Site of the leaking aneurysm was the

internal carotid artery in 11 patients, middle cerebral artery in 5, anterior cerebral artery in 3 and basilar artery in 1. Multiple aneurysms were found in 3 of 19 cases. In one patient, the proximal common carotid artery had been surgically occluded for the treatment of internal carotid aneurysm¹⁴⁾.

Technical data of the angiography were summarized in the table. Only two patients survived^{2), 18)}, and 18 patients expired with or without operative intervention. Interval between the time of angiography and death ranged from several hours to 6 months.

Table Technical data of angiography in 20 cases.

Total number of cases	20
Site of needle :		
Common carotid	11
Internal carotid	6
Vertebral	1
Brachial	1
Unknown	1
Mode of injection :		
Hand	13
Injector	6
Unknown	1
Anesthesia :		
Local	9
General	5
Unknown	6

The contribution of angiography to the rupture of an intracranial aneurysm is problematical. The rupture could be purely coincidental. On the other hand, the direct effect of the contrast medium, effects of cross compression, impact waves, pressure effect of a bolus injection and the cardiovascular effects of stressful maneuver have been supposed to be a possible causative factor. Reviewing the previous reports, however, no consistent relationship has been found between the rupture of an aneurysm and the condition of the patients or the angiographic techniques.

An aneurysmal rupture is the most serious complication of angiography. In view of the high mortality of conservatively treated cerebral aneurysm and the recent improvement in the results of its operative treatment, however, it is evident that the clinical value of angiography in patients suspected of having an aneurysm far outweighs its risk.

Summary

A case of contrast medium extravasation from an intracranial aneurysm is presented and the available literature reviewed. No consistent relationship has been found between the rupture of an aneurysm and the condition of the patients or the angiographic techniques.

KEY WORDS. Intracranial aneurys. Contrast medium extravasation. Cerebral angiography. Complication.

References

- 1) Beamer YB, Corsino JF, Lynde RG : Rupture of an aneurysm of the internal carotid artery during arteriography with filling of the subarachnoid space and demonstration of a temporal lobe mass. Case report. *J Neurosurg* **31** : 224-226, 1969.
- 2) Ferrary D, Vio M : Radiological demonstration of rupture of a carotid aneurysm during cerebral angiography. Case report. *J Neurosurg* **31** : 462-464, 1969.
- 3) Freemon FR : Dye entering subarachnoid space through a bleeding intracranial aneurysm. *JAMA* **211** : 295-296, 1970.
- 4) Gallagher JP, Yamamoto YL : Rupture of an intracranial aneurysm following arteriography : Case report. *Bull Georgetown Univ Med Center* **9** : 97-99, 1956.
- 5) Goldstein SL : Ventricular opacification secondary to rupture of intracranial aneurysm during angiography. Case report. *J Neurosurg* **27** : 265-267, 1967.
- 6) Hoff JT, Potts DG : Angiographic demonstration of hemorrhage into the fourth ventricle. Case report. *J Neurosurg* **30** : 732-735, 1969.
- 7) Jackson JR, Tindall GT, Nashold BS Jr : Rupture of an intracranial aneurysm during carotid angiography. A case report. *J Neurosurg* **17** : 333-336, 1960.
- 8) Jamieson KG : Rupture of an intracranial aneurysm during cerebral angiography. *J Neurosurg* **11** : 625-628, 1954.
- 9) Jenkinson EL, Sugar H, Love H : Rupture of an aneurysm of the internal carotid artery during cerebral angiography. *Am J Roentgenol* **71** : 958-960, 1954.
- 10) Karadayi A, Londqvist M, Tovi D : Rupture of an intracranial aneurysm with ventricular opacification during angiography. Case report. *Neurochirurgia* **16** : 59-62, 1973.
- 11) Lehrer HZ, Gross LA, Poon TP : Ruptured intracranial aneurysm. Contrast agent extravasation during brachial arteriography. *Arch Neurol* **27** : 351-353, 1972.
- 12) Marc JA, Schechter MM, Azar-Kia B : Intraventricular bleeding from cerebral aneurysmal rupture. *Neuroradiology* **5** : 184-186, 1973.
- 13) Murphy DJ, Goldberg RJ : Extravasation from an intracranial aneurysm during carotid angiography. Case report. *J Neurosurg* **27** : 459-461, 1967.
- 14) Osgood C, Martin LG : Intraventricular contrast extravasation during carotid angiography. *Surg Neurol* **2** : 49-50, 1974.
- 15) Sakamoto T, Yosimoto T, Suzuki J : Extravasation from an intracranial aneurysm during carotid angiography. *Brain Nerve* **24** : 603-606, 1972.
- 16) Teal JS, Wade PJ, Bergeron RT, et al : Ventricular opacification during carotid angiography secondary to rupture of intracranial aneurysms. *Radiology* **106** : 581-583, 1973.
- 17) Triska H : Ein Fall von Kontrastmittelextravasat bei einem ruptierten Aneurysma der Arteria cerebri media. *Zbl Neurochir* **22** : 291-295, 1962.
- 18) Vines FS, Davis DO : Rupture of intracranial aneurysm at angiography. Case report and comment on causative factors. *Radiology* **99** : 353-354, 1971.
- 19) Waga S, Kondo A, Moritake K, et al : Rupture of intracranial aneurysm during angiography. *Neuroradiology* **5** : 169-173, 1973.

和文抄録

脳血管撮影により造影剤の血管外漏洩を示した
脳動脈瘤の1例

京都大学医学部脳神経外科学教室 (主任: 半田 肇)

半田 讓二・青山 育弘・半田 肇

59才, 女, 右内頸動脈後交通動脈分岐部動脈瘤で, 初回のクモ膜下出血発作後18日目に再発作をきたし, その直後の頸動脈撮影で造影剤の血管外漏洩をみとめた稀な症例を報告し, 過去の報告例19例とあわせ検討した.

これら計20例について, 動脈瘤の部位, クモ膜下出血後血管撮影までの時間的経過, 検査時の患者の状態, 血管撮影の手技などと造影剤の血管外漏洩との間に確実な因果関係があることを示す成績はえられなかった.