
臨 床

Intraarticular Injection of Mucopolysaccharide
Polysulfuric Acid Ester in the Treatment of
Osteoarthritis of the Hip Joints

by

SEISUKE TANAKA and TETSUO ITO

Department of Orthopaedic Surgery, Faculty of Medicine, Kyoto University

(Received for Publication May, 1, 1976)

Physical therapy, antiphlogistic analgics of nonsteroids, and steroid therapies by means of an intraarticular injection¹⁰⁾ have long been prescribed for the conservative treatment of osteoarthritis of the hip joint. The agents of intraarticular injection included heparin⁵⁾, mucopolysaccharide polysulfuric acid ester⁶⁾, extract of cartilage and cancellous bone¹⁾, silicon oil⁴⁾, and hyaluronic acid¹³⁾. Intraarticular injection of mucopolysaccharide polysulfuric acid ester (Arteparon forte, Luitpold-Werk. Munich, Germany) was developed by Eylau⁵⁾ in 1957, and applied clinically since 1959. Subsequently, clinical case reports were documented by Böttcher²⁾, Preußer¹²⁾, and Fujimoto and Ueno⁷⁾. Clinical results of nine patients treated with Arteparon forte since 1972 are reported herein.

The mucopolysaccharide polysulfuric acid ester used in this treatment was prepared by polysulphating the polysaccharide portion which remained after removal of the protein from the mucopolyprotein complex. Arteparon contains 50 mg of the mucopolysaccharide polysulfuric acid ester and Arteparon forte 250 mg. The latter is used for the treatment of osteoarthritis of the hip.

Patients and Administration

During the period from July 1972 to February 1973, Arteparon therapy was given in nine Japanese patients. Five patients had a secondary osteoarthritis of the hip due to acetabular dysplasia, one had a primary osteoarthritis, and three an avascular necrosis of the femoral head; three males and six females; ages ranged from 23 to 50 years with 36 years being the average (Table 1). All nine patients had refused surgery and Arteparon forte was prescribed for relief of pain.

Key words : Osteoarthritis of the hip, Spontaneous avascular necrosis of the femoral head,
Mucopolysaccharide

Present address : Seisuke Tanaka ; Department of Orthopaedic Surgery, Faculty of Medicine, Kyoto University, Shogoin-Kawara-cho, Sakyo-ku, Kyoto 606, Japan.

Table 1. Cases

Patients	Age	Sex	Disease	Times of injection
1	38	F	primary osteoarthritis	6
2	29	F	secondary osteoarthritis	10
3	39	F	secondary osteoarthritis	10
4	43	M	spontaneous necrosis	10
5	23	F	secondary osteoarthritis	10
6	40	F	secondary osteoarthritis	9
7	32	F	secondary osteoarthritis	10
8	50	M	spontaneous necrosis	10
9	29	M	spontaneous necrosis	8

Secondary osteoarthritis : originated congenital acetabular dysplasia.

Spontaneous necrosis : spontaneous avascular necrosis of the femoral head.

Arteparon forte was injected directly into the inguinal region, at the point determined to be the neck of the femur. One injection per week for 4-6 weeks was prescribed. This was followed by one injection weekly for 2-4 weeks. The shortest period of injection was one month and the longest was six months.

Before any administration to any patient blood and urinary chemistry was carried out to detect abnormalities in bleeding and coagulation times.

Cases

Case 1. To a 38-year-old female with primary osteoarthritis of the left hip,

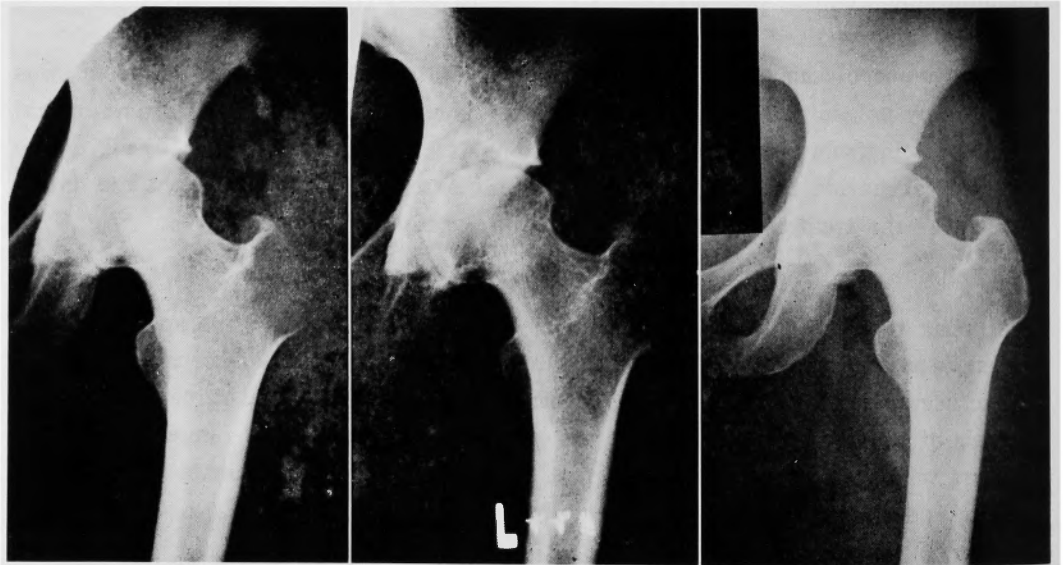


Fig. 1. Female, 38 years old. Primary osteoarthritis.

Left : before treatment. Middle : seven months after the last injection
Right : three years and one month after the last injection

intraarticular injection of Arteparon forte was started on July 1972. Pain and walking ability improved after a total of six injections. During the subsequent three years and one month, the patient had no complaints, however, roentgenogram revealed a transient enlargement of the cyst in the acetabular roof, which later improved (Fig. 1).

Case 4. To a 43-year-old male with spontaneous avascular necrosis of the right femoral head, a total of 2,500 mg of Arteparon forte was injected during the period from July to October 1972. Pain as well as general well being were improved. Even two years and 10 months after the injection the patient is quite comfortable. Differences in the findings between before and after the treatment were nil as viewed on the roentgenogram (Fig. 2).

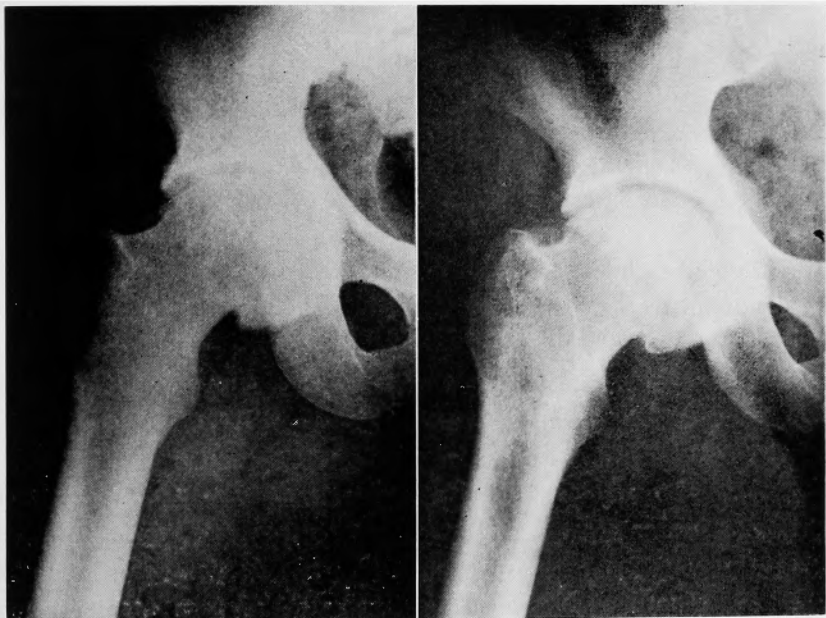


Fig. 2 Male, 43 years old. Spontaneous necrosis of the femoral head.
Left : before treatment, Right : two years and ten months after the last injection

Case 5. To a 23-year-old female with osteoarthritis of the left hip originating from congenital acetabular dysplasia, Arteparon therapy was prescribed in July of 1972. Effects were noted after the sixth injection had been given. The total administration was completed with the tenth injection, when pain was much improved. Even two years and 10 months after the treatment the effects have lasted. Roentgenographic findings showed no change (Fig. 3).

Case 7. A 32-year-old female with osteoarthritis of the both hips originating from congenital acetabular dysplasia underwent varus osteotomy on the right femur in January 1972. Arteparon therapy was prescribed for the left hip joint in July

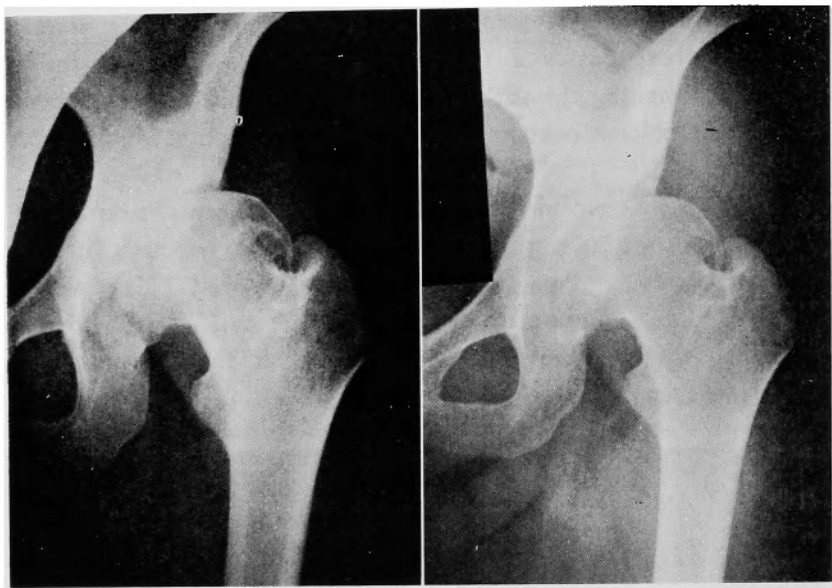


Fig. 3 Female, 23 years old. Secondary osteoarthritis.

Left : before treatment, Right : two years and ten months after the last injection

1972. After the eighth injection therapeutic effects were noted and after the tenth injection the administration was terminated. Pain and walking ability were improved two years and six months after the treatment and the effects have lasted. Although the bone sclerosis of the acetabular roof and the narrowing of the joint space revealed on the roentgenogram remain unimproved, the patient is content with the therapeutical results.

Case 9. To a 29-year-old male with spontaneous avascular necrosis of the left femoral head, Arteparon forte were prescribed during the period from August of 1972 to February of 1973. Follow-up examinations for two years and six months revealed that the patient experienced no increase of pain despite a progressing collapse of the femoral head as seen on the roentgenogram. Due to the slight aggravation of limitation of hip motion and activity of daily living (ADL), the total score was lower than that of the preadministration time.

Results

Follow-up examinations were performed for the period from one year to three years and one month, average two years and seven months.

The hip function before and after the present Arteparon therapy was evaluated using the numerical scale on the basis of 100 points, formulated by the Japanese Orthopaedic Association¹⁴⁾ (Table 2). Table 3 shows the condition of patients before the present treatment and the therapeutic results of Arteparon. In all the patients except one, the beneficial effects were noted after the sixth-eighth injection and

Table 2. Rating scale for hip disabilities

I. Pain		II. Gait	
None	40	Normal	20
Slight	30	Slight limp, no support	15
Moderate	20	Severe limp, one cane	10
Severe.....	10	Severe limp, two crutches	5
Severe at rest	0	Cannot walk	0
III. Mobility			
Flexion		Abduction	
More than 90°	12	More than 30°	8
Between 89° and 60°	9	Between 29° and 20°	6
Between 59° and 30°	6	Between 19° and 10°	4
Under 29°	3	Under 9°	2
Ankylosis or fixed deformity with bad position.....	0		
IV. Activities of daily living			
	Possible	Difficult	Impossible
Chair sitting.....	2	1	0
Sitting on straw mat	2	1	0
Bowing from sitting on straw mat.....	2	1	0
Standing up from floor	2	1	0
Squatting	2	1	0
Putting on socks.....	2	1	0
Cutting toe nails	2	1	0
Standing on one leg	2	1	0
Going up stairs	2	1	0
Going down stairs	2	1	0

Table 3. Results

Patients	Pain	Walking ability	Mobility	ADL	Total score	Improved score	Follow-up period(months)	X-ray	Subjective assessment
1	20-40 [*]	10-20 ^{**}	20-18 ^{**}	19-19 ^{**}	69-97 ^{**}	+28	37	improved	sufficient
2	20-30	10-10	9-9	18-17	57-66	+9	34	no change	sufficient
3	20-40	10-15	20-20	17-18	67-93	+26	34	no change	sufficient
4	20-30	10-15	18-20	13-17	61-82	+21	34	no change	sufficient
5	20-30	15-20	20-20	18-20	73-90	+17	34	no change	sufficient
6	20-30	15-20	20-20	13-12	68-82	+14	12	no change	sufficient
7	20-30	10-20	20-20	19-18	69-88	+19	30	no change	sufficient
8	20-30	10-10	18-16	6-5	54-61	+7	32	worse	unclear
9	30-30	15-15	13-10	16-13	74-68	-6	30	worse	unclear

* : before therapy ** : after therapy

Follow-up period : period between the last injection and the last examination.

effects of this therapy remain even to the present (Fig. 4).

Roentgenographic findings revealed that Arteparon forte resulted in improvement of primary osteoarthritis, whereas there was no effect in five patients with secondary

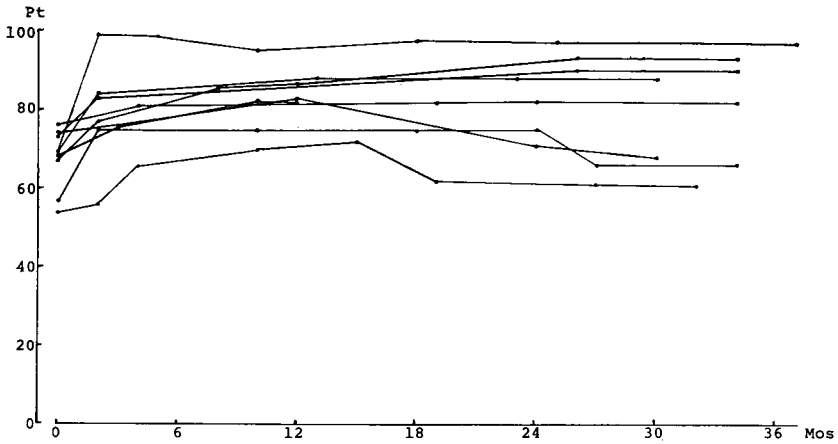


Fig. 4. Beneficial effects were lasted for a long time.

osteoarthritis originating from congenital acetabular dysplasia. In the three patients with spontaneous avascular necrosis of the femoral head, two showed aggravation of the disease. This aggravation is considered to be the natural course of avascular necrosis of the femoral head, and cannot be ascribed to the effect of the prescribed drug.

Side Effects

Out of the nine patients, eight complained of pain at the injected region and one patient complained of headache. The pain was slight in degree and was ameliorated after five minutes at the least or after three days at the longest. A tendency to shortening the duration of pain along with repeated injections was noted. In addition, two patients complained of abnormal menstruation.

Clinical examinations revealed that Arteparon caused no significant variation in bleeding and blood coagulation times. The general blood tests, urinary analysis and chemical analysis of blood showed no significant variation between before and after the treatment even in the two patients with abnormal menstruation.

Discussion

As Arteparon given intraarticularly disappears from the synovia within a short time and does not appear in the circulatory system, Viernstein¹⁶⁾ considered that most of the Arteparon is taken up into the articular cartilage. Culture experiments of cartilage tissue were conducted by Taguchi et al.¹⁵⁾ who found that Arteparon was greatly reduced in volume in the culture media. Such has also been proved histochemically by Dettmer³⁾. This researcher found that metachromasia disappears in the articular cartilage of advanced osteoarthritis, whereas, when Arteparon treatment is given, metachromasia reappears and remains even after water-washing. In the case of osteoarthritis also, he reported that decreasing metachromasia of

degenerative cartilage and diminution of mucopolysaccharide occurs. Such occurrences have been attributed to a disturbance in mucopolysaccharide synthesis or to acceleration of its decomposition⁹⁾.

As to the action of Arteparon on mucopolysaccharide protein complex, Iwata et al.¹¹⁾ incubated human cartilage containing ³⁵S-labelled-mucopolysaccharide-protein complex in Krebs-Ringer solution, and then measured the isotope liberated from the solution. As a result, Arteparon showed a high inhibitory action on the decomposition of mucopolysaccharide complex. On the basis of enzymology, Greiling⁸⁾ reported that Arteparon inhibits the activity of mucopolysaccharide decomposition enzyme (Chondroitinhydrosulfat- Glykanohydrolase, Hyaluronat-Glykanohydrolase).

As to the action of Arteparon on biosynthesis of mucopolysaccharide protein complex in the chondrocytes, Taguchi et al.¹⁵⁾ allowed Arteparon to act on the cartilage of human knee joint and observed an enlarged Golgi apparatus of chondrocytes. In Golgi apparatus in the embryo-chondrocytes of hens who have an active synthesis of mucopolysaccharide, Golgi vacuole is well developed. In view of this result, these authors considered that Arteparon would have effects on the synthesis of mucopolysaccharide protein complex in the articular cartilage, thereby rendering good therapeutic effects in humans.

At least eight to ten injections of Arteparon are required to obtain therapeutic effects in cases of osteoarthritis of the hip^{6),12)}. Efficacy rates are reportedly 62.8 %—88.5 %^{6),12)}. As to the efficacy of Arteparon for each disease, Eylau⁶⁾ reported 100 % efficacy rates for traumatic diseases, 75.0 % for imperfect ossification, 68.8 % for inflammatory, 64.4 % for primary osteoarthritis, 53.8 % for secondary osteoarthritis and 50.5 % for avascular necrosis of the femoral head. The results of our own examinations revealed the highest efficacy in the treatment of primary osteoarthritis. Out of the three patients with spontaneous avascular necrosis of the femoral head, one was strikingly responsive to Arteparon, one was only slightly responsive, and the other one showed a slight aggravation of the disease because of limitation of motion and of disturbance in ADL which occurred one year and one month after the injection. Regeneration of once destroyed articular cartilage cannot be expected with Arteparon therapy⁶⁾. In general, although Arteparon is effective in improving clinical symptoms, it is ineffective in improving roentgenographic findings.

Summary

In the treatment of osteoarthritis of the hip joint, intraarticular injections of mucopolysaccharide polysulfuric acid ester (Arteparon forte) were given to nine patients including five with congenital acetabular dysplasia, three with spontaneous avascular necrosis of the femoral head, and one with primary osteoarthritis. Pain was relieved in all patients. Therapeutic effects have continued up to present day, that is during the three years and one month follow-up examination. Side effects

are negligible. On the basis of the therapeutic results, Arteparon is considered to be suitable chemotherapy to be prescribed before surgical intervention.

Acknowledgement

Thanks are due to Miss M. Ohara for assistance with the manuscript.

References

- 1) Bollet, A. J., Bonner, W. M. and Nance, J. L. : The presence of hyaluronidase in various mammalian tissues. *J. Biol. Chem.*, **238** : 3522, 1963.
- 2) Böttcher, H. . Neue Wege in der konservativen Behandlung von Koxarthrosen. *Zschr. Orthopädie*, **98** : 483, 1964.
- 3) Dettmer N. : Elektronenmikroskopische Befunde an biotisch gewonnenen Knochen, Speziell ihrer Grundsubstanz. *Arch. Orthop. Unfallchir.*, **60** : 155, 1966.
- 4) Donahue, W. C. : Effect and fate of intraarticular silicon fluid. *Clin. Orthop.*, **77** : 305, 1971.
- 5) Eylau, O. : Zur Pathogenese und causalen Behandlung der Kniegelenkarthrosen. *Med. Klin.*, **53** : 2367, 1960.
- 6) Eylau, O. : Intraartikuläre Arthrosen-Behandlung mit einem Mucopolysaccharidpolyschwefelsäureester. *Zschr. ärzt. Fortbild.*, **55** : 37, 1966.
- 7) Fujimoto, K. and Ueno, R. : Intraarticular injection of mucopolysaccharide polysulfuric acid in the treatment of gonarthritis. *Clin. Orthop. Surg.*, **7** : 407, 1972 (in Japanese).
- 8) Greiling, H. : Biochemische Probleme des degenerativen Rheumatismus. *Zschr. ärzt. Fortbild.*, **55** : 240, 1966.
- 9) Greiling, H. and Stuhlsatz, H. W. : Biochemische Untersuchungen zur Wirkungsweise eines Polysaccharidsulfates bei degenerativen Gelenkerkrankungen. *Z. Rheumaforsch.*, **25** : 116, 1966.
- 10) Hollander, J. L., Brown, E. M., Jessar, R. A. and Brown, C. Y. : Hydrocortisone and cortisone injected into arthritic joints. Comparative effects of and use of hydrocortisone as a local antiarthritic agent. *J. Amer. Med. Ass.*, **147** : 1629, 1951.
- 11) Iwata, H., Kaneko, M., Terashima, Y., Yasuhara, T., and Nakagawa, M. : Structural studies of synthetic chondroitinpolysulfide, and its effects on articular cartilage metabolism. *Orthop. Surg.*, **25** : 1155, 1974 (in Japanese).
- 12) Preußner, E. : Neue Ergebnisse der AR-67-Behandlung von Coxarthrosen. *Zschr. ärztl. Fortbild.*, **56** : 658, 1967.
- 13) Rydell, N., and Balazs, E. A. : Effect of intra-articular injection of hyaluronic acid on the clinical symptoms of osteoarthritis and on granulation tissue formation. *Clin. Orthop.*, **80** : 25, 1971.
- 14) Shima, Y., Tamaki, T., Yokozaki, M., Tanaka, S., Yoshinaga, H., Tagawa, H., and Ueno, R. : Comparative studies on various operative treatments for osteoarthritis of the hip. *J. Jap. Orthop. Ass.*, **45** : 813, 1971 (in Japanese).
- 15) Taguchi, Y., Terayama, K., and Aono, Y. : Electrodiagnostic studies on the effects of mucopolysaccharide polysulfide ester in the treatment of articular cartilage. *Rinsho to Kenkyu*, **50** : 874, 1973 (in Japanese).
- 16) Viernstein, K. : Über die Wirkung von Eleparon bei intraartikulärer Anwendung. *Med. Klin.*, **59** : 305, 1964.

和文抄録

股関節症に対するムコ多糖多硫酸エステル関節内注入

京都大学医学部整形外科学教室（主任：伊藤鉄夫教授）

田中清介，伊藤鉄夫

股関節症の保存的療法として種々の関節内注入療法があるが，その中でもムコ多糖多硫酸エステル関節内注入療法の有効性は注目に値するものがある。この療法は1957年 Eylau により開発され1959年より主として西独で臨床的に使用されている。我々もまた1972年から1973年にかけて先天股脱あるいは臼蓋形成不全由来の二次性股関節症5例，特発性大腿骨頭壊死3例，一次性股関節症1例，計9例に使用した経験を持ち，今回長期成績を検討した。

治療効果はムコ多糖硫酸エステル（アルテパロン・

フォルテ）6～8回の注射で発現した。1例の特発性大腿骨頭壊死を除いては，いずれの症例においても成績の改善がみられ，特に疼痛に対し効果的であった。いったん得られた効果は最長3年1カ月の症例をはじめとして，長期持続している。但し，レ線所見に対しては効果的ではなかった。一般に股関節症では，未処置（自然放置）では増悪をみるが，アルテパロンが股関節症に対し保存的療法として有効であることが確認できた。