

## Experimental Studies on Hepatic Hemodynamics and Function in Postsinusoidal Block

KATSUMI KAWABE, TAKASHI YOKOTA,  
RYUJI MIZUMOTO and ICHIO HONJO

First Department of Surgery, Faculty of Medicine, Kyoto University

Received for Publication May 26, 1977

### Introduction

From the hemodynamic point of view, portal hypertension is generally classified as postsinusoidal block or presinusoidal block, depending on where the primary block to portal blood flow lies. It is well established that the Budd-Chiari syndrome and portal thrombosis represent almost pure instances of postsinusoidal block and presinusoidal block, respectively, and most liver cirrhosis has been considered to be intrahepatic postsinusoidal block. Because portal venous inflow is disturbed due to the extremely high degree of resistance to the portal blood flow in cases of portal hypertension, the liver is supplied by the hepatic artery alone, and in cases of presinusoidal block all of the arterial blood flow leaves via the natural circulatory pathway of the hepatic vein, but in cases of postsinusoidal block it leaves in a reverse direction via the portal vein on the hepatic side.

Since Whipple<sup>28)</sup> reintroduced Eck's fistula to clinical surgery in the treatment of portal hypertension in 1945, a number of clinical and experimental studies have been done on hemodynamic and metabolic changes in the liver supplied with the hepatic artery alone after an end to side portacaval anastomosis<sup>1)2)3)7)11)12)16)17)19)22)</sup>. However, the function of the hepatic artery with a reversed flow through the portal vein of the hepatic side, which has been demonstrated in postsinusoidal block, has not been investigated in detail.

In the present experiment, the hemodynamic changes and function of the liver in postsinusoidal block were investigated and compared with those in presinusoidal block under identical condition in the same body after ligation of the portal vein branches of the right half of the liver and ligation or constriction of the hepatic vein of the left half, following a side to side portacaval anastomosis.

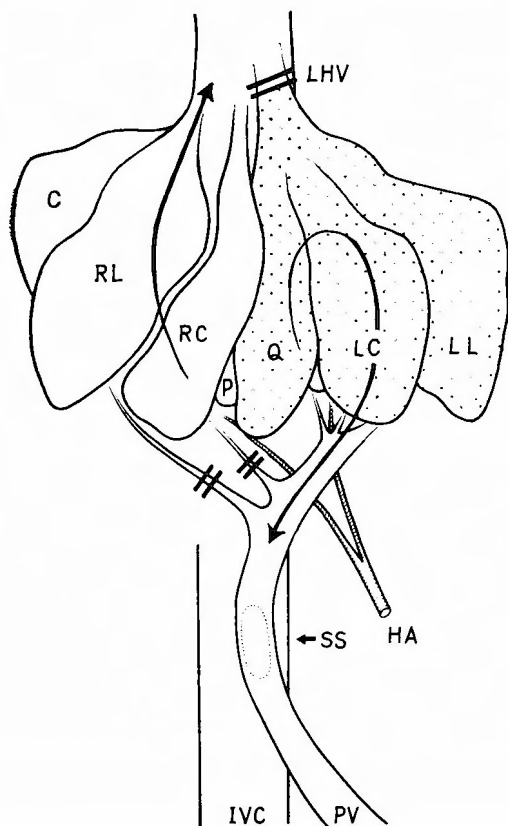
### Materials and Methods

In dogs, the venous blood of the left half of the liver, including the left lateral, left central, quadrate lobes, and most of the papillary process of the caudate lobe, is drained by a single

---

Key Words : Portal hypertension, Presinusoidal block, Postsinusoidal block, Side to side portacaval anastomosis

Present address : First Department of Surgery, Faculty of Medicine, Kyoto, University, Sakyo-ku, Kyoto, 606, Japan.



**Fig. 1.** Schematic representation of canine liver with side to side portacaval anastomosis in Group 1. The right branches of the portal vein and the left hepatic vein were ligated.

// site of vessel ligated

C Caudate lobe

RC : Right central lobe

RL : Right lateral lobe

Q Quadrate lobe

LC : Left central lobe

LL : Left lateral lobe

P Papillary process of caudate lobe

SS : Side to side portacaval anastomosis

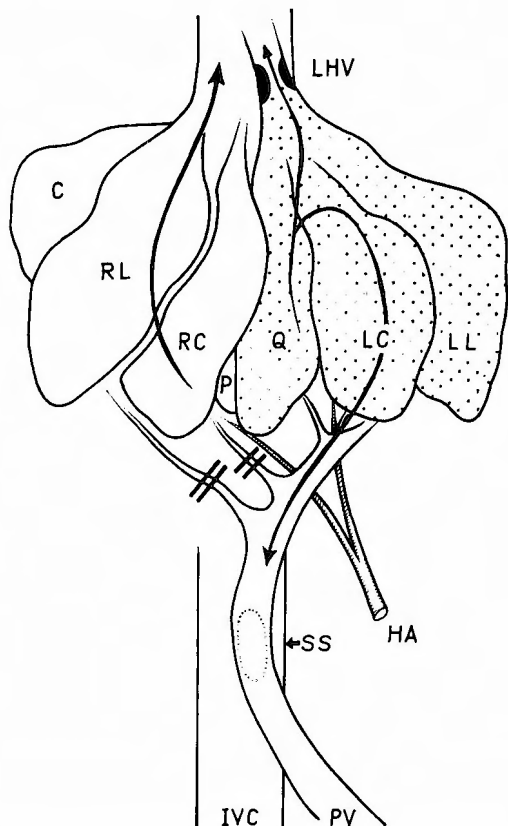
IVC : Inferior vena cava

HA : Hepatic artery

PV : Portal vein

LHV : Left hepatic vein

left hepatic vein. That of the right central lobe is drained by a central hepatic vein, and that of the right two lobes, including



**Fig. 2.** Schematic representation of canine liver with side to side portacaval anastomosis in Group 2. The left hepatic vein was constricted with a cellophane tape until the portal pressure rose to 200mm saline.

the caudate and right lateral lobes, is drained by several right hepatic veins.

Forty-seven adult mongrel dogs of both sexes weighing between 6 and 28 kg were used. Under intravenous nembutal anesthesia, 25 mg/kg body weight, the abdomen was opened through a long midline incision and large side to side portacaval anastomosis, 1.8 to 3.0 cm in length depending on body weight, was carried out. As the canine liver is almost completely lobulated, the right branches of the portal vein and the left hepatic vein were ligated in Group 1 to produce presinusoidal

block in the right half and postsinusoidal block in the left half of the liver in the same dog as shown in Figure 1. In Group 2 the left hepatic vein was not ligated, but constricted with a cellophane tape until the portal pressure rose to 200 mm saline before construction of the portacaval anastomosis as shown in Figure 2. Hemodynamic and functional changes were observed immediately after the operation in acute experiment and 8 weeks later in chronic experiments.

**Hepatic artery flow :** Immediately after killing of the experimental animals with an intravenous injection of 40 ml of 15 w/v% KCL solution following infusion of about 400,000  $^{85}\text{Sr}$ -labelled microspheres  $50\mu$  in diameter into the left ventricle through a silicone tube inserted into a carotid artery, the liver was removed, radioactivity was measured, and the ratio of radioactivity in the right to that in the left lobe was calculated. After the infusion of about  $20\mu\text{Ci}$   $^{131}\text{I}$ -BSP through the common hepatic artery, blood samples were withdrawn from the portal vein on the hepatic and intestinal sides of the portacaval anastomosis and the radioactivity in these blood samples was measured to determine the direction of the blood flow in the portal vein on the hepatic side.

**Oxygen extraction ratio :** Blood was taken from the iliac artery, the portal vein on the hepatic side, the right hepatic vein and mesenteric vein. Hemoglobin concentration, blood oxygen tension and pH were measured, and the oxygen concentration of each sample was calculated. The oxygen extraction ratio in the hepatic lobes was calculated from the following formula ;

$$\text{Oxygen extraction ratio} = \frac{\text{Arterial O}_2 \text{ conc.} - \text{Venous O}_2 \text{ conc.}}{\text{Arterial oxygen conc.}}$$

**Liver function test:** Following ligation of the cystic duct, individual bile ducts were cannulated and bile was collected separately from the left and right halves of the liver after intravenous injection of  $40\text{--}80\mu\text{Ci}$  of  $^{131}\text{I}$ -BSP, and bile flow and radioactivity were measured.

**Histologic examination :** After being fixed with 10% neutral formalin and embedded in paraffin, liver slices were cut  $8\mu$  thick and stained with hematoxylin-eosin and azan stains. The Student's t-test was used for statistical analysis of the results, with  $P \leq 0.05$  accepted as the level of significance of differences between means.

## Results

### I. Postsinusoidal block in left half of the liver after ligation of left hepatic vein in Group 1.

#### A. Acute experiment :

##### (1) Changes of hepatic artery flow :

Grossly, the color of the left lobes with postsinusoidal block was dark with slight congestion, but that of the right lobes with presinusoidal block showed little change. Following the injection of  $^{131}\text{I}$ -BSP via the common hepatic artery, radioactivity was detected in the blood of the portal vein on the hepatic side, but not in that on the intestinal side, showing reversed flow from the left half of the liver into the portal vein. The ratio of blood flow per gram of liver in the right to that in the left half was  $1 : 0.602 \pm 0.170$  in experimental group, while it was  $1 : 0.984 \pm 0.253$  in normal dogs, indicating that the blood

**Table 1.** Ratio of Blood Flow in Right to that in Left Half of Liver per Gram of Liver Tissue in Group 1

| Dog No.                           | Acute Experiment |                   | Dog No. | Chronic Experiment |                   |
|-----------------------------------|------------------|-------------------|---------|--------------------|-------------------|
|                                   | Right Half       | Left Half         |         | Right Half         | Left Half         |
| 1                                 | 1                | 0.81              | 6       | 1                  | 1.35              |
| 2                                 | 1                | 0.76              | 7       | 1                  | 0.59              |
| 3                                 | 1                | 0.59              | 8       | 1                  | 1.06              |
| 4                                 | 1                | 0.34              | 9       | 1                  | 0.766             |
| 5                                 | 1                | 0.51              | 10      | 1                  | 0.669             |
|                                   |                  |                   | 11      | 1                  | 0.975             |
| Mean $\pm$ S. D.                  | 1                | 0.602 $\pm$ 0.170 | 1       | :                  | 0.902 $\pm$ 0.259 |
| Mean $\pm$ S. D. of normal 5 dogs | 1                | 0.984 $\pm$ 0.253 | 1       | :                  | 0.984 $\pm$ 0.253 |
| t-test vs. Control                |                  | p < 0.05          |         |                    | 0.6 < p < 0.7     |

flow in the liver lobes with postsinusoidal block after ligation of the hepatic vein was less than that in the liver lobes with presinusoidal block after ligation of the portal vein branches ( $P < 0.05$ ) (Table 1).

(2) Oxygen extraction ratio :

The oxygen concentration in the blood in the portal vein on the hepatic side of the portacaval anastomosis was virtually equal to that on the intestinal side. The oxygen extraction ratio in the left half of the liver with postsinusoidal block was also the same as that

**Table 2.** Oxygen Concentration and Extraction Ratio  
Acute Experiment in Group 1

| Dog No.                              | Right Half                       |    |       |                               | Left Half  |    |       |                               |
|--------------------------------------|----------------------------------|----|-------|-------------------------------|--|----|-------|-------------------------------|
|                                      | O <sub>2</sub> Concent. (Vol. %) |    |       | O <sub>2</sub> Extract. Ratio | O <sub>2</sub> Concent. (Vol. %)                             |    |       | O <sub>2</sub> Extract. Ratio |
| Hepatic artery to right hepatic vein |                                  |    |       |                               | Hepatic artery to portal vein on hepatic side of anastomosis |    |       |                               |
| 12                                   | 12.82                            | to | 14.35 | 19.5%                         | 17.82  | to | 14.37 | 19.3%                         |
| 13                                   | 17.02                            | to | 12.77 | 25.0%                         | 17.02  | to | 12.74 | 25.1%                         |
| 14                                   | 17.95                            | to | 10.51 | 41.4%                         | 19.95  | to | 11.07 | 38.3%                         |
|                                      | 17.41                            | to | 14.20 | 18.4%                         | 17.41  | to | 14.97 | 14.0%                         |

## Chronic Experiment in Group 1

| Dog No. | Right Half                       |    |       |                               | Left Half                        |       |       |                               |
|---------|----------------------------------|----|-------|-------------------------------|----------------------------------|-------|-------|-------------------------------|
|         | O <sub>2</sub> Concent. (Vol. %) |    |       | O <sub>2</sub> Extract. Ratio | O <sub>2</sub> Concent. (Vol. %) |       |       | O <sub>2</sub> Extract. Ratio |
| 16      | 14.81                            | to | 11.52 |                               | 22.2%                            | 14.81 | to    |                               |
| 17      | 9.95                             | to | 6.85  | 31.2%                         | 9.95                             | to    | 8.42  | 15.4%                         |
| 18      | 10.60                            | to | 8.46  | 20.2%                         | 10.60                            | to    | 8.32  | 21.5%                         |
| 19      | 12.93                            | to | 10.83 | 16.3%                         | 12.93                            | to    | 10.62 | 17.9%                         |
| 20      | 10.40                            | to | 9.20  | 11.4%                         | 10.40                            | to    | 9.40  | 9.6%                          |

in the right half with presinusoidal block (Table 2).

(3) Liver function test :

The ratio of bile flow from the right to that from the left half of the liver was 1 : 1.028 ± 0.262 in the experimental group, while it was 1 : 0.720 ± 0.248 in normal dogs, showing no significant difference in the left and right lobes from that in normal dogs (0.05 < p < 0.1) (Table 3). The ratio of <sup>131</sup>I-BSP in bile excreted from the right to that from the left half of the liver was 1 : 0.994 ± 0.242 in the experimental group, while it was 1 : 0.949 ± 0.202 in normal dogs. Thus, there is no difference in BSP excretion between the liver lobes with presinusoidal and those with postsinusoidal block (p > 0.7) (Table 4).

**Table 3.** Ratio of Bile Flow from Right to that from Left Half of Liver per Gram of Liver Tissue

| Acute Experiment in Group 1  |                   | Chronic Experiment in Group 1 |               | Chronic Experiment in Group 2 |               |
|------------------------------|-------------------|-------------------------------|---------------|-------------------------------|---------------|
| Right Half : Left Half       |                   | Right Half : Left Half        |               | Right Half : Left Half        |               |
| (31)                         | 1 : 0.91          | (36)                          | 1 : 0.794     | (21)                          | 1 : 0.386     |
| (32)                         | 1 : 1.04          | (37)                          | 1 : 0.535     | (22)                          | 1 : 0.460     |
| (33)                         | 1 : 0.62          | (38)                          | 1 : 1.136     | (23)                          | 1 : 0.810     |
| (34)                         | 1 : 1.16          | (39)                          | 1 : 0.926     | (24)                          | 1 : 0.463     |
| (35)                         | 1 : 0.41          | (40)                          | 1 : 0.658     | (25)                          | 1 : 0.730     |
|                              |                   |                               |               | (26)                          | 1 : 0.740     |
|                              |                   |                               |               | (27)                          | 1 : 0.879     |
| Mean ± S. D.                 | 1 : 1.028 ± 0.262 | 1                             | 0.810 ± 0.220 | 1                             | 0.638 ± 0.182 |
| Mean ± S.D. of normal 5 dogs | 1 : 0.720 ± 0.248 | 1                             | 0.720 ± 0.248 | 1                             | 0.720 ± 0.248 |
| t-test : vs Control          | 0.05 < p < 0.1    |                               | 0.5 < p < 0.6 |                               | 0.5 < p < 0.6 |

( ) = Dog No.

**Table 4.** Ratio of <sup>131</sup>I-BSP from Right to that from Left Half of Liver per Gram of Liver Tissue

| Acute Experiment in Group 1  |                   | Chronic Experiment in Group 1 |               | Chronic Experiment in Group 2 |               |
|------------------------------|-------------------|-------------------------------|---------------|-------------------------------|---------------|
| Right Half : Left Half       |                   | Right Half : Left Half        |               | Right Half : Left Half        |               |
| (31)                         | 1 : 1.316         | (36)                          | 1 : 0.318     | (21)                          | 1 : 0.855     |
| (32)                         | 1 : 0.926         | (37)                          | 1 : 0.629     | (22)                          | 1 : 0.751     |
| (33)                         | 1 : 0.588         | (38)                          | 1 : 0.680     | (23)                          | 1 : 0.922     |
| (34)                         | 1 : 1.136         | (39)                          | 1 : 1.024     | (24)                          | 1 : 0.423     |
| (35)                         | 1 : 1.005         | (40)                          | 1 : 0.375     | (25)                          | 1 : 0.611     |
|                              |                   |                               |               | (26)                          | 1 : 0.249     |
|                              |                   |                               |               | (27)                          | 1 : 0.570     |
| Mean ± S. D.                 | 1 : 0.994 ± 0.242 | 1                             | 0.605 ± 0.252 | 1                             | 0.626 ± 0.221 |
| Mean ± S.D. of normal 5 dogs | 1 : 0.949 ± 0.202 | 1                             | 0.949 ± 0.202 | 1                             | 0.949 ± 0.202 |
| t-test : vs. Control         | 0.7 < p < 0.8     |                               | p < 0.05      |                               | p < 0.05      |

( ) = Dog No.

## B. Chronic experiment :

### (1) Changes of hepatic artery flow :

Eight weeks after the initial operation, the left half of the liver with postsinusoidal block showed a slightly dark color with congestion, but the right half showed little change. Following the injection of  $^{131}\text{I}$ -BSP into the common hepatic artery, radioactivity was detected in the blood in the portal vein on the hepatic side, but not in that on the intestinal side, indicating reversed flow from the left half of the liver into the portal vein. The ratio of blood flow in the right to that in the left half was  $1 : 0.902 \pm 0.259$  in the experimental group, with no significant difference from the value of  $1 : 0.984 \pm 0.253$  in normal dogs ( $p > 0.7$ ). Therefore the hepatic artery flow of the left half with postsinusoidal block was the same as that of the right half with presinusoidal block in the chronic stage, showing a return to normal of hepatic artery flow which had been decreased in the acute stage in the liver lobes with postsinusoidal block (Table 1).

### (2) Oxygen extraction ratio :

In most experimental animals the blood oxygen concentration was higher in the portal vein on the hepatic side than in the right hepatic vein. The oxygen extraction of the left half of the liver with postsinusoidal block was 50-84% that of the right half with presinusoidal block, showing that blood oxygen in arterial inflow was consumed more efficiently in the right lobes with presinusoidal block (Table 2). Further, the blood oxygen concentration in the portal vein on the intestinal side was higher than in that on the hepatic side, and the oxygen extraction ratio of the reversed blood flow in the liver lobes with postsinusoidal block exceeded that of the intestinal blood flow.

### (3) Liver function test :

The ratio of bile flow of the right to that of the left half of the liver was  $1 : 0.810 \pm 0.220$  in the experimental group, showing no significant difference in the left and right hepatic lobes from that in normal dogs ( $p > 0.5$ ) (Table 3). However, the ratio of  $^{131}\text{I}$ -BSP in bile excreted from the right to that from the left half was  $1 : 0.605 \pm 0.252$  in the experimental group, while it was  $1 : 0.949 \pm 0.202$  in normal dogs, showing a clear reduction in the secretory capacity of the liver lobes with postsinusoidal block ( $p < 0.05$ ) (Table 4).

### (4) Changes of liver weight and histologic findings :

The ratio of the liver weight of the right two lobes, the caudate and right lateral lobes, to the total body weight was  $0.52 \pm 0.11\%$  and that of the left two lobes, the left central and left lateral lobes, was  $0.86 \pm 0.06\%$  in the experimental group (Table 5). These were lower than in normal dogs, but slightly in the left lobes ( $p < 0.01$ ). In the left half of the liver with postsinusoidal block, necrosis and vacuolar degeneration were observed microscopically with intense destruction of liver cells, but few changes in the right half with presinusoidal block. Celiac angiogram revealed the hepatic artery to be tortuous and dilated in the liver lobes with postsinusoidal block.

## II. Postsinusoidal block in left half of liver after constriction of left hepatic vein in Group 2

### (1) Hemodynamic changes :

**Table 5.** Ratio of Liver Weight to Body Weight

| Chronic Experiment in Group 1 |                     |                     | Chronic Experiment in Group 2 |                     |                     |
|-------------------------------|---------------------|---------------------|-------------------------------|---------------------|---------------------|
|                               | Right lobes (C, RL) | Left lobes (LC, LL) |                               | Right lobes (C, RL) | Left lobes (LC, LL) |
| (36)                          | 0.52%               | 0.92%               | (21)                          | 0.55%               | 1.35%               |
| (37)                          | 0.31%               | 0.84%               | (22)                          | 0.50%               | 1.48%               |
| (38)                          | 0.59%               | 0.84%               | (23)                          | 1.00%               | 1.17%               |
| (39)                          | 0.54%               | 0.94%               | (24)                          | 0.61%               | 1.17%               |
| (40)                          | 0.63%               | 0.78%               | (28)                          | 0.74%               | 1.21%               |
|                               |                     |                     | (29)                          | 0.75%               | 0.90%               |
|                               |                     |                     | (30)                          | 1.05%               | 0.89%               |
|                               |                     |                     | (25)                          | 0.96%               | 1.07%               |
|                               |                     |                     | (26)                          | 0.50%               | 0.85%               |
|                               |                     |                     | (?7)                          | 0.90%               | 0.95%               |
| Mean±S. D.                    | 0.52±0.11%          | 0.86±0.06%          |                               | 0.76±0.20%          | 1.10±0.20%          |
| Mean±S. D. of normal 5 dogs   | 0.82±0.12%          | 1.20±0.20%          |                               | 0.82±0.12%          | 1.20±0.20%          |
| Weight loss                   | -39%                | -26%                |                               | -8.5%               | -8.3%               |
| t-test: vs. Control           | p<0.01              | p<0.01              |                               | 0.4<p<0.5           | 0.3<p<0.4           |

( ) = Dog No.

In the right half of the liver with presinusoidal block after ligation of the portal vein branches, there were no marked changes grossly, but the left half with postsinusoidal block after construction of the hepatic vein showed a slightly darker color without congestion or swelling. Autopsy revealed cicatrisation of the wall of the constricted hepatic vein, and in most cases the hepatic vein had been constricted to 1/2 or 1/3 its original diameter. Immediately following the injection of  $^{131}\text{I}$ -BSP into the common hepatic artery, radioactivity was detected in the portal vein on the hepatic side of the shunt, but not in the distal mesenteric vein. Thus, it was demonstrated that the arterial blood entering the left half of the liver flowed out partly via the constricted hepatic vein and partly via the portal vein in a reversed flow.

## (2) Liver function test :

Changes of bile flow were very variable and not significant in each dog ( $p>0.5$ ) (Table 3). The ratio of  $^{131}\text{I}$ -BSP in bile excreted from the right to that from the left half of the liver was 1 : 0.626±0.221 in the experimental dogs, while it was 1 : 0.949±0.202 in normal dogs, showing a greater reduction in  $^{131}\text{I}$ -BSP excretory function in the liver lobes with postsinusoidal block ( $p<0.05$ ) (Table 4).

## (1) Liver weight and histologic findings :

The ratio of the liver weight of the right two lobes, the caudate and right lateral lobes, to the total body weight was 0.76±0.20%, and that of the left two lobes, the left central and left lateral lobes, was 1.10±0.20% in the experimental group. These values were 8.3±8.5% lower than in normal dogs ( $p>0.4$ ) (Table 5). Microscopically, there was little damage to liver cells, and fibrosis was not detected in stains with azan.

### Discussion

In 1877 Eck proved that the portal vein of dogs could be ligated with impunity provided splanchnic blood was shunted into the vena cava. For about 60 years this research was unnoticed until the first wide clinical application of portacaval anastomosis by WHIPPLE<sup>28)</sup>. This shunting operation has come to be applied mainly to treat bleeding esophageal varices. It has been shown that animals can survive in good health for long time after diversion of the portal venous flow following an end to side portacaval anastomosis, where the liver is supplied by the hepatic artery alone with the hepatic vein as the outflow tract. However, the results of long-term follow-up studies of portacaval anastomosis have recently drawn attention of many investigators to the postoperative development of hepatic atrophy and postshunt encephalopathy<sup>12)13)19)22)26)</sup>. CALLOW<sup>1)</sup> and PANKE<sup>17)</sup> have reported the incidence of encephalopathy as 52% and 26%, respectively. It has been shown that encephalopathy, hepatic insufficiency and cardiac insufficiency are important factors related to late mortality following this shunt operation<sup>17)15)24)</sup>. Moreover, in cases with a high grade of postsinusoidal block, that is, in cases of the Budd-Chiari syndrome and of advanced liver cirrhosis where collateral circulation of the portal vein has developed, it sometimes happens that the blood flow into the liver from the hepatic artery reverses its direction within the liver and is drained into the portal vein on the hepatic side<sup>6)8)9)18)20)27)</sup>. In such cases it is thought that portasystemic collateral circulation develops, and most of the portal blood bypasses the liver and flows into the systemic circulation. Furthermore, when the sinusoidal pressure exceeds the portal pressure, part of the arterial blood entering the liver is reversed and drained via the portal vein in cases with severe postsinusoidal block or after a side to side portacaval anastomosis<sup>27)23)</sup>. The prognosis of the Budd-Chiari syndrome is generally unfavorable, death often being due to hepatic insufficiency or bleeding esophageal varices. However HUTCHISON<sup>4)</sup> described a patient who lived for 25 years, and HALES<sup>5)</sup> one who lived for 4 years after obstruction of all hepatic veins and another who lived for 13 years after obstruction of the inferior vena cava.

After a side to side anastomosis for patients with bleeding esophageal varices, MULDER<sup>14)</sup> showed, with BSP tests and oxygen extraction ratio, that the reversed flow into the portal vein was beneficial and effective in maintaining liver function.

TAMAKI, GOLBY and ORLOFF<sup>25)</sup> compared the extraction ratios of BSP, NH<sub>3</sub> and O<sub>2</sub> of the reversed portal flow with those of the blood flow via the hepatic vein after a side to side portacaval anastomosis following constricting the hepatic vein in the dog, and they concluded that the hepatic venous pathway was significantly more efficient than the reversed portal route.

REILLY, PRICE, SAWADA, DAVIDSON and VOORHEES<sup>21)</sup> calculated the rate of removal of NH<sub>3</sub>, BSP, O<sub>2</sub> and radiogold from the reversed portal flow after a side to side portacaval anastomosis in dogs and showed that the rate of removal of these metabolic tracers increased when the hepatic venous outflow resistance had been acutely or chronically increased.



In these investigations, the function of the reversed portal flow might have been influenced by both the left and the right half of the liver under different experimental circumstances, such as the left hepatic vein and right central vein being constricted or kept intact, and the right hepatic vein being ligated or kept intact. Furthermore, although the hepatic venous blood flow was calculated by subtracting the reversed blood flow from the hepatic artery flow, it is doubtful whether hepatic vein blood flow was exactly identical to the difference between the hepatic arterial flow and the reversed portal flow. In the present experiment, the effect of postsinusoidal block on hepatic hemodynamics and function was investigated and compared with that of presinusoidal block, after ligation or constriction of the hepatic vein from the left half of the liver and after ligation of the portal vein branches to the right half following the construction of a side to side portacaval anastomosis in the same dog at the same time to avoid many influences on hepatic blood flow and liver function, such as anesthesia, the general condition, and individual differences.

In the acute stage, congestion was observed in the left hepatic lobes of which the hepatic vein was ligated, and blood flow was also less than in the right lobes of which the portal vein branches were ligated, but liver function tests showed equal values for the right and left lobes. In this acute stage there was no liver cell damage, and a reversed flow into the portal vein was observed without any difference in oxygen extraction between the right and left halves of the liver. Thus it appears that if collateral circulation develops sufficiently following obstruction of the hepatic vein, adequate liver function might be maintained in the acute stage. On the other hand, although the blood flow in the left lobes was almost the same as in the right lobes, eight weeks later in the chronic stage, the  $^{131}\text{I}$ -BSP excretory capacity in the left lobes with postsinusoidal block was markedly lower than that in the right lobes with presinusoidal block.

These results suggest that the reversed flow does not perfuse the sinusoidal system sufficiently in the chronic stage, accompanying with severe liver cell damage. Therefore, the lobes with occlusion of the hepatic vein show serious deterioration of liver function even if collateral circulation was sufficiently developed, due to the decreased function of the reversed flow and severe damage to the liver cells in the chronic stage.

Furthermore, the present experiment reveals that some hepatic arterial blood flows reversely into the portal vein eight weeks after constriction of the hepatic vein in Group 2, in which histologic changes were only slight and liver function remained normal. Therefore, liver function may decrease due to ineffectiveness of the reversed flow of the hepatic artery, even if the liver cells show mild changes in postsinusoidal block.

### Summary

In cases of the Budd-Chiari syndrome or advanced liver cirrhosis with collaterals of the portal vein, it has already been demonstrated that arterial blood entering the liver is reversed and drains into the portal vein. In the present experiment, the effect of postsinusoidal block on hepatic hemodynamics and function was investigated and compared with

that of presinusoidal block, after ligation or constriction of the hepatic vein in the left half of the liver and ligation of portal vein branches to the right half following a side to side portacaval anastomosis, under identical condition in the same dog at the same time.

(1) In the postsinusoidal block immediately after occlusion of the hepatic vein, all of the arterial inflow of the liver is reversed into the portal vein on the hepatic side of the anastomosis, but liver function remains almost as similar as presinusoidal block.

(2) Eight weeks after occlusion of the hepatic vein, liver cell damage progresses and the arterial inflow to the liver becomes ineffective, even though collateral circulation may be sufficiently developed.

(3) When constriction of the hepatic vein continues for a long time, liver function is lowered with slight damage of liver cells accompanied by reversed flow of hepatic artery blood into the portal vein on the hepatic side of the anastomosis.

#### References

- 1) Callow, A. D., Resnick, R. H., Chalmers, T. C., Ishihara, A. M., Garceau, A. J. and O'Hara, E. T.: Conclusion from a controlled trial of the prophylactic portacaval shunt. *Surgery* **67** : 97-103, 1970.
- 2) Chowdhury, A. R. and Finestone, A. J. An usual case of portal systemic encephalopathy. *Amer J Digest Dis* **20** : 176-181, 1975.
- 3) Edmondson, H. T., Jackson, F. C., Juler, G. L., Sigel, B. and Perrin, E. B. : Clinical investigation of portacaval shunt : IV. A report of early survival from emergency operation. *Ann Surg* **173** : 372-380, 1971.
- 4) Hutchison, R. and Simpson, S. L. : Occlusion of the hepatic veins with cirrhosis of the liver. *Arch Dis Child* **5** : 167-186, 1930.
- 5) Hales, M. R. and Scatliff, J. H. Thrombosis of inferior vena cava and hepatic veins (Budd-Chiari syndrome). *Ann Int Med* **65** : 768-781, 1966.
- 6) Kessler, R. E., Tice, D. A. and Zimmon, D. S. : Retrograde flow of portal vein blood in patients with cirrhosis. *Radiology* **92** : 1038-1042, 1969.
- 7) Kline, D. G., Crook, J. N. and Nance, F. C. : Eck's fistula encephalopathy ; long term studies in primates. *Ann Surg* **173** : 97-103, 1971.
- 8) Lenthal, J., Reynold, T. B. and Donovan, A. J. : Excessive out-put of bile in Chronic hepatic disease. *Surg. Gynec Obstet* **130** : 243-253, 1970.
- 9) Longmire, W. P., Jr., Mulder, D. G., Mahoney, P. S. and Mellinkoff, S. W. : Side-to-side portacaval anastomosis for portal hypertension. *Ann Surg* **147** : 881-897, 1958.
- 10) Langer, J. J. and Fisher, M. M. Clinical spectrum of the Budd-Chiari syndrome and its surgical management. *Amer J Surg* **129** : 137-145, 1975.
- 11) Mikkelsen, W. P. : Therapeutic portacaval shunt. *Arch Surg* **108** : 302-305, 1974.
- 12) McDermott, W. V., Jr.: Evaluation of the hemodynamics of portal hypertension in the selection of patients for shunt surgery. *Ann Surg* **176** : 449-456, 1972.
- 13) McDermott, W. V., Barnes, B. A., Nardi, G. L. and Ackroyd, F. W. : Postshunt encephalopathy. *Surg Gynec Obstet* **126** : 585-590, 1968.
- 14) Mulder, D. G., Pleasted, W. G., III, Hanafee, W. N. and Murray, J. F. : Hepatic circulatory and functional alterations following side-to-side portacaval shunt. *Surgery* **59** : 923-931, 1966.
- 15) McDermott, W. V., Jr. : Surgery of the liver and portal circulation. Lea & Febiger. Philadelphia 1974.
- 16) Orloff, M. J., Wall, M. H., Hickman, E. B. and Neesby, T. : Influence of stomal size of portacaval shunts on peripheral blood ammonia levels. *Ann Surg* **158** : 172-181, 1963.
- 17) Panke, W. F., Rousselot, L. M. and Burchell, A. R. : A sixteen-year experience with end-to-side portacaval shunt for variceal hemorrhage Analysis of data and comparison with other types of portasystemic anastomoses. *Ann. Surg* **168** : 957-965, 1968.

- 18) Price, J. B., Jr., Voorhees, A. B., Jr. and Britton, R. C. : Operative hemodynamic studies in portal hypertension. *Arch Surg* **95** : 843-852, 1967.
- 19) Price, J. B., Jr., McCullough, W., Peterson, L., Britton, R. C. and Voorhees, A. B. : Effects of portal systemic shunting on intestinal absorption in the dog and in man. *SurgGynec Obstet* **125** : 305-310, 1967.
- 20) Reuter, S. R. and Redman, H. C. : Gastrointestinal angiography. W. B. Saunders Company 221-224, 1972.
- 21) Reilly, J. W., Price, J. B., Jr., Sawada, M., Dawidson, D. and Voorhees, A. B., Jr. : Effect of increased outflow resistance on retrograde portal flow and hepatic and metabolic efficiency following a side-to-side portacaval shunt. *Surgery* **66** : 1026-1033, 1969.
- 22) Smith, G. W. and Mouzas, G. L. . The metabolic response of the liver to portacaval shunt. *Surgery* **68** : Surgery 341-349, 1970.
- 23) Salam, A. A., Warren, W. D., James, R. LePage, Viamonte, M. R., Dune Hutson and Zeppa, R. : Hemodynamic contrasts between selective and total porta-systemic decompression. *Ann Surg* **173** : 827-844, 1971.
- 24) Turcotte, J. G. and Lambert, M. J. Variceal hemorrhage, hepatic cirrhosis and portacaval shunt. *Surgery* **173** : 372-380, 1971.
- 25) Takami, A., Golby, M. and Orloff, M. J. : Effect of side-to-side portacaval shunt on hepatic hemodynamics and metabolism. *Surgical Forum* 324-326, 1968.
- 26) Warren, W. D., Restrepo, J. E., Respass, J. C. and Muller, W. H., Jr. : The importance of hemodynamic studies in management of portal hypertension. *Ann Surg* **159** : 387-404, 1963.
- 27) Warren, W. D., Femon, J. J., Viamonte, M., Martinez, L. O. and Martin Kalser. : Spontaneous reversal of portal venous blood flow in cirrhosis. *Surg Gynec Obstet* **126** : 315-323, 1968.
- 28) Whipple, A. O. : The problem of portal hypertension in relation to the hepatosplenopathies. *Ann Surg* **122** : 449-475, 1945.

## 和文抄録

肝血行動態の実験的研究とくに  
postsinusoidal block 肝について

京都大学医学部外科学教室第1講座

川部 克己, 横田 峻

水本 龍二, 本庄 一夫

肝は肝動脈と門脈の2重支配をうけ、その肝内血行動態は肝静脈系の変化により種々の肝灌流をとることが知られている。Budd-Chiari syndrome や進行した肝硬変症では流出路の障害のため、肝リンパの産生とともに流入した肝動脈血が肝側門脈を逆行し、側副路を介して肝から流出することが指摘されているが、この逆行血の機能に関してはまだ十分な検討がなされていない。われわれは犬の分葉肝がそれぞれ独立した脈管構築をもつ特徴を利用して、左右の分葉肝が特有の血行支配をうけるように工夫した。すなわち側々門脈下大静脈吻合を造設して肝右半の門脈を結紮して pre-sinusoidal block とし、肝左半の肝静脈を結紮または狭窄して postsinusoidal block として、同一生体内で、従って同一条件で肝動脈が自然の outflow tract をとる pre-sinusoidal block 肝の機能と対比しな

がら、肝動脈血が肝側門脈を逆行する postsinusoidal block 肝の血行動態や機能の変化を検討し、以下の結果を得た。

- (1) 肝静脈閉塞直後の急性期においては、すべての流入肝動脈血は肝側門脈を逆行するが、肝機能は比較的良好に保持され、本来の肝動脈支配肝 (pre-sinusoidal block) におけるそれと殆んど変りはない。
- (2) 肝静脈閉塞が長期間持続すると、側副血行路が十分であっても、肝細胞の障害が進行して肝機能は低下し、流入肝動脈血の多くは sinusoid を bypass して無効血となっている。
- (3) 肝静脈狭窄が長期間持続する場合にも、肝細胞障害は軽微であるが、肝側門脈を逆行して流出する肝動脈血流があらわれ、肝機能の低下をまねく。