Arch Jap Chir 48 (2), 173~187, März, 1979

A New Artificial Intestinal Valve in the Dog : Its Comparative Function with the Intussuscepted Conical Valve and the Mucosal Valve

SATOSHI OHNISHI

The Second Department of Surgery, Faculty of Medicine, Kyoto University
(Director : Prof. Dr. YORINORI HIKASA)
Received for Publication Jan. 4, 1979.

Introduction

Two types of the artificial intestinal valves, the intussuscepted conical valve[2)6)9)] and the mucosal valve[1)4)16)], prepared by the invagination procedure have been reportedly useful to prevent certain disorders after surgical operation of the gastrointestinal tract. However, evidence was lacking for these valves about the postoperative events, the degree of stenosis induced, and their anti-reflux efficiency. It is important, with respect to anti-reflux apparatus in the intestinal tract, to achieve an effective anti-reflux function and at the same time to avoid significant stenosis. A new type of intestinal valve, referred to as the "muscular valve" in this paper, is reported and these three types of valves were studied comparatively with specific reference to the three standpoints described above.

methods and materials

Operative technique for the muscular valve : The seromuscular layer was detached from a length of an intestinal segment equal to its diameter. Hemostasis was performed carefully avoiding damage to the submucosal layer. The denuded mucosa was invaginated ditally together with the proximal side of the intestinal segment. The length of the invaginated segment was approximately one and a half to twice the length of its diameter, and the raw edge of the sectioned layer and the adjacent intestinal wall were sutured along the external contact fold of the invagination with interrupted silk sutures (Fig. 1).

Operative technique for the conical valve : Intestinal invagination was made, the length of the invaginatum being one and a half to twice the length of its diameter. Interrupted silk sutures were placed along the external contact fold (Fig. 2).

Operative technique for the mucosal valve : The seromuscular layer was detached from an intestinal segment, the length of which was twice the size of its diameter. After invaginating the denuded mucosa into the intestinal lumen, the raw edges of the sectioned layers were sutured with interrupted silk sutures (Fig. 2).

Key words : Intestinal valve, Reflux, Manometry
Present address : The 2nd Department of Surgery, Faculty of Medicine, Kyoto University, Sakyo-ku, 606, Japan.

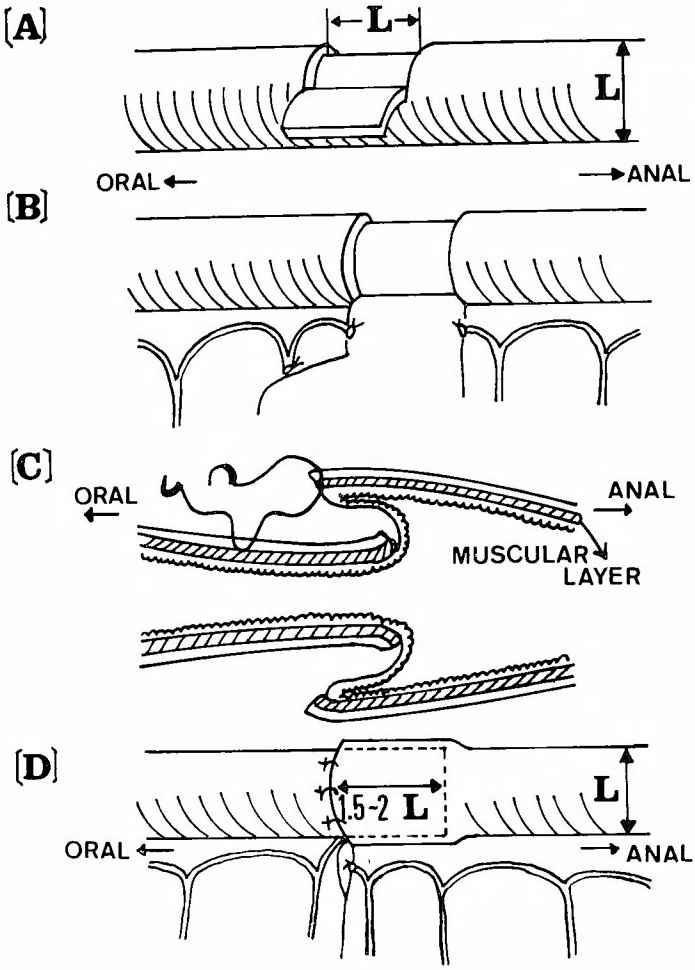

Fig. 1. Technique of the muscular valve (see text).

postoperative studies : (A) In 60 healthy mongrel dogs, the postoperative events asso ciated with these valves were studied. These valves were examined histologiclly using H & E., or Azan and van Gieson stains. Both muscular and mucosal valves were studied o the fifth postoperative day using microangiography.

(B) To assess the degree of stenosis caused by these valves, the following experimen was performed. Healthy mongrel dogs weighing between 7 and 13 kg were fasted for 2 hours and then anesthetized with intravenous pentobarbital sodium (25 mg/kg). Laparotom was performed in each dog and one of these valves was fashioned in the proximal jejunun Then seven muscular valves, five conical valves and three mucosal valves were made in 1 dogs. After three weeks, second laparotomy was performed and calibration of the extern intestinal diameter was performed on the distal and proximal segments adjacent to th valves.

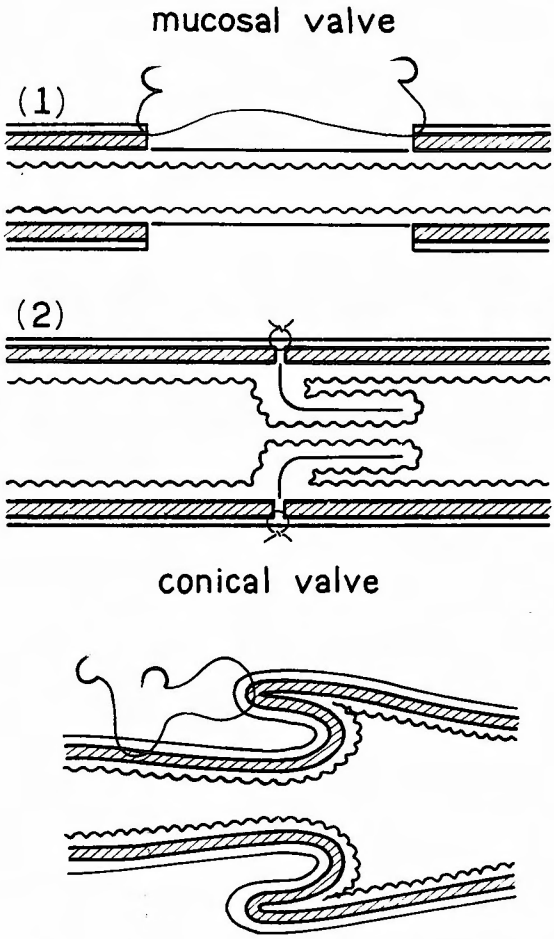

Fig. 2. Technique of the mucosal and the conical valve (see text).

(C) To assess the anti-reflux efficiency of these valves, the following experiment was performed. Fourteen mongrel dogs weighing 7 to 13 kg were divided into four groups. Group 1 (muscular valve) : In each of four dogs a muscular valve was fashioned in the proximal jejunum. Three weeks later Maydl's type of the jejunal fistula, with 7 cm Roux-en-Y limb involving this valve, was fashioned in each dogs. Group 2 (conical valve) : Three dogs were managed similarly to the dogs in group 1, the only difference being that conical valves were fashioned rather than muscular valves. Group 3 (mucosal valve): In three dogs mucosal valves were fashioned and managed similarly. Group 4 (control) : In each of five dogs the Maydl's type of jejunal fistula, with a 7 cm Roux-en-Y limb not involving any valves was fashioned in the proximal jejunum. After these treatments all dogs of these four groups were observed carefully and the volume of intestinal secretions through the fistula was measured (Fig. 3).

(D) To estimate quantitatively the degree of stenosis and the anti-reflux efficiency of

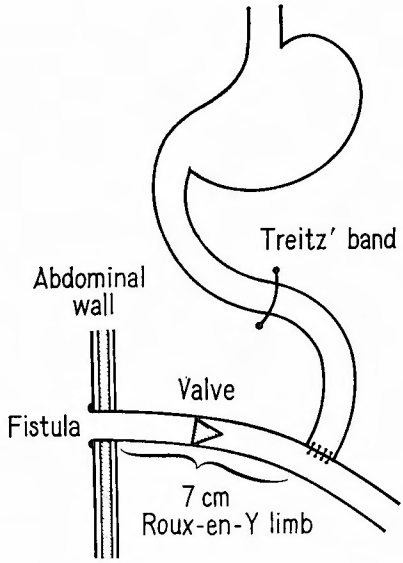

Fig. 3. Maydl's type of jejunal fistula with an intestinal valve was made in the upper jejunum for study of anti-reflux efficiency. Subsequently, close observation was made on secretion from the fistula.

each type of the valve, a manometric study was performed in the various postoperative periods by a modified SITNIK's method[13]. Laparotomy was performed on the dogs with the intestinal valves using intravenous anesthesia with pentobarbital sodium (25 mg／kg) and the following procedure was carried out under direct vision. A 20 cm intestinal segment, with a valve located at the middle of the segment, was isolated by severing the intestine but retaining its nerve and blood supply. Two polyethlene tubes were inserted together for a distance of about 2 cm either into the proximal or distal side opening of the segment. This insertion opening was closed with silk suture, the other end remaining open. One of these tubes was connected with a manometer and the intraluminal pressure was traced by the water-filled open-tip method. The other tube was connected with an infusion pump and warm physiological saline was infused at the rate of 30 ml/min. In the pressure study from the proximal side, the plateau of intraluminal pressure was defined as "stenosis pressure" and in the study from the distal side, the highest peak pressure was defined as "reflux pressure" (Fig. 4). These pressures were measured either three or four times with each valve and presented as mean values. Control values were obtained in 20 cm jejunal segments without any valve.

(E) For long follow-up study of a muscular valve, one dog in the Group 1 of postoperative study (C) was observed for one year and then its Roux-en-Y limb was brought back surgically to its own place. After three weeks, the intestinal calibration was performed under laparotomy.

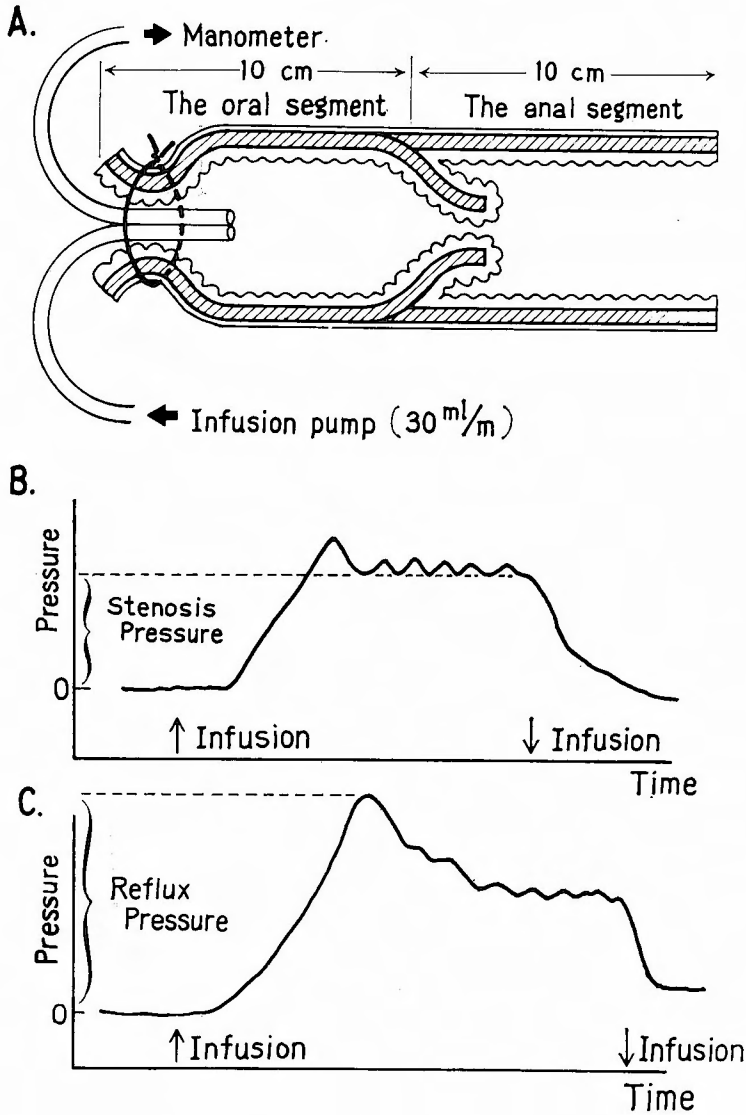

Fig. 4. Manometric study of the intestinal valve. A: Manometric analysis was undertaken on the intestinal segment with the valve under laparatomy. B: Manometry from the oral side segment was performed for the "stenosis pressure" measurement. C: Manometry from the analside segment was done for the "reflux pressure" measurement.

Results

(A) Two of 15 dogs with a muscular valve and two of eight dogs with a conical valve suffered from intestinal invagination in relative early postoperative periods. To prevent the invagnation, the antimesenteric border of the intestinal segment adjacent to a valve was anchored to its own mesentery with two or three sutures (Fig. 5). After this preventive procedure was adopted, invagination was not experienced in the subsequent 18 dogs with a muscular

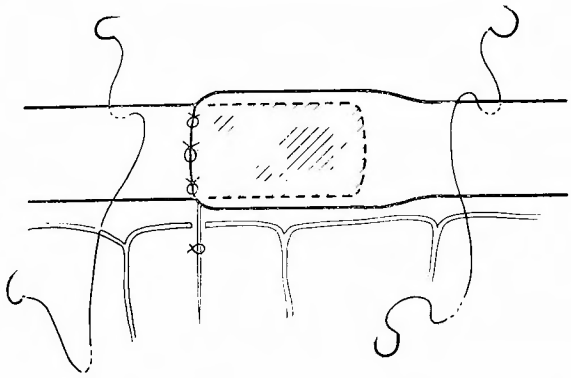

Fig. 5. The anchoring procedure of the valve to its mesentery was useful for prevention of invagination.

Fig. 6. The jejunal fistula with a muscular valve was extirpated after the fistulous study, and the intestinal wall over the valve was incised. The apex of the valve was then visible.

valve, although one of six dogs with a conical valve, treated by anchorig, died from invagination. Although hematoma arising in the muscular valve and the mucosal valve was apt to cause intestinal stenosis within the first week after the operation, it was prevented with careful hemostasis. In the late postoperative period, 2 of 15 dogs with a conical valve suffered from severe intestinal obstruction caused by an unexpected breakdown due to spontaneous slipping of sutures. The apex of the mucosal valve was found to be necrotic and fell off partially within the first week after the operation. Microangiography indicated that the apex of the mucosal valve was more severely injured from circulatory disturbance

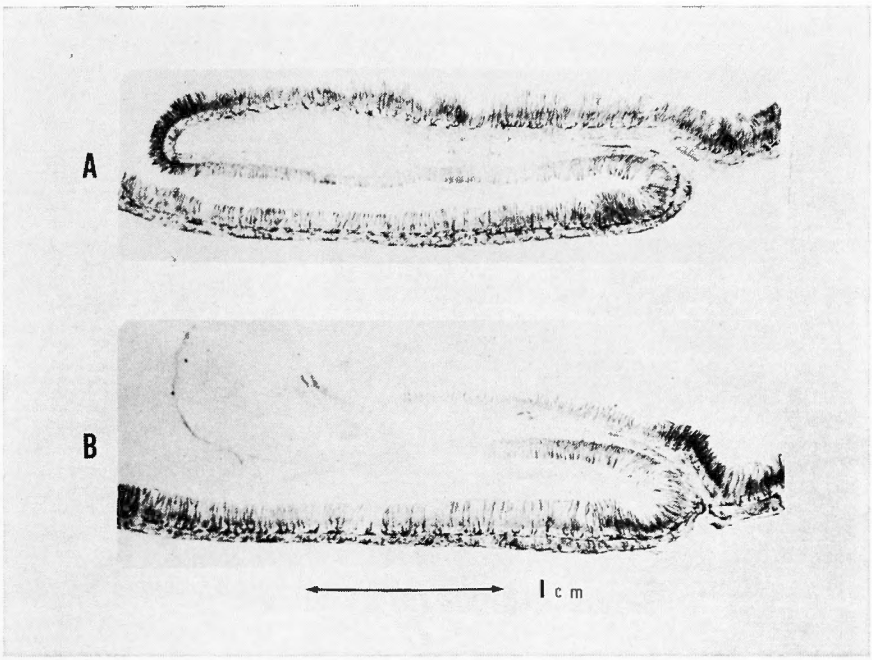

Fig. 7. Microangiography of the muscular valve (A) and the mucosal valve (B) in the fifth postoperative day. Circulatory disturbance was severe in the apex of the mucosal valve.

than that of the muscular valve (Fig. 7). Histological observation of these valves indicated the following findidgs. In the muscular valve, the folded intestinal wall adhered completely with its serosal surface, and the muscular layer of the outer side was lost, but that of the inner side was retained. In the conical valve, the adhesion of the folded wall could not be seen except at the site of sutures, and the muscular layer of it was retained in a line. In the mucosal valve, the adhesion was complete, the muscular layer in the folded wall was lost, and the apex of it was fibrous due to necrosis. The Auerbach's ganglion cells in the muscular valve and the conical valve were retained and stained normally (Fig. 8).

(B) The study of caliber change indicated the following findings. In seven dogs with the muscular valve, dilatation of the intestine proximal to this valve was not observed in the third to fourth week after operation, though very slight dilatation was observed in one dog after the half year follow-up. In addition, dilatation of the distal side was seen in some of these dogs. In all of five dogs with the conical valve and two of three dogs with the mucosal valve, mild dilatation of the intestine proximal to these valves was observed (Fig. 9).

(C) The study of the anti-reflux efficiency indicated the following findings. In all dogs of Group 1 and 2, intestinal secretion from the fistula was not present. All dogs of Group 3 and 4 died within five days from dehydration after the second operation, due to dripping of the secretion during the resting state and its rapid flow after eating (Table I).

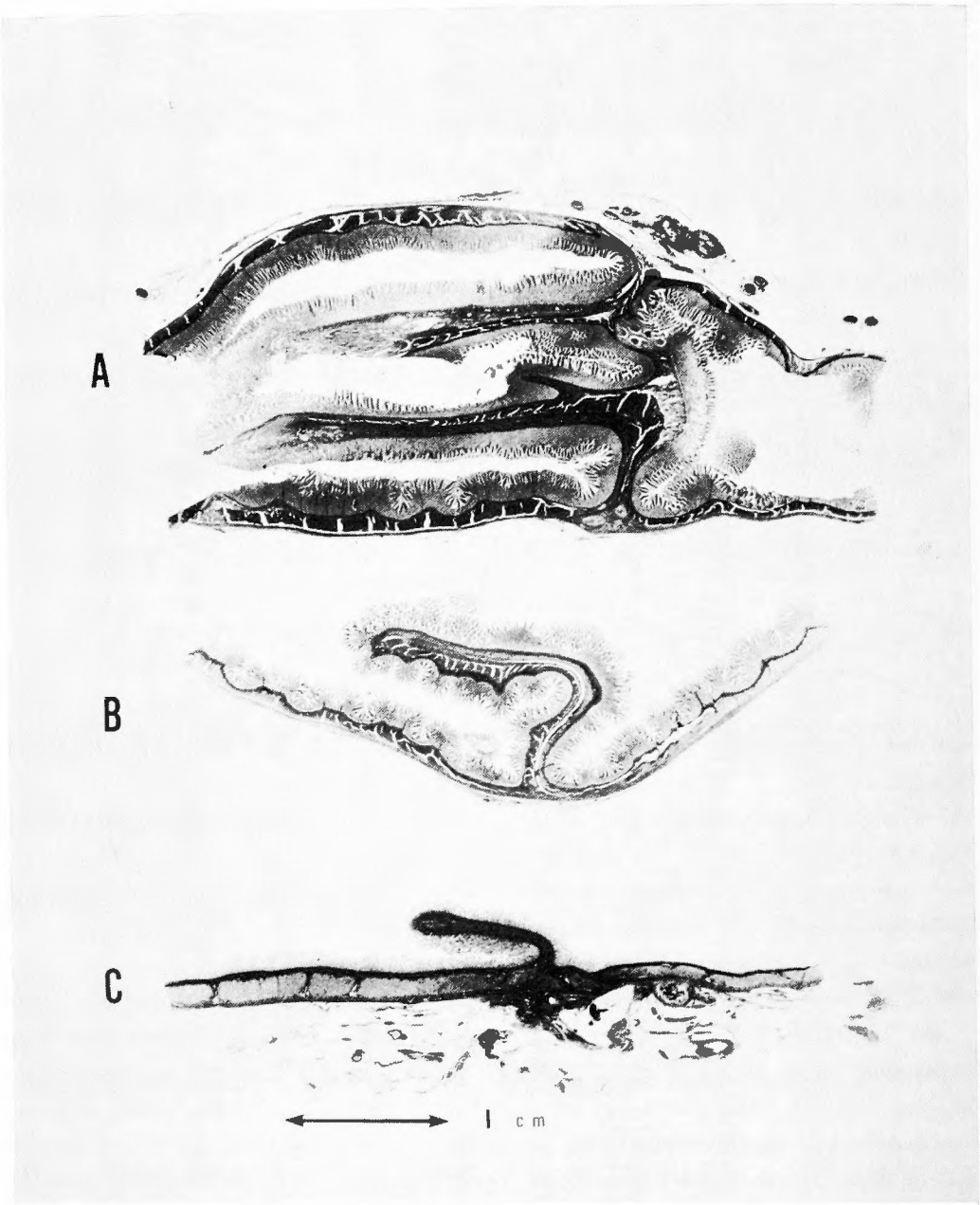

Fig. 8. Longitudinal sections of the three valves (Azan stain). A: The entire muscular valve. B: Half of a conical valve. C. Half of a mucosal valve. (see text)

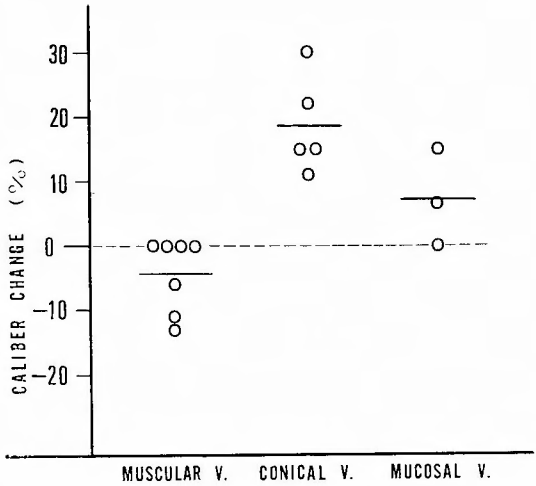

Fig. 9. Caliber change study in the late postoperative period, 4 weeks to 2nd month. Caliber change was represented by the following formula. Caliber change $(\%) = \frac{O-A}{A} \times 100$ O : outside diameter of the proximal intestinal segment adjacent to the valve. A: outside diameter of the distal. Bars in this figure represent the mean values ; −4.5% in the muscular valve, +18.5% in the conical valve and +7.2% in the mucosal valve.

Table I. Outflow through the external fistula in the late postoperative period, 4 weeks to 2nd month

	Outflow (cases)	
	(+)	(−)
Muscular valve	0	4
Conical valve	0	3
Mucosal valve	3	0
Control	5	0

(D) The manometric study indicated the following findings. The "stenosis pressure" and the reflux pressure of the control intestinal segments were 0.7±0.7cm H_2O (mean± standard error) and 0.7±0.7cm H_2O, respectively. In the period within eight days after operation, the stenotic pressure of the muscular valve was 12.6±3.4cm H_2O, and this value was, though not significantly, higher than that of the conical valve, 8.6±3.6cm H_2O. After this early period, that of the muscular valve, the conical valve and the mucosal valve were 7.0±1.2cm H_2O, 7.0±1.2cm H_2O and 11.3±1.5cm H_2O, respectively. These values were significantly higher than the control value ($p < 0.01$). The reflux pressures of all the four muscular valves were over 200cm H_2O, while that of one conical valve was 108cm H_2O, but those of the other three conical valves over 200cm H_2O. These values were so high that the infusion was stopped so as not to injure the intestinal wall. Reflux pressures of three

Table II. Manometric study in the late postoperative period, 4 weeks to 2nd month

	Muscular v.	Conical v.	Mucosal v.	Control
"Stenosis pressure" (cmH_2O)	7.0 (5) ±1.2*°	7.0 (5) ±1.2°	11.3 (4) ±1.5°	0.7 (3) ±0.7
"Reflux pressure" (cmH_2O)	No 1. > 200 No 2. > 200 No 3. > 200 No 4. > 200 No 5. > 200	No 6. > 200 No 7. > 200 No 8. > 200 No 9. > 200 No 10. = 108	No 11. > 200 No 12. = 37 No 13. = 20 No 14. = 15	0.7 (3) ±0.7

* Me an (Number) ± SE. °$p<0.01$ vs control.

mucosal valves were 37, 20 and 15cm H_2O but in the other mucosal valve it was over 200 cmH_2O (Table Ⅱ).

(E) Secretion from the fistula of this dog was not observed during the one year follow-up. At the time of the final laparotomy, the proximal intestinal segment adjacent to the valve was very slightly dilated, while the postoperative courses were uneventful.

Discussion

The intussuscepted conical valve reported by BASSO[2] and the intestinal muscular ablation by HIDALGO et al.[5], referred by TOBIK, LUKASIEWICZ and STARZEWSKI as the "mucosal valve"[16], are typical artificial intestianl valves produced by the invagination procedure. Other types of intestinal valves also have been reported in the literature.[10,12,14,17] We could not, however, find information pertaining to the postoperative events, the anti-reflux efficiency and the degree of stenosis of these valves. And another artificial intestinal valve, the muscular valve, was presented in this paper, which is a refined technique of the intestinal valve by telescoping anastomosis we reported.[18,19] The purpose of this study was to obtain knowledge about the above three standpoints in these three kinds of the invagination valves; the muscular, the conical and the mucosal valve.

Postoperative events : Intestinal invagination occurred in 13% of the muscular valve group, and 25% of dogs of the conical valve group respectively, although the anchoring procedure was able to prevent this trouble. Since invagination occurs more easily in the intestine of the dog than man, this preventive technique may not be needed in clinical application. It is, however, clinically important that an unexpected breakdown of the conical valve could occur in any postoperative period because of no adhesion of the folded wall.

The degree of stenosis : The caliber change study indicated that the muscular valve did not induce stenosis, while the other two valves were mildly stenotic. The distal intestinal dilatation in some dogs with a muscular valve is of unknown origin, but it will be not important in clinical use. The manometric study could not elicit difference in the degree of stenosis among these three valves in the late postoperative period. Since these manometrical tests were not made under physiological state, the results of the caliber change study may indicate the propulsive peristalsis of the folded wall of the muscular valve in physiolo-

gical state. The muscular valve was found, though not significantly, to be more stenotic than the conical valve within the early postoperative period, but this problem was improved by adequate hemostasis of the denuded mucosa.

The anti-reflux efficiency : The muscular valve and the conical valve had perfect anti-reflux effectiveness in the abdominal cavity within both the jejunal fistula and manometric studies. The mucosal valve, however, was not effective in the fistula study, and had variable low values of the reflux pressure. The necrotic loss of the apex of the mucosal valve accounts for its poor results.

Long term follow-up study: After one year postoperative period, the muscular valve had retained its anti-reflux effectiveness, and it was very slightly stenotic.

The author recommends the muscular valve as a postoperatively eventless, little stenotic and perfectly effective intestinal valve rather than the other two valves. Although further investigation is needed for clinical application of this valve, it will be a useful anti-reflux procedure in surgical operation of the gastrointestinal tract.

Its clinical use : Prevention of postoperative ascending cholangitis is the key point to obtain successful results after corrective surgery for congenital biliary atresia. Intestinal decompression or complete separation of the bilio-digestive anastomosis from the intestinal tract may prevent the postoperative cholangitis.[7] For the intestinal decompression, KASAI reported double-Y hepatic portojejunostomy with external fistula,[8] and for the complete separation, SAWAGUCHI and SURUGA reported hepatic portojejunnostomy with external fistula[11] and hepatic portojejunostomy in Roux-en-Y with double-barreled jejunostomy[15] respectively. Then, operative results for biliary atresia have been remarkably improved by these modifications. However, the former procedure needs very complicated technique, and the latter two procedures give rise to electrolyte derangement due to loss of bile through

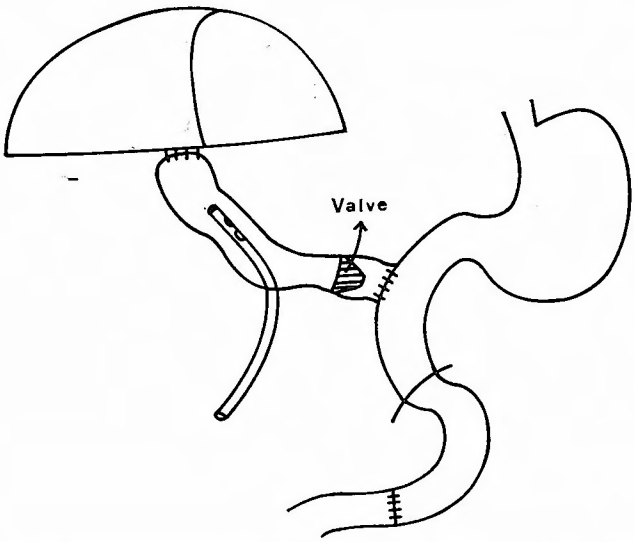

Fig. 10. Hepatic portojejuno-duodenostomy with the intestinal valve for congenital biliary atresia.

the external fistula and need the second operaton. The new intestinal valve presented by the author in this paper may be able to improve these weak points (Fig. 10).

And this new valve may perform the following clinically important function. It will prevent intrapancreatic activation of the enzymes by intestinal fluid after pancreatic cysto-jejunostomy, and ascending cholangitis after inadequately anastomosed bilio-jejunostomy

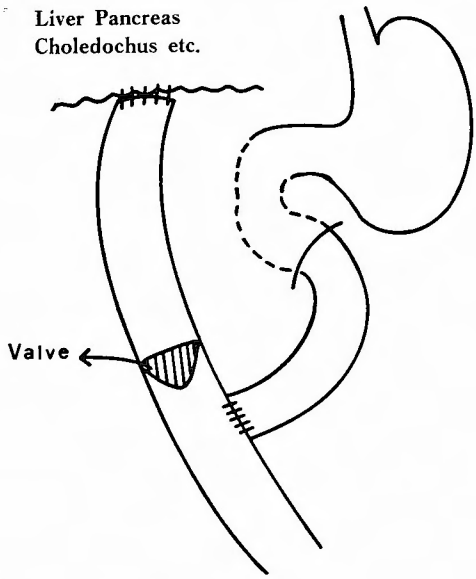

Fig. 11. Bile duct and pancreatic surgery using Roux-en-Y limb with the intestinal valve.

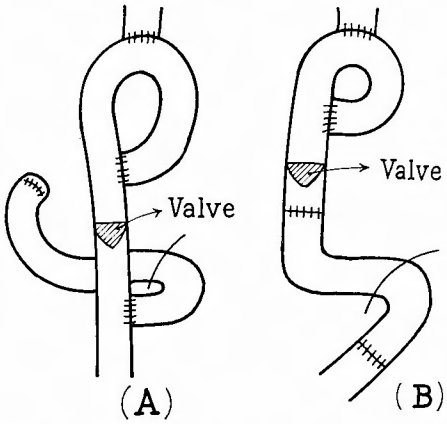

Fig. 12. Reconstruction after total gastrectomy. (A) : Roux-en-Y esophagojejunostomy with the intestinal valve. (B) : Interposed jejunal segment with the valve.

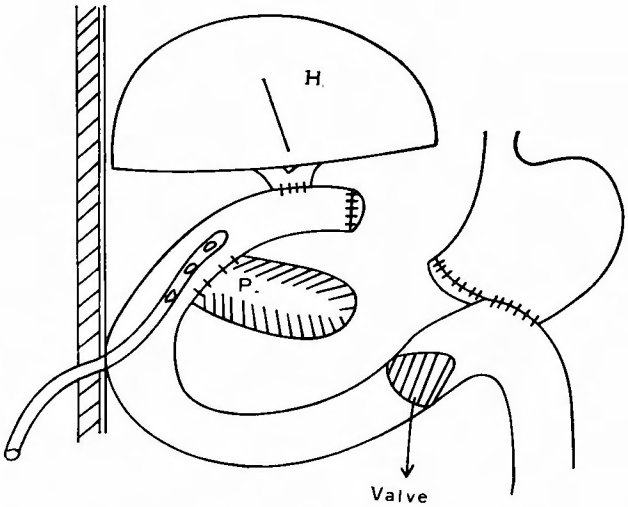

Fig. 13. Reconstructive procedure involving the intestinal valve after pancreatoduodenectomy.

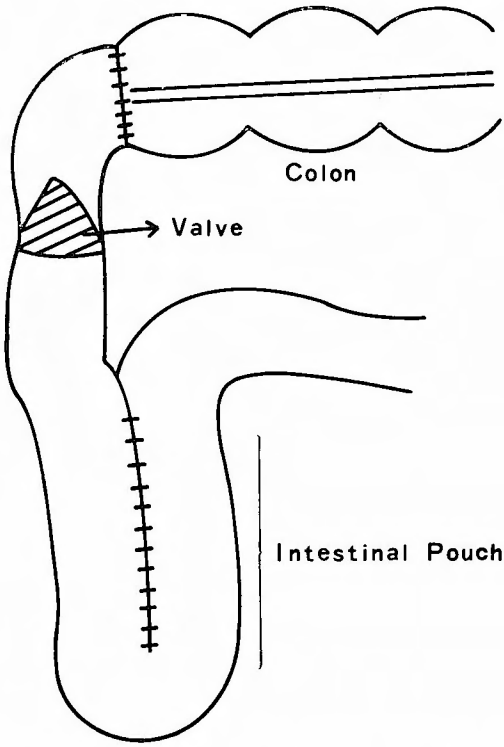

Fig. 14. Reconstructive procedure involving the intestinal pouch and the intestinal valve after massive bowel resection.

(Fig. 11). After total gastrectomy, it will protect the esophageal mucosa from bile (Fig. 12). In pancreatoduodenectomy, it will keep safe the choledocho-jejunostomy and the pancreato-jejunostomy from leakage by its anti-reflux of food and gastric juice (Fig. 13). In the surgical management of massive bowel resection, the procedures of reversed small bowel segments and formation of a pouch delay the transit through the remaining bowel, and allow a longer period for contact and absorption. But the objections to these procedures are the risks of stasis with superinfection, with aggravation of the malabsorption already caused by the short length of bowel.[3] The risks will be decreased if the intestinal valve is able to build up the bacterial barrier (Fig. 14). Further investigation will be continued in animals for clinical application of this intestinal valve.

Summary

Three types of artificial intestinal valves prepared by the invagination procedure were studied comparatively ; the intussuscepted conical valve and mucosal valve as described in the literature, and a new type of the valve referred to as the "muscular valve". Careful postoperative observation, histological study, assessment of intestinal caliber change, observation of secretion through the Maydl's type of intestinal fistula, and manometric study for a one year follow-up were performed on the intestines of dogs. Particular reference was

made to postoperative events, the degree of stenosis, and the antireflux efficiency. These postoperative courses were uneventful except for the unexpected breakdown of the conical valve and intestinal invagination caused by the conical and muscular valves in some dogs. Both the conical and the muscular valve prevented effectively the reflux of intestinal fluid, but the mucosal valve did not. The muscular valve was not so stenotic as the conical or the mucosal valve. The muscular valve is recommended as optimal for anti-reflux action in the intestine. Clinical application of this valve is discussed.

Acknowledgements

The author is grateful to Professor Dr. YORINORI HIKASA for his supervision of this research and to Associate Professor Dr. KISAKU SATOMURA for his helpful guidance. The author also thanks Dr. K. KUMADA for his instruction in manometry, Dr. H. ZHENG for his kind advice, Dr. K. TANIGAWA for his skillful help in microangiography, Dr. K. TANAKA for his strenuous efforts in the clinical application of this valve, and Professor CARL J. PFEIFFER for suggestions pertaining to the manuscript.

References

1) Ackroid FW, Giles G et al : Ileal mucosal valve to prevent reflux at the ileorectal anastomosis in the colon exclusion operation for hepatic encephalopathy. Surg Forum **20** : 356-357, 1969.
2) Basso DE : The efficacy and applicability of an intussuscepted conical valve in preventing regurgitation and leakage of intestinal contents. Ann Surg **133** : 477-485, 1951.
3) Cywes S: The surgical management of massive bowel resection. J Pediatr Surg **3** : 740-748, 1968.
4) Glassman JA : An artificial ileocecal valve. Surg Gynecol Obstet **74** : 92-98, 1942.
5) Hidalgo F, Cortes ML et al : Intestinal muscular layer ablation in short-bowel symdrome. Arch Surg **106** : 188-190, 1973.
6) Hubbard Jr TB : The prevention of bypass enteritis after jejunoileal bypass for morbid obesity. Ann Surg **187** : 502-509, 1978.
7) Kasai M: Treatment of biliary atresia with special reference to hepatic porto-enterostomy and its modifications. Prog Pediatr Surg **6** : 5-52, 1974.
8) Kasai M, Asakura Y et al : Modifications of hepatic portoenterostomy to prevent postoperative ascending cholangitis. Fifth Annual Meeting of the Pacific Association of Pediatric Surgeons, 1972, Tokyo, Japan.
9) Perl JI : Intussuscepted conical valve formation in jejunostomies. Surgery **25** : 297-299, 1949.
10) Peterson LW and Cole WH : Use of the defunctionalized loop of jejunum in biliary and pancreatic surgery. Arch Surg **56** : 445-458, 1948.
11) Sawaguchi S, Nakajo T et al : Staged reconstruction of biliary tract for congenital biliary atresia. 68 th Annual Meeting of Japanese Society of Surgery, 1968, Kanazawa, Japan.
12) Schiller WR, Didio LJA et al: Production of artificial sphincter. Arch Surg **95** : 436-442, 1967.
13) Sintnick JL, Warren WD et al: The evaluation of sphincter of Oddi function. Surg Forum **15** : 373-375, 1964.
14) Stahgren LH Roy RH et al : A mechanical impediment to intestinal flow. JAMA **187** : 41-44, 1964.
15) Suruga K: Operations for biliary atresia. Shujutsu **24** : 543-549, 1970 (in Japanese).
16) Tobik S, Lukasiewicz S et al : An attempt at forming an effective gastroesophageal mucosal valve. Surgery **77** : 225-230, 1975.
17) Waddel WR, Kern F et al: A simple jejuncolic "valve" Arch Surg **100** : 438-444, 1970.
18) Zheng H: An experimental study on the artificial intestinal valve by telescoping anastomosis. Arch Jap Chir **46** : 657-680, 1977.
19) Zheng H, Ohnishi S et al: Manometric evaluation of an artificial intestinal valve. Arch Surg **111**: 578-581, 1976.

和文抄録

新しい人工腸弁とその検討

—— the intussuscepted conical valve と the mucosal valve との批較——

京都大学外科学教室第2講座（主任：日笠頼則教授）

大　西　　慧

近代における消化器外科の進歩に伴い，臓器摘出術が安全に施行される様になって来たが，一方その術后困難症が問題となり，諸種再建術式の考案がなされている．近年，腸重積法による2種の人工腸弁（the intussuscepted conical valve 及び the mucosal valve）が，諸種術后障害を予防するに有益であると報告されている．しかし，それ等の valve の作製そのものによる術后合併症，valve 部分の通過障害の程度，それにその逆流防止機能の強さについての系統的検討はなされていない．術后合併症のない，通過障害のない，そして同時に，強い逆流防止機能を持った人工腸弁を求めて，著者の考案した新しい人工腸弁（the muscular valve）を報告すると共に，これ等3種の人工腸弁を上記した3つの見地から，成犬を用いて比較検討した．

A）術后合併症について：

muscular valve を持った犬の13%に，そして conical valve を持った犬の25%に，腸重積症が発症した．しかし，その予防的処置を加えることにより，全くそれが発症する事はなかった．犬の腸管に於ては，腸重積が発生し易いので，臨床応用に於ては，その予防的処置は必要ではないのかもしれない．又，conical valve は，術后のいずれの時期にても，その縫合部がはずれて，自然破壊がおこり，強い狭窄がおこる可能性がある．他の2種の valve についてはその心配は全くない．

B）通過障害の程度について：

muscular valve と mucosal valve にては，その作製時に十分な止血がなされない場合，血腫により術后早期において，軽度の狭窄を見る場合があるので注意が必要である．それ以后の時期においては，muscular valve では狭窄の所見が全くなかったが，他の2つの valve では，中等度の狭窄の所見が見られた．

C）逆流防止機能の強さについて：

muscular valve と conical valve は，腸管内容の逆流を完全に防止したが，mucosal valve は，その成績が一定せず，大半のものが，逆流を防止することが出来なかった．

以上の成績により，muscular valve は，他の2種の valve に比較して，安全で，狭窄が少く，又強い逆流防止機能を持った人工腸弁であると考える．又その臨床応用の術式についても検討を行った．