Arch Jap Chir 48 (2), 160~172, März, 1979

A New Operative Procedure of Hepatic Surgery Using a Microwave Tissue Coagulator

KATSUYOSHI TABUSE

Department of Gastroenterological Surgery, Wakayama Medical College
(Chief : Prof. Dr. MASAHARU KATSUMI)
Received for Publication Nov. 15, 1978.

Introduction

For success of surgery in resections of parenchymal organs, especially in hepatectomy it is essential to control hemorrhage during operation. Accepted surgical principles includ control of hepatic hilar vessels, dissection along segmental planes and individual ligatio of large bleeding points. These technics, however, may not control bleeding in numerou minute vessels in the transected parenchyma. Bleeding, leakage of bile and retention (devitalized tissue account for the majority of complication in hepatectomy[1)15)].

Microwave energy is a part of the electromagnetic spectrum, and at frequency (2,450 megacycles per second, it penetrates several centimeters into biological tissues[19] This energy is absorbed and converted into heat within the tissue. The amount of he produced within the tissue can be controlled by adjustment of the energy level and th duration of exposure. Applications of microwave energy in medicine are still within th limit of diathermy treatment, especially in the field of orthopaedics, and biological effec of microwave have only been investigated experimentally[13)]. CATER et al[2)] have shown th microwave heating acts synergistically with X-ray radiation in destroying the rat hepaton 223. Copeland and Michaelson have demonstrated that selective tumor heating causes increase ^{131}I fibrinogen localization so that ^{131}I radiation can destroy the tumor tissue[4)].

The present experiment was designed to develop a suitable apparatus of microwave f tissue coagulation-necrosis, and to use this apparutus in hepatectomy.

Materials and Methods

Apparatus :

The power source was Microtron MT-7P, a 2,450 MHz diathermy machine with 1 watts of maximum output. Application of microwave energy in the tissue coagulati process was designed as follows ; a coaxial cable was connected to the microwave chamb and the apex of the cable was connected to a monopolar antenna (Fig. 1). The base of t antenna was 10 mm in diameter. This apparatus provided 20 to 90 watts, focused arou the antenna with the width as the antenna base. Therefore, the depth of the coagulat

Key words : Hepatectomy, Mycrowave, Microtron, Tissue coagulation
Present address : Department of Gastroenterological Surgery, Wakayama Medical College, 7 Banch Wakayama-shi, Wakayama, Japan.

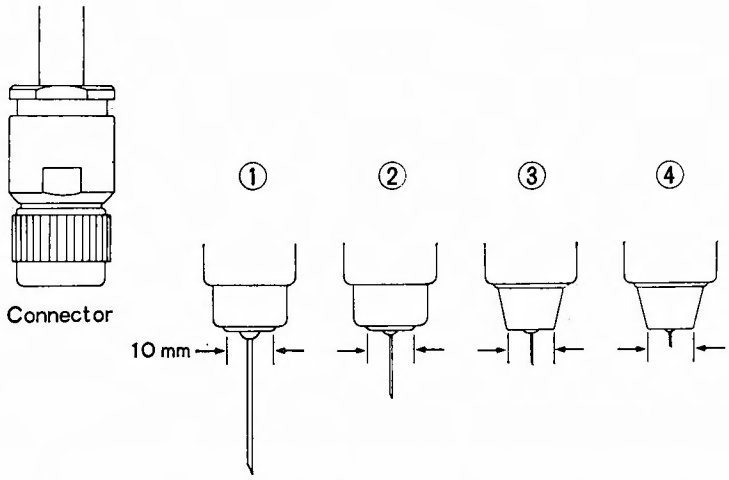

Fig 1. Illustration of four kinds of antenna. The length of No.1, 2, 3, 4, are 31.5, 15.6, 7.8 and 3.9mm respectively.

tissue was the same as the length of each antenna.

The relationship between the forward power of microwave radiation and the time of coagulation without carbonization of albumen :

As a preliminary experiment, the effect of graded irradiating power in relation to the time of coagulation was studied. A monopolar antenna was inserted into the albumen pooled in the breaker under adiabatic conditions. The range of forward power used was from 25 to 90 watts. Colour evaluation at the beginning of the coagulation was performed macroscopically.

Procedure :

Twenty-six rabbits of both sexes weighing 2.5 to 3 kg were used for the experiments. All the animals were anesthetized with 30 mg/kg of pentobarbital sodium intravenously. Laparotomy was performed with an upper midline incision, and a total of fifty-two lobes were partially resected. An average of 30 percent of liver substance was excised from each animal. Resection was carried out in different directions and planes, thus disregarding the segmental anatomy. The output power varied from 25 to 65 watts, for 20 seconds. The monopolar antenna was inserted into each parenchyma several times causing a coagulated beltlike area, 10 mm in width on the surface of the parenchyma with the depth determined by the length of each insertion. Transection of parenchyma was performed with a surgical knife. No suture materials were employed. This was a simple process that left a coagulated liver stump at the center of the transected liver. The operative procedure took about 10 minutes in all the experiments. Penicillin (10,000 units) was administered intraperitoneally, and the operative wound was closed primarily by one-layer silk suture (Fig 2). Experimental animals were divided into 8 groups. The 1st group was sacrificed immediately after the experiment. The second, 3rd, 4th, 5th, 6th, and 7th group were sacrificed at the intervals

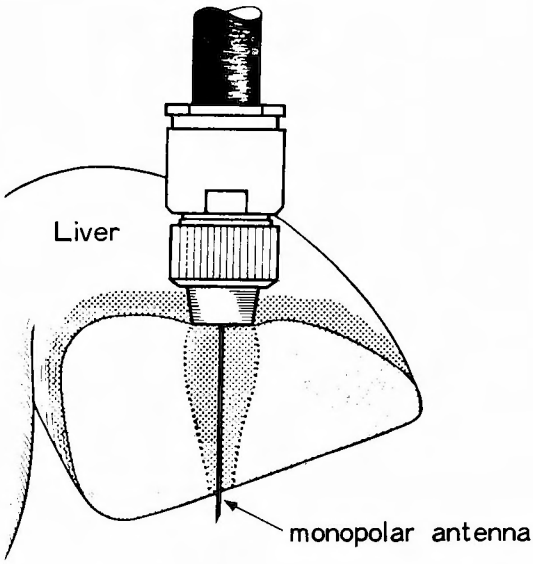

Fig 2. The typical placement of an antenna at the operation. Dark shading shows the coagulated area.

of 3, 7, 14, 21, 60, 90 and 180 days, respectively. The 1st group consisted of 5 animals and the others 3.

Angiography :

One of the animals in each group was used for portangiography. Immediately after cannulation to the portal vein, the liver was removed for portography. A contrast medium of micropaque with 10 percent gelatine was perfused. Soft X-ray studies of the vessels were made. The transected major vessels were clearly visible at the center of the films.

Tissue heating :

To examine the temperature of the tissue adjacent to the antenna, the livers of five rabbits in the immediate group were used. The animals were anesthetized with 30 mg/kg pentobarbital sodium, and access to the liver was gained through an upper midline incision. The temperature of the liver was recorded by a copper-constantan thermocouple inserted into the liver. Heating time varied from 5 to 20 seconds and output power was from 50 to 65 watts.

Chemical analysis :

Five samples were obtained from auricular vein at the time described above. The activities of SGOT and SGPT levels were assayed by the method of Reitman-Flankel. The serum alkaline phosphatase level (Al-p) was assayed by the method of King-King.

Autopsy :

The process of healing at the margin of the liver was examined macroscopically and microscopically at the time described above. After the abdomen and lower chest were opened, examination for evidence of necrosis, infection and abscess formation, as well as

bleeding and bile leakage were made. The liver weight was compared with the preoperative weight of the whole liver which was calculated at the immediate group. The specimens for microscopical examination were fixed in 10 percent formalin and then enbedded in paraffin blocks. Sections thus obtained were stained with hematoxylin and eosin.

Results

The relation of forward power of microwave radiation to the time of coagulation of albumen was hyperbolic as shown in Fig. 3. These curves indicate the characteristic parameters. The above results lead to Fig. 4 in which the colour evaluation for representative coagulated area of the albumen was summarized.

Rabbit hepatectomy :

Traction on the separating edges of the coagulation caused some hemorrhage, probably due to rupture of blood vessels prior to transection and coagulation. This bleeding could be reduced by limiting the traction and could be controlled by temporarily directing the tip of the antenna to the bleeding site, and no suture materials are needed. The operative procedure took about 10 minutes in all experiments. Neither postoperative bleeding nor bile peritonitis was observed. None died within 72 hours after hepatectomy but two died shortly after that time. One of them died of intestinal obstruction due to incisional hernia on the 4th postoperative day and the other died of jaundice due to obstruction of the common bile duct on the 10th postoperative day. At the time of autopsy abscess formation was observed at the edge of the liver in one of 24 rabbits.

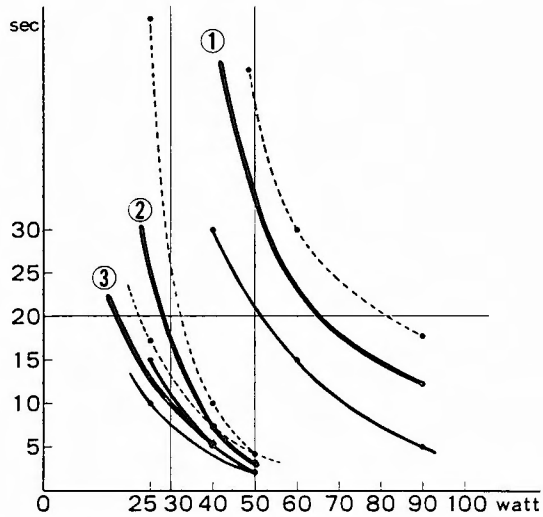

Fig 3. The relation of forward power of microwave radiation to the time of coagulation of albumen. The thin solid lines indicate the relationship of the power to the time at the beginning of albumen coagulation, and the thin broken lines do that at the beginning its carbonized. The thick solid lines show the reasonable limit.

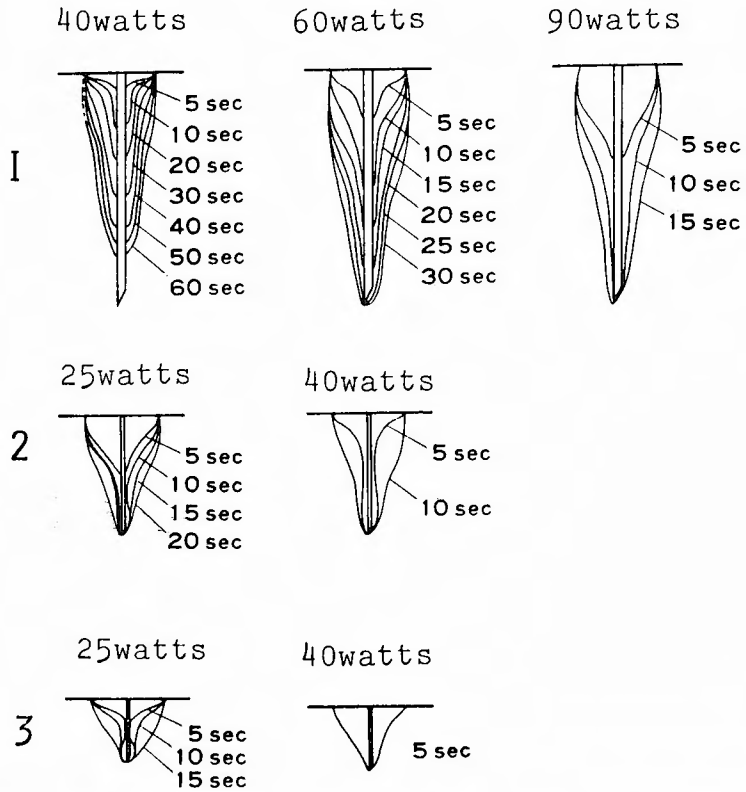

Fig 4. Illustration of representative coagulated area of the albumen without carbonization for each of three antennas.

Fig 5. Portography of sample immediately after hepatectomy in rabbits.

Angiography :

The vessels were sealed by heat coagulation. Veins up to 3 mm in diameter could be coagulated (Fig. 5). No contrast medium leakage was observed from the margin. An avascular area was 8 to 10 mm thick at the edge. This layer was sharply demarcated from the normal parenchyma.

Tissue heating :

The experimental temperature measurements were found to be reproducible with a 91 percent accuracy. Fig. 6 and 7 show a typical temperature response of rabbit liver adjacent

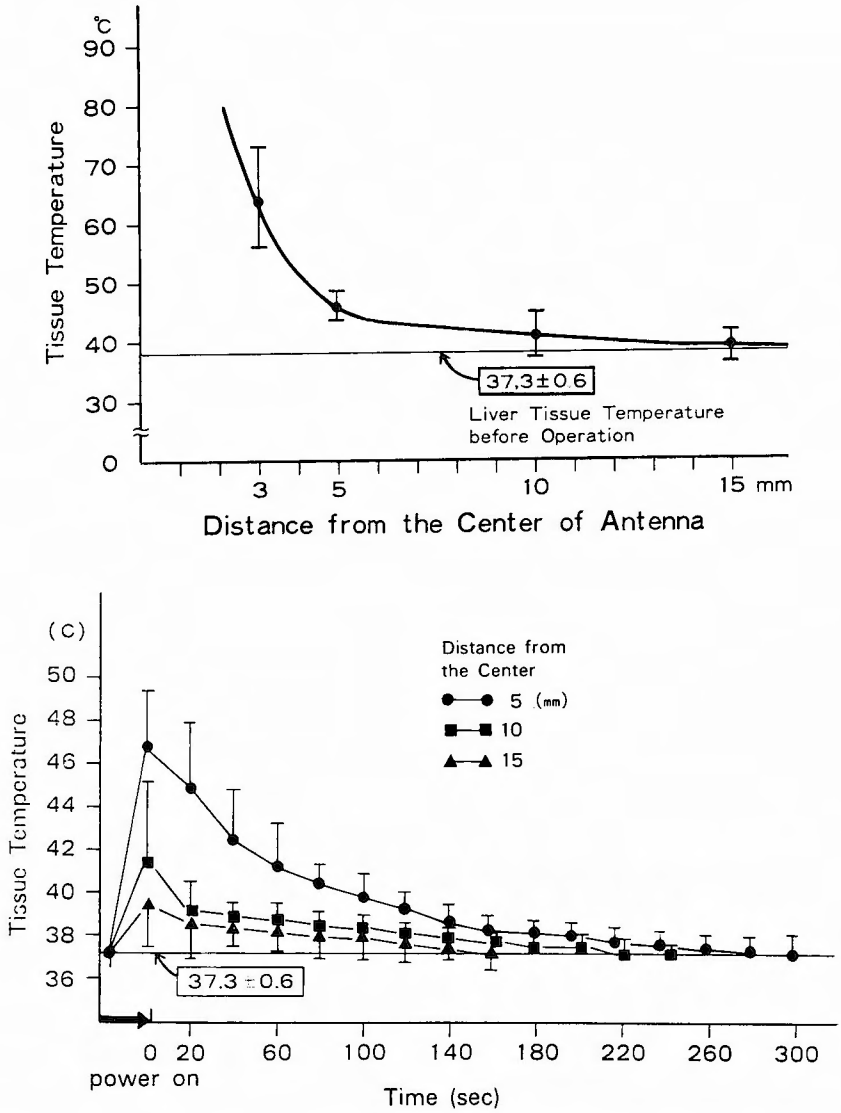

Fig 6. 7. In vivo rabbits liver thermal response to microwave coagulation. Each value represents a mean with standard deviation of 6 rabbits.

to the coagulated tissue which is made by 20 seconds radiation with the microwave energy with thermocouple placement 10 mm deep and between 3 and 15 mm from the center of the coagulated tissue. At a distance of 3 mm from the center, the maximum temperature was 65°C, while at 5 mm, the tissue temperature was 46.7°C, and at 10 mm, it did not exceed 43°C. Since the minimum temperature at which cellular thermal damage occurs is about 43°C, the result of the temperature measurements indicate that the extent of thermal damage caused by microwave energy may be less than 10 mm wide.

Chemical analysis :

The changes of SGOT, SGPT and serum Al-p activities are shown in Fig. 8. In all the cases, SGOT and SGPT increased markedly, with a peak 6 to 12 hours after the hepatectomy. These two enzyme activities equally returned to the preoperative level seven days after hepatectomy. Serum Al-p activity was more prolonged than the activities of SGOT and SGPT.

The process of healing at the resected liver stump :

Macroscopical findings ;

The liver was congested. The margin of the liver and subjacent coagulated area were covered with omentum on the 1st postoperative day. The necrotic area was relatively circumscribed. On the 3rd postoperative day, the necrotic area was 8 to 13 mm thick

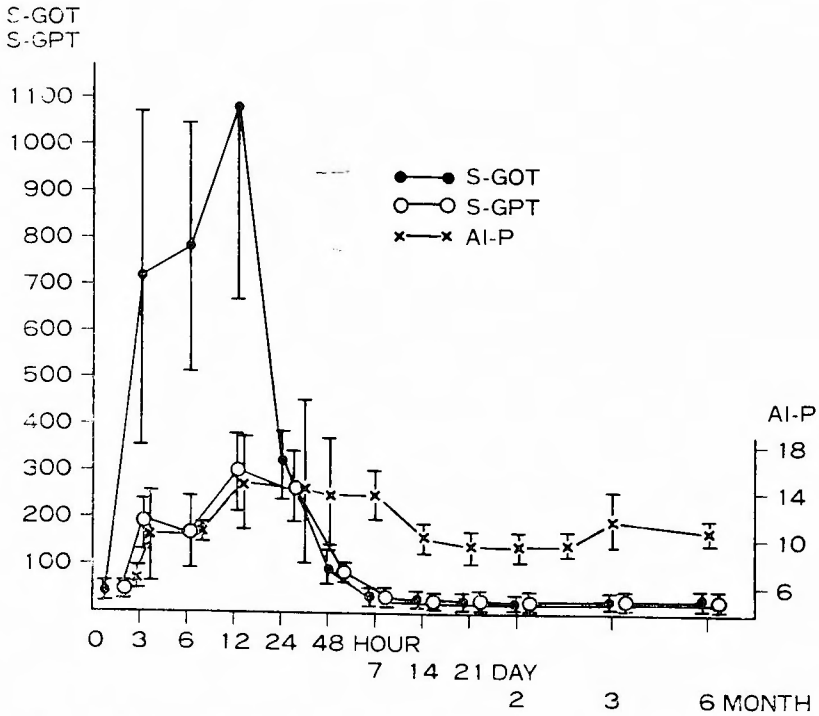

Fig 8. Changes in serum activities of GOT, GPT and Al-p after partial hepatectomy in rabbits by microwave coagulator. (Mean±SD)

Fig 9. The margin of the liver on the 7th postoperative day. The layer is sharply demarcated from the underlying parenchyma which has a normal appearance.

(Fig. 9) and covered with omentum. This necrotic layer was totally different from the underlying parenchyma which appeared congested. On the 7th and 14th postoperative day, the resected liver stump was covered with granulation and the necrotic area was firmly encapsulated. The liver was still congested. On the 60th postoperative day, congestion of the liver subsides. A small necrotic area still remained and the stump was covered with granulation tissue and omentum, and no abscess formation was found.

Microscopical findings

The histology showed destruction of the hepatic tissue a few days after operation. It was alleviated on the 3rd postoperative day. Fibroblasts appeared on the 3rd postoperative day and connective tissue began to proliferate on the 7th postoperative day, increasing its intensity as time elapsed (Fig. 10). Hepatocytes were edematously swollen and vacuoles appeared up to 21 postoperative days, but these vacuoles disappeared within 60 postoperative days and hepatocytes returned to normal size. By the 90th or 180th postoperative day, the margin of the liver was covered with connective tissue in most cases, and no abscess formation was visible. The liver lobes which was not resected showed nearly normal configurations of the liver structure, frequent mitoses of hepatocyte, and no appearance of small round cells on the Glisson's part throughout the postoperative course.

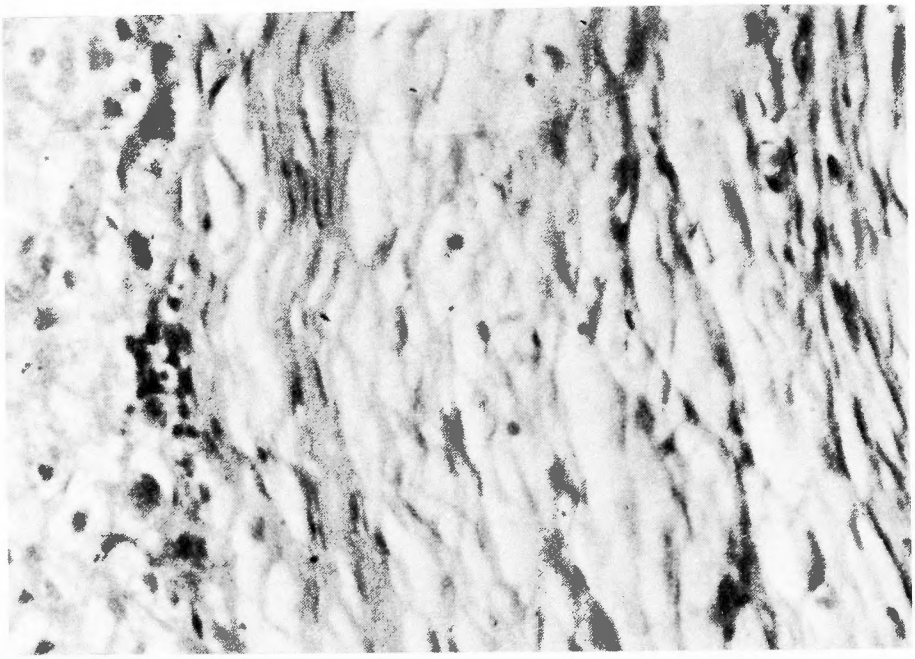

Fig 10. On 7th postoperative day Microscopical appearance of the margin of the liver. The margin of the liver is covered with connective tissue. Hematoxylin-eosin stain ; original magnification ×140.

Liver weight :

The mean weight of hepatic remnants was seen to be only a percentage of the calculated preoperative liver weight. Regeneration of the remainng liver rapidly occurred after hepatectomy and the mean liver weights of two groups of three rabbits killed on the 21st and 180th postoperative day were 135 and 143 percent respectively. These data coincide with 35 percent increase of the mean body weight during the observation periods.

Discussion

At present, hepatic lobectomies are often reported in literature and hepatic surgery has emerged to become an important part of general surgery.

Despite the control of hepatic hilar vessels[16)18)] and resection along anatomic planes[6)], bleeding from the raw liver surface may considerable. Many methods have been devised to solve this problem, such as the clamp[14)] and suture technic, fingerfracture resection[10)], deep parenchymal mattress sutures, application of hemostatic agents, and tissue adhessives. Mattress suture has been the most widely used technic[17)]. When the sutures are done too tightly, the hepatic parenchyma will be strangulated, when done too loosely, postoperative bleeding or bile peritonitis will be inevitable. Furthermore, the peripheral tissue from the suture line might be devitalized as a result of circulatory disturbance. On the other hand, the resected liver stump by finger fracture technic can be expected to heal better and

with few complications. Packing of the liver stump with omentum has been abandoned because of the high risk of infection[20]. Intermitttent occlusion of the porta hepatis combined with hypothermia[12], has been recommended in difficult situations, and the use of caval tourniquets[5], numerous hemoclips[3], and a special liver clamp has been recommended. More recent technics included the promising use of electrosurgical scalpel[9], laser radiation[7], cryosurgery[8] and plasma scalpel[11] to control hepatic bleeding.

Hence, the difficulties encountered in controlling the oozing of blood and bile from the liver parenchyma are reflected in the number of different methods suggested and in the universal recommendation of postoperative drainage.

In the present series, a large number of liver lobes were resected with the use of microwave coagulator and a surgical knife. Transection was carried out in different planes with a very small amount of blood loss. After the resection, the surface was dry without blood or bile leak. With the present technic, no foreign material was employed. Vessels up to 3 mm in diamiter were safely coagulated. If some of the intermediate-sized vessels were injured they could usually be identified, and easily coagulated with the microwave coagulator.

No infection was encountered in the present series except in one case. The resected area was completely sterile at the time of surgery due to the high temperature created by the microwave. The coagulated crust is not only a very poor environment for bacterial proliferation but also a shield against bacterial invasion to the liver substance although it leaves a broad zone of coagulated parenchyma along the liver stump. The coagulated area was covered by a firm crust instead of soft necrotic tissue. It is thought that this method is better performed by means of no carbonization rather than electrosurgical, plasma, and laser scalpel of which the crust may be torn slightly.

The coagulated necrotic area was sharply demarcated from the underlying parenchyma, which showed congested findings by macroscopical and microscopical examinations. Furthermore, these results were in accord with those of temperature measurements.

The microwave irradiated from the antenna penetrates into the tissue and attenuates exponentially ; $I = Io\ e^{-\mu x}$ Here Io is the power density of the absorbed energy around the antenna, and I is the density at distance x. μ is a constant which characterizes the attenuation rate for a particular tissue at a particular frequency. I drop off rapidly at the longer distance beyond x. In the liver tissue, I reduces to zero within 3 cm to 4 cm from the antenna at 50 W/cm^2. The present results showed a transient increase after operation in the activities of SGOT, SGPT and Al-p, and the safety of this procedure in rabbits is reflected by the histological changes. Also, circulatory shock or systemic adversed effects could not be observed in rabbits after operating. A question is raised as to whether the coagulated tissue remaining in a living body for a long time would become a hepatic antigen. However infiltration of inflammatory small round cells was not observed in Glisson's sheathes and activities of SGOT, SGPT and Al-p did not increase on and after the 7th postoperative day in all the rabbits. These results suggest that autoimmunological damage of liver cells, and systemic adverse effects may not be induced by proper coagulation-

necrosis of the liver tissue by the microwave.

Four kinds of high-energy scalpels are currently available : laser scalpels, a plasma scalpel, electrosurgical scalpels, and microwave coagulators[10)16)]. With all these instruments however, effectiveness is proportional to damage : it will be emphasized that one cannot produce an effective high energy scalpel that will not damage tissue. Therefore these kinds of scalpels may be useful if they are safe, easy to use, not outrageously expensive, and soundly effective. In these respects, I believe that this microwave coagulator is superior to other especially in hepatic resection, though I have not yet done a direct comparison with laser scalpels, a plasma scalpel, and electrosurgical scalpels.

The procedure in hepatic resection divided by OHSAKA is lack in practicality for clinial challenges. This study including long-term observations, shows that partial hepatectomy using my newly devised, microwave coagulator can be carried out simply and safely with minimal hemorrhage without bile leakage and other complications, and with a sound healing.

Conclusion

As a preliminary experiment, the relationship between the forward power of microwave radiation and the time of coagulation withouh carbonization of albumen was defined. Then, the suitable condition could be chosen.

Partial resection of fifty-two liver lobes was performed on twenty-six rabbits. These rabbits were investigated from various points of view. The results were as follows ; 1) Complete control of bleeding or bile leakage. 2) Autopsy performed one day to six months postoperatively revealed satisfactory healing without infection in all animals expect one. 3) Portoangiography indicated that veins up to 3 mm in diameter could be sealed. 4) The temperature measurements showed that the extent of thermal damage caused by microwave energy might be less than 10 mm wide from the center of the coagulated tissue. 5) Chemical analysis and histological observation indicated that damage of liver cells was transient and systemic adverse effects might not be indused by proper coagulation-necrosis of the liver tissue by the microwave.

Acknowledgment

Grateful acknowledgment is made to Prof. M. KATUMI, M.D. and his collaborators for their constant guidance in this investigation. Thanks are also due to the president, T. SENTANI, and engineers of Heiwa Electronic Industrial Co., LTD for providing the apparatus. This investigation was supported, in part, by a grant from the Education Ministry of Japan towards Research in Scientific Development.

References

1) Ackroyd FW, Pollard, et al : Massive hepatic resection in the treatment of severe liver trauma. Am J Surg **117** : 442-448, 1969.
2) Cater DB, Silver IA et al : Combined therapy with 220 kv roentgen and 10 cm microwave heating in rat hepatoma. Acta Radiol Ther Phys Biol **2** : 321-330, 1964.
3) Clark WR and Leather RP: Hemostasis during liver resections. Surgery **67** : 556-557, 1970.

4) Copeland ES and Michaelson SM : Effect of selective tumor heating on the localization of ^{131}I fibrinogen in the Waker carcinoma 256. Acta Radiol Ther Phys Biol **9** : 323-339, 1970.
5) Gentile JM and MacLean LD Improved technic for human hepatic resection. Am J Surg **117** : 424-425, 1969.
6) Goldsmith NA and Woodburn RT : The surgical anatomy pertaining to liver resection. Surg Gynec Obstet **105** : 30-35, 1957.
7) Hall RR, Beach AD et al : Partial heaptectomy using a carbon-dioxide laser. Brit J Surg **60** : 141-144, 1973.
8) Healey WV, Prieble CJ Jr et al: Hepatic cryosurgery. Arch Surg **103**: 384-392, 1971.
9) Kluge TH and Ullal SR : Electrosurgery in resections of the liver, an experimental study. Am J Surg **122** : 792-796, 1971.
10) Koshugi S, Takakura K et al : A technique of tissue coagulation by microwave. Iyodenshi to Seitaikogaku (Japan) **11** : 16-23, 1972.
11) Lin TY, Chen KM et al : Total right hepatic lobectomy for primary hepatoma. Surgery **48** : 1048-1060, 1960.
12) Link WJ, Incropera FP et al :A plasma scalple, comparison of tissue damage and wound healing with electrosurgical scalpel and steel scalpel. Arch Surg **111** : 392-397, 1976.
13) Longmire WP Jr and Marable SA . Clinical experiences with major hepatic resections. Ann Surg **154** : 460-468, 1961.
14) McLees BS and Finch ED: Analysis of reported physiologic effects of microwave radiation. Advan Biol Med Phys **14** : 163-226, 1973.
15) Nakayama K : Simplified hepatectomy. Brit J Surg **45** : 645-649, 1957.
16) Ohsaka A: Surgical application of microwave. Surg Diag Treat **14** : 920-927, 1972 (Japan)
17) Owen MP, Wolfman EF et al : The management of liver trauma. Arch Surg **103** : 211-215, 1971.
18) Pack GT and Backer HW : Total right hepatic lobectomy. Ann Surg **138** : 253-258, 1953.
19) Pack GT and Islami AH : Recent result in cancer researh, Tumors of the liver. Springer Verlag New York, 1970.
20) Quattlebaum JK : Massive resecton of the liver. Ann Surg **138** : 788-796, 1953.
21) Schwan H p : Biophysics of Diathermy. pp. 55-115, Warerly Baltimore Maryland 1958.
22) Trinker MB Jr: Resection of the liver, JAMA **112** : 2006-2009, 1939.

和文抄録

マイクロ波組織凝固装置による新しい肝切除術

和歌山県立医科大学消化器外科学教室（主任：勝見正治教授）
田　伏　克　惇

実質性臓器，特に肝切除術は，現在も尚，一般に外科的に近づき難い存在にあり，手術手技として，術中術後の肝切断面よりの出血及び胆汁漏出が重要な問題である．ところで，マイクロ波は，従来より理学的療法としてのみ医療に用いられてきたが，著者は，本波の有する熱エネルギーに着目し，これをできる限り，小領域に集中せしめることによって，組織を凝固せしめ得る装置を試作し，これを用い，実験的に肝切除を行ない，次のような成績を得た．

(1)，卵白凝固実験により，本装置のアンテナの種類による出力と発振時間の相互関係が求められ，使用条件の撰択が可能となった．

(2)　家兎肝において，肝実質面及び最大径 2.5～3 mm 大の血管でも十分止血され，再開通しないことが認められた．

(3)　肝組織の温度的影響は，アンテナ中心より10 mm までの範囲であった．

(4)　切除断端において，凝固壊死の残存が長期にわたり続くが，感染もなく経過し，脱落することが無い為，後出血もなく胆汁漏出も認められなかった．

(5)　術後早期の一過性の血清 GOT, GPT, Al-P の上昇を認めたが，24時間後には回復に向い，以後肝障害の危惧は考えられなかった．又6カ月間の観察で，本法に特異な合併症及び全身的影響も認められなかった．

以上の成績より本装置及びこれを用いた肝切除法は，十分実用性があり，臨床応用も可能であると考えられる．