Arch Jap Chir 48 (3), 289~296, Mai, 1979

Reconstruction of Mitral Valve with Regurgitation due to Ruptured Chordae Tendineae of Anterior Leaflet

SHIGEHITO MIKI, NORIKAZU TATSUTA, YUTAKA KONISHI, MITSUHIKO MATSUDA, HIROSHI ISHIHARA, TEIICHI TANIGUCHI, YOSHISADA SHIRAISHI, KATSUHIKO MATSUDA, SHINJI MURATA, KATSUHIKO MURATA, YUKIO CHIBA, CHIN-TZER KAO and YORINORI HIKASA

The 2nd Department of Surgery, Faculty of Medicine, Kyoto University
(Director : Prof Dr. YORINORI HIKASA)

KAZUAKI MINAMI
The 2nd Department of Surgery, Shiga Medical College
(Director : Prof. Dr. YOSHIO OKADA)

KEITA SUEKANE
Department of Anestegiology, Faculty of Medicine, Kinki University
Received for Publication Feb. 26, 1979.

The decision to treat mitral regurgitation due to ruptured chordae tendineae surgically is reached on the basis for the extent of the valvular segment that has lost chordal support, pliability of the leaflet tissue and the condition of the subvalvular apparatus. There seems to be wide agreement on the feasibility of valvuloplastic surgery for mitral regurgitation due to ruptured chordae tendineae of the posterior leaflet and our experience also shows a high rate of success of plastic repair[10].

On the other hand, mitral regurgitation due to rupture of the chordae tendineae attached to the anterior leaflet varies greatly in severity, and the method of surgery should be selected cautiouly according to the anatomical alterations. Here we reviewed our experience with surgery on the mitral apparatus with ruptured chordae tendineae of the anterior leaflet and present our indications for reparative surgery of this lesion.

Clinical Materials

Eleven patients were treated with mitral valve surgery for ruptured chordae tendineae of the anterior leaflet. Their ages ranged from 25 to 63 years. Five were male and six female. These patients are divided into two groups according to the operative produre.

Group I consists of five patients who had mitral valve replacement (Table 1). A

Key words : Mitral regurgitation, Ruptured chordae tendineae, Anterior Leaflet, Valvulo-and Annuloplasty, Carpentier ring.
索引語：僧帽弁閉鎖不全，腱索断裂，前尖，弁及び弁輪形成術，Carpentier 環，
Abstract of this paper was read at the VIII World Congress of Cardiology, Tokyo, Sept. 17-23, 1978.
Present address : Dr SHIGEHITO MIKI ; 1655-61, 5-Tezukayama, Nara, 631, Japan.

Table 1.

Patients with ruptured chordae tendineae of the anterior leaflet
Group I MVR as procedure of choice

Patient	E.M	K.H.	M.N.	K.T.	M.K
Age	25	25	51	28	30
Sex	m	f	m	f	m
Chief Complaint	Easy fatiguability	Palpitation	Orthopnea	Palpitation Dyspnea	Easy fatiguability
CTR %	56	59	71	67	68
ECG	RSR, LVH, LAH	AF, LVH, LAH	RSR, LVH	AF, LVH	RSR, LVH
Pp/Ps	40/104	30/110	67/126	58/96	42/104
PC(m) mmHg	14	15	32	26	22
PC(v) mmHg	45	21	58	30	39
C. I.	3.42	3.93	1.39	1.90	2.23
Grode of MR	4+	3+	Not performed	3+	4+
NYHA	II	III	IV	III	II
Etiology	B.E.	R.h.d	Ischemic h.d	R.h.d.	R.h.d.
Site of rupture (3)	Para Med.Chord ant., post.	Para Med. Chord ant, post.	Para Comm.Chord Main Chord Para Med Chord posterior	Para Comm.Chord Post.	Para Comm.Chord ant., post.
Remarks	S-E D 4M AVR (S-E B 10A) Alive	S-E B 3M Alive	S-E B 3M Sudden onset Died	L-K 22M Alive	L-K 22M AVR (L-K 18A) Alive

S-E D : Starr-Edwards disc valve
S-E B Starr-Edwards ball valve
L-K Lillehei-Kaster pivoting disc valve

Table 1

Table 2.

Patients with ruptured chordae tendineae of the anterior leaflet
Group II Reparative Surgery as procedure of choice

Patient	E.W.	K.M.	J.W.	S.I.	N.O.	A.U
Age	46	63	46	41	28	37
Sex	f	f	m	f	f	m
Chief Complaint	Orthopnea	Orthopnea	Dyspnea	Dyspnea	Easy Fatiguabil	Palpitation on Exertion
CTR %	67	66	59	56	50	54
ECG	RSR, LVH	AE, LVH, LAH	AF, LVH, LAH	RSR, LVH, LAH	RSR, LVH, LAH	AF, LVH
Pp/Ps	80/136	37/134	54/100	72/100	28/104	31/125
PC(m) mmHg	32	17	22	28	14	13
PC(v) mmHg	59	24	48	78	19	20
C.I	2.33	1.60	4.70	3.00	4.18	2.92
Grade of MR	4+	4+	4+	4+	3+	4+
NYHA	II	III	III	IV	II	II
Etiology	Luetic ?	Idiopathic	Idiopathic	Idiopathic	Idiopathic	B.E.
Site of rupture (3)	Para Comm. Chord post	Main Chord anterior	Para Comm Chord. ant.	Para Comm. Chord. ant.	Para Comm. Chord. post.	Para Comm Chord post Cleft chord posterior
Procedures performed	MVR (S-E B 3M) TAP	MVR (S-E B 4M)		MVR (S-E B 3M)	Suture of cleft in the mural leaflet	
Remarks	Sudden onset Alive Paravalv. leak.	Died of LOS	Sudden onset residual MR 2+	Sudden onset Died of Bleeding	Alive residual MR 2+	Alive residual MR 1+

Table 2

history of rheumatic fever was elicited in three patients (K.H., K.T. and K.M.), of bacterial endocarditis in one (E.M.) and of ischemic heart disease in one (M.N.). In three patients (E.M., K.H. and K.T.), the excised mitral valve was deformed with rigid,

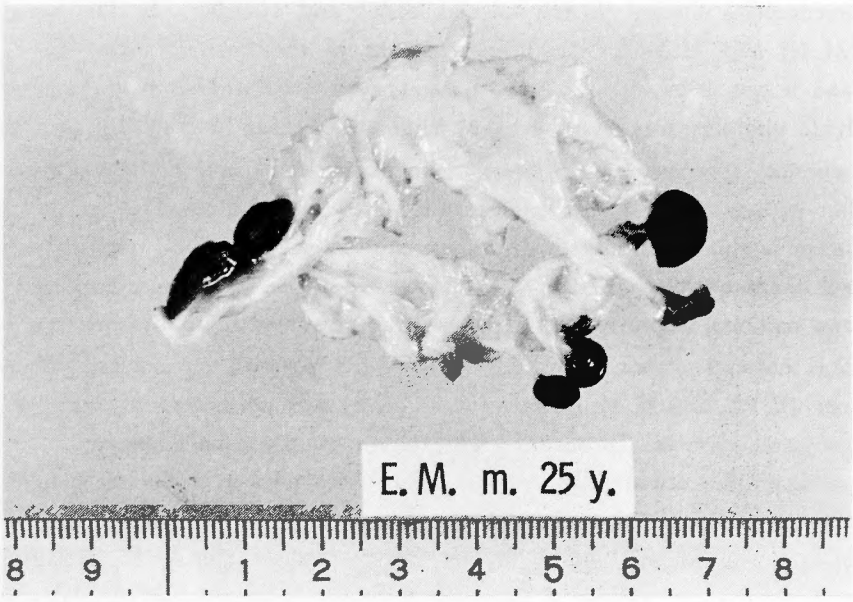

Fig. 1. Excised mitral valve of patient E. M..

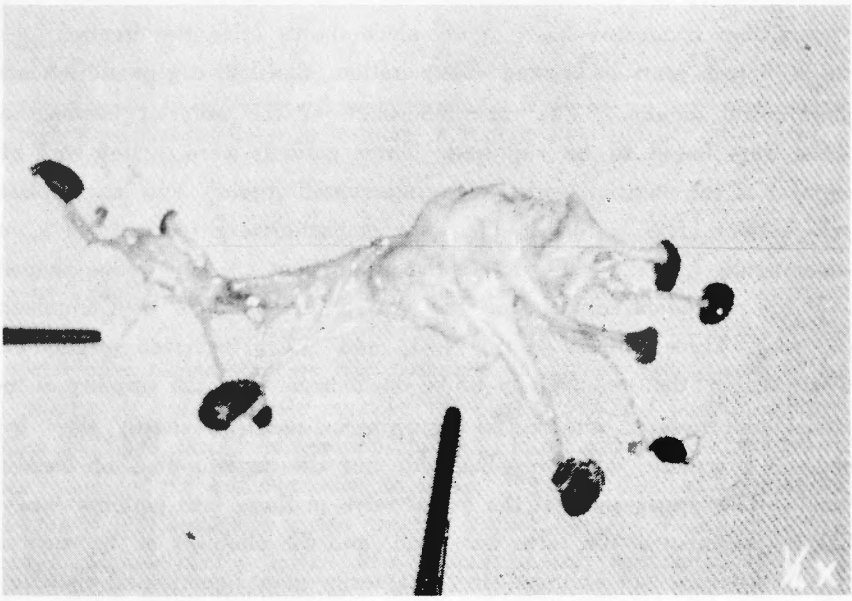

Fig. 2. Excised mitral valve of patient M. K..

nodurally thickened orifices and with thickened, fused and shortened chordae. Rupture of the chordae was found at the mid-portion of the valvular orifice, the para medial chordae of Carpentier et al[3]., in two patients (E. M. and K. H.) with thickened and rounded edges (Fig. 1) and at the posterior commissural region, the para commissural chordae[3], in one (K. T.). In these patients, rupture of the chordae was probably secon-

dary to degenerative change in the valvular leaflet and chordae. In the remaining two patients (M.N. and M.K.), the broad segment of the anterior leaflet had lost chordal support, and it was clear that reparative surgery was not feasible. In the excised valve of patient M.N., pliability was preserved with slight thickening in the orifice area. Almost all of the chordae attached to the posterior commissure of the anterior leaflet were ruptured. In the other patient (M.K.), the excised mitral valve was thin except for the mid-region of the anterior leaflet. Deformity of the intact chordae seemed to be very slight. The para commissural chordae[3] of the anterior and posterior commissures were ruptured (Fig. 2). In these two patients, rupture of the chordae was presumed to be the primary lesion.

Group II consists of six patients who were treated with valvuloplasty (Table 2). In two patients (E.W. and K.M.) simple annuloplasty was performed at both the anterior and posterior commissures. However, regurgitation could not be eliminated, so prosthetic valves were inserted. Patient E.W. was in good health until a productive cough developed suddenly three years prior to operation. Since then, a cardiac murmur had been noted. The mitral valve was pliable with a dilated mitral annulus. There was a flail segment in the posterior commissural region of the anterior leaflet due to loss of chordal support. The site of rupture was the para commissural chordae[3]. If this flail segment could be plicated by annuloplasty, regurgitation might be suppressed to a minimum. Patient K.M. had a history of persistent congestive heart failure since shortly after the ligation of a patent ductus arteriosus two years before mitral exploration. She had a gigantic left atrium with widely dilated mitral annulus. The main chordae[3] of the anterior commissure of the anterior leaflet were found to be ruptured. Three patients were treated with plication of the flail segment of the anterior leaflet with interrupted stitches and annuloplasty at both commissures (patient. J.W.), or at the anterior commissure (patient S.I.), or at the posterior commissure (patient N.O.). In the last patient (A.U.) wedge-shaped excision and repair of the redundant segment of the leaflet was combined with annuloplasty with a Carpentier ring. Three patients (J.W., N.O. and A.U.) survived surgery, but in one (S.I.) the sutures of the annuloplasty broke down because of the fragility of the annular and left atrial wall tissure, and mitral regurgitation recurred shortly after bypass was discontinued. A prosthetic valve was inserted, but the patient died of bleeding on the operating table. The appearance of the mitral valve in these four patients was somewhat similar. The fail segment of the valve was small, and the pliability of the valve leaflet was well preserved. Rupture had occurred in the anterior para commissural chordae[3] in two patients (J.W. and S.I.), and in the posterior para commissural chordae[3] in two (N.O. and A.U.). Patient A.U. had an additional rupture of the cleft chordae in the posterior leaflet, the redundant segment of which was excised in the same manner as the anterior leaflet. Postoperative echocardiography of the three suriving patients showed improvement with a decrease in the diastolic descending ratio and in the left atrial diameter, and postoperative left ventriculograms revealed residual mitral regurgitation of grade 1 to 2 plus with decrease in left atrial size (Fig. 3).

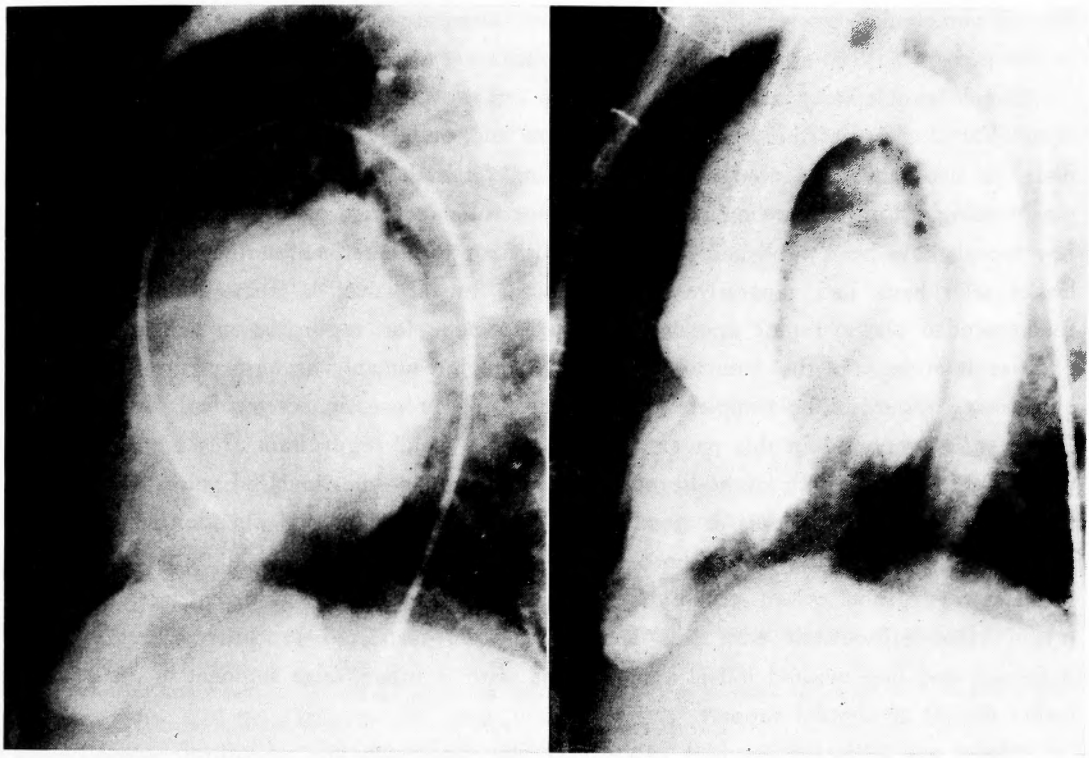

Fig. 3. Lateral view of left ventriculogram of patient N. O. before (left) and after (right) operation showing decrease in grade of regurgitation and left atrial size.

Discussion

Our experience with reconstruction of the anterior leaflet of the mitral valve with regurgitation due to ruptured chordae tendineae has been described. Three of five patients who had mitral valve replacement as the procedure of choice had deformed, rigid valves and fused, thickened and shortened chordae. The other two had pliable leaflet tissue with a broad area of valve devoid of chordal support. In six patients, reparative mitral valve surgery was attempted ; it was successful in three. These patients had pliable leaflet tissue with small area of flail segments in the anterior leaflet.

Reparative surgery of the mitral valve apparatus with regurgitation due to ruptured chordae tendineae includes reconstruction of the ruptured chordae and plastic repair of the mitral valve and annulus. In the reconstruction of the chordae, direct reattachment of the ruptured end to the papillary muscle[2)7)] or substitution with autologous pericardium[18)], Teflon fabric[12)], and suture materials[6)7)12)20)] have been employed. In these reports, however, reconstruction of the chordae of the anterior leaflet is mentioned only a few cases[2)7)18)]. There is an assumption that with chordal substitute, shrinkage of the left ventricular cavity might lead to redundancy of new chordae with eversion of the leaflet into the left atrium and recurrent insufficiency and potential thrombogenic materials were inserted in

the left ventricular cavity[4]. The authors did not attempt reconstruction of ruptured chordae in the present series, since none of the patients were good candidates for the procedure.

Simple annuloplasty at both commissures in two patients did not eliminate regurgitation. Valvuloplasty of the everting segment of the leaflet combined with standard annuloplasty in two cases and wedge-shaped excision of the redundant tissue along with annuloplasty using a Carpentier ring in one case gave satisfactory results in this series. Only a few reports have been published of patients with ruptured chordae tendineae of the anterior leaflet who have had reparative surgery of the mitral valve[4)8]. Some authors who have recommended plastic repair employ valve replacement for regurgitation due to ruptured chordae tendineae of the anterior leaflet[5)14)15)19)21], presumably because of the difficulty of eliminating regurgitation completely and the fear of progression of residual regurgitation. However, as reported in this paper, patients with a small regurgitant area are apt to have pliable leaflet tissue with slight fibrous thickening around the involved valve segment and this slight thickening affords a good base for securing stitches of plication which approximate the neighboring intact chordae. Annuloplasty combined with the above procedure reduced regurgition to an acceptably small grade. The authors think that candidates for mitral valve replacement with this entity should be restricted to those patients with a deformed and degenerated mitral appartus and with a broad valve segment of the anterior leaflet devoid of chordal support.

There are different opinions concerning the long term fate of mitral reconstructive surgery. Pakrashi et al. analysed their 89 survivors of mitral annuloplasty and found that clinical improvement was maintained for up to 14 years, further corroborating the beneficial effect of annuloplasty[15]. Reed reported that 80 per cent of the patients who had undergone his mitral annuloplasty showed good to excellent results for up to 7 years[17]. Oury et al. obtained excellent results with annuloplasty using the Carpentier ring[13]. On the contrary, initial good results were maintained for up to 4 years in only 16 of 29 patients treated with mitral annuloplasty by Penther et al., who concluded that the indication for annuloplasty were few, primarily mitral insufficincy without obvious cardiac enlargement, with normal sinus rhythm and with only a recent history of congestive heart failure.[16] Angel stated that 50 per cent of patients who had had mitral annuloplasty for anterior leaflet lesions returned with very significant recurrent murmurs[1] The survivors in the present series have a slight degree of residual mitral regurgtation, and this requires cautious follow up. Our experience with valvuloplastic surgery for congenital mitral regurgitation may afford some illumination on this problem. In a long term lollow up of 29 cases, those patients with less than 2 plus residual mitral regurgitation have not shown any incrased severity, and they have continued in a stable condition for at least 8 years[11].

Conclusion

Experience with surgery of the mitral valve apparatus with ruptured chordae tendineae of the anterior leaflet has been reviewed from the view point of feasibility of reconstuctive

surgery. Simple annuloplasty could not eliminate regurgitation. Plication of the flail segment of the anterior leaflet combined with annulopasty in two cases and wedge-shaped resection and repair of the flail segment of the valve combined with annulopasty using the Carpentier ring in one case reduced regurgitation to an acceptably small grade. Plastic repair of mitral valve with regurgitation due to ruptured chordae tendineae of the anterior leaflet is feasible when the site of the rupture is eccentric and the number of ruptured chordae is small and the leaflet tissue is pliable.

References

1) Angel WW Discussion in 14.
2) Barratt-Boyes BG : Surgical correction of mitral incompetence resulting from bacterial endocarditis. Brit Heart J **25** : 415-420, 1963.
3) Carpentier A, Guerinon J, et al : Pathology of the mitral valve. In the Mitral Valve. A Pluridisciplinary Approach edited by Kalmanson K, Edward Arnold Ltd London, 1976, p. 65.
4) Ellis FH, Frye RH, et al : Results of reconstructive operation for mitral insufficency due to ruptured chordae tendineae. Surgery **59** 165-172, 1966.
5) Gerbode F, Hill JD, et al : Surgical correction of mitral insufficiency due to ruptured chordae tendineae. Circulation 37 and 38, suppl **1** : 119-123, 1968.
6) January LE, Fisher JM, et al : Mitral insufficiency resulting from rupture of normal chordae tendineae. Report of a surgically corrected case. Circulation **26** : 1329-1333, 1962.
7) Kay JH and Egerton WS : The repair of mitral insufficiency associated with ruptured chordae tendineae. Ann Surg **157** : 351-360, 1963.
8) McGoon DC : Repair of mitral insufficiency due to ruptured chordae tendineae. J Thoracic Cardiovasc Surg **39** 357-362, 1960.
9) Menges Jr. H, Ankeney JL, et al : The clinical diagnosis and surgical management of ruptured mitral chordae tendineae. Circulation **30** : 8-16, 1964.
10) Miki S, Tatemichi K, et al : Mitral regurgitation due to ruptured chordae tendineae…… Surgcal technique from the view point of site of rupture. J Jap Assoc Thorac Surg **24** : 594-595, 1976. (In Japanese)
11) Miki S, Tatsuta N, et al : Valvuloplastic surgery and late results of congenital mitral insufficiency. Proceedings of the International Congress of Cardiovascular Surgery Organized by the 'M. E. Debakey' International Cardiovascular Society edited by Balas P and Chavatzas D Athens Greece, 1977 p. 129-135.
12) Morris JD, Penner DA et al : Surgical correction of ruptured chordae tendineae. J Thoracic Cardiovasc Surg **48** : 772-780, 1964.
13) Oury JH, Folkerth TL, et al : Indications and late results of reconstructive mitral surgery… hemodynamic evaluation of the Carpentier ring. In the Mitral Valve. A Pluridisciplinary Approach. edited by Kalmanson D, London, Edward Arnold Ltd 1976 p. 541.
14) Oury JH, Peterson KL, et al : Mitral valve replacement versus reconstruction. An analysis of indications and results of mitral valve procedures in a consecutive series of 80 patients. J Thoracic Cardiovasc Surg **73** : 825-835, 1977.
15) Pakrashi BC, Mary DA et al : Clinical and hemodynamic results of mitral annuloplasty. Brit Heart J **36** : 768-780, 1974.
16) Penther P, Bourdarias JP et al : Long-term Prognosis after mitral annuloplasty for acquired mitral insufficiency. Clinical evaluation. Brit Heart J **32** : 427-435, 1970.
17) Reed GE : Surgical treatment of valvular heart disease. Part IV. Mitral valve surgery. A brief for closed valvuloplasty and repair in preference to prosthetic replacement. Amer Heart J **76** : 432-434, 1968.
18) Rittenhouse EA, Davis CC, et al : Replacement of ruptured chordae tendineae of the mitral valve with autologous pericardial chordae. J Thoracic Cardiovasc Surg **75** 870-876, 1978.
19) Roberts WC, Braunwald E et al : Acute severe mitral regurgitation secondary to ruptured

chordae tendineae. Clinical hemodynamic and pathologic considerations. Circulation **33** : 58-70, 1966.
20) Sanders CA, Scannel JG, et al : Severe mitral regurgitation due to ruptured chordae tendineae. Circulation **31** : 506-516, 1965.
21) Selzer A, Kelly JJ, et al : Immediate and long range results of valvuloplasty for mitral regurgitation due to ruptured chordae tendineae. Circulation **45** and **46**, suppl **1** 52-56, 1972.

和文抄録

前尖腱索断裂による僧帽弁閉鎖不全症に対する弁形成術

京都大学医学部外科学教室第2講座
三木 成仁，龍田 憲和，小西 裕，松田 光彦
石原 浩，谷口 亨一，白石 義定，松田 捷彦
村田 真司，村田 雄彦，千葉 幸夫，高 欽澤
日笠 頼則

滋賀医科大学外科学教室第2講座
南 一 明

近畿大学医学部麻酔学教室
末 包 慶 太

腱索断裂による僧帽弁閉鎖不全症のうち，後尖腱索断裂によるものは弁形成術で対処出来る症例が多いことは諸家の指摘するところであり，著者らの成績もこれを支持しているが，前尖腱索断裂によるものについては弁置換術を選ぶという報告が多い．しかし，腱索断裂症例の弁尖の中には，柔軟で，肥厚軽度であり，切除するのに躊躇する場合もある．そこで，前尖腱索断裂による僧帽弁閉鎖不全症の自験例11例を対象として弁形成術の適応を検討した．

患者の年令は25才から63才．男性5例，女性6例．5例に弁置換術を，6例に弁形成術を第一選択とした．弁置換術を第一選択とした症例のうち3例の僧帽弁は，変形高度で，硬化，結節状肥厚を示して可動性は著しく障害されるており，腱索は硬化，癒合，短縮していた．他の2例では弁尖は薄く，可動性はよく保たれていたが，腱索断裂の範囲が広く，弁形成術を考慮する余地はなかった．弁形成術を第一選択とした症例のうち，Para commissural chordae に断裂のあった1例と，main chordae に断裂のあった1例，計2例に両交連部で弁輪縫縮術のみを行ったが逆流軽減せず弁置換術に切換えた．また，Para commissural chordae に断裂のあった3例に対して，腱索断裂部の弁尖を縫縮したのち，弁輪縫縮術を行ったところ，2例で逆流を制禦出来たが，弁輪及び左房組織の脆弱であった1例では縫縮部が裂開したので急拠人工弁置換に切換えたが失った．前尖の Para commissural chordae と後尖の cleft chordae に断裂のあった1例では断裂腱索附着弁尖部を切除，縫合したのち，Carpentier ring を用いて弁輪縫縮術を行い逆流を制御出来た．弁形成術生存例3例の術後エコー図では左房径が減少しており，術後左室造影では(+)乃至(++)の遺残逆流を認めるが安定している．

前尖腱索断裂症例のうち，断裂部位が Para commissural chordae の領域に限局して，その数が少く，弁尖の肥厚軽度で柔軟な症例では弁形成術で対処出来る余地が残されており，術式としては断裂腱索附着弁尖部を縫縮又は切除縫合したのち，弁輪縫縮術を併用する方法により逆流を制御可能である．