

Studies on Surgical Adjuvant Chemotherapy for Colorectal Cancer and Administration of Neocarzinostatin into the Lumen of the Colon or Rectum using a Double Balloon Catheter and Iontophoresis

SHINJI AKAO

The 2nd Surgical Division, Yamaguchi University School of Medicine
(Director: Prof. Dr. KOICHI ISHIGAMI)

Received for publication, Nov. 10, 1980.

Introduction

In Japan the incidence of colon cancer is lower than in western countries, but recently there is a tendency toward an increase¹⁶⁾. The 5-year survival rate after palliative surgery has increased with the advance of techniques and adjuvant chemotherapy^{1,5)}. In hope of an even more improved rate, the author investigated the effects of intramural injection and intraluminal administration of 5-FU into the isolated colon or rectum and the administration of Neocarzinostatin (NCS) into the lumen of the colon or rectum using double balloon catheter combined with iontophoresis.

Chapter 1. Fundamental investigation on several routes of 5-FU administration

Five-FU solution was given to dogs intramurally into the colon, by intraluminal administration into the isolated segment of the colon and by rapid intravenous administration. The levels of 5-FU in the peripheral blood, thoracic duct lymph, portal vein blood and several organs were determined by bioassay using the Band Culture Method^{9,27,31)} (OKUBO, in 1955) (Table 1). Blood and lymph were centrifuged at 2000 rpm for 5 minutes, and their supernatant fluids were used for the measurement. To determine 5-FU concentrations in different organs, the dogs were

Table 1. Measurement of concentrations of anticancer agents

| | |
|----------------------------------|---|
| Specimen | 1. Organs are resected 2. Saline solution or PBS is added 3. Organs are homogenized and extracted at 4°C for 24 hours |
| Method of measurement | Band culture method |
| Anticancer agent | 5-FU |
| Strain of test organism | St. aureus 209-P |
| Medium | M-H medium |
| Incubation at 37°C | 24 hours |
| Minimum inhibition concentration | 0.025 mcg/ml |

Key words: Neocarzinostatin, 5-FU, Adjuvant chemotherapy, Colorectal cancer, Double balloon catheter.

索引語: ネオカルチノスタチン, 5-FU, 手術合併化学療法, 結腸直腸癌, 二重バルーン付きカテーテル.

Present address: Department of Surgery, Ube Kosan Central Hospital, Kiwa, Ube City, Yamaguchi, 755-01 Japan.

exsanguinated and the excised tissues were minced with scissors, homogenized into an emulsion and diluted with physiological saline or pH 7.2 phosphate buffer solution using double the volume of the homogenates. These homogenates were kept at 4°C for 24 hours. The resultant supernatant fluids were used for the measurement of 5-FU concentration.

(1) Intravenous administration of 5-FU

Materials and Methods: Adult mongrel dogs weighing about 7 to 10 kg were anesthetized with Ketamine chloride at a dose of 10 mg/kg i.m. and the respiration was controlled by intratracheal intubation. The abdominal cavity was opened through a midline incision and a "cut down" tube was inserted from the splenic to the portal vein. Thereafter, in the left supraclavicular region, the thoracic duct was separated and cannulated with a 21G elastic needle to collect the thoracic duct lymph. The femoral vein was also cannulated for blood collection. Five-FU solution was administered in a dose of 50 mg/kg i.v. and concentrations of this preparation in the femoral vein blood, portal vein blood and thoracic duct lymph were measured for the next 2 hours.

Results: In the femoral vein blood, 5-FU levels abruptly decreased 5 minutes after injection and the levels were reduced by one half 15 minutes later. Thereafter, the concentrations decreased gradually, but a low level was detected from 60 to 120 minutes after injection. In the portal vein blood, 5-FU levels were lower than the levels in the femoral vein blood and decreased from 5 minutes after injection and were reduced by one half 20 minutes after injection. Low levels were detected 120 minutes after injection. In the thoracic duct lymph, 5-FU levels were detected from 5 minutes after injection and reached a peak level at 15 minutes after injection. Thereafter, the concentrations abruptly decreased and low levels were detected from 60 to 120 minutes after the injection (Fig. 1). Levels of 5-FU at 120 minutes after injection were much the same in the liver and colon, but were lower in the small intestine and mesenteric lymph nodes.

(2) Intramural injection of 5-FU into the colon

Methods and Materials: Adult mongrel dogs weighing 7 to 10 kg were anesthetized as mentioned above and 5-FU was given intramurally into the colon in a dose of 50 mg/kg.

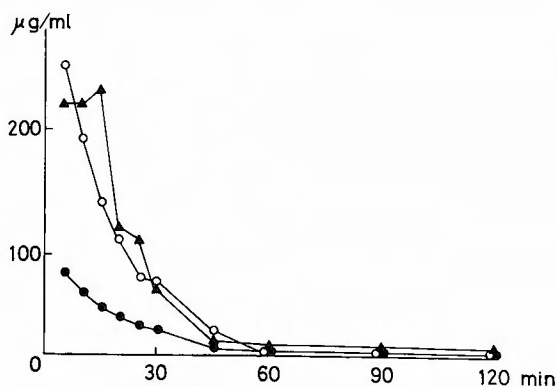


Fig. 1. Peripheral blood, portal blood and thoracic duct lymph levels of 5-FU in dogs following intravenous administration of 50 mg/kg of 5-FU
 ○-○ Peripheral venous blood, ●-● Portal blood, △-△ Thoracic duct lymph.

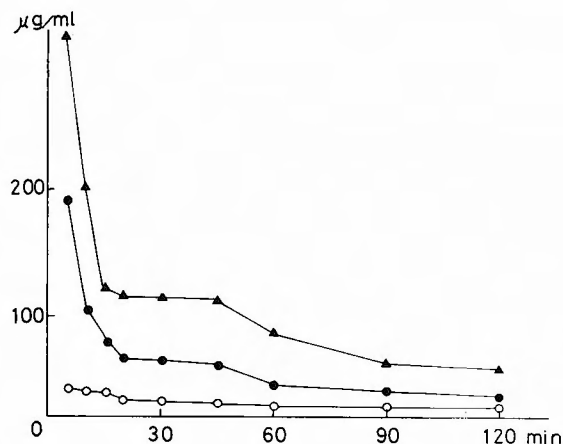


Fig. 2. Peripheral blood, portal blood and thoracic duct lymph levels of 5-FU in dogs following intramural injection of 50 mg/kg of 5-FU
 ○-○ Peripheral blood, ●-● Portal blood, ▲-▲ Thoracic duct lymph.

Results: Five-FU concentrations in the femoral vein blood were the lowest as evidenced 5 to 120 minutes after the injection. Five-FU concentrations in the portal vein blood decreased abruptly from 5 minutes after injection, were reduced by one half 10 minutes later and then gradually decreased until 120 minutes after the injection. Five-FU concentrations in the thoracic duct lymph showed the highest levels, decreased abruptly from 5 minutes after injection, were reduced by one half from 10 to 15 minutes after injection and gradually decreased until 120 minutes after injection (Fig. 2.). Among 5-FU levels in the organs at 120 minutes after the injection, there were extremely high levels in the injected portion of the colon and fairly high levels in the mesenteric lymph nodes and small intestine.

(3) Intraluminal administration of 5-FU into the colon

Materials and Methods: Adult mongrel dogs weighing about 7 to 10 kg were anesthetized as mentioned above. Five-FU solution was administered into the isolated segment of the colon in a dose of 50 mg/kg. The isolated colon segment along with the marginal vessels, measuring approximately 15 cm in length, was prepared by placing two silk sutures around the bowel and ligating them before administration of 5-FU solution.

Results: Five-FU was not detected either in the femoral vein blood or in the thoracic duct lymph. Five-FU concentrations in the portal vein blood reached a peak level 30 to 45 minutes after administration and were detected at a low level until 120 minutes after the administration (Fig. 3.). Extremely high levels were noted in the isolated colon, but the levels in the mesenteric lymph nodes, liver and small intestine were low. All these data are shown in Table 2.

Chapter 2. Intramural and intraluminal administrations of 5-FU to colorectal cancer patients

In these patients, a laparotomy was done. A "cut down" tube was inserted from the mesenteric to the portal vein to collect the portal vein blood. Peripheral venous blood and portal vein blood were taken at 5, 15 and 30 minutes after the drug administration.

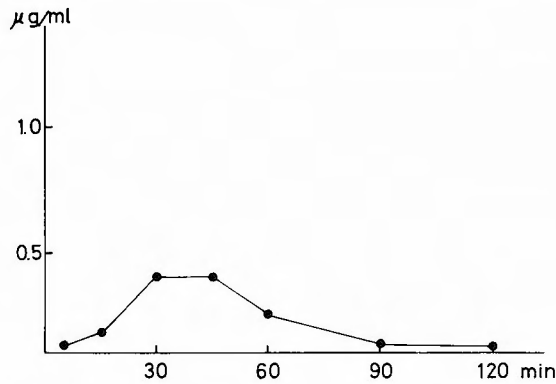


Fig. 3. Portal blood levels of 5-FU in dogs following intraluminal administration of 50 mg/kg of 5-FU

Table 2. 5-FU levels in organs 120 min after administration in dogs with thoracic duct drainage (mcg/g), Dose 50 mg/kg

| Organ | Intravenous administration | Intramural injection | Intraluminal administration |
|------------|----------------------------|----------------------|-----------------------------|
| Liver | 3.2 | 0.05 | 20.0 |
| Colon | 3.2 | 480.0 | 101.0 |
| Intestine | 0.5 | 0.05 | 27.0 |
| Lymph node | 0.8 | 1.88 | 10.0 |

(1) Intraluminal administration of 5-FU to rectal cancer patients

The tumor bearing rectum was isolated by ligating a silk suture placed around the rectosigmoid and the purse-string suture placed at the anus. Five-FU solution was given to 5 patients into the lumen of the isolated rectum in a dose of 50 mg/kg.

Results: Peripheral vein blood levels of 5-FU did not change during 5 to 30 minutes, however, the portal blood levels tended to decrease (Fig. 4.). Among 5-FU concentrations in the rectum, liver, paracolic lymph nodes, intermediate lymph nodes and metastatic liver tumor

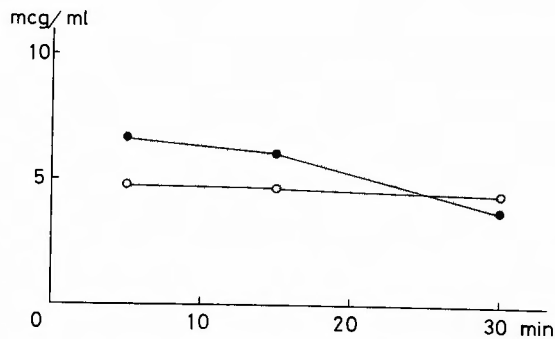


Fig. 4. Portal blood and peripheral blood levels of 5-FU after intraluminal administration of 50 mg/kg of 5-FU in rectal cancer patients
○—○ Peripheral venous blood, ●—● Portal blood.

in combined resected cases, the levels in the rectum showed the highest values. Five-FU levels in the case of rectal cancer and metastatic liver tumor were high, but they remained low in the liver and lymph nodes.

(2) Intraluminal administration of 5-FU to colon cancer patients

The tumor bearing loops of the colon were isolated by two silk sutures placed around the bowel, oral and anal to the tumor. Five-FU was injected into the lumen of this colon segment in a dose of 50 mg/kg, in six patients.

Results: Peripheral blood levels of 5-FU were nil and portal vein blood levels did not change from 5 to 15 minutes. Among 5-FU concentrations in the colon, tumor and paracolic lymph nodes, these levels in the tumor were extremely high as were the levels in the colon and lymph nodes (Fig. 5).

(3) Intramural injection of 5-FU in the colon cancer patients.

Five-FU was injected into the adjacent normal colonic wall oral and aboral to the tumor in a dose of 50 mg/kg, in two patients.

Results: Peripheral blood levels did not change from 5 to 30 minutes, but portal vein blood levels decreased abruptly from 5 minutes after the injection (Fig. 6). Five-FU concentrations were assessed in the colon, tumor, paracolic lymph nodes, intermediate lymph nodes, liver and metastatic liver tumor, and highest levels were found in the tumor. Five-FU levels in the

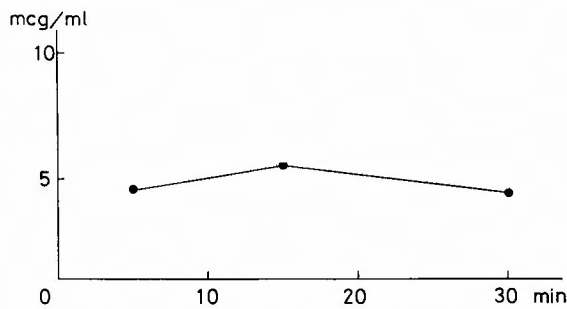


Fig. 5. Portal blood levels of 5-FU after intraluminal administration of 50 mg/kg of 5-FU in colon cancer patients

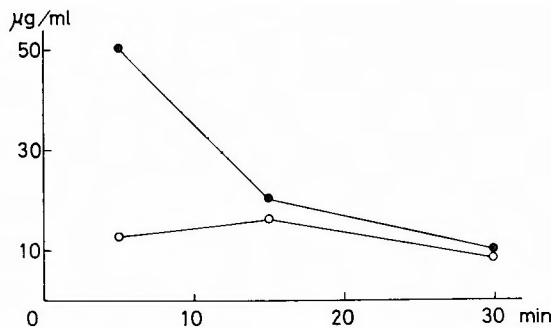


Fig. 6. Peripheral blood and portal blood levels of 5-FU after intraluminal administration of 50 mg/kg of 5-FU in rectal cancer patients

Table 3. 5-FU levels in organs after intraluminal administration and intramural injection in colorectal cancer patients (mcg/g)

| | Colon cancer | | Rectal cancer |
|-------------------|-----------------------------|----------------------|-----------------------------|
| | Intraluminal administration | Intramural injection | Intraluminal administration |
| Colon | 144 | 92 | 60 |
| Tumor | 380 | 196 | 24 |
| Paracolic node | 136 | 7.6 | 0.1 |
| Intermediate node | | 16.8 | 1.6 |
| Liver | | 3.0 | 0.04 |
| Liver metastasis | | 13.5 | 5.7 |

metastatic liver tumor, colon and lymph nodes were high, but these levels in the liver were the lowest. All these data are summarized in Table 3.

Chapter 3. Fundamental experiments on NCS administration, in particular NCS-iontophoresis

In these experiments, the concentrations of NCS in various fluids and tissues were determined by bioassay, the Band Culture Method. The strain of test organism: *sarcina lutea* 9341. Minimum inhibition concentration: 0.1 mcg/ml.

(1) In vitro inactivation of NCS by various dog tissue homogenates

Effects of anticancer drugs on the cancer lesion were depended on the concentrations and duration of the drug. The inactivation of antitumor antibiotics by tissue homogenates is ascribed to the adsorption at 0°C and the enzymatic decomposition at 37°C^{10,21}.

Materials and Methods: Various dog tissues were resected and fresh tissues, such as lung, liver, small intestine, stomach, lymph nodes and pancreas were placed into the physiological saline solution, homogenized and made into 30% emulsions. These tissue homogenates were mixed with equal volumes of NCS solution and the final NCS concentration was 5 mcg/ml. Drug levels in the mixtures were measured one and two hours after the mixing at 0°C and 37°C.

Results: The inactivation of NCS by tissue homogenates was not observed at 0°C, but did occur at 37°C. The inactivation of NCS by the liver and lymph nodes was intense at 37°C.

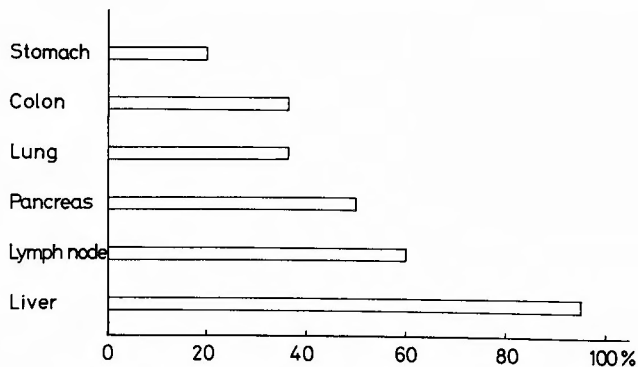


Fig. 7. Inactivation of NCS by dog tissues. Tissue homogenates and NCS were mixed, final concentration of NCS in homogenates was 5 mcg/ml, and incubated at 37°C for 60 min.

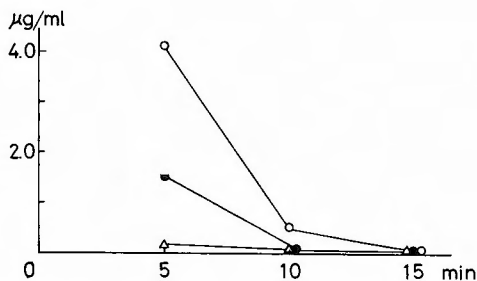


Fig. 8. Peripheral blood, portal blood and thoracic duct lymph levels of NCS after intravenous administration of 3 mg/kg of NCS in dogs
 ○-○ Peripheral blood, ●-● Portal blood, △-△ Thoracic duct lymph.

The inactivation by the colon, small intestine, pancreas and so forth, was moderately at 37°C (Fig. 7.). Consequently the inactivation of NCS was thought to be caused by the enzymatic decomposition.

(2) Intravenous administration of NCS

Materials and Methods: Adult mongrel dogs weighing about 7 to 10 kg were used. NCS solution was given in a dose of 3 mg/kg i.v.. NCS concentrations in these three body fluids were assessed using the same aforementioned methods.

Results: In the femoral vein blood, NCS levels abruptly decreased from 5 minutes after injection and were detected until 10 minutes after injection. In the portal vein blood, these levels were lower and were detected only 5 minutes after injection. NCS levels in the thoracic duct lymph were lowest and were maintained for 10 minutes. Detection at 15 minutes after injection was nil (Fig. 8.).

(3) Intramural injection of NCS solution into the colon

Materials and Methods: In adult mongrel dogs weighing about 7 to 10 kg, the above-mentioned methods were used and NCS solution was given intramurally into the colonic wall in a dose of 3 mg/kg.

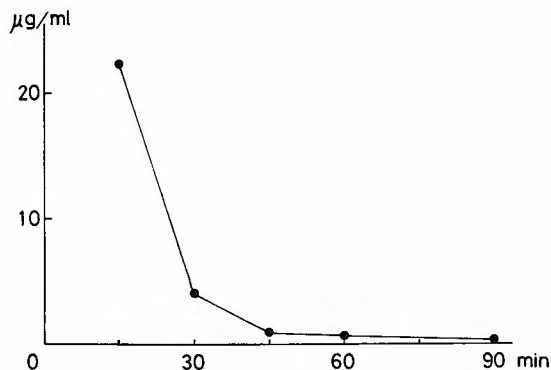


Fig. 9. Thoracic duct lymph levels of NCS after intramural administration of 3 mg/kg of NCS in dogs

Results: NCS levels were not detected in the femoral and portal vein blood and NCS concentrations in the thoracic duct lymph decreased abruptly from 15 minutes after injection and continued at this low level until 90 minutes after the injection (Fig. 9.).

(4) Intraluminal administration of NCS solution into the colon .

Materials and Methods: In adult mongrel dogs weighing about 7 to 10 kg, the same aforementioned methods were used. NCS solution was administered into the isolated segment of the colon in a dose of 3 mg/kg. The isolated segment along with the marginal vessels, measuring approximately 15 cm in length was prepared by placing two silk sutures around the bowel and ligating them before administration of the NCS solution.

Results: NCS was not detected in these three body fluids, however, in the dogs with a circular colonic mucosal defect, NCS levels in the thoracic duct lymph were measurable from 15 minutes after administration and arrived at a peak level at 30 minutes, maintaining a low level until 90 minutes after administration (Fig. 10.).

(5) Fundamental experiments on NCS-Iontophoresis

As NCS is an acidic single-chain polypeptide ionized at a pH over 3.26, application of the direct current into NCS solution shifted the molecules to the anode^{15,19)}. NCS was not inactivated by the direct current. Movement and permeance of NCS in the colonic wall was then assessed by the application of the direct current.

(i) Movement of NCS by the application of the direct current

The movement of NCS was observed with polyacrylamide gel iontophoresis. Electrophoresis of NCS solution was carried out using tris-glycine buffer (pH 8.5), running at a constant 100V for one hour. NCS was stained with amido black 10B and moved about 5 cm from cathodic to the anodic side.

(ii) Permeance of NCS into the colonic wall by iontophoresis

Materials and Methods: Two small vessels were separated by the resected colonic wall of the dog. The vessel on the mucosal side setting the cathode was filled with 20 ml of NCS solution in the solvent containing 100 mcg/ml NCS and the other vessel which was on the serosal side setting the anode was filled with the distilled water. Direct current was passed between both electrodes at 15 mA for 45 minutes. Thereafter, the resected colonic wall was divided into

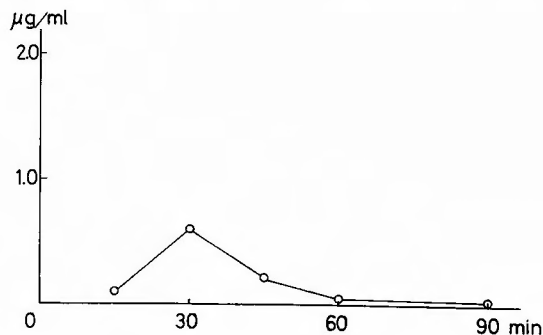


Fig. 10. Thoracic duct lymph levels of NCS after intraluminal administration of 3 mg/kg of NCS in dogs with a defect of the mucosal layer of colon

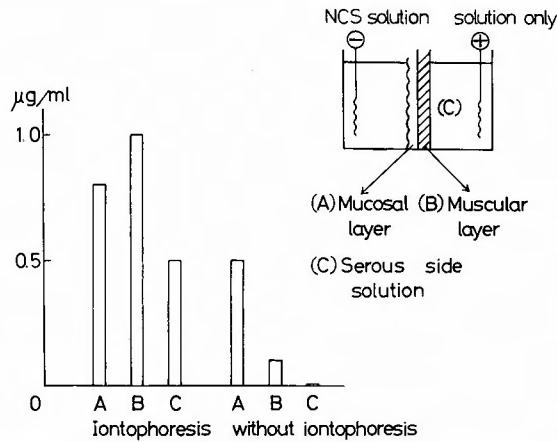


Fig. 11. NCS concentrations in the mucosal layer, muscular layer and serous side solution after iontophoresis and those without iontophoresis

the mucous and muscular layers and NCS concentration in each layer was measured.

Results: When a direct current was applied NCS concentration in the muscular layer was higher than that in the mucosal layer. NCS concentration in the mucosal layer was 0.8 mcg/g, while that in the muscular layer was 1.0 mcg/g and in the serosal solution 0.5 mcg/ml. When direct current was not given, NCS concentration in the muscular layer was lower than that in the mucosal layer. NCS concentration in the mucosal layer was 0.5 mcg/g and that in the muscular layer was 0.1 mcg/g. NCS in the serosal fluid was not detected (Fig. 11).

(6) Administration of NCS into the lumen of the colon using a double balloon catheter combined with iontophoresis

This experiment was performed under the assumption that when the intraluminal administration of NCS was combined with iontophoresis, permeance of NCS into the colonic wall and

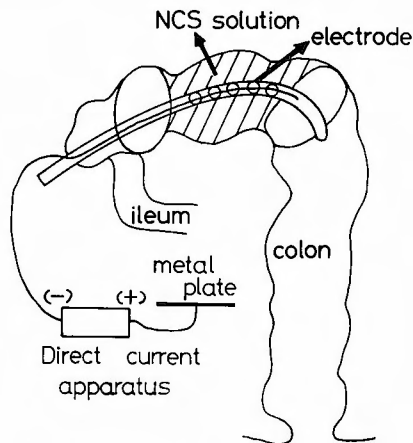


Fig. 12. Intraluminal administration of NCS using a double balloon catheter combined with NCS-iontophoresis

carcinoma tissues might be accelerated and the distribution of the drug to the regional lymph nodes might increase.

Materials and Methods: In adult mongrel dogs weighing about 7 to 10 kg, the same aforementioned methods were used and a double balloon catheter, in which a silver electrode was set between the balloons, was inserted into the colon via the cecum. A copper plate was placed on the back of the dogs. NCS solution was infused into the lumen of the colon between the two inflated balloons at a dose of 3 mg/kg (1 mg=1 ml). Direct current was passed from the copper plate to the silver electrode at 15 mA for 90 minutes (Fig. 12.).

Results: NCS was not detected in the femoral vein blood, portal vein blood and thoracic duct lymph, however, NCS levels in the muscular layer were 1.9 mcg/g. These levels were higher than those of the intramural injection (Fig. 13.).

(7) Comparison of NCS levels in various tissues of DMH-treated rats between intraluminal administration of NCS combined with NCS-Iontophoresis and that without NCS-Iontophoresis

Materials and Methods: Male Wistar rats (4 to 6 weeks old) were given 21 mg/kg of dimethylhydrazine solution weekly for 20 weeks. The stock solution for injections included 400 mg of DMH dissolved in 100 ml of water containing 37 mg of EDTA and was adjusted to pH 6.5 using sodium hydroxide.^{3,17,18)} When the rats developed clinical evidence of colonic disease such as rectal bleeding or palpable abdominal mass, the animals were anesthetized with

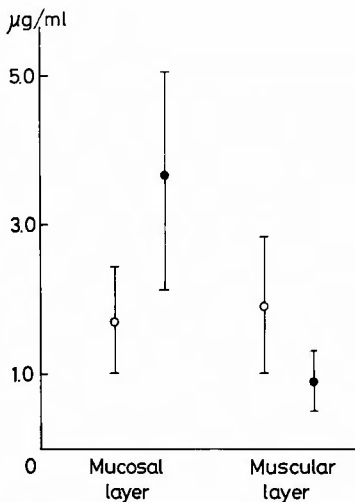


Fig. 13.

Fig. 13. Comparison of NCS concentrations in the mucosal layers and muscular layers of colons, by intramural injection V.S. intraluminal administration with iontophoresis in dogs

○ Intramural injection, ● Intraluminal administration with iontophoresis.

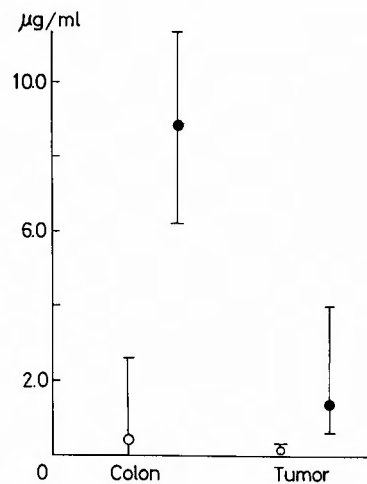


Fig. 14.

Fig. 14. NCS concentrations in the colon and tumor by intraluminal administration with iontophoresis in rats. dose 2 mg/rat

○ Intraluminal administration, ● Intraluminal administration with iontophoresis.

nembutal (0.2 mg/i.m.rat). The peritoneal cavity was opened and a catheter with an electrode was inserted from the anus. About 8 cm length of the colon was isolated by two silk sutures placed around the bowel. NCS solution was administered into the isolated segment of the colon in a dose of 2 mg/rat. In the case of intraluminal administration combined with iontophoresis the copper plate was placed on the back of the rats and direct current was passed from the copper plate to the catheter electrode at 15 mA for 90 minutes.

Results: Each method of administration was performed in eight rats, respectively. NCS was not detected in the portal vein blood and peripheral blood at 90 minutes after administration. In the case of intraluminal administration combined with iontophoresis, NCS levels in the colon were 6.2 to 11.2 mcg/g and those in the tumor were 0.5 to 3.9 mcg/g. In the case of intraluminal administration without NCS-Iontophoresis, NCS levels in the colon were 0 to 2.6 mcg/g and those in the tumor were 0 to 0.4 mcg/g (Fig. 14.).

Chapter 4. Clinical use of intraluminal administration and intraluminal administration combined with iontophoresis of NCS

(1) Intraluminal administration and intraluminal administration combined with iontophoresis of NCS in the colon cancer patients

Methods: In the colon cancer patients, a laparotomy was done and a “cut down” tube was inserted from the mesenteric to the portal vein to collect the portal vein blood. Peripheral blood and portal blood were taken at 5, 15 and 30 minutes after drug administration. The tumor bearing loop of colon was isolated by two silk sutures ligated around the bowel oral and aboral to the tumor and a double balloon catheter was inserted into the isolated segment. Both balloons were inflated and NCS solution, 0.5 mg/kg in about 100 ml, was infused into the lumen of the colon between two inflated balloons. Direct current was passed from the copper plate to the silver electrode at the magnitude of 5 to 10 mA for 30 minutes. Intraluminal administration of the drug was given to the three patients and intraluminal administration combined with iontophoresis was given to four patients.

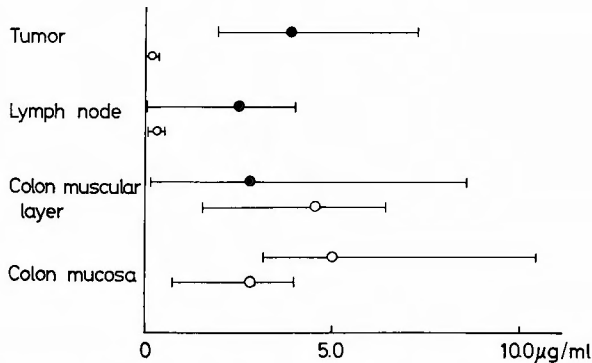


Fig. 15. Comparison of the distribution of NCS between intraluminal administration and intraluminal administration with iontophoresis in colon cancer patients. Dose 0.5 mg/kg
 ○ Intraluminal administration, ● Intraluminal administration with iontophoresis.

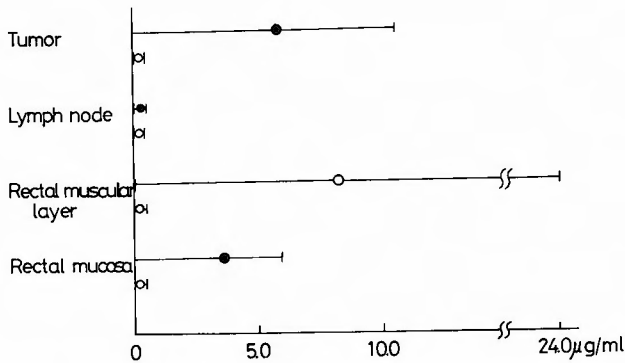


Fig. 16. Comparison of the distribution of NCS between intraluminal administration and intraluminal administration with iontophoresis in rectal cancer patients. Dose 0.5 mg/kg
○ Intraluminal administration, ● Intraluminal administration with iontophoresis

Results: NCS was not detected in the portal vein and peripheral blood. NCS concentrations in the mucosal and muscular layers of the resected colon were similar with both methods. NCS concentrations in the tumor of the colon and lymph nodes were 2.0 to 7.1 mcg/g and 0 to 4.0 mcg/g, respectively, in the method combined with iontophoresis, while concentrations were 0 to 0.4 mcg/g and 0 to 0.5 mcg/g, respectively, in the method without iontophoresis (Fig. 15).
(2) Intraluminal administration and intraluminal administration combined with iontophoresis of NCS in the rectal cancer patients

Methods: Using aforementioned method, NCS solution (0.5 mg/kg) was given intraluminally to three patients and intraluminal administration combined with iontophoresis was carried out in the three patients.

Results: NCS was not detected in the portal vein and peripheral blood. In the resected specimens, NCS concentrations in the mucosal and muscular layers of the rectum and in the tumor of the rectum were 0 to 6 mcg/g, 0 to 24 mcg/g and 0 to 10.5 mcg/g, respectively, in the method with iontophoresis, 0 to 0.5 mcg/g, 0 to 0.5 mcg/g and 0 to 0.4 mcg/g, respectively, in the method without iontophoresis. NCS concentrations in the lymph nodes were low with both methods (Fig. 16)..

Discussion

Colorectal cancer is treated with surgical resection, radiotherapy and local or general chemotherapy. With regard to the operation, the 5-year-survival rate has improved after adoption of the "no-touch isolation technic".³⁶⁾ Radiotherapy has not played a major role in the treatment of cancer of the intestine, except for rectal cancer. HIGGINS et al.¹⁴⁾ reviewed the rationale for preoperative radiotherapy as follows, a) improving the resectability rate by reducing the bulk of tumor, b) minimizing regional metastasis, c) minimizing distant metastasis, and d) reducing local recurrence at the excision side. They reported that in patients undergoing

combined abdominoperineal resection, the five-year-survival rate was 46% in the irradiated group and 30% in the controls. However, no particular benefit was seen in patients with positive regional lymph nodes metastases. In 1955 FISHER et al.⁸⁾ reported that tumor cells were recovered from the blood of the major mesenteric venous channels in 8 of 25 patients with colorectal carcinoma. DEDDISH⁷⁾ reported that preoperative X-ray therapy did not appear to influence the survival rate in patients free of lymph node metastasis, but definitely benefited those demonstrating lymphatic involvement. In 1957 SHAPIRO³⁰⁾ reported that neither surgery nor chemotherapy alone produced "cures" of tumors in mice, but that the combination resulted in a 57 per cent "cure" rate of the tumors. When anticancer agents are being considered, it is important that effective adjuvant therapy be given as soon as possible after surgery in order to destroy the micrometastases before they become macroscopic and relatively insensitive⁴⁾. Routes of administration of anticancer drugs include intravenous, oral, intraluminal, intramural and intra-arterial. In unresectable and recurrent colorectal cancer patients, intra-arterial infusion chemotherapy has been performed and successful cases have been reported^{25,35)}. Intramural and intraluminal administrations are given during the surgery. COLE and ROUSSELOT^{6,28)} demonstrated that 5-FU is absorbed from the colonic wall by intraluminal administration into the isolated colon in dogs and administration in colorectal cancer patients at the time of operation. They reported that stage I and II survivals in the 5-FU treated patients reached 80% versus 62% in the control groups. According to recent reports^{11,29)}, recurrence free survival analysis at five years indicated that the survival rate in the fluorouracil-treated colorectal group was 69 percent, while the rate was 68 per cent in the control group. In the fluorouracil-treated group with carcinoma of the colon and serosal penetration, the survival rate was 75% compared with 66% in the control group. In the treated rectal group with both positive serosa and lymph nodes, it was 40% compared with 13% in the control group. In the colorectal cancer patients, the improvement of survival rate and the reduction of tumor by intravenous administration of 5-FU were reported and its effectiveness was established^{12,13,20,22,37)}. Recently the benefit of combination therapy with 5-FU, methyl CCNU, BCG, vincristine and others was demonstrated in patients with metastatic large bowel cancer^{2,23,26)}. In the studies reported in the present paper, drug levels in the colonic wall were high in the case of intraluminal and intramural administrations and levels in the lymph nodes were the highest in the case of intramural injection. Regarding the distribution of 5-FU, intramural injection was the best method. SHUKLA et al.³³⁾ and YAMADA et al.³⁸⁾ reported the same results. Neocarzinostatin was detected in the culture filtrate of streptomyces carzino-staticus and it was an antitumor antibiotics. NCS inhibits DNA synthesis, and the action is not time-dependent, and it is inactivated by ultraviolet irradiation^{24,32,34)}. When NCS was given in a dose of 3 mg/kg i.v. to dogs, the drug was not detected in the colonic wall, however, in the case of intraluminal administration detection in the colonic wall was 1.0 to 3.0 mcg/g. With intraluminal administration combined with iontophoresis, NCS was detected at rates of 0.5 to 5.5 mcg/g in the colonic wall. In the colorectal cancer patients, the colonic wall and tumor revealed high NCS levels in the case of intraluminal administration combined with iontophoresis.

Conclusion

In attempts to improve the operative curability of colorectal cancer, the author investigated local adjuvant chemotherapy combined with operation, intraluminal administration and intramural injection of 5-FU and NCS, and intraluminal administration of NCS combined with NCS-Iontophoresis. The results were as follows: 1) When 5-FU solution was injected into the colonic wall, the drug was absorbed into the portal vein blood and the thoracic duct lymph for a short period, spread to the intramural lymphatics and reached the regional lymph nodes, in a high concentration. In the liver 5-FU levels showed high values. 2) When 5-FU was administered into the lumen of the colon, it was detected only in the portal vein blood. Drug levels in the liver and lymph nodes showed low values. 3) When NCS was injected into the colonic wall, the drug was detected in a high level in the thoracic duct lymph and the colonic wall. 4) When NCS was administered into the lumen of the colon, it was not absorbed through the normal colonic mucosa. When the mucosa of the colon was removed, the drug was slightly absorbed and detected at a low level in the thoracic duct lymph. 5) NCS was not inactivated by direct electric current and shifted to the anode in the application of polyacrylamide gel electrophoresis. 6) When NCS was administered into the lumen of the colon combined with iontophoresis, the drug permeated the colonic wall through the normal mucosa and distributed in the tumor and colonic wall, at high levels. There were no complications in the clinical cases. From these results, considering the high levels of drug distribution, intramural injection of 5-FU and NCS administration into the lumen of the colon using a double balloon catheter combined with iontophoresis proved to be effective in cases of colorectal cancer as an adjuvant local chemotherapy. Furthermore, the intraluminal administration of NCS combined with iontophoresis had few and minor side effects.

Acknowledgements

The author expresses gratitude to Prof. Dr. *Koichi Ishigami* for his kind guidance and to the staff of our department for their cooperation throughout this study.

The abstract of this paper was presented at the 12th general meeting of the Japanese Society of Gastroenterological Surgery, Hirosaki, July, 1978 and the 79th general meeting of the Japanese Surgical Society, Sapporo, May, 1979.

References

- 1) Alarcon J: Adenocarcinoma of the colon and rectum. A review of surgical treatment in 302 patients. *Dis Colon & Rectum* **22**: 35-39, 1979.
- 2) Baker LH, et al: Phase III comparison of the treatment of advanced gastrointestinal cancer with bolus weekly 5-FU VS Methyl-CCNU plus weekly 5-FU. *Cancer* **38**: 1-7, 1976.
- 3) Barkla DH, et al: Surface change in the descending colon of rats treated with dimethyl-hydrazine. *Cancer Res* **37**: 262-271, 1977.
- 4) Burchenal JH: Adjuvant therapy-theory, practice and potential. *Cancer* **37**: 46-57, 1976.
- 5) Cole DR, et al: Absorption patterns of intraluminal 5-FU in the isolated right colon of the dog. *Surg* **55**: 252-257, 1964.
- 6) Carter SK: Large bowel cancer the current status of treatment. *J Nat Cancer Inst* **56**: 3-10, 1976.
- 7) Deddish MR: The effect of preoperative roentgen therapy on 10 and 5 years results of surgical treatment of cancer of the rectum. *Surg Gynecol Obstet* **111**: 507-508, 1960.

- 8) Fisher MR, et al: The cytologic demonstration and significance of tumor cells in the mesenteric venous blood in patients with colorectal carcinoma. *Surg Gynecol Obstet* **100**: 102-108, 1955.
- 9) Fujita H: Bioassay of anticancer agents. *Media Circle* **92**: 1-12, 1967.
- 10) Fujita H: In vivo distribution and inactivation of neocarzinostatin. *J Antibiot* **23**: 471-478, 1970.
- 11) Grossi CE, et al: Intraluminal fluorouracil chemotherapy adjunct to surgical procedures for resectable carcinoma of the colon and rectum. *Surg Gynecol Obstet* **145**: 541-544, 1977.
- 12) Hahn RG: A double blind comparison of intensive course 5-FU by route in the treatment of colorectal carcinoma. *Cancer* **35**: 1031-1035, 1975.
- 13) Higgins GA, et al: Fluorouracil as an adjuvant to surgery in carcinoma of the colon. *Arch Surg* **102**: 339-343, 1971.
- 14) Higgins GA, et al: The role of preoperative irradiation in cancer of the rectum and rectosigmoid. *Surg Clin North Amer* **152**: 847-857, 1972.
- 15) Ishida, N, Katsuo K: New anticancer agent "neocarzinostatin" *Igaku no ayumi* **57**: 815-816, 1966. (in Japanese).
- 16) Jinnai D, et al: Statistical analysis of cancer of the colon and rectum. *Cancer & Chemotherapy* **4**: 897-905, 1977.
- 17) Kamitani J, et al: Experimental colon cancer in rats induced by 1, 2. Dimethylhydrazine—with special reference of its preferential location. *Igaku no ayumi* **101**: 82-84, 1977. (in Japanese).
- 18) Katayanagi T: Experimental colonic cancer. *Saishin-Igaku* **32**: 2414-2419, 1977. (in Japanese).
- 19) Kohno M, et al: Studies on stability of antitumor protein, neocarzinostatin. *J Antibiot* **27**: 707-714, 1974.
- 20) Krakoff IH: Chemotherapy of gastrointestinal cancer. *Cancer* **30**: 1600-1603, 1972.
- 21) Kumasaka T: In vivo inactivation of anticancer antibiotic by body fluids and cells of experimental animals. *Chemotherapy* **12**: 1-9, 1964.
- 22) Li MD, Ross ST: Chemoprophylaxis for patient with colorectal cancer. *JAMA* **235**: 2825-2828, 1976.
- 23) Mavligit GM, et al: Adjuvant immunotherapy and chemioimmunotherapy in colorectal cancer (Duke's Class C). *Cancer* **40**: 2726-2730, 1977.
- 24) Meienhofer JH, et al: Primary structure of neocarzinostatin, an antitumor protein. *Science* **178**: 875-876, 1972.
- 25) Miura K, et al: Intra-arterial infusion chemotherapy with 5-FU and mitomycin C in advanced cancer of colon and rectum. *Cancer & Chemotherapy* **4**: 971-982, 1977.
- 26) Moertel CG, et al: Brief communication: Therapy of advanced colorectal cancer with combination of 5-Fluorouracil, Methyl-1, 3 cis (2 chlorethyl)-1-nitrosourea and vincristine. *J Nat Cancer Inst* **54**: 69-71, 1975.
- 27) Okubo H, Okamoto Y: Microbioassay of antibiotic levels in body fluids and tissues. *Clinic J Jap* **31**: 441-447, 1973.
- 28) Rousselot LM, et al: Intraluminal chemotherapy adjuvant (NH₂ or 5-FU) to operation for cancer of the colon and rectum. *Ann Surg* **162**: 407-415, 1965.
- 29) Rousselot LM, et al: Adjuvant chemotherapy with 5-Fluorouracil in surgery for colorectal cancer. *Dis Col Rect* **15**: 169-174, 1972.
- 30) Shapiro D, Fugmann R: A role for chemotherapy as an adjuvant to surgery. *Cancer Res* **17**: 1098-1101, 1957.
- 31) Shibata G: Studies on supplementary chemotherapy combined with surgical treatment of carcinoma of the esophagus. *Arch Jap Chir* **44**: 169-198, 1976.
- 32) Shimayama M, Kimura K: Unique characteristics in cytotoxic action of neocarzinostatin. *Cancer & Chemotherapy* **6**: 105-110, 1979.
- 33) Shukla HS, et al: Distribution of 5-Fluorouracil to the body tissues compared after intraluminal, intravenous and intramural administration in gastrointestinal cancer. *Am J Surg* **133**: 346-350, 1977.
- 34) Takamoto S, Oota K: Effect of antitumor antibiotics on the cell cycle traverse of culture FL cells. *Cancer & Chemotherapy* **6**: 59-70, 1979.
- 35) Takami M, et al: Intra-arterial infusion chemotherapy for recurrent and unresectable colorectal cancer. *Cancer & Chemotherapy* **6**: 275-230, 1979.
- 36) Turnbull RB, et al: Cancer of the colon: The influence of no-touch isolation technic on survival rates. *Ann Surg* **166**: 420-425, 1967.
- 37) Laurence W Jr, et al: Chemotherapy as an adjunct to surgery for colorectal cancer. *Ann Surg* **181**: 616-623, 1975.
- 38) Yamada K, et al: Intraluminal, lymph node, hepatic and serum levels after intraluminal and intramural injection of 5-Fluorouracil in the dog. *Am J Surg* **131**: 253-257, 1976.

和文抄録

結腸直腸癌の手術合併制癌剤療法に関する研究,
とくに Double balloon catheter および
電気泳動を応用した局所投与法

山口大学医学部外科学教室第2講座 (指導: 石上浩一教授)

赤 尾 伸 二

結腸・直腸癌手術の根治性を向上させるための合併局所化学療法として、5-FU、ネオカルチノスタチン(NCS)の大腸壁内注射および大腸内腔内投与ならびにNCSの大腸内腔内投与電気泳動併用法について検討し、次のような成績を得た。

1) 5-FUを大腸壁内に局注すると、5-FUは胸管リンパ、門脈血および末梢血中に迅速に吸収され、壁内リンパ流によって所属リンパ節に高濃度に分布し、肝にも高濃度に分布した。

2) 5-FUを大腸内腔内に投与すると門脈血中のみ検出され、リンパ節および肝には低濃度の分布しかみられなかった。

3) NCSを大腸壁内に注射すると、胸管リンパ中のみ高濃度に検出され、一方大腸壁内にも高濃度に分布した。

4) NCSを大腸内腔内に投与すると、正常粘膜からはほとんど吸収されなかったが、大腸粘膜に欠損の

ある場合には胸管リンパ中に低濃度で検出された。

5) NCSは通電によって不活性化をうけず、かつ通電によって陽極側に移動した。

6) 大腸内腔内投与法にNCS-Iontophoresisを併用すると、正常大腸粘膜からのNCSの浸透が促進され、さらに大腸腫瘍内および大腸壁内に高濃度のNCSが検出された。また臨床例に本法を応用しても特別の合併症を認めなかった。

イヌおよび臨床例における検討成績より考えると、結腸・直腸癌手術の合併療法としては5-FUの壁内注射及びNCSの内腔内投与にIontophoresisを併用する方法が薬剤の濃度分布よりみて有効な方法であると思われた。またNCS内腔内投与にIontophoresisを併用する方法は副作用も少なく、Double balloon catheter挿入可能な部では頻回に行えるという長所をもっていた。