

Effects of an Artificial Intestinal Valve on Massive Bowel Resection

TETSUJI HANAFUSA

The 2nd Department of surgery, Faculty of Medicine, Kyoto University
(Director: Prof. Dr. KAZUE OZAWA)

Received for Publication, Oct. 30, 1985.

Introduction

Massive bowel resections, required in certain instances of total colon aganglionosis, intestinal atresia, necrotizing enterocolitis, or midgut volvulus during the neonatal period and in ulcerative colitis, *Crohn's* disease, mesenteric vascular occlusions or malignancies in adults, are increasing in frequency. The operation, which entails surgical removal of more than 66% of the small bowel, results in intractable diarrhea, malabsorption, steatorrhea and precipitate weight loss. Removal of the ileocecal valve during resections of major portions of the small intestine is frequently required, however the elimination of the ileocecal valve during resection increases the severity of diarrhea and malabsorption. Actually, cases of massive intestinal resection including ileocecal valve seemed more difficult to control than cases preserving the valve.

After massive resection, functional adaptation of the residual intestine may occur, depending upon its length, location and adaptive capabilities.

Many surgical techniques have been developed to encourage residual intestine adaptation. These include vagotomy and pyloroplasty, recirculating loops, reversed segments, colonic interposition, artificial sphincters or valves, intestinal lengthening and electrical pacing. Among these, sphincter or valve formation seems to be effective in regulating transit and preventing reflux, when the ileocecal valve is removed.

Those observations accelerate development of an artificial valve compensating the loss of the ileocecal valve.

This report describes the effects of an artificial valve, formed by means of intussusception of the colon, and discusses surgical approaches to the short bowel syndrome.

Materials and Methods

Forty-six mongrel puppies aged 3~5 months and weighing 3~6 kilograms were used in the experiment. All were dewormed and immunized for canine distemper and hepatitis at the age of 5~6 weeks. The animals were moved to the laboratory 2 to 3 weeks before the operation to

Key words: Massive bowel resection, Short bowel syndrome, Artificial intestinal valve, Ileocecal valve.

索引語：腸管大量切除，広汎腸切除症候群，人工腸弁回盲弁。

Present address: The 2nd Department of Surgery, Faculty of Medicine, Kyoto University, Sakyo-ku, Kyoto 606, Japan.

Table 1. Chow Components—Oriental yeast company

	water	7.0 g		vitamin A	867 IU
	protein	27.8		D ₃	173
	fat	6.0		E	4 mg
	fiber	1.3		K ₃	0.06
	inorganic substances	5.7		B ₁	1.2
	carbohydrates	52.2		B ₂	2
	total energy	kcal	vitamin	B ₆	1
	energy	374.0		B ₁₂	5 μ g
		—		niacin	8 mg
				pantothenic Ca	7.5
				biotin	0.02
				folic acid	0.15
				inositol	50
				cholin chloride	100
				vitamin C	9.5
amino acids	Alanine	— g		inorganic substances	total
	Arginine	1.44	Ca		0.97
	Aspartic acid	1.46	P		0.82
	Cystine	2.15	Mg		0.19
	Glutamic acid	0.30	Na		0.40
	Glycine	3.18	K		0.43
	Histidine	1.40	Fe		19 mg
	Isoleucine	0.77	Al		5
	Leucine	2.27	Cu		0.59
	Lysine	1.44	Zn		5.04
	methionine	0.41	Co		0.53
	phenylalanine	1.12	Mn		8.30
	proline	2.01	SiO ₂		0.41 g
	serine	0.70	I		—
	threonine	0.68	Ca/P		1.18
tryptophane	0.30	Ca/Mg	5.10		
tyrosine	0.59	K/Na	1.08		
valine	1.03				

per 100 gm

acclimate them.

They were fed a diet of chow (Table 1) and water ad libitum. The laboratory was kept at 24°C and 70% humidity. During this period 14 dogs died of respiratory disease or hemorrhaging.

The remaining animals were divided into the following 5 groups: (Fig. 1)

Group A: 3 dogs, 90% resection of the distal small intestine. The distal end of the remaining jejunum was anastomosed end-to-end to the proximal end of the remaining ileum.

Group B: 8 dogs, 80% resection of the distal small intestine.

Group C: 10 dogs, 80% resection of the distal small intestine, including the ileocecal valve. The distal end of the remaining jejunum was anastomosed end-to-end to the ascending colon.

Group D: 3 dogs, 80% resection of the small intestine, including the ileocecal valve. An

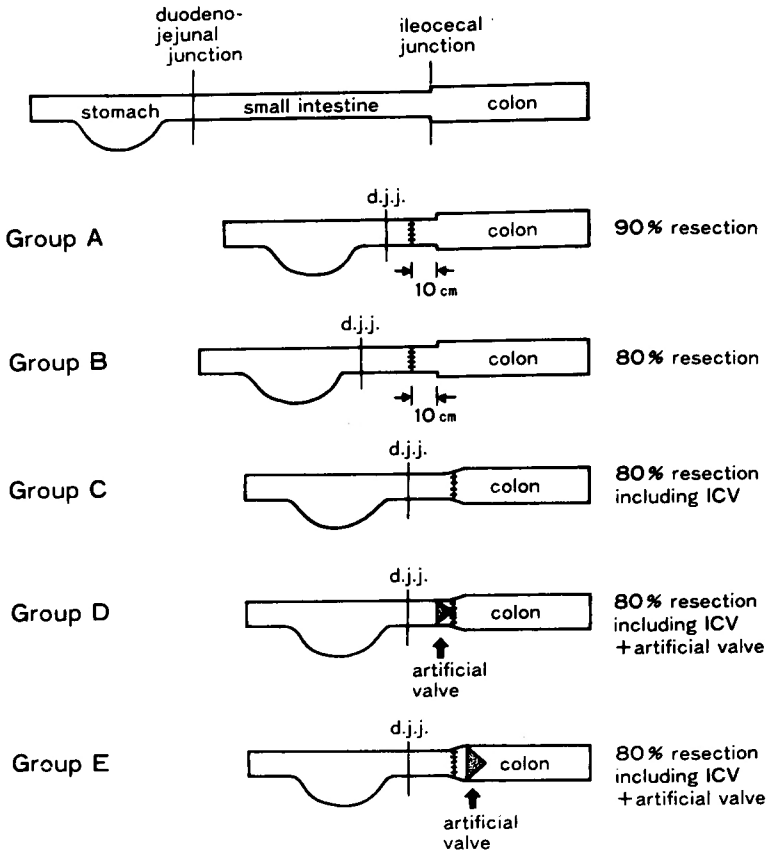


Fig. 1. Diagram of operative procedures of 5 surgical groups
 d.j.j.: duodeno-jejunal junction, \equiv : anastomosis
 \triangle : artificial valve, ICV: ileocecal valve

artificial valve was formed 5 cm orad to the jejuno-colonic anastomosis.

Group E: 8 dogs, 80% small bowel resection, including the ileocecal valve. An artificial valve was formed 5 cm aborad to the jejuno-colonic anastomosis.

The animals were given only water for 6 hours preoperatively. Intraoperatively the dogs were given intravenous fluids (*Hartman's* solution) 100 ml/kg.

The animals were anesthetized intravenously with 25 mg/kg pentobarbital sodium. The peritoneal cavity was entered through a mid-line abdominal incision by clean operation.

Intestine length from the duodeno-jejunal junction (ligament of *Treitz*) to the ileocecal junction along the anti-mesenteric border was measured using a plastic ruler.

All animals underwent a small bowel resection with or without resection of the ileocecal valve. Following resections the animals in groups A, B and C received end-to-end anastomosis by layer-to-layer method using 3-0 Dexon sutures. Animals in groups D and E, following resection, underwent creation of the artificial valve.

Operative technique for the artificial valve

The vas recti of the mesentery were divided. Seromuscular layer was detached from a length of an intestinal segment equal to its diameter at the jejunum and half at the ascending colon. The proximal segment up to the denuded segment was invaginated to the distal intestine (Fig. 2 and 3) and the raw edge of the distal part was sutured to the seromuscular layer of the proximal part with interrupted 3-0 silk sutures. Then the enteron and the mesentery were sutured using approx. 6 stitches to prevent transit obstacle by adhesion or bend at the valve plastic site and valve dehiscence.

The abdominal cavity was closed using two layers of interrupted sutures. Postoperatively, the animals were immediately given water per os, followed by a chow 12 hours later. Intravenous fluid administration was not performed.

Measurement

Body weight

Body weight was measured prior to operation, immediately after operation and at weekly intervals thereafter.

Stool assessment

Stool consistency was observed every three to four days.

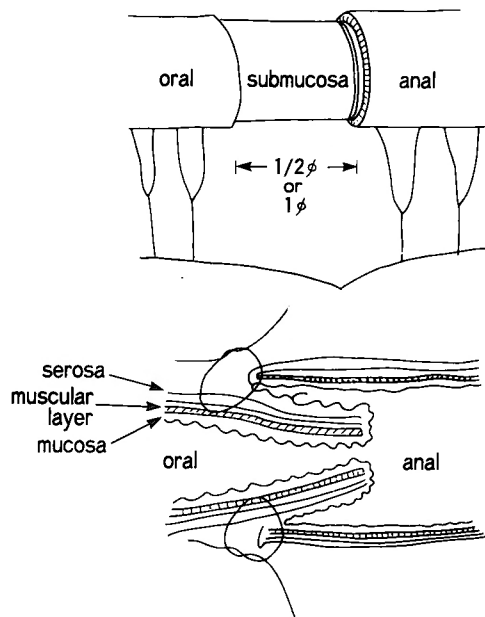


Fig. 2. (upper) Artificial intestinal valvuloplasty.

The seromuscular layer was detached from a length of an intestinal segment equal to its diameter at the small intestine and half at the colon. Only vasa recti in the ablated portion were cut off.

(lower) Artificial valve cross section. Note the rupture at both the proximal and distal ends of the intestinal muscular layer; the serosa backed with mucosa is on the proximal side.

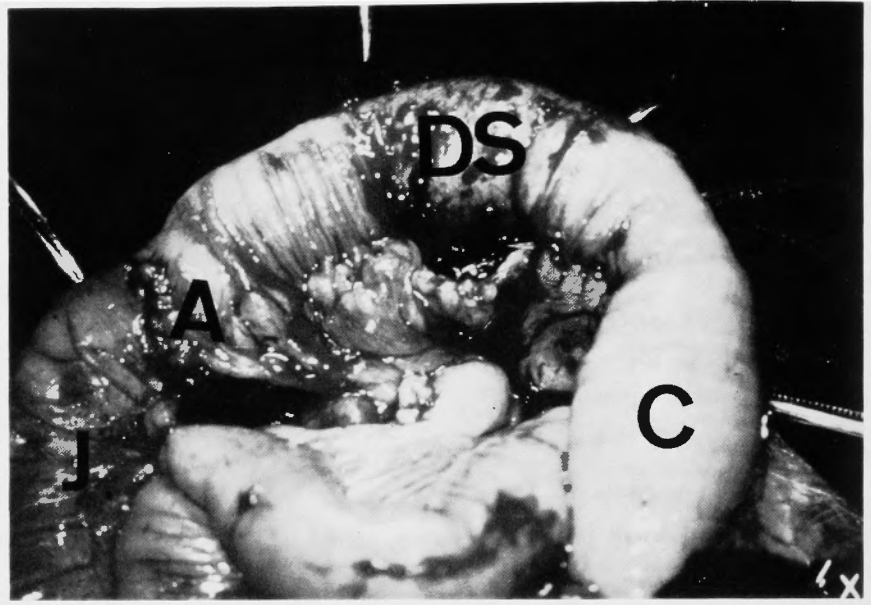


Fig. 3. Photogram of the artificial valve formation before invagination in group E.
 A : jejunocolonic anastomosis
 C : ascending colon
 DS: denuded segment (both muscle layers removed)
 J jejunum

Laboratory data

Red blood cell count, hemoglobin and hematocrit levels, electrolytes, total protein and albumin concentration, total cholesterol level and triglycerides were measured preoperatively and again 15 weeks after operation.

Morphological Studies

Microscopic examination by hematoxylin-eosin stain was performed at death or 15 weeks after operation.

Result

Mortality

In group A, 3 animals with severe diarrhea and weight loss died at 6, 16, and 27 days, while in group D, 2 dogs with severe diarrhea and weight loss died at 18 days, the remaining animal survived.

After 5 weeks mortality was zero% in group B, 20% in group C and 12.5% in group E. After 10 weeks, cumulative mortality was 12.5% in group B, 40% in group C and 25% in group E. During this period, death in group C dogs was related to progressive cachexia with diarrhea characterized by excessive weight loss, while death in group E dogs was related to abdominal wall infection and diarrhea. After 15 weeks, mortality was 12.5% in group B, 50% in group C and 25% in group E. (Fig. 4)

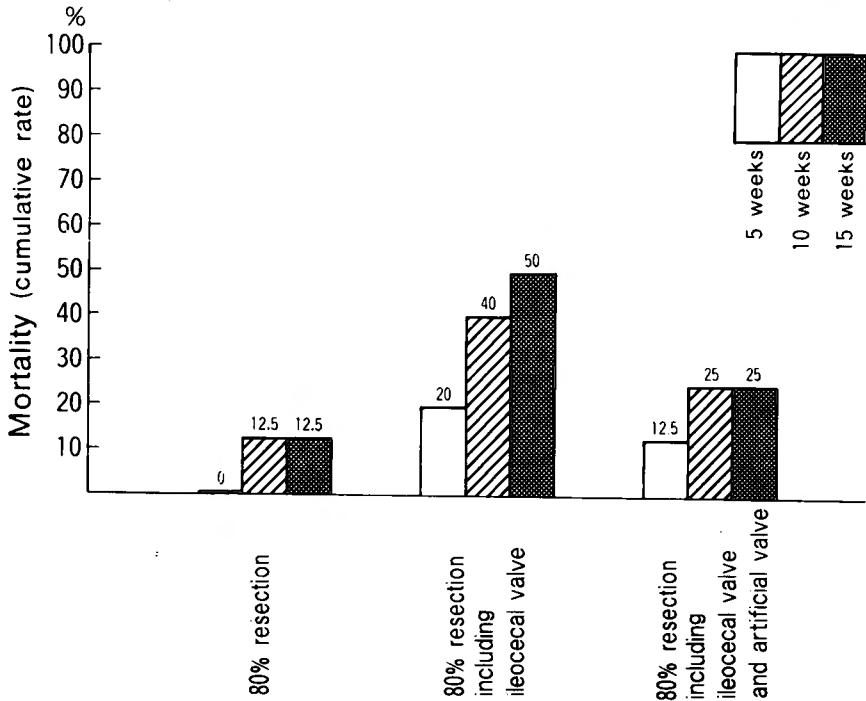


Fig. 4. Mortality

In the 80% resection group, no dogs died during the 10 weeks after operation. The mortality rate was 50% in the 80% resection with resected ileocecal valve group and 25% in the artificial valve group.

Groups A and D were excluded due to the small number of cases ($n=3$). In group A (90% resection), animals died at 6, 16 and 27 days.

The valve in one animal from group E was disrupted at autopsy, the time of disruption is unknown. This case was removed from the assessment.

Body weight

The average mean weight in the postoperative period is plotted and shown in Figs. 5 and 6. The 90% resection group (A) and 80% resection including ileocecal valve plus jejunal valve group (D) were not plotted.

Group B showed a sharp drop during the first postoperative week, followed by a gradual gain. Average weight loss was about 13% of initial weight, and at 3.5 weeks the average weight of group B exceeded the preoperative level. (range 2.5~4.5 weeks)

Group C also showed a sharp drop in the first postoperative week, followed by a plateau. Weight loss was about 22% and continued up to 7 weeks. After 15 weeks, animals surviving in group C showed a mean weight loss of 7%.

Group E also showed a sharp drop during the first postoperative week, followed by a gradual gain. Average weight loss was about 14% of initial body weight, and at 5.5 weeks the average weight of group E exceeded the initial level. (range 2.5~8 weeks)

Weight change did not correlate with remaining small bowel length or operation time (Table

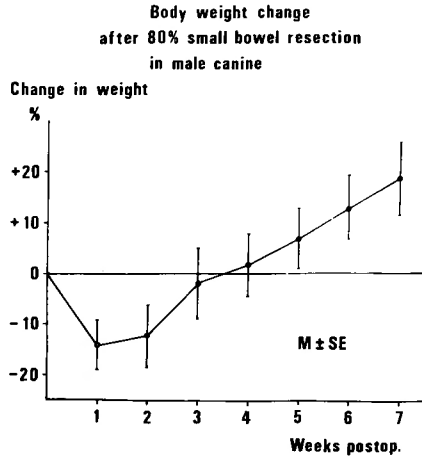


Fig. 5. Body weight changes after 80% small bowel resection (group B). The average weight was lost about 13% of the initial period, and exceeded the preoperative level at 3.5 weeks.

2). Weight gain or loss seemed to depend most on the presence or absence of the ileocecal or artificial muscular valves.

Stool assessment

Stool consistency was observed every three to four days. Stool frequency was not measured.

In group A stool consistency was watery, in group B semisolid (formed) to solid after 3 weeks, group C remained watery after 15 weeks, stool consistency in group E was semisolid after 15 weeks.

Laboratory data (Table 3, Fig. 7)

No statistically significant changes were observed in red blood cell count, hemoglobin and

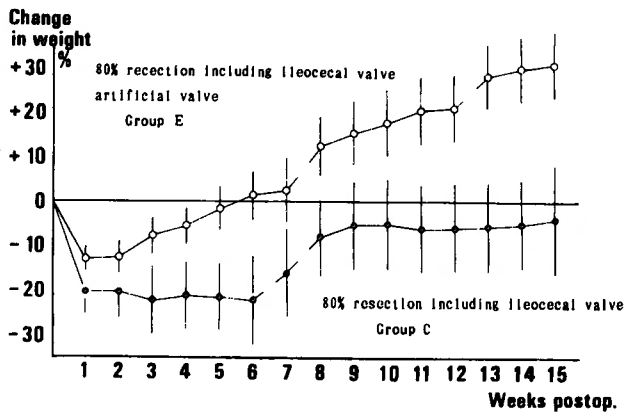


Fig. 6. Body weight changes of the 80% small intestine/ileocecum resection with or without the artificial valve fitting groups. (groups C and E) Group C showed a sharp drop in the first postoperative week, followed by a plateau, while group E showed a sharp drop, followed by a gradual gain. At 5.5 weeks the average weight of group E exceeded the initial level.

Table 2. The length of the small intestine prior to and after operation was comparable. There was no significant differences between each groups.

	Length of small intestine	
	original (cm)	post resection (cm)
80% resection	218.3 ± 23.39	43.7 ± 4.68
80% resection including ICV	226.6 ± 15.99	45.3 ± 3.19
80% resection including ICV + artificial valve	216.7 ± 13.74	44.7 ± 3.59

hematocrit levels between groups C and E. Serum sodium, potassium and chloride levels also showed no statistically significant changes.

A slight statistically significant drop was noted in total protein and albumin concentration in groups C and E.

The drop in total cholesterol levels was more marked in group C than in group E. Statistically significant changes were also noted in triglyceride levels of both groups.

Morphology of the residual intestine (Fig. 8)

At the time of death or sacrifice for long term living animals of groups B, C and E, the most noticeable intestinal changes were thickening and dilatation of the gut. Microscopically, increase in the number of vili and crypt length was noticed in the jejunum, but not in the colon. No significant differences between groups C and E were observed.

Clinical observations

Animals which survived the immediate trauma of operation did fairly well. They began to

Table 3. Red blood cell, hemoglobin, hematocrit and electrolytes at 15 weeks post operatively. There were no statistically significant changes in red blood cell count, hemoglobin and hematocrit levels between groups C and E. Serum sodium, potassium and chloride levels also showed no statistically significant changes.

	Group C 80% resection including ICV	Group E 80% resection including ICV + artificial valve	no operation
RBC $10^4/\text{mm}^3$	625 ± 196	611 ± 125	545 ± 82.4
HB g/dl	13.2 ± 3.57	12.5 ± 2.91	10.6 ± 1.88
Ht %	40.0 ± 9.85	37.5 ± 8.44	33.1 ± 5.08
Na mEq/l	152.6 ± 4.42	149.7 ± 4.17	148.8 ± 3.22
K mEq/l	5.40 ± 1.10	5.76 ± 1.11	4.80 ± 0.67
Cl mEq/l	112.2 ± 9.64	107.8 ± 5.11	108.1 ± 4.61
Ca mEq/l	4.38 ± 0.59	5.14 ± 0.39	4.80 ± 0.67
Mg mEq/l	2.30 ± 0.40	1.98 ± 0.26	2.69 ± 0.27

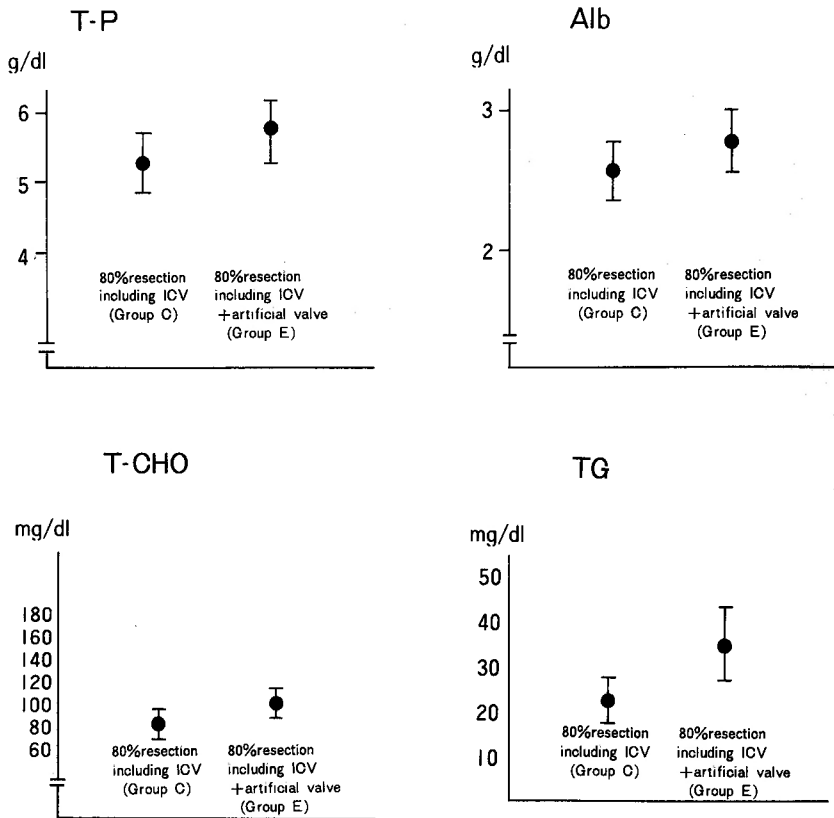


Fig. 7. Total protein, albumin, total cholesterol and triglyceride level at 15 weeks post operatively.

A statistically significant drop was noted in total protein and albumin concentration in groups C and E.

The drop in total cholesterol level was more marked in group C than in group E. Statistically significant changes were also noted in triglyceride levels of both groups.

T-P : total protein
 Alb : albumin
 T-CHO: total cholesterol
 TG : triglyceride
 ICV: ileocecal valve

drink within 12 hours and to eat within 24, however most of dogs had a rather poor appetite.

The noses of animals which failed to regain body weight were dry, the coats lost the usual healthy sheen, and shedding or decubitus ulcers were common.

Complication

The valve in one puppy from group E was disrupted at autopsy (Fig. 9). The dog grew favorably regaining its preoperative weight in three weeks.

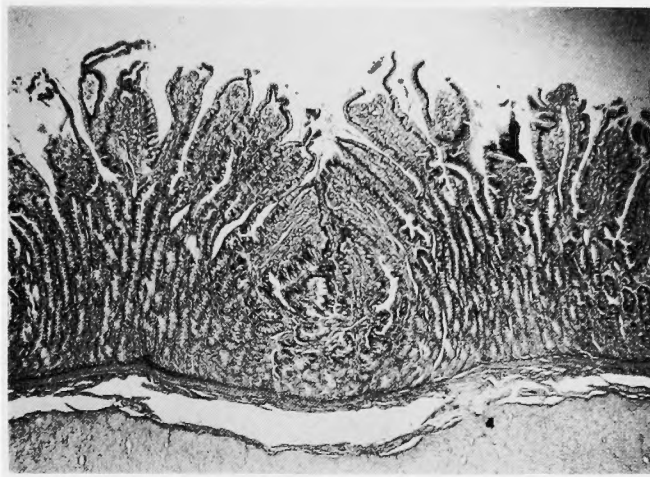


Fig. 8-1. Photograph of the jejunum, after 15 weeks in group E. (HE \times 10) Increase in villous height and crypt depth was noticed.

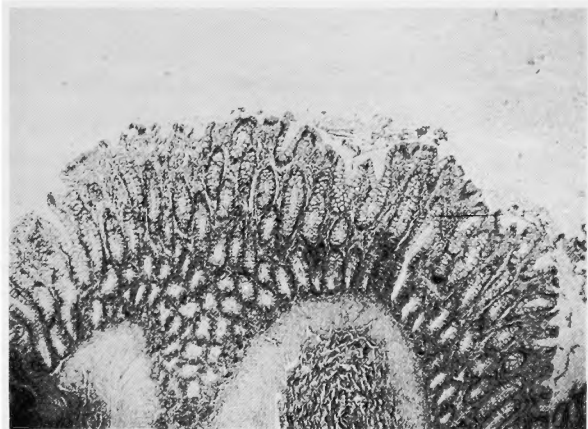


Fig. 8-2. Photograph of the colon, after 15 weeks in group E. (HE \times 10)

Discussion

Surgical Approaches to the short bowel syndrome

Many surgical approaches have been attempted in short bowel syndrome after massive bowel resection (Table 4). Some are already merely of historical relevance, while others are not yet clinically applicable.

Many attempts have been made to prolong transit time, the idea being to better absorption by longer contact of the intestine with the nutrients as a result of delayed transit. The valve or sphincter was also formed on the basis of this viewpoint and to prevent reflux from the colon to the small intestine.

Some attempts were made as well to directly increase the absorptive surface (induction of neomucosa and intestinal transplantation). Each will be described.

1. Vagotomy and pyloroplasty

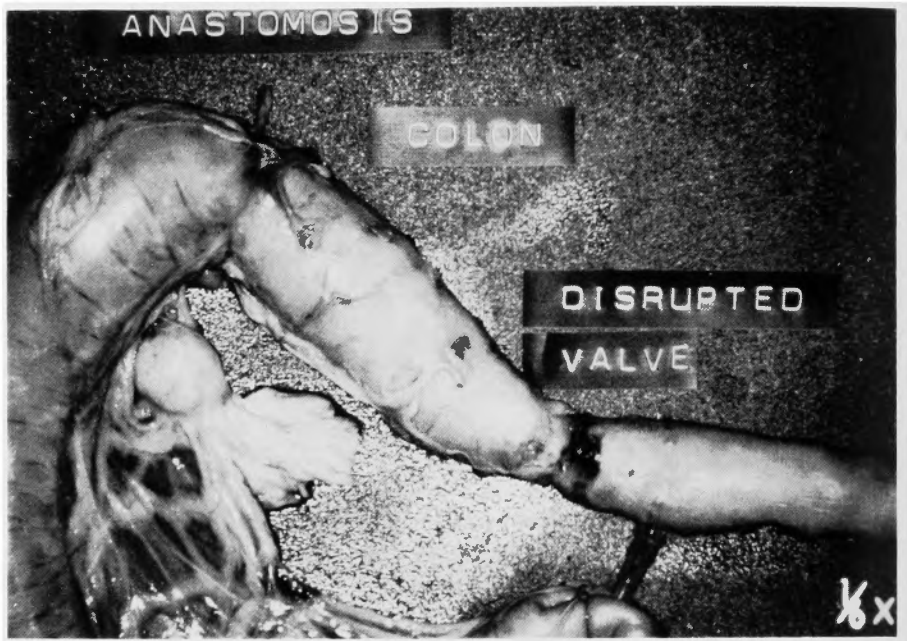

Fig. 9. Disrupted valve in one animal from group E.

This technique aims at delaying gastric emptying and prevention of hypersecretion. *Federic*⁶⁵⁾ noted a weight-loss prevention effect and good survival rate in dogs, the effect emerging 3 weeks after resection. Others reported clinical ineffectiveness⁶⁷⁾ as well as a tendency toward incontinent stomach using this method⁶⁷⁾.

Vagotomy and pyloroplasty are effective approaches to the hypersecretion inevitable after massive bowel resection and the subsequent acid-induced diarrhea⁶⁹⁾, but the appearance of H₂ receptor antagonists^{18,73)} seems to have diminished their significance.

2. Reversed small intestinal segment

This method, having the oldest history, dates from *Mall's* report in 1896⁶⁴⁾. *Hammer*⁴²⁾,

Table 4. Surgical procedures for the short bowel syndrome

Vagotomy and pyloroplasty
Reversed small intestinal segment(s)
Isoperistaltic small intestinal insertion
Colonic interposition
Interposed gastric tubes
Recirculating loops
Intestinal lengthning procedure
Induction of neomucosa
Electrical pacing
Intestinal transplantation
Valve or sphincter formation

Singleton^{99,100}, *Sako*⁹¹ and *Stalgren*¹⁰² found delayed transit time and improved intestinal absorption in their experiments, explaining that this was because the cephalad peristalsis in the reversed segment delayed transit in the proximal bowel and contributed to absorption of nutrients. Up to 1978, 29 clinical cases were reported⁵ since *Gibson*³⁴ presented the first effective case in 1962.

Disadvantages of the approach are possible fatal obstruction dependent on the beazer formation, its length and individual variables, the risk of new processes added to the shortened small intestine and the impossibility of preventing bacterial ascent⁵⁵.

3. Isoperistaltic segment insertion

*Torbey*¹⁰⁷ and *Singleton*¹⁰¹ described this approach, believing that the isopepristaltic "tonic" segment would slow the transit time. This technique has never been clinically used.

The disadvantages are the need for application of processes to the residual small intestine and unavoidable ascending infection.

4. Colonic interposition

In this method, the colon is interposed in part of the jejunum⁴⁷ or ileum⁴⁶. *Garcia*³⁰ clinically used it.

Antiperistaltic colonic interposition was presented by *Trinkle*¹⁰⁹, *Carner*¹⁵ and *Lloyd*⁵⁹. Its effect is controversial.

Complications, including fatal bowel obstruction, have been reported⁵⁹. In cases with removed ileocecal junction, retrogressive infection is inevitable.

5. Interposed gastric tube

Interposed gastric tube was reported by *Gerwig* et al.³³. A segment of the stomach was fashioned into a tube and interposed antiperistaltically. No clinical use has been found.

6. Recirculating loops

This approach was an attempt to make pass intestinal contents repeatedly through the intestinal tube by forming a loop at part of the small intestine, so as to prolong contact time with the mucosa and thereby improve absorption²². In experiments, some found it effective⁸³, others found it ineffective^{2,12}. It has been reported as clinically effective^{13,62}.

However, it has only historical relevance, in view of the procedural complexity and the frequency of complications¹².

7. Lengthened intestine

In intestinal adaptation the increase is in terms of diameter, not length of the tubular cavity. Thus the intestine is lengthened, to double transit time, by dividing the residual intestine lengthwise into two parts which are then closed and connected, doubling transit time although the absorptive surface area remains unchanged⁷. Clinical trials reported by *Boeckman* et al.⁹ show remarkable efficacy.

This is an interesting idea although any failure in such extensive manipulation of the valuable intestine would be irreparable.

8. Induction of neomucosa

This is based on the idea of creating a new absorptive surface area in the intestinal tube. The small intestine is incised lengthways and sutured to the surface of the colonic serosa. It is

shown that a new mucosa is formed at this site and that enterocytes in this area contain the normal enzyme system⁸⁹. This technology is not used clinically.

9. Electrical pacing

*Collin and Kelly*¹⁷⁾ took up this method. Electrical stimulation increases slow wave frequency in the intestinal tube, creating a larger absorptive capacity. This was said to affect not only retrograde, but also forward pacing³⁶⁾; however it is not clinically used.

10. Intestinal transplantation

Some clinical cases have been reported^{58,81)}. The survival period was a maximum 76 days. In the near future, the situation of parenteral nutrition vs. transplantation may become that of renal dialysis vs. renal transplantation.

Length of Resected Intestine

Dogs from whom 80% of intestine was resected together with the left ileocecum (group B) initially lost weight, then slowly regained it. By 13 weeks they had increased their preoperative weight by 50% under normal conditions of nutrition, with glossy fur and wet nose. Even the younger dogs were thought capable of survival and growth. On the other hand, dogs undergoing 90% resection (group A) died early and seemed difficult of survival without positive management, including hyperalimentation. *Schiller*⁹⁶⁾ reported that experimental dogs barely withstood 90% intestinal resection, dying within 7 weeks. Other investigators^{12,15)} obtained similar results; *MacBy*⁶²⁾ found some dogs surviving 85% resected small intestine. *Haymond*⁴⁴⁾ first reported 50% to be the safety limit, taken from statistical analysis of 257 cases. This limit has been raised with the progress of intravenous alimentation. *Jordan*⁴⁸⁾ regarded 50% or less resection as moderate, 50-80% extensive and 80% or more as radical, finding that in the radical group, most survived, though 23 of 44 animals were morbid. Massive bowel resection was defined as 2/3 or greater¹⁰⁵⁾ (2m or more)⁵⁾ resection of the small intestine in adults and a residual small intestine of 75 cm or less in children⁸⁷⁾, a length corresponding to 50-70% or more resection of the small intestine.

Surviving cases with resection of the entire small intestine have been reported^{10,20)}, since living cases with a few inches of residual small intestine were presented^{3,16,66,68,108,112)} and parenteral nutrition was advocated by *Wilmore and Dudrick* in 1968¹¹⁴⁾, that is, survival was proved possible to some extent^{10,97)} even with complete resection, depending on the treatment. These cases, however, were assumed to be difficult of lengthy survival, owing to liver changes resulting from hyperalimentation^{63,89)} as well as from the massive bowel resection^{23,41,78)}.

In view of the above, intestinal transplantation may be one of the answers.

Intestinal Adaptation

In the 80% small intestine resection group (group B), the mortality was zero% 5 weeks after operation, 12.5% at 10 weeks and zero over the remaining period of observation (11 to 15 weeks). The body weights decreased by 13% early after operation returning to preoperative levels in 2.5 to 4.5 weeks (3.5 weeks on average). *Pullan*⁸²⁾ divided intestinal adaptation into three stages; immediate postoperation (Stage I); recovery/adaptation (Stage II), characterized by frequent diarrhea, weight loss and shortened transit time; and stabilized (Stage III). The animals

in group B rapidly passed through the first and second stages and entered the final stage by 5 weeks after operation.

On the other hand, animals with 80% small intestine and ileocecum resection (group C) had cumulative mortality rates of 20%, 40% and 50% at 5, 10 and 15 weeks, respectively. The weight loss reached 22%, remaining 7%, on average, even in those dogs that survived beyond 15 weeks. The stool remained watery at 15 weeks and was first semisolid at 25 weeks, exceeding the period of observation. This shows a more prolonged *Pullan's* second stage in this group than in group B and suggests that the ileocecum plays an important role in intestinal adaptation.

Intestinal adaptation after massive bowel resection, completed in Stage III via Stage I and II, has been morphologically and physiologically investigated. In morphology, the growth of villi^{28,61,72,74,80,95,98,115}, the increased depth of crypts^{74,113,117}, the increased diameter of the tubular cavity^{50,95,115}, and the growth of microvilli^{52,90} were presented, and are acceptable, with some objections^{25,54}. In this study, clear differences were not found microscopically in living dogs in each group after 15 weeks.

Shortened transit time and accentuated migrating myoelectric complex are regarded as intestinal physiological adaptations⁵⁰. In *Pullan's* second stage, therefore, physiologic diarrhea should be taken into consideration as well as that hitherto regarded as a result of gastric hypersecretion²⁹, disturbance of lipid absorption⁷⁹ or colon irritation caused by failure of bile salt reabsorption^{111,117}, in cases of resected ileocecal valve.

The Role of the Ileocecal Valve

Clear differences were observed in mortality, weight curves, stool assessment and blood chemistry between the 80% small intestine resection (group B) and 80% small intestine/ileocecum resection groups (group C). Group B showed a significant difference in mortality (12.5%) in comparison with group C (50%) while in group C the weight loss was 22% with less likelihood of recovering it (7% loss remaining even in survivors beyond 15 weeks). In these experimental models, these results can be regarded as dependent on the presence or absence of the ileocecal valve, even though in group B preserved 10 cm of the terminal ileum was preserved, where as group C kept 10 cm of the jejunum instead.

In the digestive tract, digestion and absorption are efficiently performed via the constriction mechanism, that is, modulation of content transmission and prevention of reflux via valve or sphincter in situ. Constriction activity shows some differences between the oral and anal sides, in particular at the esophagocardium and ileocecum. The constriction action is strong at these sites.

In the ileocecum, the constriction mechanism is comprised of the ileum, running into the boundary of the cecum, and the ascending colon, whose diameter is about three times that of the ileum. Valve function is extremely excellent in this area, with a transition pressure of 20 cm H₂O or less and a reflux prevention pressure of 40 cm H₂O or more¹¹⁸.

*Kellogg*⁵¹, one of the first surgeons to investigate the ileocecal valve, said that it "not only prevents reflux of material from the colon into the small intestine but also regulates the movement

of material from the small intestine into the colon (in a manner quite analogous to the action of the pylorus in passing digested food from the stomach into the small intestine)".

*Stalgren*¹⁰²⁾ described "jejunal hurry" due to unrestricted jejunal motility in resection of the ileum including the ileocecum and *Singleton et al.*¹⁰¹⁾ indicated that neither 80% small intestine resection nor ileocecum resection resulted in differences in absorption or transit, but the combination of both resections led to marked abnormality of absorption and rapid transit. *Reid*⁸⁴⁾ studied 90% small intestine resection and valvotomy in experimental animals and found higher mortality and less weight recovery in the valvotomy group.

In 17 clinical cases, *Cosner*¹⁹⁾ found that patients with the ileocecal valve remaining had transient and moderate malabsorption whereas those with the ileocecum resected showed severe and permanent malabsorption.

*Ricotta*⁸⁸⁾, *Weser*¹¹¹⁾, *Ogilvie*⁷⁶⁾ and *Kalser*⁴⁹⁾ pointed out short transit in resection of the ileocecal valve, which accurately reflected the modulation of transit or flow through the small intestine by the valve. The one problem is whether such regulation comprises merely the retardance of nutrient passage, that is, whether the valve merely interrupts the flow, or whether it functions as a true valve or sphincter.

It is noteworthy that the ileocecal valve not only prolongs transit but also opens and closes repeatedly without small intestinal stasis²⁴⁾. The valve opens and shuts not only with changes in internal pressure, which is most important, but in reflecting the pattern of more proximal activity, as does the esophagocardium¹⁰⁶⁾.

The function of the ileocecal valve is effective in preventing material rich in bacteria from refluxing from the colon into the small intestine.

Richardson and Griffen^{39,85)} found 76 times the bacterial colonies and severe weight loss in dogs with resected ileocecum and believed that the loss was caused by colonization in the small intestine resulting from the inflow of bacteria. Similar findings were presented by *Gazer*³²⁾, *Mallory*⁶⁵⁾, *Cumming*²¹⁾ and *Mitchell*⁷⁰⁾. Colonization and shortened transit time⁵³⁾, or the bacterial contamination itself⁷¹⁾, might prevent absorption. Colonization in the residual small intestine was reported to have increased deconjugated bile acid and to have promoted the inhibition of protein, carbohydrate, electrolyte, vitamin B₁₂ and folic acid absorption, as well as to have encouraged bacterial diarrhea^{11,111,117)}.

As described above, the ileocecal valve functions in the regulation of transit and as a bacterial barrier. These are important functions, particularly in massive bowel resection.

*Reid*⁸⁴⁾ stated that the clinically critical length for survival was 40 cm of the small bowel if the ileocecal valve was removed. *Benson*⁶⁾ described that if the valve was preserved, 30 cm of the small intestine was sufficient for survival and less than 30 cm made survival difficult; if the valve was not preserved, however, even 30 cm of the intestine was not enough for survival. *Wilmore*¹¹⁶⁾ reviewed English references and reported that, of 50 neonates with 75 cm or less postoperative residual small intestine, 5 with 15 to 30 cm of intestine and no ileocecal valve died but 8 of 15 with the same length of the intestine and the valve survived. All neonates survived, regardless of ileocecum resection, in whom at least 40 cm of the small intestine was preserved.

In addition, *Gil-Verner*³⁵⁾ adjudged the ileocecal valve area "an ideal substitute for ureter and bladder" in urological surgery; *Lee*⁵⁶⁾ substituted the valve area for the stomach with good results, and *Endo*²⁶⁾ succeeded in using it in biliary atresia. Judging from the above, the valve seems to be extremely valuable in reflux prevention and flow regulation.

Considering that the valve not only works anatomically but is subject to nervous control^{27,31)} and may be affected by gastrointestinal hormones, particularly secretin and gastrin⁴⁾, it may seem strange that it functions well when transplanted to other sites. However, this can be explained on the basis of internal pressure changes, which is the most important factor in the function of the valve.

Evaluation of Artificial Intestinal Valves

Several differences were found between groups C and E (combined ileocecum resection and artificial valve graft): mortality, 50% in group C, 25% in group E; initial weight loss, 22% in group C and 14% in group E. The initial weight loss was found in both groups, to different extents, but weight did not return to the preoperative value (remaining 7% below preoperative) in 15 weeks, and there was no sign of increase, in group C, whereas it increased slowly and returned to the preoperative average 5.5 (2.5 to 8) weeks after operation in group E. Further, the stool 15 weeks after operation was watery in group C, while solid in group E.

In terms of laboratory data, the artificial intestinal valve graft group showed better results for serum protein, albumin, cholesterol and triglyceride. This means that the artificial valve graft clearly promoted intestinal adaptation.

This is probably partly because the artificial valve regulated the flow of digested material and prolonged the transit time, and partly because it prevented colonization in the small intestine. The artificial valve graft was found to have the same effect as the preserved ileocecal valve.

*Stahlgren*¹⁰³⁾ pointed out that transit time was prolonged merely by obstruction. The ileocecal valve opens and closes mainly owing to changes in internal pressure, with a transition pressure of 20 cm H₂O or less and a reflux pressure of 40 cm H₂O, preventing stasis at the proximal (that is, the small intestinal) side. The artificial intestinal valve used in the present study consisted of one layer each of circular and longitudinal muscles, both sides of which were covered by mucosa. The transit (average 26.4 cm H₂O) and reflux (average 44.5 cm H₂O) pressures were almost equal to those of the ileocecal valve^{75,94)}.

Radiologic examination in clinical cases proved that the prosthesis did not cause obstruction,

Table 5. Valve or sphincter formation after massive bowel resection

Glassman	1942	Hidalgo	1973
Stahlgren	1964	Grosfeld	1974
Schiller	1967	Careskey	1981
Ackroyd	1969	López-Pérez	1981
Waddel	1970	Ricotta	1981
Grier	1971	Diego	1982
Richardson	1972		

but opened and closed⁴³⁾. It may have satisfied the requisite of *Ricotta*⁸⁸⁾, "prevention of stasis in the small intestine".

In 1913, *Kellogg*⁵¹⁾ attempted to regulate digestive flow and prevent reflux from the colon to the small intestine when the ileocecal valve was removed in intestinal surgery. In 1942, *Glassman*⁸⁷⁾ first used a substitute for the valve in massive intestinal resection.

*Satomura*⁹³⁾ listed four essential functions for valve mechanisms intervening in the enteron; (1) passes material in the peristaltic direction under a certain pressure, (2) prevents reflux in the antiperistaltic direction up to a certain pressure and allows reflux over that pressure, (3) prevents organic stenosis, (4) maintains narrower tubular cavity on the proximal side than on distal side of the valve or presents no caliber change. Additional important conditions are (5) a constant direction of digestive flow at a steady state, (6) long-term competence⁹²⁾, and in massive intestinal resection, (7) no manipulation of the residual small intestine. The requirement described in (4) should be strictly investigated because massive resection will lead to expansion of the cavity of the residual intestine, particularly the upper tube, as a result of intestinal adaptation.

Glassman's artificial valve is a mucosal intussuscepted valve placed 20 cm proximal to the ileocolostomy site. Unfortunately, the mucosal valve shows inconstant direction because it is not supported by the muscle layer but contracts without long-term competence finally becoming merely stenotic. In addition to these, the valve presents the following disadvantages: placement in the residual intestine probably causes colonization in the area distal to the valve and the precious intestine is likely to be damaged.

Here, pioneering trials will be reviewed. (Table 5) *Stahlgren*¹⁰³⁾ used "jejunal pleating" for plication of the partial jejunum and partial stenosis. This result cannot be truly called a valve.

*Schiller and DiDio*⁸⁶⁾ invented a valve mechanism in which the serosa and longitudinal muscular layer were ablated and the circular muscle was preserved. Obviously, the circular muscle plays the primary role of the sphincter. Raised tonus of the muscle causes contraction and closure of the tube; the contracted longitudinal muscle shortens the longer diameter of the intestine and leads to relative expansion of its inner diameter. Ablation of the longitudinal muscular layer facilitates these processes. Another key point of the sphincter action is passive opening by raised internal pressure. This may become a problem with *Schiller's* valve.

*Waddel et al.*¹¹⁰⁾ performed jejunocolostomy and anti-telescoping anastomosis in 3 clinical cases. Two showed decreased frequency of diarrhea and weight gain, whereas one needed valve resection owing to intestinal obstruction.

The valve was aborad, and is thought to be better for transit in the anti-peristaltic direction than in the peristaltic direction. It is feared that bowel obstruction will inevitably occur. The obstruction may cause delay in transit, which decreases absorption¹⁰³⁾. The valve may be incompetent for shifting microorganisms upward.

*Grier*³⁸⁾ formed a nipple valve of antiperistaltic direction in the residual small intestine of dogs with 80% intestinal resection. The valve is aborad, like *Waddel et al.*'s, and merely seems to accelerate obstruction.

*Hidalgo*⁴⁵⁾ re-investigated a mucosal valve similar to *Glassman's* and regarded it as effective. *Suruga*,¹⁰⁴⁾ and coworkers, a Japanese surgeon, operated in a clinical case for which there was no long-term follow-up report; even his co-worker was doubtful of the efficacy of the mucosal valve.

In resection of the small intestine and 50% of ileocecum, *Richardson*⁸⁶⁾ prepared and bacteriologically investigated an antiperistaltic reversed segment (6 cm long), a *Schiller's* sphincter and an *Ackroyd's* mucosal valve¹⁾. He reported that the sphincter and valve were effective.

*Grosfeld*⁴⁰⁾ resected a 2.5 cm circumferential segment of longitudinal muscle and anastomosed both sides to prepare a valve. This was a type of mucosal valve and *Schiller* sphincter.

*Careskey*¹⁴⁾ first used small animals in his experiments; this permitted the use of large numbers of animals. However, the valve itself was of the *Grier* type and its inherent defects remained.

*Lopez-Perez*⁶⁰⁾ investigated an ileal intussuscepted valve for use after massive bowel resection. A nit comprising 1 cm and 1.5 cm ablations of seromuscular layers connected to the ends of a 3-3.5 cm of an ileal segment was intussuscepted in the distal (or intestinal) direction and sutured. Thus, the valve consisted of two layers of muscle, but the continuity of the muscular layers was broken at the base of the valve.

*Riccota*⁸⁸⁾ presented a substituent for the ileocecal valve that was formed as a 4 cm nipple valve by folding outward one end of the small intestine (after ileocecum resection) and intussuscepting and inosculating it into the colon. He reported the results of a clinical case and experiments involving dogs, stating that the valve was effective against mortality and weight loss. Conical in structure, the valve is well-designed to prevent divarication, a defect of conventional conical valves⁷⁷⁾, but requires a bit of improvement in ease of causing stenosis.

As complication, valve disruption was found in one puppy (Fig. 9). The puppy grew favorably, however, regaining its original weight in three weeks and 170% of that weight in 15 weeks. This case showed the high efficacy of the artificial valve. It was not known when the valve was disrupted. If it occurred early, earlier aid in intestinal adaptation would lead to better results. If so, the present view with regard to postoperative management should be changed. This valve is harder to break than previous conical valves, because of the monolayer muscle in the valval lip. However strict care should be taken in handling the valve, such as when affixing it to the mesentery.

Location of Artificial Valve

No conclusions can be drawn because the groups contained only a few animals (n=3). However, two of the three animals in group D (jejunal valve fitting) died at *Pullan* Stage I (18th day); one survivor lost up to 38% of its weight and did not regain it (-25%) even 10 weeks after the operation, although the artificial valves were placed in the residual enteron in both group D and E. This forces us to discuss the location of the valve.

Although possible colonization in the section between the intestine distal and the valve decreased the effective absorption area, the length of the section was only 5 cm. Are such effects found in a postoperative period as short as 18 days? It is also difficult to believe that partial ablation of the intestinal muscle layer caused mixing disorder. Ultimately, the only explanation

may be obstruction at the location of the valve.

Conclusion

As described in the previous paper, ileocecal lesions were enucleated from patients (as many as 9 of 10) undergoing massive bowel resection. These statistics induced us to apply artificial valves to this pathology.

For experiments, 46, 3-6 kg young dogs were divided into 5 groups ;

90% resection group (n=3)

80% resection group (n=8)

80% resection plus ileoceccal valve resection (n=10)

80% resection with ileocecal valve resection plus jejunal valve fitting* (n=3)

80% resection with ileoceccal valve resection plus colonic valve fitting* (n=8)

Mortality, weight, stool appearance, blood chemistry, morphology and clinical observations were obtained.

The 80% resection group showed good postoperative adaptation, while the 80% resection plus ileocecal valve resection group showed poor adaptation, results which seemed to depend on the presence of the ileocecal valve.

Significant differences were found in weight, mortality, stool appearance and blood chemistry between the artificial valve (colonic) fitting group and the ileocecal valve resection group.

The artificial intestinal valve as well as the ileocecal valve played an important role after massive bowel resection.

In massive resection, the ileocecal valve should be preserved to the utmost.

The artificial valve is useful in cases of ileocecum resection.

References

- 1) Ackroyd FW, Giles G, et al: Ileal mucosal valve to prevent reflux at the ileorectal anastomosis in the colon exclusion operation for hepatic encephalopathy. *Surg Forum* **20**: 356-357, 1969.
- 2) Altman DP, Ellison EH: Massive intestinal resection ; Inadequacies of the recirculating loop. *Surg Forum* **16**: 365-367, 1965.
- 3) Anderson CM: Long term survival with six inches of small intestine. *Br Ned J* **543**: 419-422, 1965.
- 4) Balfour TW: The ileocecal junction. *Alimentary sphincters and their disorders*. 193-199. Macmillan publishers LTD. London. 1981.
- 5) Barros AAB, Parks TG, et al: The problems of massive small bowel resection and difficulties encountered in management. *Postgrad Med J* **54**: 323-327, 1978.
- 6) Benson CD: The surgical and metabolic aspects of massive small bowel resection in the newborn. *J pediatr Surg* **2**: 227-240, 1967.
- 7) Bianchi A: Intestinal loop lengthening-A technique for increasing small intestinal length. *J pediatr Surg* **15**: 145-151, 1980.
- 8) Binnington HB, Sumer H, et al: Functional characteristics of surgically induced jejunal neomucosa. *Surgery* **75**: 805-810, 1974.
- 9) Boeckman CR, Traylor R: Bowel lengthening for short gut syndrome. *J pediatr Surg* **16**: 996-997, 1981.

* an artificial valve formed by means of intussusception.

- 10) Bordos DC, Cameron JL : Successful long-term intravenous hyperalimentation in the hospital and at home. *Arch Surg* **110** : 439-441, 1975.
- 11) Borgstrom B, Lundh G, et al : The site of absorption of conjugated bile salt in man. *Gastroenterology* **45** : 229-238, 1963.
- 12) Budding J, Smith CC : Role of recirculating loops in the management of massive resection of the small intestine. *Surg Gynecol Obstet* **125** : 243-249, 1967.
- 13) Camprodon R, Guerrero JA, et al : Shortened small bowel syndrome; Mackby's operation. *Am J Surg* **129** : 585-586, 1975.
- 14) Careskey J, Weber TR, et al : Ileocecal valve replacement. *Arch Surg* **116** : 618-622, 1981.
- 15) Carner DV, Raju S : Failure of antiperistaltic colon interposition to ameliorate short-bowel syndrome. *Am Surgeon* **47** : 538-540, 1981.
- 16) Clayton BE, Cotton DA : A study of malabsorption after resection of the entire jejunum and the proximal half of the ileum. *Gut* **2** : 18-22, 1961.
- 17) Collin J, Kelly KA, et al : Absorption from the jejunum is increased by forward and backward pacing. *Br J Surg* **66** : 489-492, 1979.
- 18) Cortot A, Fleming CR, et al : Improved nutrient absorption after cimetidine in short-bowel syndrome with gastric hypersecretion. *N Engl J Med* **300** : 79-80, 1979.
- 19) Cosnes J, Gendre JP, et al : Role of the ileocecal valve and site of intestinal resection in malabsorption after extensive small bowel resection. *Digestion* **18** : 329-336, 1978.
- 20) Craig RM, Neumann T, et al : Severe hepatocellular reaction resembling alcoholic hepatitis with cirrhosis after massive small bowel resection and prolonged total parenteral nutrition. *Gastroenterology* **79** : 131-137, 1980.
- 21) Cumming JH, James WP, et al : Role of the colon in ileal resection diarrhea. *Lancet* **1** : 344-347, 1973.
- 22) Davis HC, Wolcott MW, et al : Intestinal recirculation as an aid to absorption ; An experimental study. *Arch Surg* **79** : 597-599, 1959.
- 23) Derblom H, Nylander G, et al : Absorption and liver function following extensive resection of the small intestine in the rat. *Acta Chir Scand* **123** : 57-66, 1962.
- 24) DiDio LJA, Carril CF : Observacoes sobre o mecanismo do piloro ileo-cecocolico em individuo vivo com a papila ileo-ceco-colica exteriorizada. *Rev Brasil Gastroent* **6** : 67-96, 1954.
- 25) Dowling RH, Booth CC : Functional compensation after small bowel resection in man. *Lancet* **2** : 146-147, 1966.
- 26) Endo M, Nakano M, et al : The biliary cutaneous conduit using ileocecal segment for the prevention of reflux cholangitis in biliary atresia. [JPN] *Jap J Pediatr Surg* **13** : 749-754, 1981.
- 27) Farrar JF, Zfass AM : Small intestinal motility. *Gastroenterology* **52** : 1019-1037, 1967.
- 28) Flint JM : The effect of extensive resections of the small intestine. *Johns Hopkins Med J* **23** : 127-144, 1912.
- 29) Frederick PL, Craig TV : The effect of vagotomy and pyloroplasty on weight loss and survival of dogs after massive intestinal resection. *Surgery* **56** : 135-143, 1964.
- 30) Garcia VF, Templeton JM, et al : Colon interposition for the short bowel syndrome. *J Pediatr Surg* **16** : 994-995, 1981.
- 31) Gazet JC, Jarrett RJ : The ileocaeco-colic sphincter. *Br J Surg* **51** : 368-370, 1964.
- 32) Gazet JC, Kopp F : The surgical significance of the ileocecal junction. *Surgery* **56** : 565-573, 1964.
- 33) Gerwig WH, Ghaphery A : Experimental attempt to delay alimentary transit after small bowel exclusion. *Arch Surg* **87** : 34-41, 1963.
- 34) Gibson LD, Carter R, et al : Segmental reversal of small intestine after massive bowel resection. *JAMA* **182** : 952-954, 1962.
- 35) Gil-Vernet JM : The ileo-colic segment in urologic surgery. *J Urol* **94** : 418-426, 1965.
- 36) Gladen HE, Kelly KA : Enhancing absorption in the canine short bowel syndrome by intestinal pacing. *Surgery* **33** : 281-286, 1980.
- 37) Glassman JA : An artificial ileocecal valve. *Surg Gynecol Obstet* **74** : 92-98, 1942.
- 38) Grier RL, Nelson AW, et al : Experimental sphincter for short-bowel syndrome. *Arch Surg* **102** : 203-208, 1971.
- 39) Griffen WO, Richardson JD, et al : Prevention of small bowel contamination by ileocecal valve. *South Med J* **64** : 1056-1058, 1971.
- 40) Grosfeld JL, Cooney DR, et al : Experimental ileocecal valve replacement in puppies. *Surg Forum*

- 25 : 364-365, 1974.
- 41) Gupta MC, Neale G, et al : Liver structure and function following small bowel resection. *Gut* **14** : 438-443, 1973.
 - 42) Hammer JM, Seay PH, et al : The effect of antiperistaltic bowel segments on intestinal emptying time. *Arch Surg* **79** : 537-541, 1959.
 - 43) Hanafusa T, Satomura K : A clinical study on artificial intestinal valve. *Arch Jpn Chir* **55** : 202-211, 1986.
 - 44) Haymond HE : Massive resection of the small intestine ; An analysis of 257 collected cases. *Surg Gynecol Obstet* **61** : 693-705, 1935.
 - 45) Hidalgo F, Cortes ML, et al : Intestinal muscular layer ablation in short-bowel syndrome. *Arch Surg* **106** : 188-190, 1973.
 - 46) Hatcher NE, Salzberg AM : Pre-ileal transposition of colon to prevent the development of short bowel syndrome in puppies with 90 percent small intestinal resection. *Surgery* **70** : 189-197, 1971
 - 47) Hatcher NE, Mendez-Picon G, et al : Prejejunal transposition of colon to prevent the development of short bowel syndrome in puppies with 90 per cent small intestine resection. *J Pediatr Surg* **8** : 771-777, 1973.
 - 48) Jordan PH, Stuart JR, et al : Radical small bowel resection ; Report of two cases. *Am J Dig Dis* **3** : 823-843, 1958.
 - 49) Kalser MH, Roth JLA, et al : Relation of small bowel resection to nutrition in man. *Gastroenterology* **38** : 605-615, 1960.
 - 50) Kato H : Rat small intestinal motility after massive bowel resection. *Arch Jpn Chir* **52** : 690-702, 1983.
 - 51) Kellogg : Surgery of the ileocecal valve. *Surg Gynecol Obstet* **17** : 563-576, 1913.
 - 52) Kisaka Y : Effect of an artificial intestinal valve on intestinal adaptation in the rat. *Arch Jap Chir* **48** : 261-288, 1979.
 - 53) Kremen AJ, Linner JH, et al : An experimental evaluation of the nutritional importance of proximal and distal small intestine. *Ann Surg* **140** : 439-448, 1954.
 - 54) Lansky Z, Dodd RM, et al : Regeneration of the intestinal epithelium after resection of small intestine in dogs. *Am J Surg* **116** : 8-12, 1968.
 - 55) Leading article : Reversed loops in the short gut syndrome. *Br Med J* **28** : 709-710, 1975.
 - 56) Lee CM : Transposition of a colon segment as a gastric reservoir after total gastrectomy. *Surg Gynecol Obstet* **92** : 456-465, 1951.
 - 57) Leonard AS, Levine AS, et al : Massive small-bowel resections. *Arch Surg* **95** : 429-435, 1967.
 - 58) Lillehei RC, Idezuki Y, et al : Transplantation of stomach, intestine and pancreas ; Experimental and clinical observations. *Surgery* **62** : 721-741, 1967.
 - 59) Lloyd DA : Antiperistaltic colonic interposition following massive small bowel resection in rats. *J Pediatr Surg* **16** : 64-69, 1981.
 - 60) López-Pérez GA, Martínez AJ, et al : Experimental antireflux intestinal valve. *Am J Surg* **141** : 597-600, 1981.
 - 61) Loran MR, Althansen TL : Hypertrophy and changes in cholinesterase activities of the intestine, erythrocytes and plasma after "partial" resection of the small intestine of the rat. *Am J Physiol* **193** : 516-520, 1958.
 - 62) MacBy MJ, Richards V, et al : Methods of increasing the efficiency of residual small bowel segments. *Am J Surg* **109** : 32-38, 1965.
 - 63) Maini B, Blackburn GL, et al : Cyclic hyperalimentation ; An optimal technique for preservation of visceral protein. *J Surg Res* **20** : 515-525, 1976.
 - 64) Mall F : Reversal of the intestine *Johns Hopkins Hosp Rep* **1** : 93-110, 1896.
 - 65) Mallory A, Savage D, et al : Patterns of bile acids and microflora in the human small intestine. II, Microflora. *Gastroenterology* **64** : 34-42, 1973.
 - 66) McClenahan JE, Fisher B : Physiologic effect of massive small intestinal resection and colectomy. *Am J Surg* **79** : 684-688, 1950.
 - 67) Mckelvey STD : Gastric incontinence and postvagotomy diarrhea. *Br J Surg* **57** : 741-747, 1970.
 - 68) Meyer HW : Sixteen-year survival following extensive resection of small and large intestine for thrombosis of the superior mesenteric artery. *Surgery* **51** : 755-759, 1962.
 - 69) Meyers WC, Jones RS : Hyperacidity and hypergastrinemia following extensive intestinal resection. *World J Surg* **3** : 539-544, 1979.
 - 70) Mitchell J, Zuckerman L, et al : The colon influences ileal resection diarrhea. *Dig Dis Sci* **25** : 33-41,

1980.

- 71) Mollin DL, Booth CC, et al: The absorption of vitamin B₁₂ in control subjects in Addisonian pernicious anemia and in the malabsorption syndrome. *Brit J Haemat* **3**: 412-418, 1957.
- 72) Monari U: Experimentelle Untersuchungen über die Abtragung des Magens und des Dünndarms beim Hunde. *Beitr Klin Chir* **16**: 479-492, 1896.
- 73) Murphy JP, King DR, et al: Treatment of gastric hypersecretion with cimetidine in the short-bowel syndrome. *N Engl J Med* **300**: 80-81, 1979.
- 74) Nygaard K: Resection of the small intestine in rats. III Morphological changes in the intestinal tract. *Acta Chir Scand* **133**: 233-248, 1967.
- 75) Ohnishi S: A new artificial intestinal valve in the dog; Its comparative function with the intussuscepted conical valve and the mucosal valve. *Arch Jap Chir* **48**: 173-187, 1979.
- 76) Ogilvie WH: Preservation of ileocecal sphincter in resection of the right half of the colon. *Br J Surg* **19**: 8-24, 1931.
- 77) Perl JI: Intussuscepted conical valve formation in jejunostomies. *Surgery* **25**: 297-299, 1949.
- 78) Peura DA, Stromeyer FW, et al: Liver injury with alcoholic hyaline after intestinal resection. *Gastroenterology* **79**: 128-130, 1980.
- 79) Pinter KG, Hyman H, et al: Fat and nitrogen balance with medium chain triglycerides after massive intestinal resection. *Am J Clin Nutr* **22**: 14-20, 1969.
- 80) Porus RL: Epithelial hyperplasia following massive small bowel resection in man. *Gastroenterology* **48**: 753-757, 1965.
- 81) Preston FW, Macalalad F, et al: Survival of homografts of the intestine with and without immunosuppression. *Surgery* **60**: 1203-1210, 1966.
- 82) Pullan JM: Massive intestinal resection. *Proc Roy Soc Med* **52**: 31-37, 1959.
- 83) Redmond DC, Muraki T, et al: Effects of recirculating jejunal loops on absorption and transit after massive bowel resection in dogs. *Surg Forum* **15**: 291-292, 1964.
- 81) Reid I: The significance of the ileocecal valve in massive resection of the gut in puppies. *J Pediatr Surg* **10**: 507-510, 1975.
- 85) Richardson JD: The importance of the ileocecal valve in intestinal absorption. *Texas Rep Biol Med* **28**: 408-409, 1970.
- 86) Richardson JD, Griffin WO: Ileocecal valve substitutes as bacteriologic barriers. *Am J Surg* **123**: 149-153, 1972.
- 87) Rickham PP: Massive small intestinal resection in newborn infants. *Ann Roy Coll Surg Engl* **41**: 480-492, 1967.
- 88) Ricotta J, Zuidema GD, et al: Construction of an ileocecal valve and its role in massive resection of the small intestine. *Surg Gynecol Obstet* **152**: 310-314, 1981.
- 89) Rodgers BM, Hollenbeck J, et al: Intrahepatic cholestasis with parenteral alimentation. *Am J Surg* **131**: 149-155, 1976.
- 90) Saijo H: Pathophysiological studies after massive resection of the small intestine. [*JPN*] *Mieigaku* **21**: 109-138, 1977.
- 91) Sako K, Blackman GE: The use of a reversed jejunal segment after massive resection of the small bowel. *Am J Surg* **103**: 202-205, 1962.
- 92) Satomura K, Kisaka Y, et al: Intestinal valves by telescoping anastomosis and non-transected muscular valve. *Arch Jap Chir* **48**: 21-32, 1979.
- 93) Satomura K, Tanaka K: Bile duct reconstruction by jejunum-interposition with the artificial intestinal valve (non-transected muscular type) for the treatment of the congenital bile duct atresia. [*JPN*] *Gekachiryō* **41**: 563-567, 1979.
- 94) Satomura K, Hanafusa T, et al: Experimental and clinical studies of an artificial intestine valve. [*JPN*] *Gekachiryō* **47**: 191-198, 1982.
- 95) Scheffan M, Galli SJ, et al: Intestinal adaptation after extensive resection of the small intestine and prolonged administration of parenteral nutrition. *Surg Gynecol Obstet* **143**: 757-762, 1976.
- 96) Schiller WR, DiDio LJA: Production of artificial sphincters; Ablation of the longitudinal layer of the intestine. *Arch Surg* **95**: 436-442, 1967.
- 97) Sheldon GF: Role of parenteral nutrition in patients with short bowel syndrome. *Am J Med* **67**: 1021-1029, 1979.
- 98) Shin CS, Chaudhry AG, et al: Early morphologic changes in the intestine following massive resection

- of the small intestine and parenteral nutrition therapy. *Surg Gynecol Obstet* **151**: 246-250, 1980.
- 99) Singleton AO, Rowe EB: Peristalsis in reversed loops of bowel. *Ann Surg* **139**: 853-857, 1954.
- 100) Singleton AO, Kurrus FD, et al: The increasing of absorption following massive resections of bowel by means of antiperistaltic bowel segments as measured by radioiodine fat absorption studies. *Ann Surg* **154**: 130-132, 1961.
- 101) Singleton AO, Redmond DC, et al: Ileocecal resection and small bowel transit and absorption. *Ann Surg* **159**: 690-694, 1964.
- 102) Stalgren LH, Umana G, et al: A study of intestinal absorption in dogs following massive small intestinal resection and insertion of an antiperistaltic segment. *Ann Surg* **156**: 483-492, 1962.
- 103) Stahlgren HC, Roy RH, et al: A mechanical impediment to intestinal flow: Physiological effects on intestinal absorption. *JAMA* **187**: 41-44, 1964.
- 104) Suruga K, Hirai Y, et al: Massive resection of small intestine in the newborn. [*JPN*] *Gekachiryō* **31**: 289-296, 1974.
- 105) Symposium: The 74th annual meeting of the Japan Surgical Society [*JPN*] *J Jpn Surg Soc* **76**: 216-239, 1975.
- 106) Thomas PA, Mann CV: Alimentary sphincters and their disorders. 227-232. Macmillan Publishers LTD. London, 1981.
- 107) Torbey K, Waddell WR: Function of the colon after removal of analsphincters and replacement by denervated ileal segments. *Ann Surg* **154**: 424-431, 1961.
- 108) Trafford HS: The outlook after massive resection of small intestine with a report of two cases. *Br J Surg* **44**: 10-14, 1956.
- 109) Trinkle JK, Bryant LR: Reversed colon segment in an infant with massive small bowel resection; A case report. *J Kent Med Ass* **65**: 1090-1091, 1967.
- 110) Waddell WR, Kern F, et al: A simple jejunocolic "valve" ; For relief of rapid transit and the short bowel syndrome. *Arch Surg* **100**: 438-444, 1970.
- 111) Weser E: The management of patients after small bowel resection. *Gastroenterology* **71**: 146-150, 1976.
- 112) West ES, Montague JR, et al: Digestion and absorption in a man with three feet of small intestine. *Am J Dig Dis* **5**: 690-692, 1939.
- 113) Williamson RCN: Intestinal adaptation; Structural, functional and cytokinetic changes. *N Engl J Med* **298**: 1393-1402, 1978.
- 114) Wilmore DW, Dudrick SJ: Growth and development of an infant receiving all nutrients exclusively by vein. *JAMA* **203**: 860-864, 1968.
- 115) Wilmore DW, Dudrick SJ, et al: The role of nutrition in the adaptation of the small intestine after massive resection. *Surg Gynecol Obstet* **132**: 673-680, 1971.
- 116) Wilmore DW: Factors correlating with a successful outcome following extensive intestinal resection in newborn infants. *J Pediatr* **80**: 88-95, 1972.
- 117) Wright HK, Tilson MD: The short gut syndrome; Pathophysiology and treatment. *Curr Prob Surg* **3**: 3-51, 1971.
- 118) Zeng HL: An experimental study on the artificial intestinal valve by telescoping anastomosis. *Arch Jap Chir* **46**: 657-680, 1977.

和文抄録

腸管大量切除に関する基礎的，臨床的研究

—特に人工腸弁の効果について—

第2編 腸管大量切除における人工腸弁に関する実験的研究

京都大学医学部外科学教室第2講座（指導：小沢和恵教授）

花 房 徹 児

腸管大量切除は新生児外科においては，全結腸無神経節症，腸閉鎖，壊死性腸炎，腸回転異常症，等の場合に，成人外科においては，潰瘍性大腸炎，クローン氏病，腸管膜動脈血栓症，あるいは悪性腫瘍の際に行なわれる機会が増加している。その結果として，下痢，吸収障害，体重減少が持続し，社会復帰が困難な場合も多い。特に回盲部が合併切除された場合その傾向が著しい。

回盲部合併切除の頻度の高いこと，管理の困難な点より，回盲弁の働きを代償する人工腸弁をこの病態に応用した。

46頭の3～6 kgの幼犬を用いて，これを5群に別け実験した。

内訳は

90%切除群 n=3

80%切除群 n=8

80%切除+回盲弁切除群 n=10

80%切除+回盲弁切除+空腸腸弁群 n=3

80%切除+回盲弁切除+結腸腸弁群 n=8

であり，死亡率，体重変化，便性状，血液化学，形態的变化，臨床所見をとらえ，以下の結果を得た。

①80%切除群は術後の adaptation は良好

②80%切除+回盲弁切除群は adaptation 不良であった。

③上記の差は回盲弁の存在にあると考えられた。

④人工腸弁付加（結腸）群と回盲弁切除群との間に体重，死亡率，便性状，血液化学検査において明瞭な差を認めた。

以上のことより，大量腸管切除が行なわれる場合，回盲弁切除は極力避けるべきであり，やむなく，回盲弁が切除される場合人工腸弁の応用が有用である。