

Incidence of Calcification in the Pineal Gland, Habenular Commissure and Choroid Plexus of the Lateral Ventricle in Japanese

TATSUHIITO YAMAGAMI and HAJIME HANDA

Department of Neurosurgery, Faculty of Medicine, Kyoto University

(Director: Prof. Dr. HAJIME HANDA)

Received for Publication, May 1, 1985.

Summary

Computed tomography (CT) scans of 3,000 normal subjects were examined to verify the incidence of calcification in the pineal body, the habenular commissure and the choroid plexus of the lateral ventricle. In those over 10 years old, pineal calcification was found in 83% (male 83%, female 81%), habenular calcification in 18% (male 22%, female 12%). In those over 30 years of age, pineal calcification was found in 86%, habenular calcification in 20% and choroid plexus calcification in 69%. Male cases were predominate in almost all age groups.

Four types of calcification patterns were observed in the pineal region, including the pineal body and the habenular commissure: (1) Involvement of only the pineal gland (P type). This was the most frequent type. (2) and (3) Involvement of both the habenular commissure and the pineal body, either the former (Hp type) or latter (hP type) being larger. (4) The HP fused type in which the calcifications of the habenular commissure and the pineal body are fused.

The size and shape of the calcification in the pineal region were examined in 32 pineal region tumors and other germinoma cases. No specific differences were noted in the calcifications between normal groups and the germinoma cases. However, the pineal body calcification in pineal malignant teratomas tended to deviate unilaterally.

Introduction

Physiological intracranial calcifications occur in various regions such as the meningea, choroid plexus, basal ganglia, pineal region (pineal body and habenular commissure).

Since 1927 when VASTINE and KINNEY reported on calcification of pineal body²²⁾, almost all investigations were performed with a skull plain x-ray. Recently, CT scanning has used as an investigative tool^{3,25)}

We examined the patterns of calcification in the pineal region by analyzing the CT findings of normal 3,000 cases. A comparative study was done with patients who had a pineal region

Key words: Pineal calcification, Pineal body, Habenular commissure, Choroid plexus, Pineal region tumor.
索引語: 松果体石灰化, 松果体, 手綱交連, 脈絡叢, 松果体部腫瘍.

Present address: Department of Neurosurgery, Faculty of Medicine, Kyoto University, Sakyo-ku, Kyoto 606, Japan.

tumor. Calcification in choroid plexus of the lateral ventricle was also examined.

Materials and Methods

Plain CT (Hitachi CT-W3) films of patients without any organic central nervous system disorder were analyzed. These included those with mild head trauma, neurosis and migraine. There were no intracranial hematoma or abnormally low density area.

CT images were taken in slices of 10 mm thick paralleling the orbito-mental line. When the identification and judgement of pineal and habenular calcification were difficult, skull plain films and sagittal reconstruction of CT, when possible, were compared.

Age distribution was classified into 0 to 4, 5 to 9, 10 to 14, 15 to 19, 20 to 29, 30 to 39, ... 80 to 89, and over 90. The number of cases in which the pineal region was examined differed from that for the choroid plexus in the lateral ventricle, because judgement regarding a few cases was very difficult; these were excluded.

Thirty-two cases of pineal region tumor and germinoma in other regions were examined before operative treatment and radiotherapy. These examinations were performed with EMI 1010 and GE CT/T 8,800 scanner. Malignant teratoma refers to the pure or mixed type, including at least one of endodermal sinus tumor, choriocarcinoma or embryonal carcinoma element.

Results

A. Calcification of pineal region in normal subjects

The incidence of pineal region calcification including both the pineal body and habenular commissure is shown in Table 1. The frequency of calcification increased with ages. It occurred more often in males than in females, except for those in their eighth decade.

The calcifications of pineal body and habenular commissure were classified into four patterns.

1) P type (Fig. 1a)

Only the pineal body is calcified. This was the most frequent type.

Table 1. The frequency of calcification in the pineal region (%)

Age	Male	Female	Total
0 - 4	0	0	0
5 - 9	10	0	8
10 - 14	24	17	23
15 - 19	45	25	39
20 - 29	85	42	69
30 - 39	81	59	73
40 - 49	91	81	88
50 - 59	99	77	89
60 - 69	91	87	90
70 - 79	90	92	91
80 - 89	95	80	85
90 -	100	67	80

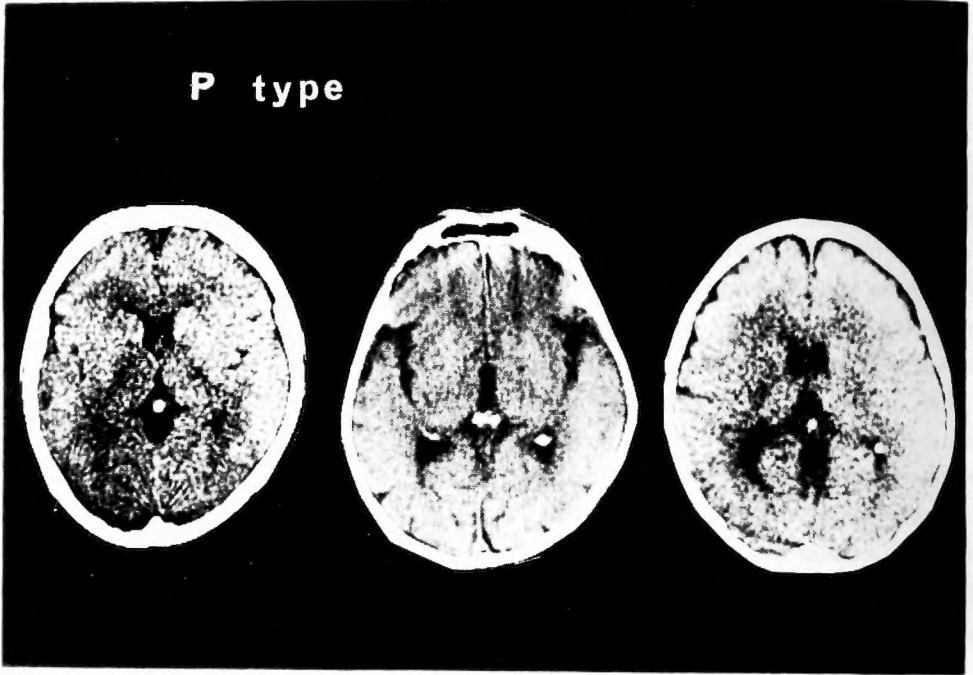


Fig. 1. Four types of calcified pattern in pineal region.
Fig. 1-a. P type. Only the pineal body is calcified.

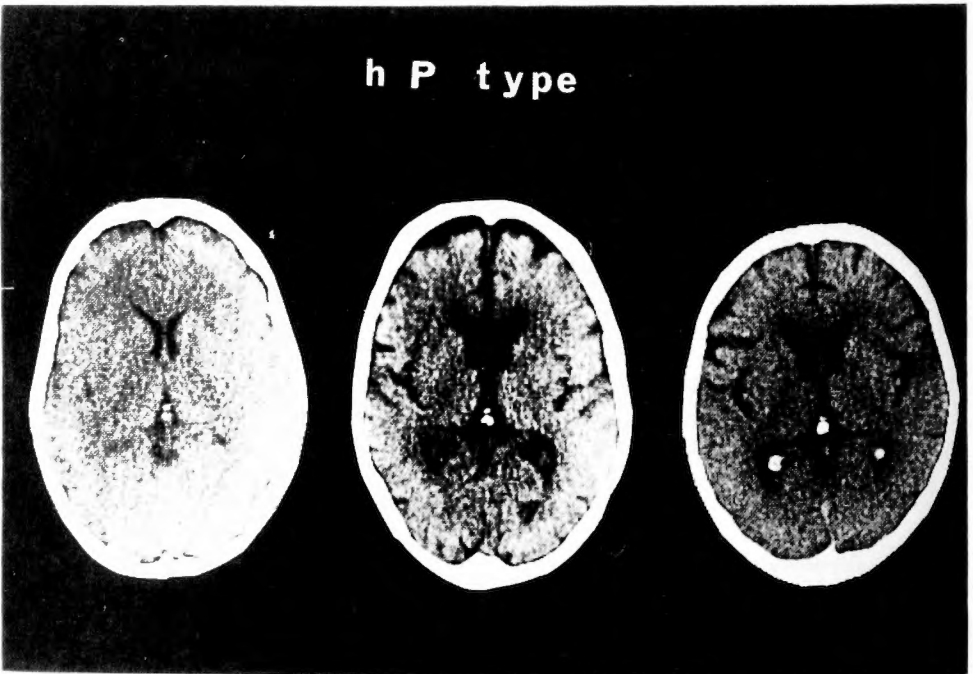


Fig. 1-b. hP type. Both habenular commissure and pineal body are calcified. The size of the latter is larger than that of the former.

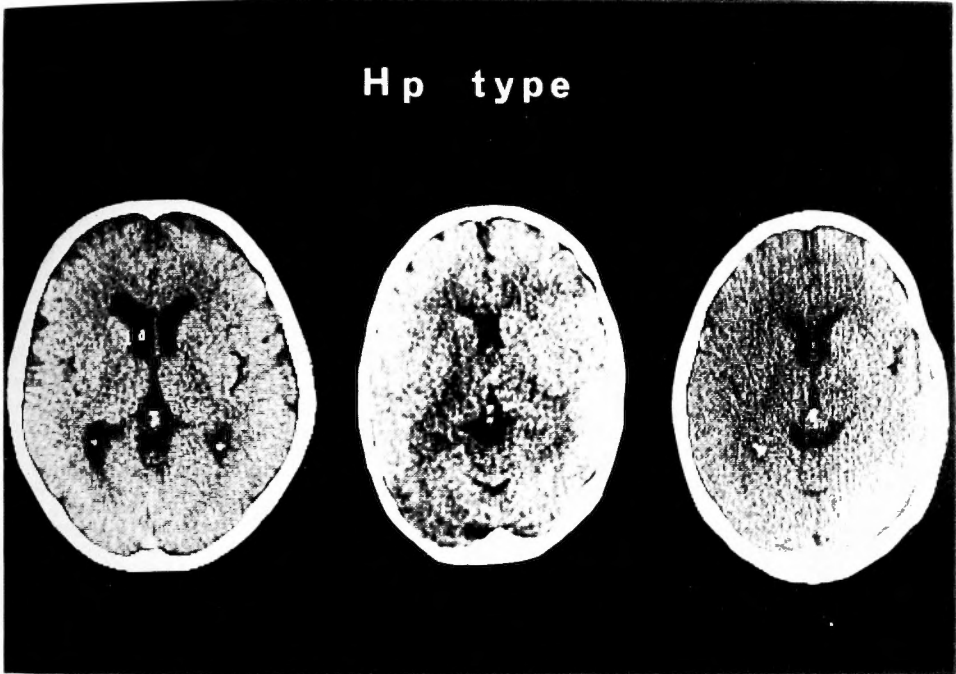


Fig. 1-c. Hp type. Both habenular commissure and pineal body are calcified. The size of the former is larger than that of the latter.

2) hP type (Fig. 1b)

Calcification of pineal body is larger than that of habenular commissure. Both calcifications appear separated on CT film. This type was less frequent than P type, but more than Hp type and HP fused type.

3) Hp type (Fig. 1c)

The size of habenular calcification is larger than that of pineal body calcification. This type was the least common out of the four.

4) HP fused type (Fig. 1d)

Calcifications of habenular commissure and pineal body are fused together and this type is further classified into four subtypes:

- i) Both calcifications are simply adjoined.
- ii) Calcification of pineal body surrounds that of habenular calcification.
- iii) The two calcifications form a Y-shaped configuration.
- iv) Two or more calcified centers of pineal body combine with the calcification of the habenular commissure.

Distinction of calcifications between pineal body and habenular commissure could be achieved by recognizing each calcification. Figure 2 shows the frequency of calcification in pineal body according to age group. The faint calcification appeared in a 6-year-old male and a 12-year-old female. Males were predominate and the calcified pineal bodies were found in 86% of those over 30 years of age (Table 2).

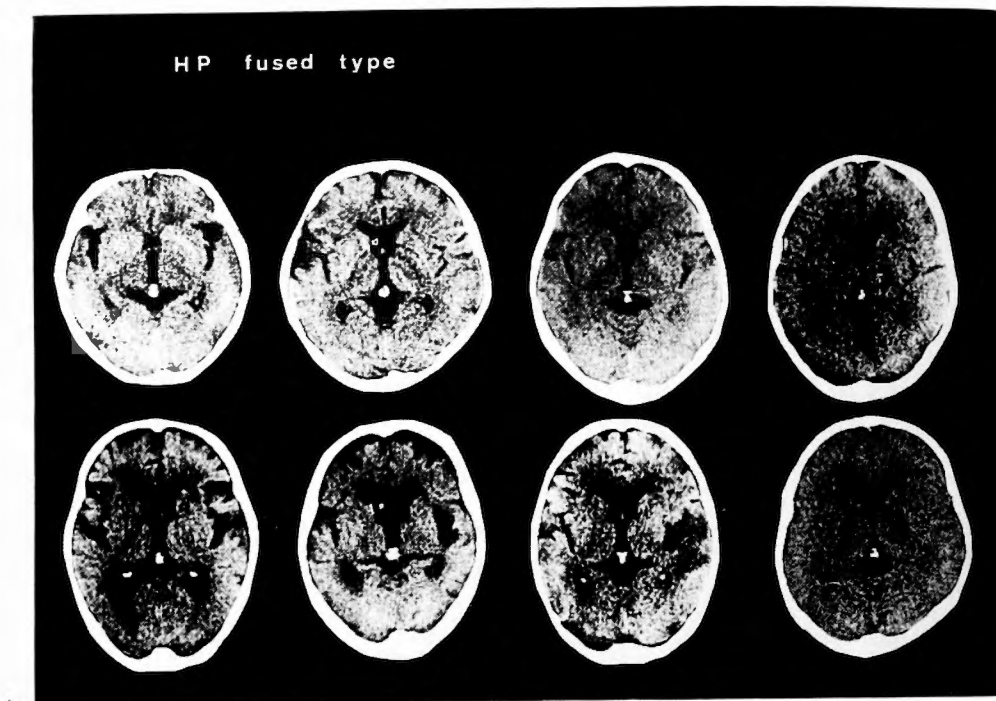


Fig. 1-d. HP fused type. The calcifications of habenular commissure and pineal body are fused.

- i) The two calcifications simply adhere (In the left).
- ii) In the left middle are the pineal bodies which surround the habenular commissure.
- iii) In the right middle are the two calcifications which create a Y-shaped configuration.
- iv) In the right are the pineal bodies which contain more than two calcified centers.

Table 2. Calcification of the pineal body

Age	Male			Female			Total		
	C	No.	%	C	No.	%	C	No.	%
0 - 4	0	28	0	0	20	0	0	48	0
5 - 9	9	105	9	0	41	0	9	146	6
10 - 14	13	71	18	5	35	14	18	106	17
15 - 19	39	81	48	18	43	42	57	124	46
20 - 29	121	149	81	44	95	46	165	244	68
30 - 39	197	240	82	75	124	60	272	364	75
40 - 49	253	291	87	93	121	77	346	412	84
50 - 59	237	251	94	121	153	79	358	404	89
60 - 69	249	272	92	169	192	88	418	464	90
70 - 79	220	245	90	241	271	89	461	516	89
80 - 89	62	67	93	71	95	75	133	162	82
90 -	4	4	100	4	6	67	8	10	80

(C) number of calcification

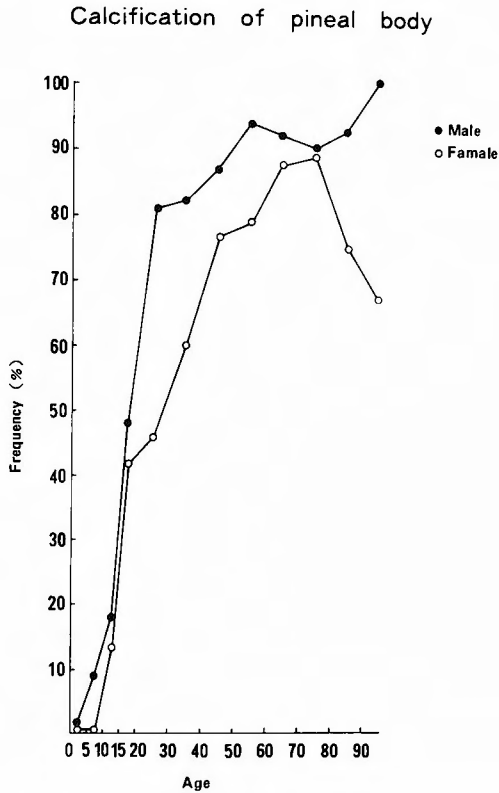


Fig. 2. The incidence of calcification in the pineal body.

Calcification of habenular commissure appeared first in 16-year-old male and in 19-year-old female. Again there was a male predominance (Table 3 and Fig. 3). The maximal frequency was 30% in males in their sixth decade. The calcified habenular commissures were noted in 20%

Table 3. Calcification of the habenular commissure

Age	Male			Female			Total		
	C	No.	%	C	No.	%	C	No.	%
0 - 4	0	28	0	0	20	0	0	48	0
5 - 9	0	105	0	0	41	0	0	146	0
10 - 14	4	71	6	1	35	3	5	106	5
15 - 19	8	81	10	3	43	7	11	124	9
20 - 29	20	149	13	9	95	9	29	244	12
30 - 39	50	240	21	10	124	8	60	364	16
40 - 49	64	291	22	15	121	12	79	412	19
50 - 59	75	251	30	19	153	12	94	404	23
60 - 69	58	272	21	28	192	15	86	464	19
70 - 79	69	245	28	43	271	16	112	516	22
80 - 89	15	67	22	16	95	17	31	162	19
90 -	0	4	0	1	6	17	1	10	10

Calcification of habenular commissure

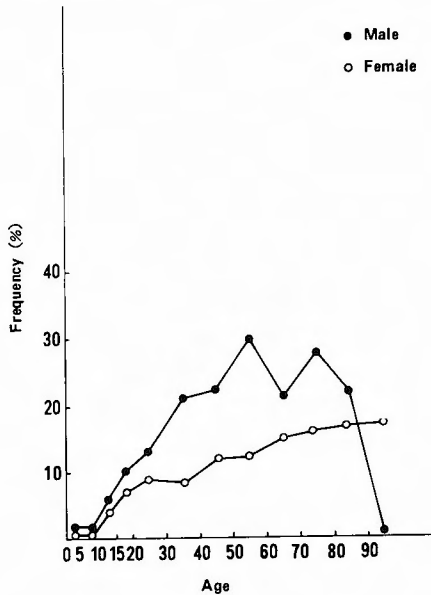


Fig. 3. The incidence of calcification in the habenular commissure.

of those over 30.

B. Calcification of pineal region in the cases of pineal region tumors and germinomas in other regions (Table 4).

All eight pineal germinoma cases exhibited calcifications of the pineal gland. The youngest was a 8-year-old boy. Germinoma of suprasellar region generally showed calcification of the pineal body except in a case of 14-year-old girl. Germinomas of the other regions also showed pineal calcification. The size and configuration of these calcifications were similar to those of normal subjects.

Eight cases (one case of pineal benign teratoma, four cases of pineal malignant teratoma, two cases of pineoblastoma and one case of ependymblastoma) exhibited round pineal calcifications in a tumor mass. In six of them, the pineal calcifications deviated from midline because of asymmetrical tumor enlargement (Fig. 4).

Calcification of habenular commissure was found in a 16-year-old with a pineal germinoma, a 15-year-old with a germinoma in the basal ganglia and a 41-year-old with a pineoblastoma. However, no definite differences in habenular calcifications were observed between the tumor cases and normal subjects.

C. Calcification of the choroid plexus in the lateral ventricle

There were symmetrical and asymmetrical calcifications, in which the unilateral side was calcified or one was definitely larger than the other. Fine unilateral calcification was noted in a 17-year-old boy and bilateral faint calcification in a 14-year-old girl. The frequency of asymmetrical calcification was 19% in males and 18% in females. There was male preponderance regarding

Table 4. Calcification of pineal region in 32 tumor cases

1) Pineal germinoma			
Case	Age	Sex	Calcification
1	8	M	P (small, round)
2	10	M	P (very small, round)
3	10	M	P (large, round)
4	11	M	P (very small, round)
5	12	M	P (very small, beaded)
6	16	M	HP fused
7	16	M	P (very small, round)
8	27	M	P (small, round)
2) Suprasellar germinoma			
Case	Age	Sex	Calcification
9	9	F	P (small, round)
10	14	F	(—)
11	14	F	P (small, round)
12	14	F	P (small, round)
13	23	F	P (very small, round)
14	23	M	P (moderate, round)
3) Germinoma of the basal ganglia			
Case	Age	Sex	Calcification
15	11	M	P (small, round)
16	12	M	(—)
17	15	M	HP fused (C-shaped)
4) Germinoma of the frontal lobe			
Case	Age	Sex	Calcification
18	34	M	P (large, round)
5) Pineal teratoma			
Case	Age	Sex	Calcification
19	3	M	(—)
20	6	M	P (moderate, round, deviated to the right)
21	7	M	(—)
6) Pineal malignant teratoma			
Case	Age	Sex	Calcification
22	11	M	P (moderate, round, deviated to the right)
23	13	M	P (moderate, round, deviated to the left)
24	14	M	(—)
25	16	F	(—)
26	48	M	P (moderate, round)
27	54	F	P (moderate, round, deviated to the right)
7) Pineoblastoma			
Case	Age	Sex	Calcification
28	2	F	(—)
29	26	M	P (moderate, round, deviated to the left)
30	41	M	HP fused
8) Ependymoma of the pineal region			
Case	Age	Sex	Calcification
31	64	F	P (small, round, deviated to the left)
9) Ependymoblastoma of the pineal region			
Case	Age	Sex	Calcification
32	1	M	P (small, beaded)

Abbreviation

M: Male, F: Female, P: Calcification of the pineal body, HP: Calcification of habenular commissure and pineal body, Maximal diameter of the pineal body calcification

very small: 1-2mm, small: 3-5mm, moderate: 6-10mm, large: more than 11mm

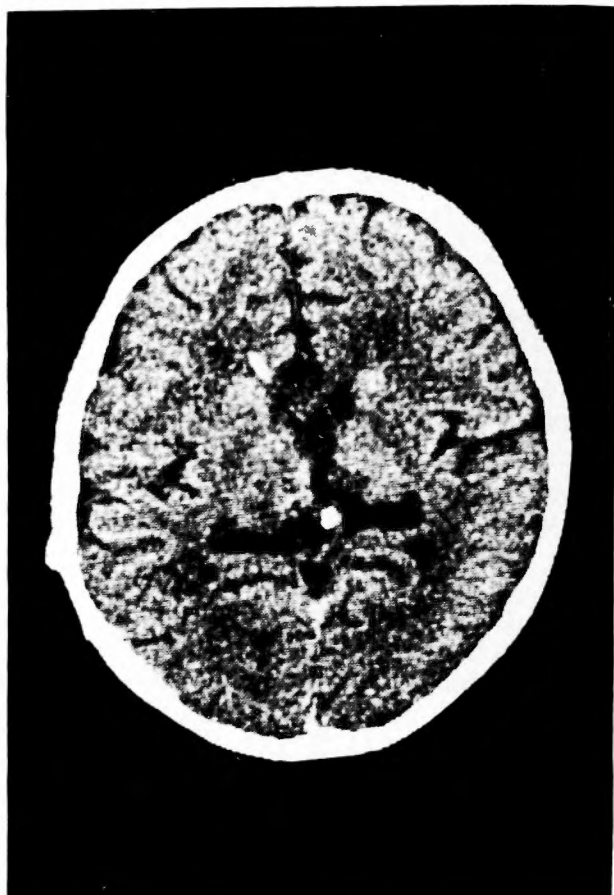


Fig. 4. Pineal malignant teratoma. Calcification of pineal body in the tumor deviates unilaterally. This was characteristic of pineal malignant teratoma and pineoblastoma.

the frequency of choroid plexus calcification until the age of 79. The calcified choroid plexus occurred in 69% over the age of 30 (Table 5 and Fig. 5).

In the pineal region tumor cases, symmetrical calcification of choroid plexus was observed in a 48-year-old patient with malignant teratoma and a 64-year-old patient with ependymoma. These configurations were identical to those observed in normal subjects.

Discussion

Pineal body calcification is generally regarded as being physiological. In 1927, VASTINE and KINNEY were the first to investigate the pineal calcification by using plain skull x-ray²²⁾. They analyzed normal cases and determined the site of normal pineal calcification. Thereafter, the frequency of pineal calcification was discussed by many investigators^{1,5,9,12,15,16)}.

After the advent of the CT scanner a smaller calcified portion of intracranial cavity could be visualized. Macpherson and Matheson surveyed 1,000 cases and compared the CT findings

Table 5. Calcification of the choroid plexus in the lateral ventricle

Age	Male					Female					Total		
	S	A	C	No.	%	S	A	C	No.	%	C	No.	%
0-4	0	0	0	28	0	0	0	0	20	0	0	48	0
5-9	0	3	3	101	3	0	0	0	36	0	3	137	2
10-14	3	2	5	71	7	1	0	1	28	4	6	99	6
15-19	12	9	21	89	24	6	2	8	48	17	29	137	21
20-29	54	7	61	152	40	18	13	31	91	34	92	243	38
30-39	108	44	152	245	62	36	4	40	117	34	192	362	53
40-49	154	35	189	282	67	57	11	68	119	57	257	401	64
50-59	141	26	167	245	68	84	19	103	158	65	270	403	67
60-69	166	36	202	270	75	103	22	125	193	65	327	463	71
70-79	167	33	200	241	83	173	38	211	277	76	411	518	79
80-89	54	2	56	67	84	71	11	82	96	85	138	163	85
90-	2	0	2	4	50	4	2	6	6	100	8	10	80

S: No. of symmetrical calcification, A: No. of asymmetrical calcification, C: No. of calcification

Calcification of the choroid plexus

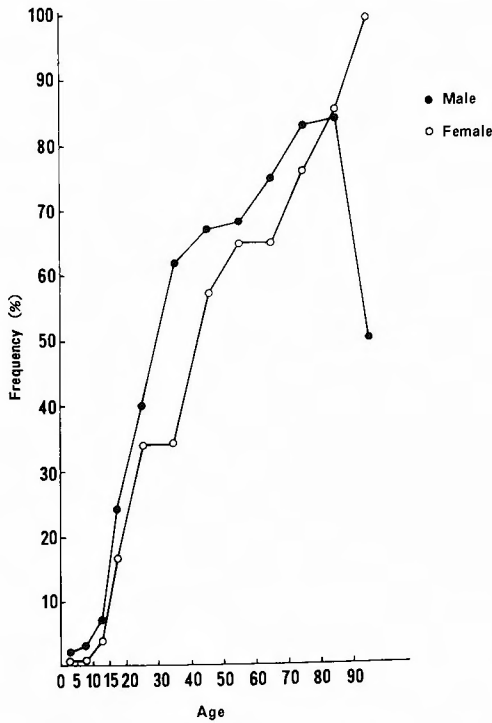


Fig. 5. The incidence of calcification in the choroid plexus of lateral ventricle, reflecting the sum of asymmetrical and symmetrical calcifications.

with those of skull plain x-ray¹³⁾. ZIMMERMAN and LILANIUK examined the frequency of pineal calcification in 725 cases under the age of 20. From their report pineal calcification in less 6 years old should be looked upon with suspicion of a pineal neoplasm²³⁾.

Almost all authors concluded that pineal calcification is rare under the age of 10; its incidence increases with age^{1,5,9,12,15)}. The frequency was 33 to 76% in Caucasians and 5 to 24% in other races as determined from skull plain film study¹²⁾. However, CT analysis disclosed a higher frequency. The higher frequency in Caucasians than in blacks might be due to the difference in exposure time to the sun⁹⁾. There is male predominance, but also the reversed was reported^{7,9,14)}.

The posterior commissure and a third ventricle are ventral to the pineal body. Habenular commissure is cranial to the posterior commissure and is situated between the suprapineal and pineal recess^{18,20)}. Anatomical studies of the choroid plexus in the third ventricle and pineal region have shed light on the anatomical relationships of habenular commissure and pineal body^{6,23,24)}.

STAUFFER et al reported calcification of habenular commissure existing 5.8 mm ventral to the pineal body calcification and described calcification of tenia habenulae. The opening portion of representative C-shaped calcification is anterior to the center of the pineal body calcification²⁰⁾. However, the site of habenular calcification is considered to be the end portion of tela choroidea in the third ventricle. Thus, the comparison with the choroid plexus of the fourth and lateral ventricles is necessary. Calcification in the choroid plexus of the fourth ventricle is difficult to detect.

As stated by MACPHERSON and MATHESON, the frequency of calcification was 83% in pineal body, 15% in habenular commissure and 79% in choroid plexus of the lateral ventricle in patients over 30¹³⁾. The present study disclosed a higher frequency in the pineal region but a lower frequency in choroid plexus than previously reported.

Deviation of pineal body calcification is useful for the diagnosis of intracranial mass¹¹⁾. However, unilateral mass does not always displace the pineal body¹³⁾.

A comparison of normal and pineal region tumor cases revealed no characteristic findings concerning pineal calcification of pineal germinoma. Pathognomonic pineal body calcification was not found in suprasellar germinoma cases. CHANG et al reported a high frequency of associated pineal calcification in male patients with suprasellar germinoma³⁾, whereas COHEN et al reported the absence of pineal calcification in such cases¹⁾. The difference was due to the ability of plain x-ray. Displacement of pineal body calcification was not observed¹⁰⁾. Pineal body calcification of malignant teratoma cases (4 out of 6) was displaced unilaterally because of asymmetrical tumor development. Furthermore, MØLLER et al argued that the calcified substance in the pineal tumor (pineocytoma) was amorphous calcium phosphate which differs from crystals of hydroxyapatite found in the normal pineal body calcification^{2,6,14,17)}. Hence it might not be correct to judge pineal body calcification as a parameter of differentiation between normal cases and the tumor cases.

Pineal body calcification is considered to be age-related. TAPP and HUXLEY reported calcium volume in the pineal gland did not change after 30 years of age²¹⁾. And the peak of

pineal calcification was reported to be the 60-years old group⁷⁾ Our results can't support any theories.

The rate of intracranial calcification found will probably increase with the advancement of radiological techniques. CT studies can overcome the limitations of plain skull x-ray. Hence our results may only represent the present standard rate in normal Japanese.

References

- 1) Adelay A and Felson B: Incidence of normal pineal gland calcification in skull roentgenograms of black and white Americans. *Am J Roentgenol Radium Ther Nucl Med* **122**: 503-507, 1974.
- 2) Angervall L, Berger S, et al: A microradiographic and x-ray crystallographic study of calcium in the pineal body and in intracranial tumors. *Acta Path Microbiol Scand* **44**: 113-119, 1958.
- 3) Chang GG, Kageyama N, et al: Pineal tumors: Clinical diagnosis, with special emphasis on the significance of pineal calcification. *Neurosurg* **8**: 656-668, 1981.
- 4) Cohen ND, Steinberg M, et al: Suprasellar germinomas: Diagnostic confusion with optic gliomas. *J Neurosurg* **41**: 490-493, 1974.
- 5) Daramola GF and Olowu AO: Physiological and radiological implications of a low incidence of pineal calcification in Nigeria. *Neuroendocrinology* **9**: 41-57, 1972.
- 6) Earle KM: X-ray diffraction and other studies of the calcareous deposits in human pineal glands. *J Neuropathol Exp Neurol* **24**: 108-118, 1964.
- 7) Fan KJ: Pineal calcification among black patients. *J Nat Med Assoc* **75**: 765-769, 1983.
- 8) Fujii K, Lenkey C, et al: Microsurgical anatomy of the choroidal arteries. Lateral and third ventricles. *J Neurosurg* **52**: 165-188, 1980.
- 9) Ganapathy K and Kalyanraman S: The calcified pineal in plain x-ray of the skull. *Neurol India* **26**: 131-134, 1978.
- 10) Izuquiedo JM, Rougerie, et al: The so-called ectopic pinealomas. A cooperative study of 15 cases. *Child's Brain* **5**: 505-512, 1979.
- 11) Ketonen L, Tallroth K, et al: Asymmetrische Verkalkung des Corpus pineale, welche eine Verlagerung der Glandula pinealis vortäuscht. *Fortschr Röntgenstr* **133**: 105-106, 1980.
- 12) Kitay JI and Altschule MD: The pineal gland. A review of the physiologic literature. Harvard University Press, Cambridge, Mass, 1954, p. 77-205.
- 13) Macpherson P and Matheson MS: Comparison of calcification of pineal, habenular commissure and choroid plexus on plain films and computed tomography. *Neuroradiology* **18**: 67-72, 1979.
- 14) Møller M, Gjerris H, et al: Calcification in a pineal tumor studied by transmission electron microscopy, electron diffraction and x-ray microanalysis. *Acta Neurol Scand* **59**: 178-187, 1979.
- 15) Mugondi SG and Poltera AA: Pineal gland calcification (PGC) in Ugandans. A radiological study of 200 isolated pineal glands. *Br J Radiol* **49**: 394-399, 1976.
- 16) Reiter RJ: The Pineal. Eden Press, Annual Research Review 5, 1980, p. 179-199.
- 17) Reiter RJ: The Pineal Gland I. CRC Press, Inc. Boca Raton Florida, 1981, p. 173-198.
- 18) Schaltenbrand G and Bailey P: Einführung in die stereo-taktische Operationen mit einem Atlas des menschlichen Gehirns. Band II. George Thieme Verlag, Stuttgart, 1959.
- 19) Silverstein A: The calcified pineal gland: Failure of displacement with unilateral cerebral mass. *J Med Soc New Jersey* **77**: 658-661, 1980.
- 20) Stauffer HM, Snow LB, et al: Roentgenologic recognition of habenular calcifications as distinct from calcification in the pineal body. Its application in cerebral localization. *Am J Roentgenol Radium Ther Nucl Med* **70**: 83-89, 1953.
- 21) Tapp E and Huxley M: The weight and degree of calcification of the pineal gland. *J Pathol* **105**: 31-39, 1971.
- 22) Vastine JH and Kinney KK: The pineal shadow as an aid in the localization of brain tumors. *Am J Roentgenol Radium Ther* **17**: 320-324, 1929.
- 23) Yamamoto I and Kageyama N: Microsurgical anatomy of the pineal region. *J Neurosurg* **53**: 205-221, 1980.

- 24) Yamamoto I, Rhoton AL, et al: Microsurgery of the third ventricle: Part I Microsurgical anatomy. *Neurosurg* **8**: 334-356, 1981.
- 25) Zimmerman RA and Bilaniuk LT: Age-related incidence of pineal calcification detected by computed tomography. *Radiology* **142**: 659-662, 1982.

和文抄録

日本人における松果体, 手綱交連および側脳室脈絡叢の石灰化の頻度について

京都大学医学部脳神経外科教室
 山上 達人, 半田 肇

日本人における松果体, 手綱交連および側脳室脈絡叢の石灰化の頻度を検討するために, 正常3000例のCTスキャンを解析した. 10才以上では, 松果体の石灰化は83%(男83%, 女81%), 手綱交連の石灰化は18%(男22%, 女12%)であった. 30才以上では, 松果体部の石灰化は86%, 手綱交連は20%そして側脳室脈絡叢は69%であった. どの石灰化も, ほとんどすべての年齢層において, 男性の石灰化の頻度が女性よりも高かった.

松果体および手綱交連を含む松果体部の石灰化の pattern に関しては, 次のように4型に分類することができた. (1) P type. 松果体のみが石灰化を示すもの

で, この type が最も多く認められた. (2) Hp type. 松果体と手綱交連の両者が石灰化を示すが, 手綱交連の方が大きい. (3) hP type. 松果体の石灰化の方が, 手綱交連よりも大きい. (4) HP fused type. 松果体と手綱交連の石灰化が融合している.

松果体部腫瘍及び germinoma の32例の松果体部の石灰化の形と大きさとこれらの正常例と比較したところ, germinoma の例と正常例の間では, 特異的な相違は認められなかったが, 松果体部の悪性の胚細胞腫においては, 石灰化が片側に偏位する傾向が確認された.