

症 例

Carcinoma of the Cystic Duct: A Case Report

MASAFUMI KOGIRE, OSAMU KITAMURA, TOSHIHIKO YAMADA, HIDEKI NODA,
MOTOKAZU ASANO and AKIKAZU YOSHIDA

The Department of Surgery, the Medical Center for Adult Diseases, Shiga
Received for Publication, July 3, 1985.

Carcinoma of the cystic duct is extremely rare. According to FARRAR²⁾, the following criteria must be satisfied for the diagnosis of primary carcinoma of the cystic duct: (1) the growth must be restricted to the cystic duct; (2) there must be no neoplastic process in the gallbladder, hepatic, or common bile ducts; (3) a histological examination of the growth must confirm the presence of carcinoma cells. In 1978, MANABE and SUGIE³⁾ reviewed only 21 cases in the literature that met FARRAR's criteria, including their own case. Herein, we present an addi-

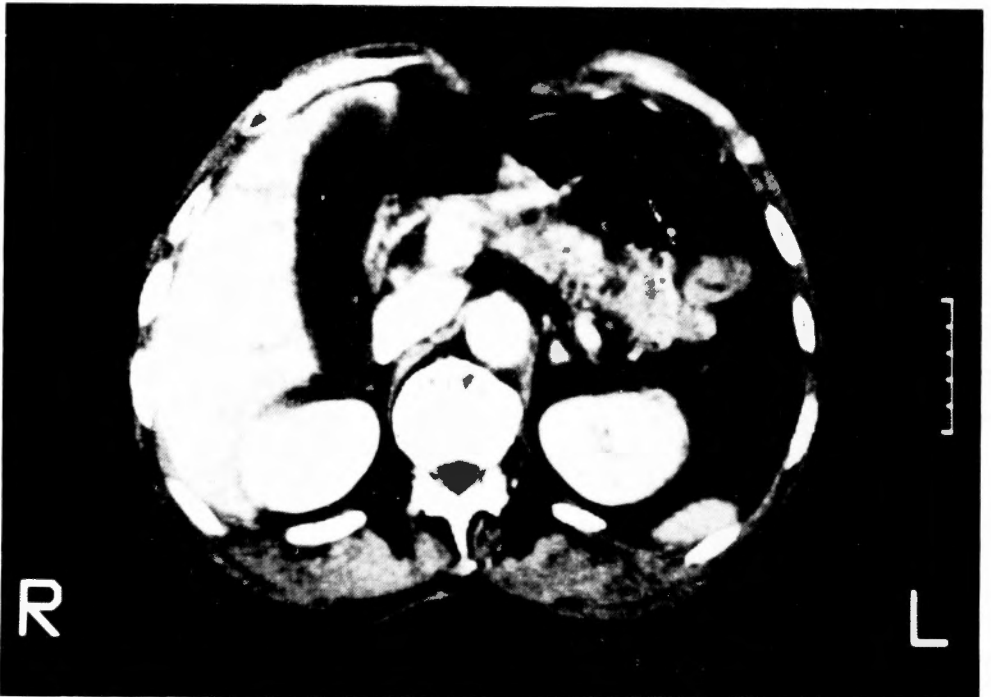

Fig. 1. Abdominal CT scan shows an enlarged gallbladder with no evidence of a gallstone.

Key words: Carcinoma of the cystic duct, Hydrops of the gallbladder.

索引語: 胆嚢管癌, 胆嚢水腫.

Present address: The First Department of Surgery, Faculty of Medicine, Kyoto University, Sakyo-ku, Kyoto, 606, Japan.

nal case of primary carcinoma of the cystic duct, which was discovered accidentally during cholecystectomy.

Case Report

A 70-year-old male was admitted to the Medical Center for Adult Diseases, Shiga, Japan, complaining of persistent right upper abdominal discomfort, which had begun about two years before. There was no history of fever, jaundice, or abdominal pain.

Physical examination revealed a smooth, nontender mass of 7×5 cm in the right upper quadrant of the abdomen. Hematological and biochemical findings were within normal limits, except for a slight elevation of total bilirubin 1.44 mg/dl (normal range 0.10–1.00). An upper gastrointestinal X-ray series showed no abnormalities. Drip infusion cholangiography (DIC) disclosed nonvisualization of the gallbladder. Computed tomography (CT) and ultrasonography showed an enlarged gallbladder, with no evidence of a gallstone (Fig. 1). However, endoscopic

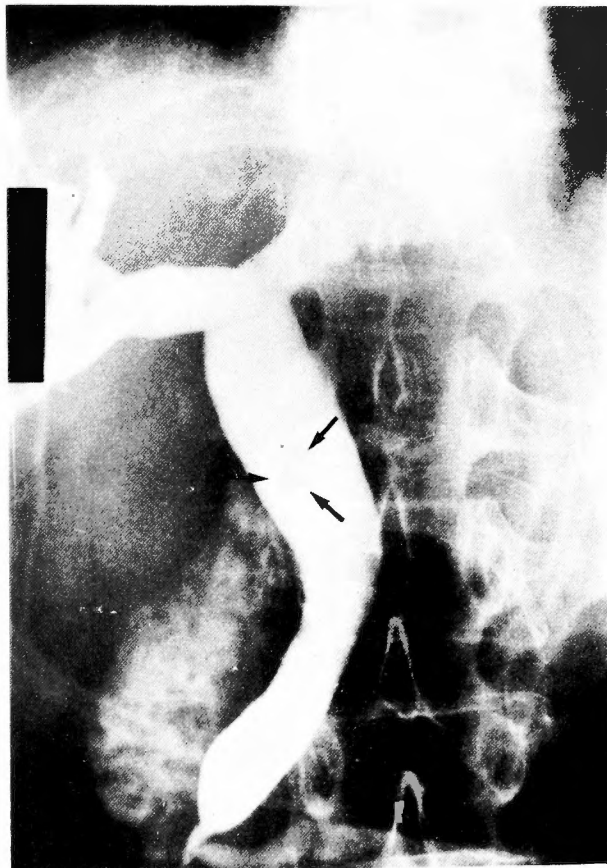

Fig. 2. Endoscopic retrograde cholangiopancreatography demonstrates a faint filling defect, presumably at the entry site of the cystic duct (arrow). The cystic duct and gallbladder are not opacified. Dilatation of the common bile duct and main pancreatic duct is also noted.

retrograde cholangiopancreatography (ERCP) demonstrated a faint filling defect, presumably at the entry site of the cystic duct. The cystic duct and gallbladder were not opacified (Fig. 2). Hydrops of the gallbladder due to a stone impacted in the cystic duct was strongly suspected.

At laparotomy, a firm nodule measuring $1.8 \times 1.3 \times 0.6$ cm was found in the cystic duct near its entrance into the common bile duct (Fig. 3). The gallbladder was tense and distended, containing "white bile". However, there were no stones. A frozen section of the nodule revealed an adenocarcinoma. The gallbladder, cystic duct and a segment of the common bile duct were resected with removal of the regional lymph nodes, and a Roux-en-Y hepaticojejunostomy was performed.

Microscopic examination showed a moderately differentiated adenocarcinoma infiltrating to the subserosa of the cystic duct (Fig. 4). There was no evidence of malignancy in the gallbladder, resected segment of the common bile duct, or the regional lymph nodes. Mild chronic inflammation was found in the gallbladder.

The patient had an uneventful recovery, and was discharged on the thirtieth postoperative day. He has remained well for twelve months since his operation, with no evidence of recurrence.

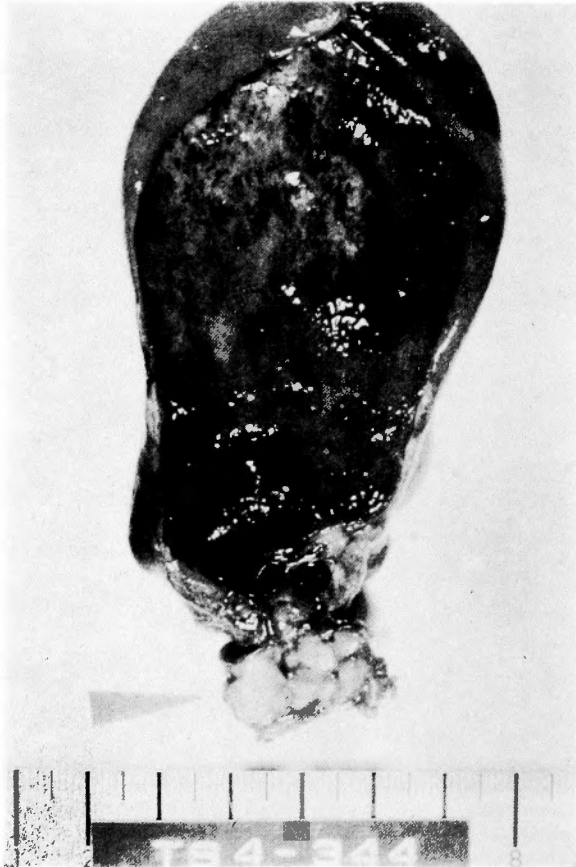

Fig. 3. Resected specimen opened to show adenocarcinoma of the cystic duct (arrow).

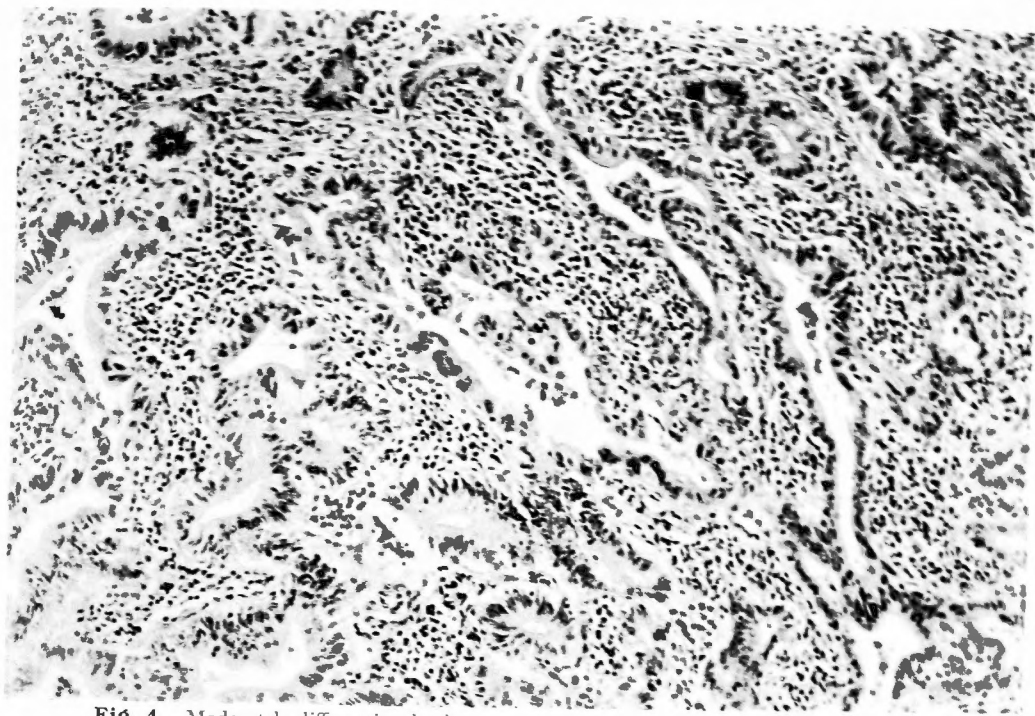


Fig. 4. Moderately differentiated adenocarcinoma of the cystic duct with chronic inflammatory infiltration is shown (hematoxylin-eosin, $\times 40$).

Discussion

Cases of primary carcinoma of the cystic duct are rarely reported, partly because of its low incidence and partly because of the difficulty in distinguishing it from carcinoma of the gallbladder, hepatic duct, or common bile duct in advanced cases. In addition to the 21 cases reviewed by MANABE and SUGIE³⁾ in 1978, only 3 more cases that meet FARRAR's criteria have been subsequently reported in the literature^{1,4,8)}. Therefore, this is the 25th case. The mean age of these 25 patients was 62 years. In contrast to carcinoma of the gallbladder, 18 (72%) of the patients were men. Associated stones in the bile ducts or gallbladder were present in only 36% of the cases.

Since the tumor easily obstructs the narrow lumen of the cystic duct and causes distension of the gallbladder, the most common clinical features of cystic duct carcinoma are upper abdominal pain and a palpable mass. Hydrops or empyema may sometimes result^{6,7)}. Fever and jaundice are less frequently present⁵⁾. On cholecystography, DIC, ERCP, or percutaneous transhepatic cholangiography, the gallbladder is seldom visualized. However, these symptoms and findings are also observed in gallstone disease. Moreover, the tumor is usually so small that it cannot be demonstrated on CT, sonography, or other radiological examinations. Though, an enlarged, nonfunctioning gallbladder with no evidence of an impacted cystic duct stone may be a clue to suspect carcinoma of the cystic duct, a correct preoperative diagnosis of cystic duct carcinoma has never been made⁵⁾.

Considering the location of the cystic duct, cholecystectomy and resection of portions of the hepatic and common bile ducts with regional lymph node dissection should be performed. According to the report of MANABE and SUGIE³⁾, the mean duration of survival for cystic duct carcinoma that met FARRAR's criteria was 20.2 months, which is better than that for carcinoma of the gallbladder or the extrahepatic bile ducts. However, the overall prognosis of carcinoma of the cystic duct, including advanced cases which do not satisfy FARRAR's criteria, remains unclear.

References

- 1) De Waele B, Beurang J, et al: Carcinoma of cystic duct leading to obstructive jaundice. *Dig Dis Sci* **29**: 865-867, 1984
- 2) Farrar DA: Carcinoma of the cystic duct. *Br J Surg* **39**: 183-185, 1951.
- 3) Manabe T and Sugie T: Primary carcinoma of the cystic duct. *Arch Surg* **113**: 1202-1204, 1978.
- 4) Montefusco P, Spier N, et al: Another facet of Mirizzi's syndrome. *Arch Surg* **118**: 1221-1223, 1983.
- 5) Nishimura A, Nakao K, et al: Carcinoma of the cystic duct: A case report. (in Japanese) *Jpn J Gastroenterol* **72**: 1095-1102, 1975.
- 6) Pack GT and Teng PK: Carcinoma of cystic duct leading to hydrops of gallbladder. *JAMA* **203**: 175-176, 1968.
- 7) Rabinovitch J, Arlen M, et al: Primary carcinoma of the cystic duct: Report of two cases. *Arch Surg* **80**: 424-433, 1960.
- 8) Wada Y, Kuroda A, et al: Carcinoma of the cystic duct. (in Japanese) "Geka Chiryō" **50**: 375-378, 1984.

和文抄録

胆嚢管癌の1例

滋賀県立成人病センター外科

小切 匡史, 北村 脩, 山田 紀彦, 野田 秀樹

浅野 元和, 吉田 昭和

胆嚢管癌の1例を経験したので報告する。

患者は70歳の男性で、2年来の右季肋部不快感を主訴として本院を受診した。腹部触診で腫大した胆嚢を触れ、DICでは胆嚢は造影されず、ERCPにて胆嚢管根部に相当する部位に淡い陰影欠損を認めた。胆嚢管への結石嵌頓による胆嚢水腫と考え、開腹術を行ったところ、結石は存在せず、胆嚢管内に1.8×1.3×0.6 cmの小腫瘤を認めた。迅速組織診断にて胆嚢管癌と判明したため、胆嚢摘出術・総肝管総胆管部分切除術・総肝管空腸吻合術を施行した。組織型は中分化型腺癌で、胆道癌取り扱い規約では、C. cir. 胆嚢は水腫型、腫瘍は結節型、So Hinfo HoBoPo N(-)M(-)

St(-) BWo HWo EWo Stage I R₁-OPとなった。術後1年の現在、再発の徴候を認めていない。

胆嚢管癌は稀な疾患であり、Farrarの定義、すなわち①癌の発育が胆嚢管に限局すること、②胆嚢・肝管・総胆管に癌を認めないこと、③組織学的に癌と確認されること、を満たす症例はさらに少なく、我々の症例が文献上25例目にあたる。胆嚢管癌の症状・所見は、胆石の胆嚢管嵌頓の症状・所見とほぼ同一であり、術前に胆嚢管癌と診断された症例は現在まで報告されていないか、嵌頓結石を画像診断上で証明しえない胆嚢腫大症例では胆嚢管癌の可能性も考慮に入れるべきである。