



TITLE:

# Surgical Treatment of Complete Atrioventricular Canal

AUTHOR(S):

MINAMI, KAZUAKI; TATSUTA, NORIKAZU; KONISHI, YUTAKA;  
MATSUDA, KATSUHIKO; YAMASATO, ARIO; CHIBA, YUKIO;  
ISHIHARA, HIROSHI; ... HIKASA, YORINORI; UEDA, TADASHI;  
HAYASHIDERA, TADASHI

---

CITATION:

MINAMI, KAZUAKI ...[et al]. Surgical Treatment of Complete Atrioventricular Canal. 日本外科宝函 1982, 51(4): 640-648

ISSUE DATE:

1982-07-01

URL:

<http://hdl.handle.net/2433/208956>

RIGHT:

---

臨 床

---

## Surgical Treatment of Complete Atrioventricular Canal

KAZUAKI MINAMI, NORIKAZU TATSUTA, YUTAKA KONISHI, KATSUHIKO MATSUDA,  
ARIO YAMASATO, YUKIO CHIBA, HIROSHI ISHIHARA, YOSHISADA SHIRAISHI,  
NOBORU NISHIWAKI, TOMOKAZU MURAGUCHI and YORINORI HIKASA

The 2nd Department of Surgery, Faculty of Medicine, Kyoto University  
(Director: Prof. Dr. YORINORI HIKASA)

TADASHI UEDA and TADASHI HAYASHIDERA

Department of Pediatrics, Faculty of Medicine, Kyoto University  
(Director: Prof. Dr. HARUKI MIKAWA)

Received for Publication, May. 10, 1982.

### Introduction

Among the problems in the repair of complete atrioventricular (A-V) canal, the anatomy is the most important in obtaining satisfactory results.

RASTELLI et al.<sup>16)</sup> established a "single-patch method", in which an atrial septal defect (ASD) and a ventricular septal defect (VSD) are closed with a single patch, and the divided common leaflets are sutured directly together to this patch. The advantage of this method is that there is no stenosis of the left ventricular outflow tract, however, a disadvantage is that the valve area is decreased due to the suturing of the common leaflet to the patch. SHIROTANI<sup>17)</sup> and HORIUCHI<sup>4)</sup> established a "two-patch method"; the common A-V leaflets are not divided, but the ASD and VSD are both closed respectively by a divided patch. The advantage of this method is that there is no decrease in valve area. However, in this lesion there are various anomalies in the common A-V leaflet and papillary muscle. Therefore, hypoplastic common A-V leaflet should be managed by valve advancement.

Recently, KAWASHIMA<sup>9)</sup> and YOSHIKUMI<sup>20)</sup> established a "cross-patch method", in which the common A-V leaflets are divided and the rims of the cross patch are sutured to the divided leaflets. The rims are made of autopericardium or Dacron. YOSHIKUMI<sup>20)</sup> emphasized that it is advisable to use autopericardium as rims in infants.

Seven cases of complete A-V canal have been repaired since December, 1972. In this report, surgical procedures and the results are described.

---

Key words: Complete atrioventricular canal, Rastelli's operation, Rastelli's classification, Two-patch method, Cross-patch method.

索引語: 完全型心内膜床欠損症, Rastelli 手術, Rastelli 分類, 二枚パッチ法, 十字形パッチ法.

Present address: The 2nd Department of Surgery, Faculty of Medicine, Kyoto University, Sakyo-ku, Kyoto, 606, Japan.

### Materials

1) Patients: Seven cases (3 males and 4 females) of complete A-V canal have been operated upon in the 2nd Department of Surgery, Kyoto University Hospital, since December, 1972, as shown in Table I. The age range at operation was from 1-12 years (mean age, 4.9 years).

2) Classification: According to Rastelli's classification, 4 cases were of type A, 2 of type B and 1 of type C.

3) Associated lesions: Concerning other associated heart diseases, Cases 1 and 6 had pulmonary stenosis (PS), and Case 3 had an absence of inferior vena cava and persistent left superior vena cava. Down's syndrome was found in Cases 1, 6 and 7. Case 1 had an agenesis of the right kidney and Case 5 had bronchial asthma.

### Surgical Procedures and Results

Case 1 was a type B complete A-V canal, with a preoperative diagnosis of pentalogy of Fallot. In order to determine the anatomy of the papillary muscle and the interventricular septum, a longitudinal right ventricular incision was made, severing the anterior right ventricular branch of the right coronary artery. The resection of the crista supraventricularis, parietal band and septal band, which were extremely hypertrophied, was performed to alleviate stenosis of the outflow tract of the right ventricle (RV). A section of autopericardium which was folded in half was used for the closure of the ASD and VSD. The suture line originated from the tip of the abnormal papillary muscle and divided its chordae tendineae into two groups; mitral and tricuspid components. The subsequent procedures were the same as Rastelli's method. However, the patient died of low output syndrome (LOS) the following day.

Case 2 was a type A complete A-V canal. A Dacron patch, the rim (5 mm in length) of which was on the mitral side at the level of the common A-V leaflet, was used for the closure of the ASD and VSD. The reconstructed anterior mitral valve was sutured to the edge of the rim. In the postoperative course, the patient suffered from right heart failure. Postoperative cardiac catheterization and angiocardiography revealed a L to R shunt (65%) at the ventricular level, equivalent pulmonary hypertension (PH), slight mitral regurgitation (MR) and tricuspid regurgitation (TR), 7 months after the operation. Reoperation was performed 1 year and 3 months postoperatively. Three small holes (3-7 mm in diameter) were found around the Dacron patch. In addition, a hole (6 mm in diameter), which appeared to be due to insufficient suture of the anterior mitral leaflet and the rim, was found. All holes were closed by direct suture. The patient is doing well now 5 years after the reoperation. Postoperative cardiac catheterization revealed that pressures in m-PA and RV were 55/30(40) and 60/0 respectively. However, residual shunt (L to R 24%) was recorded by RCG.

Case 3 was a type A complete A-V canal with an absence of inferior vena cava and persistent left superior vena cava. In this case, a Dacron cross-patch, which was made from two "L" shaped Dacron patches, was used for the closure of the ASD and VSD. Both rims (5 mm in length) were sutured together to the anterior mitral leaflet and septal tricuspid leaflet. Left heart failure

	No. 1 1.11 m	No. 2 6 f	No. 3 4 f	No. 4 12 m	No. 5 4 f	No. 6 4 m	No. 7 2.11 f
Operation	1972-12-18	1974-12-9	1976-10-25	1977-10-5	1978-10-30	1980-11-15	1981-11-2
Outcome	LOS → died	survived(Reop)	survived	survived(Reop)	LOS → died	survived	died
Rastelli's classification	B	A	A	A	A	B	C
associated Anomalies	Down's synd Agen r-Kidney PSv i.		PL-SVC absence of IVC			Down's synd PS	Down's synd
Cyanosis	≡	-	-	+	≡	±	±
CTR	0.53	0.68	0.67	0.70	0.72	0.68	0.79
Syst.murmur	3/6 (2-4LIS)	4/6 3-4LIS	3/6 (2-3LIS)	3/6 (3-4LIS)	4/6 (Apex)	2-4/6 (2-4LIS)	2-3/6 (3-4LIS)
ECG	Axis R-BBB undeterminable —	-100 incomplete	-140 incomplete	+60 incomplete	-80	-95 incomplete	-80 incomplete
Pressures	m-PA		71 49-61	115/50	108/63	70 40-48	72 45-53
	RVinf	89 3,3	87 9,5	100 -5	116 0,3	90 12	75 10
	LV	91 4, 9	102 -10.8	105 -1,20		90/20	95 15
	Ao			100 60(70)		90/50(64)	95 55(70)
	L→R					62.5%	71.2%
	R→L					40.5%	16.2%
Angio		MR ++ T +	MR +			MR ++ TR ++	MR ++ TR ++
Preop. Diagn.	T/F + ASD	Complete ECD	Complete ECD	VSD + ASD + PH	Complete ECD	Complete ECD	Complete ECD
Surgical Procedures					Lillehei-Kaster 18mm 		
Residual Shunt	/	65-70% RCG ++	40% RCG ++	L-R35%R -L27%	/	none minimum	
MR	/	++	++	+	/	minimum	
TR	/	+	+	++	/	minimum	
Complication		Hepatitis	Hemolytic Anemia				
A-V Block	—	—	—	—	—	—	—
RV/LV	0.97	0.85 -1.0 -0.60	0.68	1.15 -1.10 -0.78	0.97	1.0 -0.51	0.79

Table I. Seven patients with complete atrioventricular canal

and hemolysis were noted in the postoperative course; L to R shunt (40%) was recorded by RCG.

Case 4 was a type A complete A-V canal with a preoperative diagnosis of ASD, VSD and equivalent PH. Only in this case was right axis deviation upon ECG noted. In this case, the rim of the Dacron patch was on the mitral side, as in Case 2. Postoperative cardiac catheterization, performed 2.5 months after the operation revealed a residual L to R shunt (35%), moderate TR, slight MR and equivalent PH. Furthermore, the second postoperative cardiac catheterization, performed 2 years and 3 months after the operation, revealed a higher right ventricular pressure than left ventricular pressure, bilateral shunt (L to R shunt 37%, R to L shunt 46%) and severe TR. Reoperation was performed 2 years and 4 months after the first operation. One hole (10 mm in diameter) and two holes (5 mm in diameter) were found in the interventricular septum. There were two other holes (5-7 mm in diameter) in the atrial septum. These five holes appeared to be due to insufficient healing between the Dacron patch and the septum. All holes were closed by direct sutures and tricuspid valve replacement was performed using a prosthesis (Lillehei-Kaster valve, 25 mm in diameter). Tricuspid regurgitation occurred due to an absence of the septal leaflet and dilated tricuspid annulus. Cardiac catheterization, performed 1.5 months after the reoperation, revealed a lower RV pressure than femoral arterial pressure, and a small L to R shunt (20%).

Case 5 was a type A complete A-V canal. A Dacron patch, the rim (6 mm in length) of which was on the mitral side (as in Cases 2 and 3), was used for the closure of the ASD and VSD. However, hypoplasia of the posterior mitral leaflet resulted in severe MR. Thus a mitral valve replacement using a Lillehei-Kaster 18 was needed in order to control the regurgitation. However, a H-L bypass of long duration and large surgical damage resulted in LOS, and the patient died on the operative day.

Case 6 was a type B complete A-V canal associated with infundibular PS and Down's syndrome. The abnormal papillary muscle was divided into two groups, at the base of attachment of the mitral or tricuspid chordae tendineae. A septum was made by inserting a cross Dacron patch (as in Case 3) between the divided abnormal papillary muscle. Postoperative course was uneventful. In the postoperative cardiac catheterization, intracardiac pressures (mmHg) were: m-PA 54/16, RV 59/13, and LV 103/8. Also, no residual shunt was found, and minimum TR and MR were noted on angiography. This case was reported in detail in a previous paper.<sup>14)</sup>

Case 7 was a type C complete A-V canal associated with Down's syndrome and PH. A Dacron patch, with two sheets of pericardium (6 mm in length), attached on both sides at the level of the common A-V leaflets, was used to make a septum. All accessory chordae tendineae were cut off. The first two postoperative days were uneventful. However, on the 3rd postoperative day, systemic blood pressure dropped suddenly, resulting in left heart failure. Grade 1/6 systolic murmur, which was heard in the 4th left intercostal space shortly after the operation, increased to Grade 4/6 after the episode. The patient died of left heart failure and lung edema on the 17th postoperative day.

In autopsy, the reconstructed anterior mitral leaflet was ruptured on the suture line, resulting in severe MR. Also hypoplasia of the posterior mitral leaflet was responsible for secondary MR.

### Discussion

RASTELLI et al.<sup>16)</sup> classified complete A-V canal into three groups (A, B and C) according to the configuration of the anterior leaflet of the common A-V valve. In the type A, the anterior common A-V valve is divided into two portions, one mitral and one tricuspid, both attached medially to the muscular septum. In the type B, the anterior common A-V leaflet is divided, but not attached to the crest of the ventricular septum. The mitral and tricuspid portions of the anterior common leaflet are both attached by chordae to an abnormal papillary muscle that arises in the right ventricle near the septum. In the type C, the anterior common A-V leaflet is undivided and unattached to the septum but freely floats above it. The posterior common leaflet in all three types is usually rudimentary and shows various anatomic arrangements similar to those described for anterior common leaflet. RASTELLI et al.<sup>16)</sup> operated upon 38 patients: 25 of type A, 3 of type B and 10 of type C. Figure 1 shows the incidence in 3 types of complete A-V canal. Type A is the most frequent and is usually found independent of other anomalies. Type B and type C have been frequently associated with other major cardiac anomalies, such as PS, double outlet right ventricle and transposition of the great arteries. In 3 of 7 patients, Down's syndrome was noted. PS was found in 2 of 7 patients; both cases were type B. Rare associated diseases were as follows: agenesis of the right kidney (Case 1) and absence of inferior vena cava (Case 3).

In addition to differences in the anatomy of the anterior common A-V leaflets, there are frequently other anomalies. These can be seen as scanty valve tissue, shortened chordae tendineae, hypoplasia of the mitral valve tissue, abnormalities of the left ventricular and right ventricular papillary muscles, and double orifices in the mitral valve tissue. Although Rastelli's

Reporter	A	B	C
Rastelli <sup>16)</sup>	25	3	10
McMullan <sup>13)</sup>	20 (1)	0	7 (1)
Horiuchi <sup>5)</sup>	6 (3)	0	10 (6)
Stark <sup>18)</sup>	2 (0)	1 (0)	2 (1)
Binet <sup>2)</sup>	0	0	3 (0)
McCabe <sup>12)</sup>	2 (0)	0	2 (1)
Pacifico <sup>15)</sup>	0	1 (0)	0
Imai <sup>6)</sup>	1 (0)	0	6 (2)
Culpepper <sup>3)</sup>	3	0	8
Kawashima <sup>8)</sup>	4	1	5
total	63	6	53

( ) : dead case

Fig. 1. The incidence in three types of complete A-V canal

classification has been criticized on morphogenetic grounds,<sup>1,10,19)</sup> for the surgeon it is a convenient classification for describing surgical repair.

There are various surgical procedures for complete A-V canal (Fig. 2). Though RASTELLI<sup>16)</sup> used a single patch, the disadvantage of this method is that the valve area is decreased by the suture, especially the tricuspid valve. Thus, mitral and/or tricuspid regurgitation may occur postoperatively. A two-patch method as suggested by SHIROTANI<sup>17)</sup> and LINCOLN<sup>11)</sup> has the advantage of avoiding the incision of the valve tissue and thus the decrease in valve area. This method is advisable when the valve tissue is extremely thin as in infants and small children.

But when common A-V leaflets are scanty, this procedure may be contraindicated. Therefore, in complete A-V canal with severe scanty valve leaflet a cross-patch method is advisable when the possibility exists that mitral and tricuspid regurgitation may occur postoperatively. There are various methods to make a cross-patch, such as KAWASHIMA'S<sup>9)</sup> method and ours.

The cross-patch used in Cases 3 and 6 were constructed from two "L" shaped sheets of Dacron as shown in Fig. 2. It is convenient to be able to change the size of this cross-patch which is readily made prior to the operation. YOSHIKUMI<sup>20)</sup> emphasized that it is advisable to use autopericardium for the rims in infants. We used pericardium as rims of the septal patch in Case 7, a 2-year-old girl, who weighed 9 kg. The cross-patch method may have greater application than the two-patch method or the single patch method. In Cases 2, 4 and 5, we used an intermediate form between the single patch method and the cross-patch method, which we call 'Folded Single-Patch', however mitral and/or tricuspid regurgitation could not be adequately controlled, especially tricuspid regurgitation. Good operative results in complete A-V canal depend on cold cardioplegic myocardial protection during the operation, thus our method made the complicated procedures easier by permitting a clear operative field.

### Surgical Procedures for Complete A-V Canal

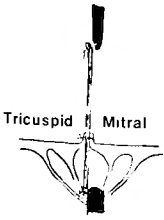
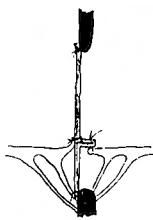
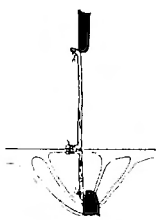
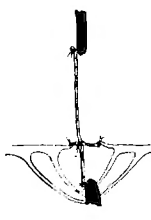
Single-Patch	Folded single-Patch	Two-Patch	Cross-Patch
 <p>Tricuspid Mitral</p> <p><sup>16)</sup> Rastelli 1966</p>	 <p>Tatsuta 1974</p>	 <p><sup>3)</sup> Horiuchi<sup>17)</sup> 1973 Shirovani 1974</p>	 <p><sup>9)</sup> Kawashima 1975 <sup>20)</sup> Muraoka 1976 Yoshizumi 1978</p>

Fig. 2. Various surgical procedures for complete A-V canal

Complications of this complex surgery are:

- 1) Damage to the A-V conduction system
- 2) Residual MR and/or TR due to an inadequate repair of the common A-V leaflet
- 3) Residual VSD and ASD due to inadequate closure of the A-V canal defect
- 4) Transient anemia due to hemolysis

In using cold cardioplegic myocardial protection, when placing the stitches in the area of the A-V node during cardiac arrest, there is a danger of causing a complete A-V block. Thus, the method in which the coronary sinus is placed on the side of the left atrium was adopted to increase safety.

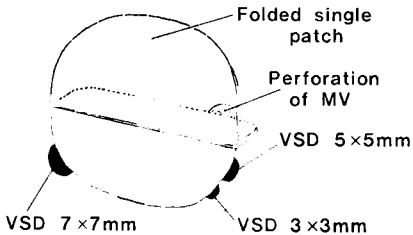
Residual shunt and regurgitation complicate the postoperative management and may cause transient hemolysis in the postoperative period, as in Case 3, however, persistent anemia due to hemolysis appears to be rare. Except for Case 1, all cases had pulmonary hypertension. Cases 2 and 4 underwent reoperation due to residual shunt, MR and/or TR and PH (Fig. 3). In these two cases, residual shunt and regurgitation, even though slight, did not alleviate PH. Therefore, reoperation should be performed as early as possible after the operation.

In Case 6, a 4-year-old boy, equivalent PH dropped to 0.5 (m-PA/LV systolic pressure ratio). KIRKLIN et al.<sup>7)</sup> reported that the mortality rate of patients less than 2 years old was not significantly higher than that of patients over 2 years old. Furthermore, he emphasized that complete A-V canal with PH should be operated upon in patients less than 2 years old in order to protect from irreversible change of lungs with PH.

The suitable rim length depends on the grade of development of common A-V leaflet. When the posterior mitral leaflet is slightly hypoplastic, the larger advancement by the rims into the

### Case 2

N O f	Rastelli A	
Operation I	'74. 12. 9	(6y)
II	'76. 3. 22	(8y)
	Preop.	Postop.
m-PA	108/69	55/30(40)
RV inf.	116/-10,8	60/0
LV or FA	110/70	100/50
Shunt(L·R)	65-70%(RCG)	24%(RCG)



### Case 4

M M m	Rastelli A	
Operation I	'77. 10. 5	(12y)
II	'80. 2. 25	(14y)
	Preop.	Postop.
m-PA	128/49(88)	71/40(56)
RV inf.	120/0,12	71/0,15
LV or FA	109/0,15	90/70(76)
Shunt	L·R37% R·L46%	L·R20%(RCG)

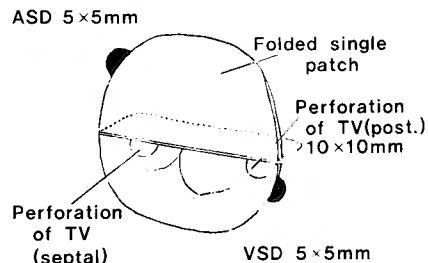


Fig. 3. The intracardiac findings upon reoperation in Cases 2 and 4



anterior mitral leaflet is necessary to control mitral regurgitation. However, in our Case 5, in which the posterior mitral leaflet was so hypoplastic that even a large advancement of the anterior mitral leaflet could not control mitral regurgitation, a prosthesis was necessary.

In the cardioplegic state, it is very difficult to accurately evaluate MR. In Case 5, severe mitral regurgitation was found shortly after the heart began to beat. When a LV-vent is inserted, the severity of mitral regurgitation can be evaluated by injecting saline solution. However, this method does not always accurately evaluate regurgitation, especially in the cardioplegic state.

### Summary

Seven patients with complete A-V canal (Rastelli's classification type A : 4, type B : 2, type C : 1) have undergone radical operation, using a 'folded single patch' or a 'cross-patch', during a 10 years period. Four patients survived the operation but three patients died. Two of the cases which survived underwent reoperation because of residual shunt and regurgitation, which, occurring from insufficient healing of sutures, resulted in postoperative heart failure.

The advantage of the cross-patch method is that there is no decrease in valve area. Hypoplastic common A-V leaflet should be managed by valve advancement using the cross-patch. A total repair of the complete A-V canal cannot be performed without slight residual shunt and regurgitation. Therefore, a long-term follow-up study is necessary, the reoperation should be aggressively performed in the early stage after the first operation.

The type B complete A-V canal was operated upon by the method, in which the abnormal papillary muscle was divided in half and the Dacron patch was inserted into the divided papillary muscle, achieving good results.

### References

- 1) Berger TJ, Kirklin JW, et al: Primary repair of complete atrioventricular canal in patients less than 2 years old. *Amer J Cardiol* **41**: 906-913, 1978.
- 2) Binet JP, Losay J, et al: Tetralogy of Fallot with type C complete atrioventricular canal—surgical repair in three cases. *J Thorac Cardiovasc Surg* **79**: 761-764, 1980.
- 3) Culpepper W, Kolff J, et al: Complete common atrioventricular canal in infancy—surgical repair and postoperative hemodynamics. *Circulation* **58**: 550-558, 1978.
- 4) Horiuchi T, Kagawa K, et al: Surgical treatment of endocardial cushion defect. *Heart* **5**: 941-949, 1973.
- 5) Horiuchi T, Kagawa Y, et al: Recent advances in surgery of congenital heart diseases. *Jpn J Thorac Surg* **28**: 854-867, 1975.
- 6) Imai Y, Wada J, et al: Cardiovascular surgery for congenital heart diseases; Past, Present and Future. *J Jpn Assoc Thorac Surg* **80**: 1356-1359, 1979.
- 7) Kirklin JW and Blackstone EH: Management of the infant with complete atrioventricular canal. *J Thorac Cardiovasc Surg* **78**: 32-34, 1979.
- 8) Kawashima Y, Matsuda K, et al: Surgery of complete endocardial cushion defect. presented in No. 34 Nihon-Kyobugeka-Gakkai, Tokyo, 1981.
- 9) Kawashima Y and Tomokuni T: Endocardial cushion defect. *Jpn J Thorac Surg* **28**: 773-780, 1975.
- 10) Kudoh T, Okamura K, et al: The classification of complete form in endocardial cushion defect. *Heart* **6**: 1309-1315, 1974.
- 11) Lincoln C: Atrioventricular canal; Surgical anatomy and repair. *Modern Cardiac Surgery*, p 125-130. edited by Longmore DB. MTP Press Limited Medical Publishers. Lancaster, 1978.

- 12) McCabe JC, Engle MA, et al: Surgical treatment of endocardial cushion defects. *Amer J Cardiol* **39**: 72-77, 1977.
- 13) McMullan MH, Wallace RB, et al: Surgical treatment of complete atrioventricular canal. *Surgery* **72**: 905-912, 1972.
- 14) Minami K, Tatsuta N, et al: Surgical treatment of type B complete atrioventricular canal. *Arch Jpn (Chir)* **50**: 689-698, 1981.
- 15) Pacifico AD and Kirklin JW: Surgical repair of complete atrioventricular canal with anterior common leaflet attached to an anomalous right ventricular papillary muscle. *J Thorac Cardiovasc Surg* **65**: 727-730, 1973.
- 16) Rastelli GC, Ongley PA, et al: Surgical repair of the complete form of persistent common atrioventricular canal. *J Thorac Cardiovasc Surg* **55**: 299-308, 1968.
- 17) Shirotani H: Radical operation for complete atrioventricular canal. *J Jpn Assoc Thorac Surg* **26**: 310-313, 1978.
- 18) Stark J: Correction of complete atrioventricular canal in infancy. *Modern Cardiac Surgery*, p 131-133, edited by Longmore DB. MTP Press Limited International Medical Puglishers, Lancaster, 1978.
- 19) Takeuchi S, Imamura H, et al: Surgical repair of complete atrioventricular canal with undivided common anterior leaflet. *J Jpn Assoc Thorac Surg* **29**: 1728-1733, 1981.
- 20) Yoshizumi M, Miyamoto S, et al: Valvulo-septal plasty for repair of complete form of endocardial cushion defect. *J Jpn Assoc Thorac Surg* **26**: 1055-1062, 1978.

## 和文抄録

### 完全型心内膜床欠損症の手術

京都大学医学部外科学教室第2講座 (主任: 日笠頼則教授)

南 一明, 龍田憲和, 小西 裕, 松田捷彦, 山里有男  
西脇 登, 千葉幸夫, 石原 浩, 白石義定  
村口和彦, 日笠頼則

京都大学医学部小児科学教室 (主任: 三河春樹教授)

上田 忠, 林寺 忠

完全型心内膜床欠損症 7 例 (Rastelli 分類・A型 4 例, B型 2 例, C型 1 例) に根治手術を施行, 生存 4 例, 死亡 3 例の結果であった。生存 4 例の内 2 例は, 遺残 ASD, VSD, MR, TR のため再手術を施行した。心内膜床欠損部に Folded single patch 又は Cross patch

を使用した。庇を作成することにより, 弁面積の拡大をもたらし, MR, TR の防止に役立ち, 特に, 低形成弁には有利である。しかし, 完全とはいい難く, 軽度の逆流を残すことが多い。従って, 長期 follow up が必要である。