

Title	Gastric Cancer from a Hyperplastic Polyp on an Endoscopic Submucosal Dissection Scar
Author(s)	Sono, Makoto; Fukuda, Akihisa; Seno, Hiroshi; Yazumi, Shujiro
Citation	Internal medicine (2019), 58: 1179-1180
Issue Date	2019-04-15
URL	http://hdl.handle.net/2433/241266
Right	The Internal Medicine is an Open Access journal distributed under the Creative Commons Attribution-NonCommercial-NoDerivatives 4.0 International License. To view the details of this license, please visit (https://creativecommons.org/licenses/by-nc-nd/4.0/).
Type	Journal Article
Textversion	publisher

[PICTURES IN CLINICAL MEDICINE]

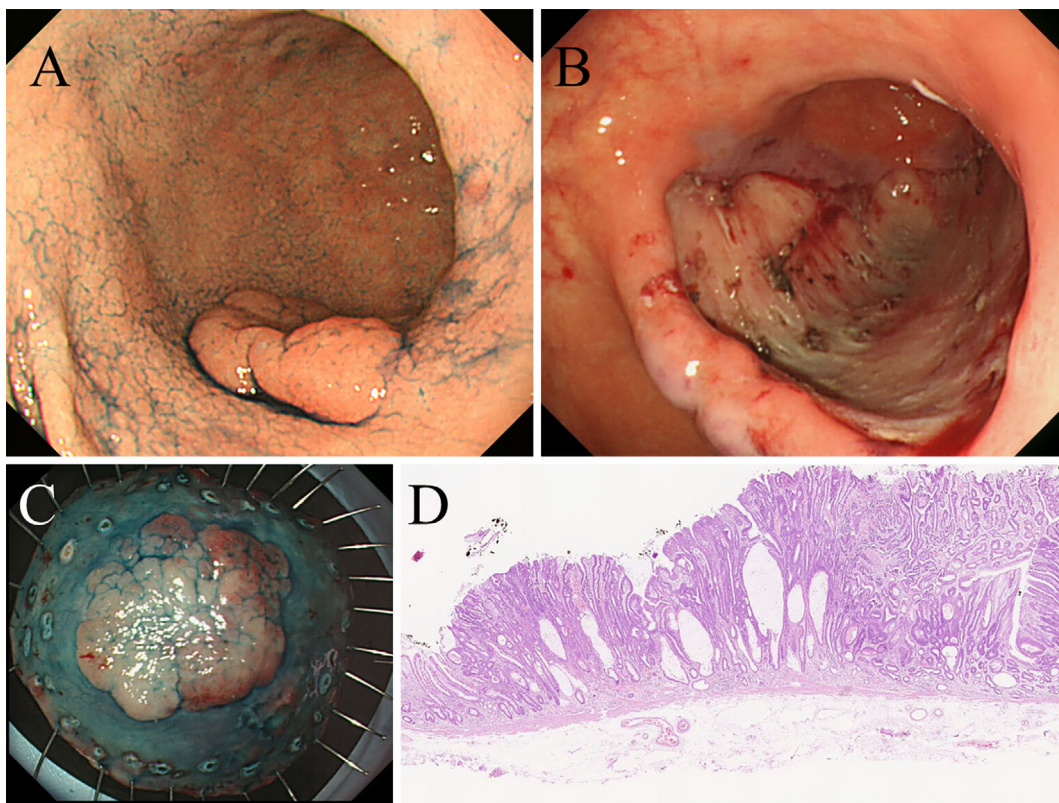
Gastric Cancer from a Hyperplastic Polyp on an Endoscopic Submucosal Dissection Scar

Makoto Sono^{1,2}, Akihisa Fukuda¹, Hiroshi Seno¹ and Shujiro Yazumi²

Key words: hyperplastic polyp, adenocarcinoma, gastric cancer, endoscopic submucosal dissection (ESD), ESD scar

(Intern Med 58: 1179-1180, 2019)

(DOI: 10.2169/internalmedicine.1636-18)



Picture 1.

A 50-year-old man with a history of *Helicobacter pylori* eradication underwent endoscopic submucosal dissection (ESD) for gastric cancer, which was pathologically diagnosed as well-differentiated tubular adenocarcinoma confined to the mucosa without ulcer or lymphovascular invasion (Picture 1). The horizontal and vertical margins were negative, so curative resection was judged to have been

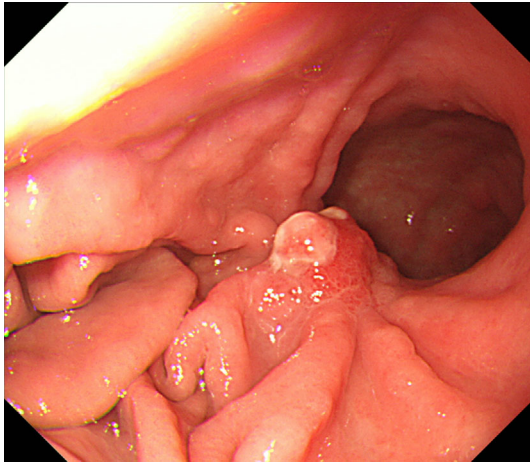
achieved.

Eight months after ESD, esophagogastroduodenoscopy demonstrated a hyperplastic polyp (HP) without malignancy on the ESD scar (Picture 2). Thirty-two months after ESD, however, adenocarcinoma arising from the widely based HP was identified (Picture 3). Because the bottom of the tumor was a benign hyperplastic lesion and because the gastric

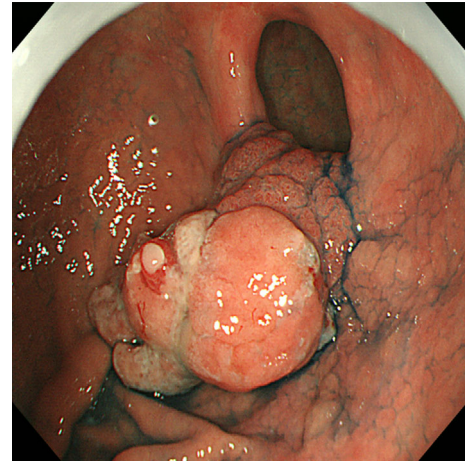
¹Department of Gastroenterology and Hepatology, Kyoto University Graduate School of Medicine, Japan and ²Division of Gastroenterology and Hepatology, Digestive Disease Center, Kitano Hospital, Japan

Received: June 2, 2018; Accepted: September 27, 2018; Advance Publication by J-STAGE: December 18, 2018

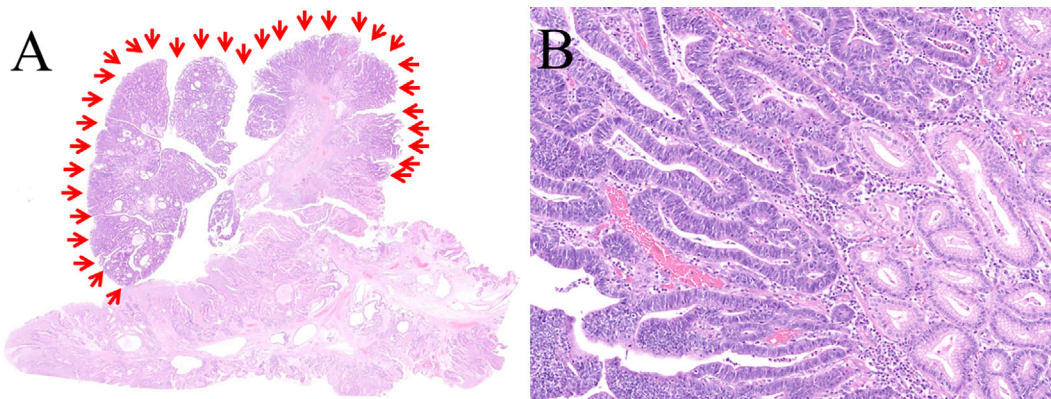
Correspondence to Dr. Shujiro Yazumi, s-yazumi@kitano-hp.or.jp



Picture 2.



Picture 3.



Picture 4.

cancer was small enough to completely resect by endoscopic mucosal resection (EMR), EMR was performed for adenocarcinoma, including a sufficient amount of the HP, which was pathologically diagnosed as well-differentiated tubular adenocarcinoma confined to the mucosa without ulcer or lymphovascular invasion. The horizontal and vertical margins were also negative (Picture 4).

Although extremely rare, we should be aware that a HP

on an ESD scar can develop into cancer. Endoscopic resection should be considered in such cases.

The authors state that they have no Conflict of Interest (COI).

The Internal Medicine is an Open Access journal distributed under the Creative Commons Attribution-NonCommercial-NoDerivatives 4.0 International License. To view the details of this license, please visit (<https://creativecommons.org/licenses/by-nc-nd/4.0/>).