



Expansion of retinal nerve fiber bundle narrowing in glaucoma: An adaptive optics scanning laser ophthalmoscopy study



Tomoko Hasegawa^a, Sotaro Ooto^{a,*}, Tadamichi Akagi^a, Takanori Kameda^a, Hideo Nakanishi^a, Hanako Ohashi Ikeda^{a,b}, Kenji Suda^a, Akitaka Tsujikawa^a

^a Department of Ophthalmology and Visual Sciences, Kyoto University Graduate School of Medicine, 54 Kawahara-cho, Shogoin, Sakyo-ku, Kyoto, 606-8507, Japan

^b Department of Experimental Therapeutics, Institute for Advancement of Clinical and Translational Science, Kyoto University Hospital, 54 Kawahara-cho, Shogoin, Sakyo-ku, Kyoto, 606-8507, Japan

ARTICLE INFO

Keywords:

Adaptive optics
Primary open angle glaucoma
Retinal nerve fiber defect

ABSTRACT

Purpose: To investigate longitudinal changes in the retinal nerve fiber bundle in eyes with primary open angle glaucoma using adaptive optics scanning laser ophthalmoscopy.

Methods: A prospective observational case series. Fourteen eyes from 12 patients with primary open angle glaucoma that exhibited retinal nerve fiber layer defects on fundus photography were imaged with adaptive optics scanning laser ophthalmoscopy over time.

Results: The expansion of retinal nerve fiber bundle narrowing was observed on adaptive optics scanning laser ophthalmoscopy in 8 eyes (57.1%) over a period of 1.44 ± 0.42 years. Retinal nerve fiber bundle narrowing expanded horizontally in 2 eyes and vertically in 6 eyes. In 3 eyes, changes in the retinal nerve fiber layer were only detectable on adaptive optics scanning laser ophthalmoscopy images.

Conclusions and Importance: The expansion of retinal nerve fiber bundle narrowing was observed using adaptive optics scanning laser ophthalmoscopy. Accordingly, this tool may be a useful tool for detecting glaucoma-related changes in retinal nerve fibers in a short time.

1. Introduction

Glaucoma is a leading cause of blindness worldwide, and its prevalence increases with aging.^{1–3} In glaucoma, damage to the retinal ganglion cells leads to thinning of both the retinal nerve fiber layer (NFL) and the ganglion cell layer, which is seen as NFL defects on fundus photography.⁴ The development of optical coherence tomography (OCT) has enabled cross-sectional imaging of the NFL, improving the detection of damage to the NFL and allowing the measurement of NFL thickness.^{5,6} Yet, OCT and other imaging modalities such as scanning laser ophthalmoscopy (SLO) fail to provide sufficient information about NFL microstructure due to aberrations in ocular optics. It is possible to compensate for these aberrations by using imaging systems that incorporate adaptive optics (AO), consisting of a wavefront sensor that measures aberrations in ocular optics and a deformable mirror or spatial light modulator to compensate for aberrations in living eyes.⁷ We previously demonstrated that AO-SLO captures images of individual retinal nerve fiber bundles in normal eyes and eyes of patients with glaucoma^{8,9} and showed that nerve fiber bundle width

changed in proportion to NFL thickness in eyes of patients with glaucoma compared to control eyes.⁹ Yet, it remains unclear whether AO-SLO is useful for detecting microstructural changes in retinal nerve fibers over time. In this study, we investigated longitudinal changes in retinal nerve fiber bundles using AO-SLO in eyes of patients with primary open angle glaucoma (POAG).

2. Materials and methods

This prospective observational longitudinal study adhered to the tenets of the Declaration of Helsinki and the study protocol was approved by the institutional review board and ethics committee of Kyoto University Graduate School of Medicine. The study enrolled primary open angle glaucoma patients with NFL defects on fundus photography and red-free SLO imaging who visited the Glaucoma Service at Kyoto University Hospital between June 2013 and April 2014. All potential participants received an explanation of the nature of the study and its possible consequences and provided written informed consent prior to participation.

* Corresponding author. Department of Ophthalmology and Visual Sciences, Kyoto University Graduate School of Medicine, 54 Shougoin Kawahara-cho, Sakyo-ku, Kyoto, 606-8507, Japan.

E-mail address: ohoto@kuhp.kyoto-u.ac.jp (S. Ooto).

<https://doi.org/10.1016/j.ajoc.2020.100732>

Received 1 August 2018; Received in revised form 26 April 2020; Accepted 30 April 2020

Available online 04 May 2020

2451-9936/© 2020 The Authors. Published by Elsevier Inc. This is an open access article under the CC BY-NC-ND license (<http://creativecommons.org/licenses/by-nc-nd/4.0/>).

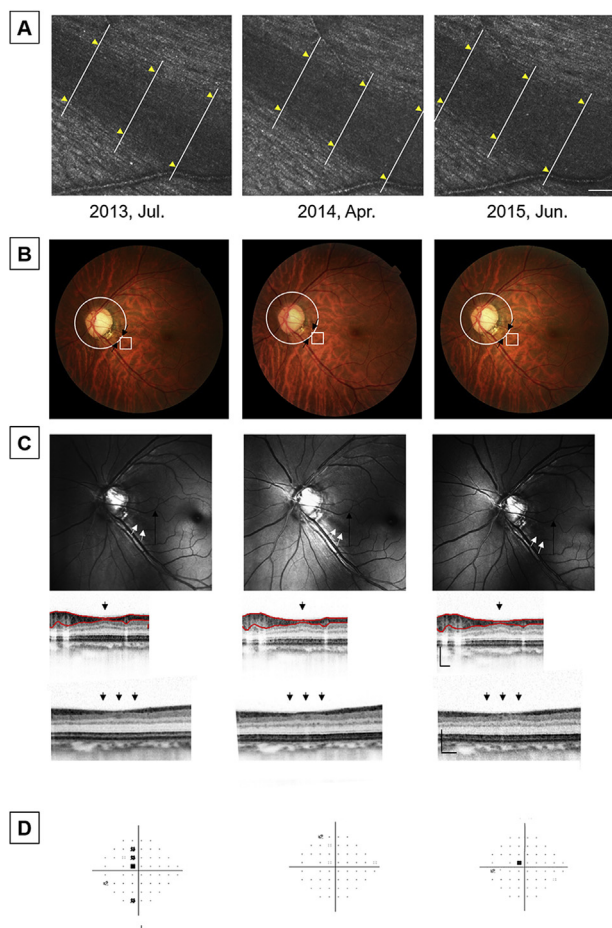


Fig. 1. Horizontal expansion of nerve fiber bundle narrowing detected on adaptive optics scanning laser ophthalmoscopy but not other modalities. Images of the left eye of a 46-year-old female patient with primary open angle glaucoma (POAG). (A) Magnified adaptive optics scanning laser ophthalmoscopy images focused on the nerve fiber layers (NFL) at locations centered 3.0 mm nasal and 0.5 mm inferior to the foveal center (white box in B). The width of nerve fiber bundle narrowing was measured at the same locations (yellow arrow heads). Nerve fiber bundle narrowing increased over time ($272 \pm 33.0 \mu\text{m}$ at 1st examination and $325 \pm 33.6 \mu\text{m}$ at final examination, $P < 0.0001$, analysis of variance with repeated measurements). Scale bar: $100 \mu\text{m}$. (B) Fundus photograph showing thinning of the lower rim of the optic disc and NFL defects (black arrows). (C) Red-free images showing NFL defects (white arrows, $280 \pm 19.9 \mu\text{m}$ at 1st examination and $287 \pm 17.8 \mu\text{m}$ at final examination, $P = 0.55$, analysis of variance with repeated measurements). Magnified spectral-domain optical coherence image scanning circumpapillary in a diameter of 3.46 mm (second line, white circle in B) and vertically (bottom line, black arrow in C) showing localized thinning of the retinal NFL at the NFL defects (black arrows). The measured value of the retinal NFL was $66 \mu\text{m}$ at 1st examination and $65 \mu\text{m}$ at final examination. Scale bar: $200 \mu\text{m}$. (D) Pattern deviation map from the static perimeter. (For interpretation of the references to color in this figure legend, the reader is referred to the Web version of this article.)

Included patients underwent a comprehensive ophthalmologic examination including an evaluation of best-corrected visual acuity (BCVA) using a 5-m Landolt chart, intraocular pressure (IOP) measurement using a Goldmann applanation tonometer, automated static visual field testing using the Humphrey Field Analyzer (24-2 Swedish Interactive Threshold Algorithm standard), gonioscopy, dilated funduscopy, color fundus photography, stereo fundus photography, red-free SLO imaging, spectral-domain OCT (SD-OCT, Spectralis® HRA + OCT; Heidelberg Engineering, scan speed: 40,000 A scans/second, lateral resolution: $6 \mu\text{m}$), and our prototype AO-SLO.^{10–12}

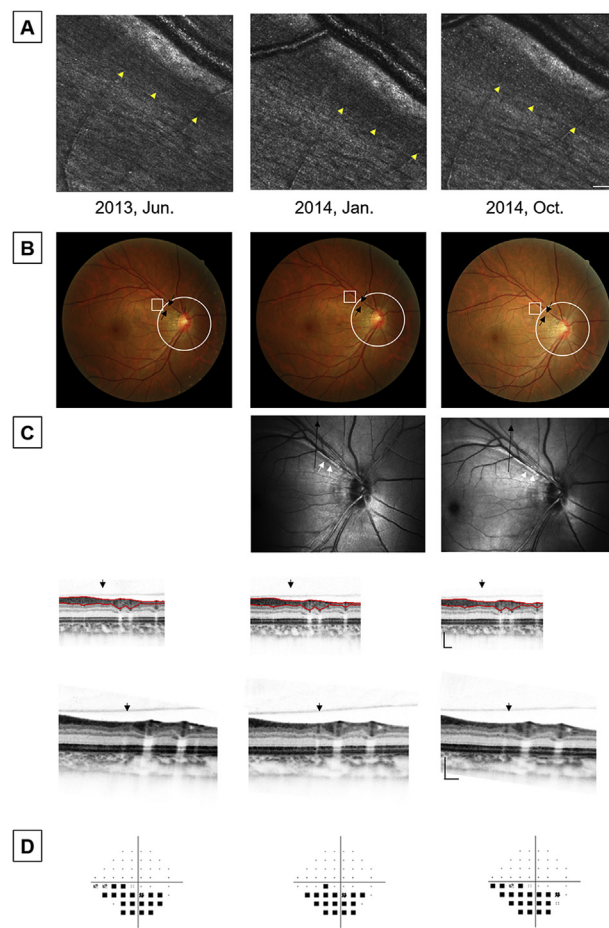


Fig. 2. Vertical expansion of nerve fiber bundle narrowing detected on adaptive optics scanning laser ophthalmoscopy but not other modalities. Images of the right eye of a 40-year-old female patient with primary open angle glaucoma (POAG). (A) Magnified adaptive optics scanning laser ophthalmoscopy images focused on the nerve fiber layer (NFL) at locations centered 3.0 mm nasal and 2.0 mm superior to the foveal center (white box in B). The cone mosaic is better visualized at the final examination, indicating vertical expansion of the NFL defect (yellow arrow heads). Scale bar: $100 \mu\text{m}$. (B) Fundus photograph showing localized thinning of the superotemporal rim of the optic disc, disc hemorrhage, and NFL defects (black arrows). (C) Red-free images showing NFL defects (white arrows). Magnified spectral-domain optical coherence image scanning circumpapillary in a diameter of 3.46 mm (second line, white circle in B) and vertically (bottom line, black arrow in C) showing localized thinning of the retinal NFL at the NFL defects (black arrows). The measured value of the RNFL was $54 \mu\text{m}$ at 1st examination and was $56 \mu\text{m}$ at final examination. Scale bar: $200 \mu\text{m}$. (D) Pattern deviation map from the static perimeter. (For interpretation of the references to color in this figure legend, the reader is referred to the Web version of this article.)

Using a prototype AO-SLO system, we captured images that focused on the NFL at locations centered 3.0 mm nasal from the foveal center and 3.0 mm upper to 3.0 mm lower from the foveal center at intervals of 0.5 mm. Thirty-two images were obtained at each location and averaged to reduce noise. The widths of nerve fiber bundle narrowing were measured in the same methods as previously reported.^{8,9} Briefly, using the digital caliper tool built into ImageJ, the width was measured at 3 points for each nerve fiber bundle narrowing and averaged (Fig. 1). The thickness of the retinal NFL on SD-OCT images was measured at the regions where the NFL narrowing was located.

3. Results

Fourteen eyes from 12 patients with POAG and NFL defects on

fundus photography were imaged with AO-SLO. The expansion of nerve fiber bundle narrowing was detected on AO-SLO images in 8 eyes (57.1%) over an observation period of 1.44 ± 0.42 years (range, 1.0–2.2 years). Nerve fiber bundle narrowing expanded horizontally in 2 eyes (Fig. 1) and vertically in 6 eyes (Fig. 2). In 3 eyes, changes in the NFL were only detectable on AO-SLO images; in these eyes, no expansion of NFL defects was detectable on color fundus photography, red-free SLO imaging, or SD-OCT (Figs. 1 and 2).

3.1. Selected case reports

Case 1 was the left eye of a 46-year-old woman with POAG (Fig. 1). The BCVA was 1.5 and the mean deviation of visual field was -0.68 dB at inclusion. IOP during the observation period was 13.5 ± 0.6 mmHg (range, 13–14 mmHg). After 2 years of observation, the mean deviation was -1.73 dB. Nerve fiber bundle narrowing expanded significantly on AO-SLO images (272 ± 33.0 μ m at 1st examination and 325 ± 33.6 μ m at final examination; $P < 0.0001$, analysis of variance with repeated measurements). NFL defect expansion was not detected on color fundus photography or red-free SLO imaging. On SD-OCT, there was no significant change in NFL thickness during the observation period (66.0 μ m at 1st examination and 65.0 μ m at final examination).

Case 2 was the right eye of a 40-year-old woman with moderate POAG (Fig. 2). The BCVA was 1.5 and the mean deviation of visual field was -5.22 dB at inclusion. IOP during the observation period was 16.3 ± 1.2 mmHg (range, 15–17 mmHg). After 1.3 years of observation, the mean deviation was -6.74 dB. Nerve fiber bundle narrowing expanded vertically on AO-SLO images. NFL defect expansion was not detected on color fundus photography or red-free SLO imaging. On SD-OCT, there was no significant change in NFL thickness during the observation period (54.0 μ m at 1st examination and 56.0 μ m at final examination).

4. Discussion

Evaluation of the NFL is important for detecting and managing glaucoma. Although red-free fundus photography and SLO imaging are standard approaches for examining the retinal NFL, changes are often undetectable until there is $> 50\%$ nerve fiber loss.¹³ The advent of OCT enabled cross-sectional imaging of the NFL^{5,6}; however, high-resolution enface imaging of the NFL has been limited by insufficient lateral resolution. In the current study, AO-SLO images had better resolution and contrast than red-free fundus photography or red-free SLO images, and microstructural changes in the NFL were only detected on AO-SLO images in a proportion of eyes.

AO-SLO revealed that nerve fiber bundles were narrowed but present in many areas in which NFL defects were observed on fundus photography and red-free SLO imaging.⁹ For this reason, we refer to abnormalities on AO-SLO images as “nerve fiber bundle narrowing” and those on red-free fundus photograph and red-free SLO imaging as “NFL defects.”

The current study showed that the expansion of nerve fiber bundle narrowing over time is distinguishable on AO-SLO. Moreover, in several eyes, this expansion was only detectable on AO-SLO images. Although the gold standard for monitoring glaucoma is automated static perimetry, this test is subjective and fluctuations hinder the accurate and sensitive evaluation of glaucoma progression over short periods of time.^{14,15} When the visual field progression was evaluated using the mean deviation value of automated static perimetry and was defined as statistically significant ($P < 0.05$) decline on linear regression, none of the 14 eyes included in the study showed significant visual field progression during the study period of 1.44 ± 0.42 years. Accordingly, AO-SLO has potential utility for monitoring glaucoma over shorter periods than is feasible with other modalities. The ability to detect microstructural changes in the NFL would help us to decide to

strengthen the treatment in patients with glaucoma. Further studies are necessary to evaluate the sensitivity and specificity of AO-SLO for detecting microstructural changes in glaucoma.

5. Conclusion

We observed the expansion of retinal nerve fiber bundle narrowing with AO-SLO. AO-SLO may have particular utility for assessing short-term glaucoma-related changes in the retinal nerve fibers.

Patient consent

This report does not contain any personal information that could lead to the identification of the patient. Written informed consent for the research was obtained from the patients prior to participation.

Funding

This study was supported in part by the Japan Society for the Promotion of Science, Tokyo, Japan (Grant-in-Aid for Scientific Research, no. 26893131) and the Innovative Techno-Hub for Integrated Medical Bio-Imaging of the Project for Developing Innovation Systems—a project of the Ministry of Education, Culture, Sports, Science, and Technology, Japan. Canon Inc. provided a prototype AO-SLO system to the authors' institution. The funding sources had no conflicts of interest with the study.

Authorship

All authors attest that they meet the current ICMJE criteria for Authorship.

Declaration of competing interest

None.

Acknowledgements

None.

Appendix A. Supplementary data

Supplementary data to this article can be found online at <https://doi.org/10.1016/j.ajoc.2020.100732>.

References

- Klein R, Klein BE. The prevalence of age-related eye diseases and visual impairment in aging: current estimates. *Invest Ophthalmol Vis Sci*. 2013;54(14):orsf5–orsf13.
- Wolfs RC, Borger PH, Ramrattan RS, et al. Changing views on open-angle glaucoma: definitions and prevalences—The Rotterdam Study. *Invest Ophthalmol Vis Sci*. 2000;41(11):3309–3321.
- Kapetanakis VV, Chan MP, Foster PJ, Cook DG, Owen CG, Rudnicka AR. Global variations and time trends in the prevalence of primary open angle glaucoma (POAG): a systematic review and meta-analysis. *Br J Ophthalmol*. 2016;100(1):86–93.
- Jonas JB, Budde WM, Panda-Jonas S. Ophthalmoscopic evaluation of the optic nerve head. *Surv Ophthalmol*. 1999;43(4):293–320.
- Leung CK, Lam S, Weinreb RN, et al. Retinal nerve fiber layer imaging with spectral-domain optical coherence tomography: analysis of the retinal nerve fiber layer map for glaucoma detection. *Ophthalmology*. 2010;117(9):1684–1691.
- Leung CK, Yu M, Weinreb RN, Lai G, Xu G, Lam DS. Retinal nerve fiber layer imaging with spectral-domain optical coherence tomography: patterns of retinal nerve fiber layer progression. *Ophthalmology*. 2012;119(9):1858–1866.
- Liang J, Williams DR, Miller DT. Supernormal vision and high-resolution retinal imaging through adaptive optics. *J Opt Soc Am A Opt Image Sci Vis*. 1997;14(11):2884–2892.
- Takayama K, Ooto S, Hangai M, et al. High-resolution imaging of the retinal nerve fiber layer in normal eyes using adaptive optics scanning laser ophthalmoscopy. *PLoS One*. 2012;7(3):e33158.
- Takayama K, Ooto S, Hangai M, et al. High-resolution imaging of retinal nerve fiber bundles in glaucoma using adaptive optics scanning laser ophthalmoscopy. *Am J*

- Ophthalmol.* 2013;155(5):870–881.
10. Makiyama Y, Ooto S, Hangai M, et al. Macular cone abnormalities in retinitis pigmentosa with preserved central vision using adaptive optics scanning laser ophthalmoscopy. *PLoS One*. 2013;8(11):e79447.
11. Arichika S, Uji A, Ooto S, Miyamoto K, Yoshimura N. Adaptive optics-assisted identification of preferential erythrocyte aggregate pathways in the human retinal microvasculature. *PLoS One*. 2014;9(2):e89679.
12. Hasegawa T, Ooto S, Takayama K, et al. Cone integrity in glaucoma: an adaptive-optics scanning laser ophthalmoscopy study. *Am J Ophthalmol*. 2016;171:53–66.
13. Quigley HA, Addicks EM. Quantitative studies of retinal nerve fiber layer defects. *Arch Ophthalmol*. 1982;100(5):807–814.
14. Chauhan BC, Garway-Heath DF, Goni FJ, et al. Practical recommendations for measuring rates of visual field change in glaucoma. *Br J Ophthalmol*. 2008;92(4):569–573.
15. Suda K, Hangai M, Akagi T, et al. Comparison of longitudinal changes in functional and structural measures for evaluating progression of glaucomatous optic neuropathy. *Invest Ophthalmol Vis Sci*. 2015;56(9):5477–5484.