



# Hemodynamic and structural changes in retinal arterial macroaneurysm after intravitreal anti-vascular endothelial growth factor injection

Shin Kadomoto, Yuki Muraoka<sup>\*</sup>, Akihito Uji, Sotaro Ooto, Tomoaki Murakami, Akitaka Tsujikawa

Department of Ophthalmology and Visual Sciences, Kyoto University Graduate School of Medicine, Kyoto, Japan

## ARTICLE INFO

### Keywords:

Adaptive optics scanning light ophthalmoscope  
Anti-vascular endothelial growth factor  
Optical coherence tomography angiography  
Retinal arterial macroaneurysm

## ABSTRACT

High resolution imaging with optical coherence tomography angiography and offset pinhole adaptive optics scanning light ophthalmoscope helped us visualize the hemodynamic and structural changes in a ruptured retinal arterial macroaneurysm in a 78-year-old woman. Intravitreal injection of anti-vascular endothelial growth factor was administered to ameliorate the condition.

## 1. Case report

A 78-year-old woman with a 5-day-history of decreased visual acuity (VA) in her left eye was referred to our clinic. The initial VA was 20/100. Color fundus photography showed retinal hemorrhage around the retinal arterial macroaneurysm (RAM) and optical coherence tomography (OCT) showed serous retinal detachment (Fig. 1 A, B, and F). Optical coherence tomography angiography (OCTA) showed blood flow signal within the RAM (Fig. 1 C and G), and the offset pinhole adaptive optics scanning light ophthalmoscope (AOSLO) video revealed pulsation and thinning of the arterial wall (Fig. 1 D-E, and video 1). The patient was administered intravitreal ranibizumab injection at the initial visit. One month after injection, the VA improved to 20/30, and the retinal exudative changes resolved substantially (Fig. 2 A,B, and F). OCTA detected no indicative intra-aneurysmal flow signal (Fig. 2 C and G), and offset pinhole AOSLO showed that the RAM was non-pulsatile and complete RAM occlusion had been achieved (Fig. 2 D-E, and video 2).

## 2. Discussion

Retinal arterial macroaneurysm (RAM) is a fusiform dilation of the retinal artery, and is common in elderly females.<sup>1</sup> Ruptured RAMs can cause retinal exudative changes and a sudden decrease in VA. Using fluorescein angiography (FA), Shults et al.<sup>1</sup> reported that in three (60 %) of five patients, the RAMs were pulsatile, and the pulsation was associated with more retinal exudation. The pulsation examined by FA may be a good clinical indicator of disease activity and visual outcomes.<sup>1</sup>

More recently, non-invasive imaging techniques including OCT and OCTA have been applied for evaluating the morphology of RAMs.<sup>2,3</sup> However, it is challenging to examine the real-time intra-aneurysmal blood flow with FA, OCT, and OCTA modalities.

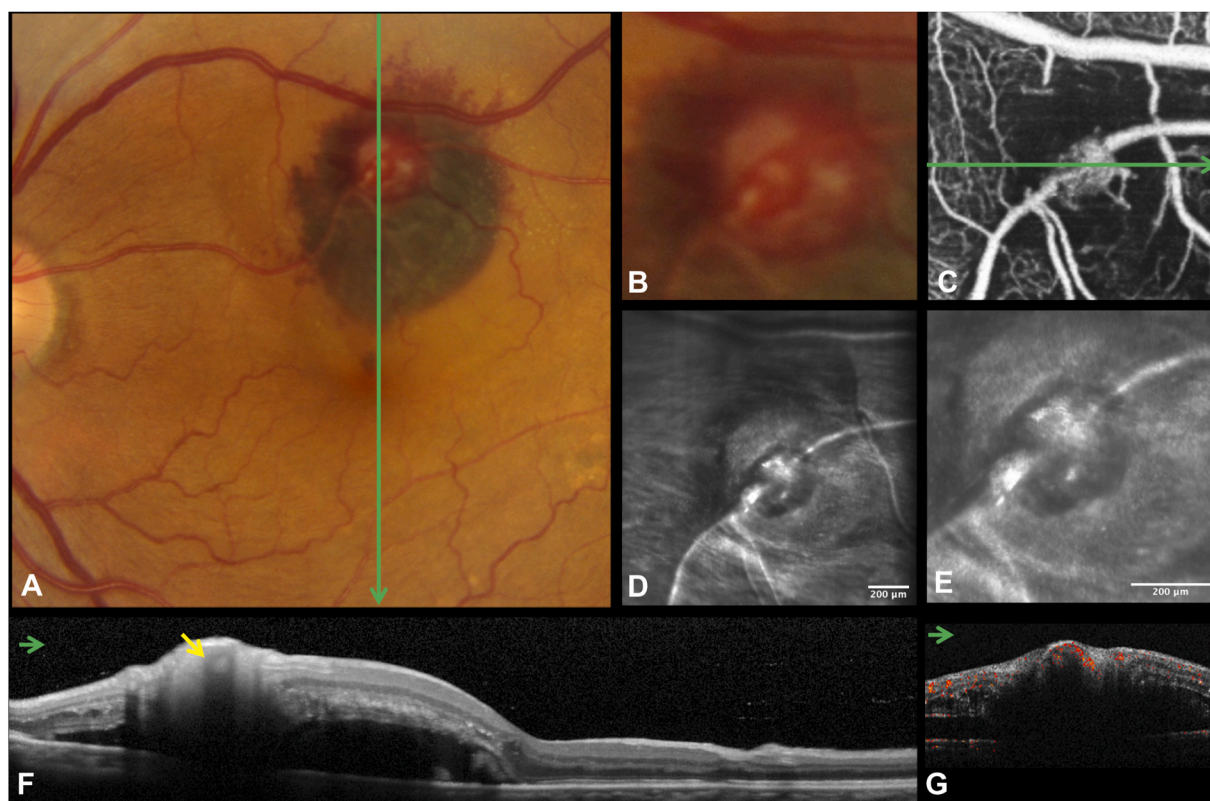
To date, direct laser photocoagulation is the first line treatment of RAM. Although focal laser treatment of a RAM can be effective and can achieve RAM closure resulting in a dry macula, the treatment is fraught with the risk of occlusion of the associated retinal artery and rupture of the RAM. Recently, the effectiveness and safety of the intravitreal anti-vascular endothelial growth factor (VEGF) injection has been reported.<sup>4</sup> However, real-time imaging of RAM for pre- and post-intravitreal anti-VEGF treatment has not yet been performed.

We have recently succeeded in elucidating the hemodynamic and ultrastructure of microaneurysms in retinal vein occlusion *in vivo* by using offset pinhole AOSLO.<sup>5</sup> In this case report, we administered an intravitreal injection of anti-VEGF for a ruptured RAM and examined the hemodynamic and structural changes pre- and post-treatment using OCTA and offset pinhole AOSLO. Although the mechanisms of RAM closure after anti-VEGF treatment were not fully elucidated, our case suggested that anti-VEGF treatment has an effect of organizing and remodeling the affected vessel wall, consequently stopping the pulsation of the RAM. Mansour and associates speculated that one of the possible mechanisms of RAM closure after anti-VEGF treatment is that VEGF blockade might alter the balance between coagulation and fibrinolysis inside the RAM leading to thrombosis and RAM remodeling.

A previous study reported macular edema recurrence after intravitreal anti-VEGF treatment in a few cases.<sup>4</sup> Although fluid control was

<sup>\*</sup> Corresponding author. 54 Shougoin Kawahara-cho, Sakyo-ku, Kyoto, 606, Japan.

E-mail address: [muraoka@kuhp.kyoto-u.ac.jp](mailto:muraoka@kuhp.kyoto-u.ac.jp) (Y. Muraoka).



**Fig. 1.** A ruptured retinal arterial macroaneurysm (RAM) was detected in the left eye of a 78-year-old-female. Color fundus photography and optical coherence tomography (OCT) show retinal and subretinal hemorrhage and serous retinal detachment around the RAM (**A**, **B**, and **F**) (arrow indicates the RAM in OCT). OCT (OCT-A1, Canon) shows blood flow signal within the RAM lesion (**C** and **G**). Offset pinhole adaptive optics scanning light ophthalmoscope shows pulsation and extreme thinning of the affected arterial wall with high resolution (**D-E**, and [Video 1](#)). (For interpretation of the references to colour in this figure legend, the reader is referred to the Web version of this article.)

successfully achieved with a one-time treatment in our case, the possibility of recurrence remained even if the RAM lesion was organized.

### 3. Conclusions

High resolution imaging with OCTA and offset pinhole AOSLO aid visualization of the hemodynamic and structural changes in a ruptured RAM pre- and post-intravitreal ranibizumab treatment *in vivo*. This case suggests that intravitreal anti-VEGF treatment may ameliorate the pathologic condition by organizing the affected vessel wall and by thrombosing within the RAM.

### Patient consent

Consent to publish this case report has been obtained from the patient in writing.

### Funding

No funding or grant support

### Authorship

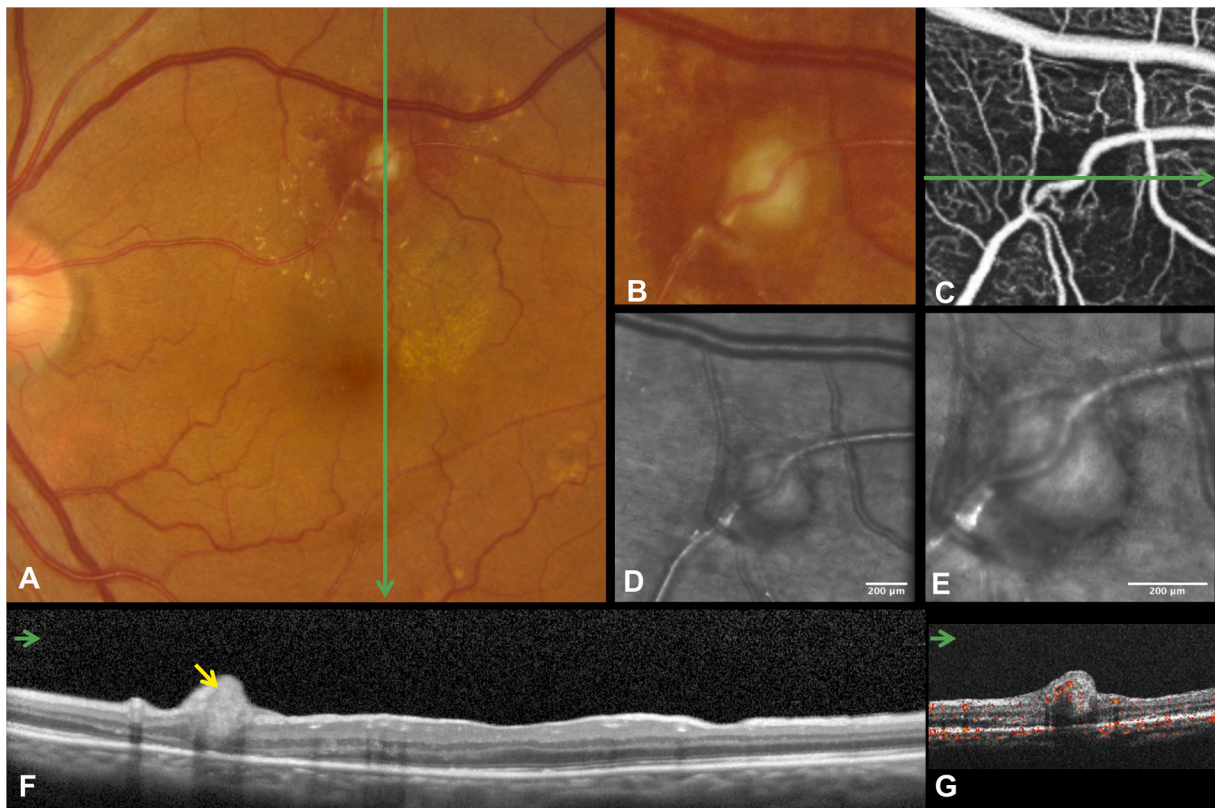
All authors attest that they meet the current ICMJE criteria for Authorship Acknowledgements: None.

### Declaration of competing interest

The following authors have no financial disclosures: SK, AU, YM, AT.

### Appendix A. Supplementary data

Supplementary data to this article can be found online at <https://doi.org/10.1016/j.ajoc.2021.101182>.



**Fig. 2.** Findings of the retinal arterial macroaneurysm (RAM) one month after intravitreal ranibizumab injection. Color fundus photography shows substantial regression of the retinal exudative changes (A) and the RAM appears greyish-white and smaller (B). Optical coherence tomography (OCT) shows complete resolution of the retinal hemorrhage and serous retinal detachment (F) (arrow indicates the RAM in OCT). Optical coherence tomography angiography shows the absence of blood flow signal in the RAM lesion (C and G). Offset pinhole adaptive optics scanning light ophthalmoscope video shows non-pulsative RAM lesion, suggesting organization of the affected arterial wall (D-E, and [Video 2](#)). (For interpretation of the references to colour in this figure legend, the reader is referred to the Web version of this article.)

## References

- Shults WT, Swan KC. Pulsatile aneurysms of the retinal arterial tree. *Am J Ophthalmol.* 1974;77:304–309.
- Lee EK, Woo SJ, Ahn J, Park KH. Morphologic characteristics of retinal arterial macroaneurysm and its regression pattern on spectral-domain optical coherence tomography. *Retina.* 2011;31:2095–2101.
- Alnawaiseh M, Schubert F, Nelis P, Wirths G, Rosentreter A, Eter N. Optical coherence tomography (OCT) angiography findings in retinal arterial macroaneurysms. *BMC Ophthalmol.* 2016;16:120.
- Mansour AM, Foster RE, Gallego-Pinazo R, et al. Intravitreal anti-vascular endothelial growth factor injections for exudative retinal arterial macroaneurysms. *Retina.* 2019; 39:1133–1141.
- Kadomoto S, Muraoka Y, Uji A, et al. Ultrastructure and hemodynamics of microaneurysms in retinal vein occlusion examined by an offset pinhole adaptive optics scanning light ophthalmoscope. *Biomed Opt Express.* 2020:11.